




Amoeba species colonizing the gills of rainbow trout (*Oncorhynchus mykiss*) in Swiss aquaculture

Stefania M. Vannetti^{1,2} | James W. Wynne³  | Chloe English⁴ | Christine Huynh⁵ |
 Ralph Knüsel² | Carolina de Sales-Ribeiro¹ | Maro Widmer⁶ | Gary Delalay¹  |
 Heike Schmidt-Posthaus¹ 

¹Department of Infectious Diseases and Pathobiology, Vetsuisse Faculty, Institute for Fish and Wildlife Health, University of Bern, Bern, Switzerland

²Fishdoc GmbH, Rain, Switzerland

³CSIRO Agriculture and Food, Tasmania, Hobart, Australia

⁴School of Biological Sciences, The University of Queensland, Queensland, Brisbane, Australia

⁵Nautilus Collaboration, Tasmania, Lucaston, Australia

⁶Interfaculty Bioinformatics Unit and SIB Swiss Institute of Bioinformatics, University of Bern, Bern, Switzerland

Correspondence

Stefania M. Vannetti, Department of Infectious Diseases and Pathobiology, Vetsuisse Faculty, Institute for Fish and Wildlife Health, University of Bern, 3012, Bern, Switzerland.

Email: stefania.vannetti@unibe.ch

Funding information

European Association of Fish Pathologists; Fish Farmers Switzerland; Swiss Federal Food Safety and Veterinary Office, Grant/Award Number: 714001610

Abstract

Nodular gill disease (NGD) is an infectious condition characterized by proliferative gill lesions leading to respiratory problems, oxygen deficiency and mortality in fish. Globally, NGD primarily impacts freshwater salmonids in intensive aquaculture systems. In recent years, numerous outbreaks of severe gill disease have affected more than half of the larger rainbow trout (*Oncorhynchus mykiss*) farms in Switzerland, mainly during spring and early summer. Mortality has reached up to 50% in cases where no treatment was administered. Freshwater amoeba are the presumed aetiological agent of NGD. The gross gill score (GS) categorising severity of gill pathology is a valuable first-line diagnostic tool aiding fish farmers in identifying and quantifying amoebic gill disease (AGD) in farmed marine salmonids. In this study, the GS was adapted to the NGD outbreak in farmed trout in Switzerland. In addition to scoring disease severity, gill swabs from NGD-affected rainbow trout were sampled and amoeba were cultured from these swabs. Morphologic and molecular methods identified six amoeba strains: *Cochliopodium* sp., *Naegleria* sp., *Vannella* sp., *Ripella* sp., *Saccamoeba* sp. and *Mycamoeba* sp. However, the importance of the different amoeba species for the onset and progression of NGD still has to be evaluated. This paper presents the first description of NGD with associated amoeba infection in farmed rainbow trout in Switzerland.

KEYWORDS

amoeba, next-generation sequencing, nodular gill disease, *Oncorhynchus mykiss*, rainbow trout, Switzerland

1 | INTRODUCTION

Gills are life-essential organs in fish. In addition to exchanging oxygen and carbon dioxide, gills play a role in nitrogen excretion and plasma pH regulation, homologous to the kidney in mammals (Evans et al., 2005; Olson, 1991). Because gills are in permanent contact with

the aquatic environment, they are a target for numerous pathogens, such as bacteria, viruses and parasites (e.g. amoeba). If fish are additionally stressed, infections with clinical signs and mortality may occur (Benhamed et al., 2014; Boerlage et al., 2020; Lima et al., 2021).

Amoeba are highly variable eukaryotic organisms distributed in soil and aquatic habitats, which can parasite the gills of

This is an open access article under the terms of the [Creative Commons Attribution-NonCommercial](https://creativecommons.org/licenses/by-nc/4.0/) License, which permits use, distribution and reproduction in any medium, provided the original work is properly cited and is not used for commercial purposes.

© 2023 The Authors. *Journal of Fish Diseases* published by John Wiley & Sons Ltd.

rainbow trout (*Oncorhynchus mykiss*) and cause disease (Daoust & Ferguson, 1985; Dyková et al., 2010; Dykova & Tysl, 2016; Tubbs et al., 2010). Several amoeba species have been found in salmonids: *Neoparamoeba perurans* causing amoebic gill disease (AGD; Boerlage et al., 2020; English, Swords, et al., 2019; English, Tysl, et al., 2019; Marcos-López & Rodger, 2020; Padrós & Constenla, 2021), alongside likely non-pathogenic strains, *Vexillifera* sp., *Pseudoparamoeba* sp., *Nolandella* sp. and *Vannella* sp. on the gills of Atlantic salmon (*Salmo salar*; English, Swords, et al., 2019; English, Tysl, et al., 2019). In rainbow trout with nodular gill disease (NGD), several species have been isolated from the gills, including, *Vannella* sp., *Naegleria* sp., *Protacanthamoeba* sp., *Acanthamoeba* sp. and *Hartmannella* sp. (Dyková et al., 2010; Padrós & Constenla, 2021; Perolo et al., 2019; Quaglio et al., 2016; Speare, 1999).

NGD is diagnosed by macroscopic and histopathologic examination of the gills (Padrós & Constenla, 2021). NGD is grossly characterized by multiple whitish nodular proliferations in the distal region of the gill filaments, often with diffuse white discoloration of the branchial arches, due to epithelial hyperplasia and/or excess mucus production. Gill histopathology shows multifocal nodular hyperplasia, lamellar fusion and often fusion between the adjacent filaments. Clinically, fish show signs of respiratory distress and often high mortality (Daoust & Ferguson, 1985; Dyková et al., 2010; Dykova & Tysl, 2016; Noble et al., 1997; Speare, 1999). Concurrent infections with bacteria, mainly *Flavobacterium* sp., are frequently detected on the gill surface of diseased fish (Daoust & Ferguson, 1986; Speare, 1999). To date, it is still unclear whether NGD is a multifactorial disease influenced by other pathogens.

So far, NGD has been described in Canada (Noble et al., 1997), New Zealand (Tubbs et al., 2010), Italy (Perolo et al., 2019; Quaglio et al., 2016), Germany (Dyková et al., 2010; Dykova & Tysl, 2016; Hoffmann et al., 1992), Poland (Antychowicz, 2007), Czech Republic (Dyková & Tysl, 2016) and Denmark (Buchmann et al., 2004; Jensen et al., 2020). However, no data are available for outbreaks in Switzerland, though several amoeba species have been described in Swiss water bodies (Gianinazzi et al., 2009). Despite NGD and the accompanying amoeba being reported across seven countries, it is unknown whether NGD can be caused by multiple amoeba species within one region or whether particular causal agents are regionally

specific. Deciphering the precise aetiology of NGD underpins developing effective disease management and treatment, and determining the causal agent begins with surveying what species are present on the gills with varying severity of pathology. This study described NGD in farmed rainbow trout in Switzerland and aimed to characterize the amoeba strains that colonize the gills with lesions compatible with NGD.

2 | MATERIALS AND METHODS

2.1 | Fish farms and sampling

Three hundred thirty-three fish from six rainbow trout farms in the Swiss midlands and prealpine regions (300–800 m a.s.l.) were sampled between March and December 2021 (Table 1). The selection of fish farms was based on the occurrence of clinical signs consistent with NGD. This included mortality, dyspnea, tachypnea, flared opercula and macroscopic gill lesions (i.e. white multifocal nodules and thickening of the filaments).

At each sampling event, the following farm design and water quality parameters were recorded: tank system (recirculation, partial recirculation, flow through), water source, tank number, fish stocking density, average fish weight, temperature, pH, dissolved oxygen, salinity, ammonium and nitrite.

Three farms are conventional, with a maximum stocking density of 80 kg/m³, and three are organic stocking a maximum of 20 kg/m³. The farms produce between 40 and 200 tons of rainbow trout annually. Each farm has 10–60 tanks for different rainbow trout age ranges.

Fish were euthanized by water exposure to 3 g Tricaine Pharmaq® (tricaine methanesulphonate, MS-222, Pharmaq) in 10 L tank water or electrocution (230 V, 16 Ampere for 3 min) followed by a gill cut.

2.2 | Macroscopic assessment of fish

For each fish, gross gill lesions were assessed using a gill score (GS). This gill scoring system was adapted from the scoring system

Fish farm	Water source ^a	System design ^b	Fish sampled	Tanks sampled	Sampling events
A	Sp, Gr, Su	Pr	87	15	7
B	Sp	Pr	115	22	7
C	Gr, Su	Re	28	6	2
D	Sp, Gr, Su	Pr	38	11	3
E	Su	Ft	40	8	2
F	Gr	Ft/Pr	25	5	1
Total			333	67	22

^aSp=spring water, Gr=ground water, Su=surface water.

^bPr=partial recirculation, Re=recirculation, Ft=flow through.

TABLE 1 Participating fish farms, number of fish sampled per fish farm, number of involved tanks and number of sampling points between March and December 2021.

developed for AGD and measures the severity of NGD based on the abundance of gross gill lesions (Taylor et al., 2009). The scoring system uses a scale of 0 (no lesions) to 5 (lesions covering >50% of the gill tissue; Boerlage et al., 2022; Taylor et al., 2009; Figure 1). To document the general health condition and the GS, the left and right side of the body and the gills of each fish were photographed with an Olympus TG-6 camera.

2.3 | Microscopic assessment of gills and histopathology

From the first left gill arch from each fish, 2 mm of gill tissue was carefully dissected and placed under a light microscope as a wet mount for examination of external parasites, including amoeba. The number of amoeba on the gills of each gill clip was classified on a scale (amoeba abundance score) from 0 (no visible amoeba) to 4 (>50% of visible gill surface covered with amoeba) as detailed in Table 2.

The first left gill arch from each fish was immediately fixed in 10% buffered formalin for 24 h for histopathological examination. At the Institute for Fish and Wildlife Health (FIWI), University of Bern, the fixed gills were dehydrated in ethanol series and embedded in paraffin, sectioned at 4 µm and stained with haematoxylin–eosin (H&E).

2.4 | Amoeba isolation and culture maintenance

A sterile cotton swab (Henry Schein®) was passed over all four right gill arches and placed into 5 mL of 0.2 µm filtered (Filtropur S 0.2, Sarstedt AG & Co. KG) fresh water, in a 15 mL tube (TPP®). The gill swabs were transported in a cool box to the FIWI for further processing. Once in the laboratory, the samples were vortexed for 30 s, the swabs were removed, and the resulting suspension was poured into a culture flask (ClearLine® tissue culture flask, 50 mL). The culture flasks were incubated at 15°C for 3 months. Cultures were fed weekly with 2 mL of autoclaved 0.01% malt extract (Malt Extract Broth, Carl Roth GmbH + Co. KG) in distilled water.

TABLE 2 Amoeba abundance score of gill clips.

Abundance	Description
0	No visible amoeba
1	1 amoeba to ≤5% of gill surface examined covered with amoeba
2	>5% to ≤20% of gill surface examined covered with amoeba
3	>20% to ≤50% of gill surface examined covered with amoeba
4	>50% of gill surface examined covered with amoeba

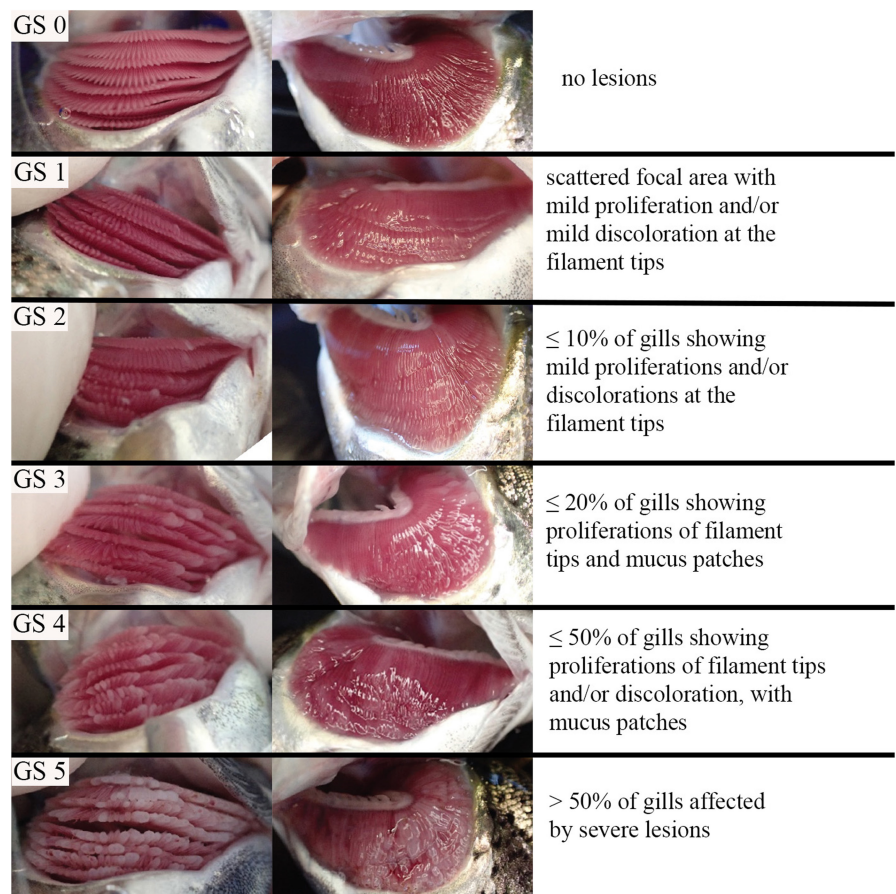


FIGURE 1 GS for NGD in rainbow trout. Left panel: gills underwater. Middle panel: gills outside water. Right panel: GS description.

2.5 | Establishment of amoeba monocultures

Amoeba culture flasks were checked every 2 days for the presence of amoeba with a Nikon inverted microscope (Nikon Eclipse TS100, Nikon Corporation) at 200 \times and 400 \times magnification. Single amoeba were isolated by pipetting into an angiogenesis 96-well plate. After 1 week, amoeba were transferred from the angiogenesis 96-well plate to a petri dish with a glass bottom (WillCo-dish®, Ø35/22 mm, WillCo Wells BV) and further incubated at 15°C for an additional week.

Pictures were taken from each amoeba culture with the DeltaVision Elite microscope with the software SoftWoRx (Version 6.5.2, GE Healthcare Companies) at a magnification of 600 \times and 1000 \times .

2.6 | DNA extraction, PCR and Sanger sequencing of amoeba in cultures

Culture samples from both, mixed and monocultures, were collected with a cell scraper (Sarstedt, Inc.) and pipetted into a 1.5 mL Eppendorf tube with a 1.5 mL culture medium. This material was centrifuged at 16000 rpm for 10 min. DNA was extracted using DNeasy Blood and Tissue Kit (QIAGEN, Hilden, Deutschland) according to the manufacturer's instructions. DNA was quantified with NanoDrop One (ThermoFisher Scientific) and stored at -20°C until further examination.

To identify amoeba species, a 600–900 bp fragment of the 18S rRNA gene was amplified using universal eukaryotic primers Ami6F1 (5' CCAGCTCCAATAGCGTATATT 3') and Ami9 (5' GTTGAGTCGAA TTAAGCCGC 3'; English, Swords, et al., 2019; Thomas et al., 2006). The Kapa Taq PCR Protocol (KapaBiosystems, Manufacturing, R&D, Cape Town, South Africa) was followed for a 25 μ L reaction, with a thermoprofile of denaturation at 95°C for 3 min, followed by 35 cycles at 95°C for 30 s, 60°C for 2 min, 72°C for 2 min, with a final extension time at 72°C for 2 min. Amplified products were visualized on a 2% agarose gel and all bands between 600 and 900 bp were excised and gel purified. The positive amplified products were sent to Microsynth AG for Sanger sequencing (Supplementary Material, Table S5).

Based on the sequencing results, two pairs of PCR primers were designed to amplify a 204 bp and 222 bp region within the 18S ribosomal gene for two amoeba genera: *Cochliopodium* spp. and *Naegleria* spp., respectively. All primers (cochFWD 5' AGCGGTGAAATGCG TAGACT 3', naegFWD 5' TGCTTAAAGCGGGCTATGAT 3', naegREV 5' TGGTCACATGAGGGTCTCAG 3'), except cochREV (5' ACATT GCTTCATTAATAGTACCA 3') were designed in primer3 (<https://bioinfo.ut.ee/primer3-0.4.0/>, Koressaar & Remm, 2007; Untergasser et al., 2012 version 0.4.0) using the default setting. CochREV was designed manually to ensure maximal specificity to *C. minus* and *C. pentarifurcatum*. The specificity of primers was tested in silico using multiple sequence alignments (Supplementary Material, Table S6) and by testing other amoeba strains, kindly provided by Tomas Tým, DOE Joint Genome Institute and Molecular Biophysics & Integrated Bioimaging, University of South Bohemia, České Budějovice, Czech Republic (Supplementary Material, Table S7).

The following PCR protocol was used: thermoprofile of denaturation at 95°C for 15 minutes, followed by 35 cycles at 95°C for 30 s, 45 s with annealing temperature specific to the primers (primers detecting *Cochliopodium* sp.: 50°C, primers detecting *Naegleria* sp. 51°C), 72°C for 45 s, with a final extension at 72°C for 45 s. The successfully amplified products were visualized in a 1.6% agarose gel. The amplified DNA was sent to Microsynth AG to be Sanger sequenced. Sequences were blasted by BLASTn (NCBI) (BLAST: Basic Local Alignment Search Tool (nih.gov)) to determine the best match.

2.7 | Next-generation sequencing and 18S rRNA assembly analysis

Since PCR and Sanger sequencing did not identify all morphologically different amoeba strains, eight DNA extracts of cultures showing distinct morphologies under light microscopy were sent for next-generation sequencing (NGS) with Illumina Nextera® DNA Library Preparation Kit (Illumina® DNA Prep, (M) Tagmentation (96 Samples)/20018705) at the NGS platform at Vetsuisse Faculty, University of Bern, Switzerland. The fragment size ranged from 200 to 2000 bp. The IDT® for Illumina® DNA/RNA UD Indexes Set A, Tagmentation (96 Indices, 96 Samples), 20027213 was used as Index Kit for the library prep. Both libraries were sequenced on an Illumina NovaSeq 6000 (Illumina; 2 \times 150 bp), generating 103–353 Mio reads per sample.

The data of sequencing lanes were merged with the sequencing lanes of the samples to obtain two fastq files for each sample (forward and reverse reads). The reads were trimmed with trimmomatic PE (Bolger et al., 2014; SLIDINGWINDOW:4:8 MINLEN:127). A collection of 18S ribosomal RNA genes, including the sequences JQ271757.1 (*Vannella* sp.), JF298257.1 (*Cochliopodium minus*) and DQ768719.1 (*Naegleria fultoni*), were concatenated in a multi FASTA-File (Supplementary Material, Table S8). The trimmed and merged reads of the samples were mapped to this file using bowtie2 version 2.3.4.1 (Langmead & Salzberg, 2012; -no-unal-local). Mapped reads were extracted using samtools version 1.8 and were de novo assembled using spades version 3.10.1 (Altschul et al., 1990; -careful -t 2 -m 16; Supplementary Materials, Table S9). Of the resulting assemblies, contigs <700 bp were filtered using bioawk (-c fastx '{if(length(\$seq)>700) {print ">"\$name; print \$seq}}') and blasted (megablast) against the NCBI nucleotide collection (date: 19.12.2022) (blastn -max_target_seqs 5 -max_hsps 1 -remote) using version 2.13.0+.

To generate the phylogenetic tree, all the de novo assembled contigs with blast hits belonging to taxa *Naegleria*, *Vannella*, *Ripella*, *Cochliopodium*, *Mycamoeba* and *Saccamoeba* were collected. In addition, 18S sequences with association to NGD from the NCBI database were included. Then contigs containing common blocks with a total length >200 bp were aligned with muscle (default settings). Blocks of regions where all positions were present in each sequence were defined with Gblocks -b4 - (Talavera & Castresana, 2007). Sequences that led to a total common block length smaller than 200 bp were excluded from multiple alignments. The neighbour-joining algorithm

was used to estimate the phylogenetic tree. As an outgroup, the 18S gene (HE650907.2) of *Paramecium multimicronucleatum* was used.

2.8 | GS and amoeba abundance analysis

The data were collected to a Microsoft Excel 2007 table (Microsoft Excel, <https://www.microsoft.com/en-gb/>, RRID:SCR_016137) and loaded in an R Script with RStudio 2022.12.0+353 (<https://www.rstudio.com/>, RRID:SCR_000432) and R 4.2.2 'Innocent and Trusting' (R Project for Statistical Computing, <https://www.r-project.org/>, RRID:SCR_001905) with package readxl 1.4.1 (<https://cran.r-project.org/web/packages/readxl/index.html>, RRID:SCR_018083). Analyses were performed with packages dplyr 1.0.10 (<https://cran.r-project.org/web/packages/dplyr/index.html>, RRID:SCR_016708) and tidyr 1.2.1 (<https://cran.r-project.org/web/packages/tidyr/index.html>, RRID:SCR_017102). Figures were computed in R with packages ggplot2 3.4.0 (<https://cran.r-project.org/web/packages/ggplot2/index.html>, RRID:SCR_014601) and cowplot 1.1.1 (<https://cran.r-project.org/web/packages/cowplot/index.html>, RRID:SCR_018081).

3 | RESULTS

3.1 | Sampled fish parameters

Of the 333 fish sampled, 231 showed NGD-like gross changes. Fish weight ranged between 50 and 300g, except for 60 fish weighing less than 50g and 11 adult fish weighing >1kg (Table 3). Out of the 55 tanks analysed, 24 had a stocking density of 3–30kg/m³, 11 of 31–60kg/m³ and 7 of 61–80kg/m³ (Table 3).

3.2 | Water quality

The average water parameters measured during the sampling events are shown in Table 4. Temperature, pH and dissolved oxygen were within the range well accepted for rainbow trout (SR 455.1, 2018).

TABLE 3 Range of weight of the fish and stocking density at each fish farm.

Fish farm	Fish weight (g)	Stocking density (kg fish/m ³)
A	7–370	3–25
B	0.4–337	8–75
C	74–3540	11–29
D	77–2000	27–80
E	165–369	12–18
F	4.7–53	20–80

Salinity in six farms was slightly increased, probably due to prior treatment with salt.

3.3 | Clinical signs

Affected rainbow trout showed apathy, tachypnea, dyspnea and abnormal swimming behaviour at the water surface with flared opercula. Mortality reached 0.1%–0.5%/day for 3–4 days until animals were treated with salt or formalin. Without treatment, mortality reached 2%–2.5%/day.

3.4 | Gross lesions and gill score

Gills from fish affected by NGD showed multifocal whitish nodules on the tips of the filaments, focal to multifocal or focally extensive mucus deposition, thickened gill filaments and discoloration. A GS was assigned to each fish to correlate the severity and extensiveness of the gill lesions (Figure 1). Figure 2 shows the number of fish for each combination of GS and the semi-quantitative evaluation of the amoeba. In fish with a low GS (0 or 1), the median semi-quantitative evaluation score of amoeba found was low (1 and 2, respectively), whereas in fish with a higher GS (2, 3, 4 or 5), the median semi-quantitative evaluation score of amoeba was higher (3, 3, 3 and 4, respectively; Figure 2). The Spearman's rank correlation coefficient was 0.448. No correlation was found between the type of farm, fish density, semi-quantitative evaluation of amoeba and GS.

On the wet mount under the light microscope, lamellar hyperplasia and high amounts of mucus were visible on all gills affected by NGD. On the lamellar surface, amoeba were present (Figure 3c,d).

3.5 | Histopathology

Gills infected by amoeba (independent of the GS) showed moderate to severe epithelial hyperplasia with lamellar fusion and squamous cell metaplasia, mainly affecting the distal tips of the filaments (Figure 4a). Multifocally, fused lamellae form cystic empty spaces (pseudocysts). Hyperplastic areas were covered with amoeba of different morphology (Figure 5); large, up to 10µm in diameter, polymorphic organisms with a dense amphophilic nucleus (Figure 5a,c); roundish organisms, approximately 5µm in diameter (Figure 5a,b) and elongated organisms, 5 × 10µm (Figure 5a,b). Multifocally, these organisms were also located in pseudocysts (Figures 4 and 5). In the filaments, infiltration by macrophages, lymphocytes and increased numbers of eosinophilic granular cells was present (Figure 4b). Hyperplastic areas showed increased single-cell necrosis and multifocal small areas of necrosis (Figure 5a). Multifocally, bacterial colonies of elongated, filamentous bacteria (*Flavobacteriaceae*) were present between the lamellae and filaments (Figure 4b).

TABLE 4 Water parameters of fish farms.

Water Parameters	Total		Farm A		Farm B		Farm C		Farm D		Farm E		Farm F		Accepted range
	Average	±SD	Average	±SD	Average	±SD	Average	±SD	Average	±SD	Average	±SD	Average	±SD	
T (°C)	11.5	2.3	11.2	2.2	11.6	2.3	12.8	2.4	12.2	2.2	11.6	2.2	15.5	0.3	Max 22
pH	7.7	0.2	7.7	0.2	7.7	0.2	7.5	0.1	7.7	0.2	7.8	0.2	7.7	0.2	5.5–9.0
Oxygen (mg/L)	8.2	2.3	8.2	2.4	8.2	2.3	7.0	2.0	8.2	2.4	9.7	2.4	8.8	0.6	Min 5.0
Oxygen (%)	81.2	22.6	81.3	23.3	81.5	23.0	72.1	20.6	83.1	23.5	96.2	22.6	93.8	6.6	60–200
Salinity (ppt)	0.2	0.5	0.1	0.6	0.2	0.5	0.4	1.0	0.2	0.6	0.0	0.0	0.1	0.0	Depends on the fish's age (Noga, 2010)
Ammonia (mg/L)	0.005	0.003	0.003	0.002	0.005	0.003	0.006	0.002	0.005	0.002	0.005	0.002	0.006	0.001	Max 0.01
Nitrite (mg/L)	0.3	0.8	0.4	0.9	0.3	0.8	0.5	1.0	0.4	0.9	0.5	1.1	0.0	0.0	Max 1.5 (pH and temp dependent)

3.6 | Amoeba culture and morphology

Six amoeba genera were isolated from 52 cultures, identified by morphology and sequence homology: *Naegleria* sp. (Alexeieff, 1912 emend. Calkins, 1913) (Figure 6a), *Cochliopodium* sp. (Hertwig et Lesser, 1874) (Figure 6b), *Vannella* sp. (Bovee, 1965) (Figure 6c), *Ripella* sp. (Smirnov, 2007) (Figure 5d), *Saccamoeba* sp. (Page, 1967) (not shown) and *Mycamoeba* sp. (Blandenier, 2017) (Figure 6e). Additionally, an unidentified amoeba has been photographed in the cultures (Figure 6f). The amoeba were isolated from fish with gill scores ranging from 1 to 5. The *Naegleria* strain had a mostly tubular, elongated morphotype with lobose pseudopodia and a hyaline cap at the anterior during locomotion (Figure 6a). A flagellated and non-flagellated stage of trophozoites was identified in the *Naegleria* strain. Flagellated trophozoites displayed two flagellae at the posterior end (see arrows in Figure 6a). The *Cochliopodium* strain had lens-shaped trophozoites with a distinct hyaline margin lined with small reticulose subpseudopodia. The central cytoplasm hump appeared granular in light microscopy (Figure 6b). The *Vannella* strain had the distinct fan-shaped locomotive morphotype of *Vannellida*. Trophozoites had no discrete pseudopodia but instead had a wide anterior hyaloplasm. The cytoplasm contained distinct vacuoles (Figure 6c). The *Ripella* strain is also a fan-shaped amoeba, but it varied between elongated or discoid shapes during the locomotion. Trophozoites had an anterior hyaloplasm and no discrete pseudopodia (Figure 6d). The *Mycamoeba* strain was a relatively small amoeba with an elongated and flattened shape. It had lobose pseudopodia during locomotion and sometimes small pseudopodia would present from the larger conical-shaped pseudopodia (Figure 6e). The unidentified amoeba strain was relatively large and had a dactylopodial-like morphotype with numerous conical subpseudopodia extending from the hyaline edge and granular cytoplasm. It presented variable shapes during locomotion (Figure 6f).

3.7 | Amoeba species identification

In 4/52 amoeba cultures, *Cochliopodium* spp. and *Naegleria* spp. were identified by Sanger sequencing (Table S5). The eukaryotic universal primers also amplified additional flagellates, ciliates and algae. The subsequent Sanger sequence data were homologous with *Spumella sinechrysos*, *Cercomonas* sp., *Paracercomonas* sp., *Cercozoan*, *Sarcocystis* sp., *Chrysophyte*, *Stramenopile*, *Spongomonadidae*, *Procrystobia sorokini*, *Leucosporidium scottii*, *Allantion* sp., *Thaumatomonadida*, *Glissomonadida*, *Holosticha pullaster*, *Tetrahymena vorax*, *Balantidium ctenopharyngodoni*, *Paraphysomonas* sp. and *Neobodo designis*.

Using genus-specific primers, *Cochliopodium* sp. was found in DNA extracts from 27 cultures and both amoeba strains (*Cochliopodium* sp. and *Naegleria* sp.) were concurrently identified in 16 cultures (Table S5). The *Cochliopodium* and *Naegleria* primers were able to amplify all *Cochliopodium* respectively *Naegleria* strains, but not other amoeba strains (Supplementary Material, Table S6).

FIGURE 2 Amount of amoeba on a gill smear determined by light microscopy in relation to gill score (GS) of each fish. The size of the square represents the relative frequency of observations in the given combination.

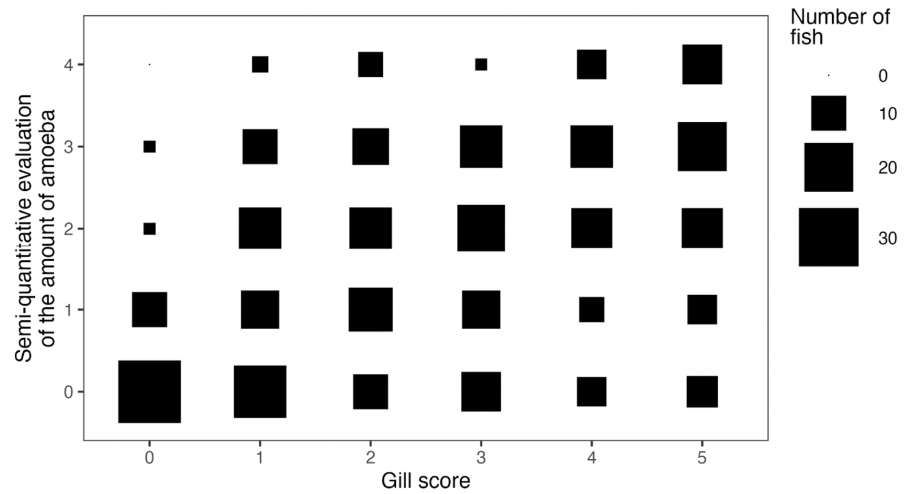
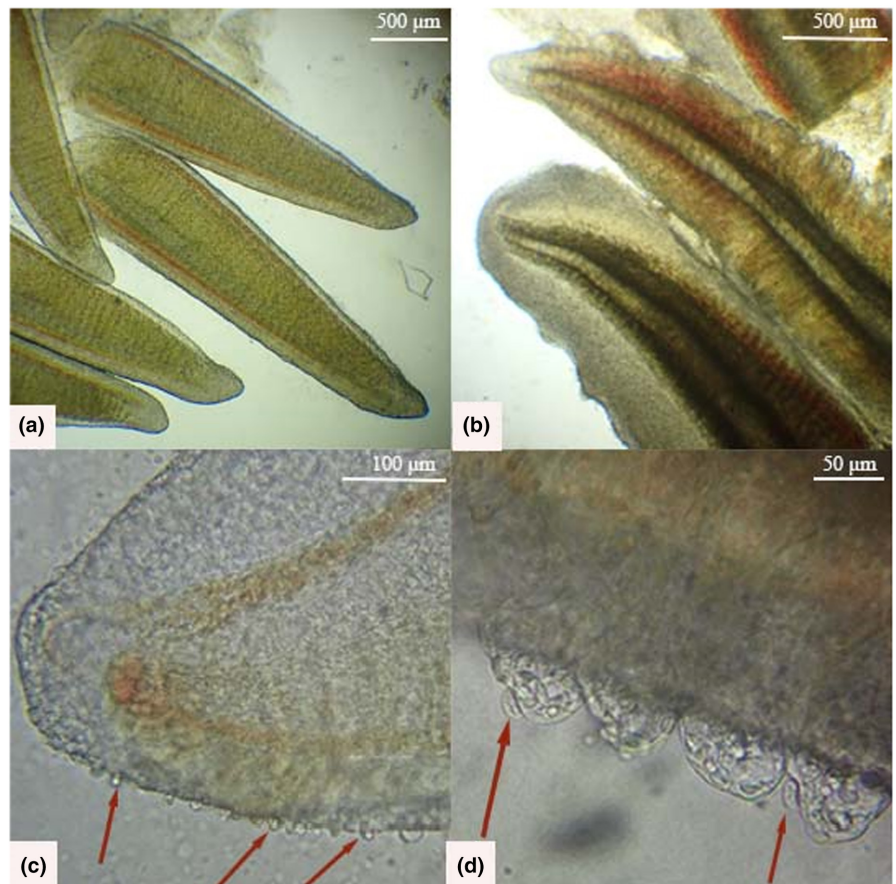


FIGURE 3 Rainbow trout gill lamellae observed through wet mounts under light microscopy. (a) healthy lamellae, (b) gill with lamellar hyperplasia and a high amount of mucus, (c) filament with a high amount of mucus and amoebae on gill surface (red arrows), (d) lamellar hyperplasia and amoeba attached on the lamellar surface (red arrows).



The reads of the samples that mapped to the collection of 18s sequences were used for *de novo* assembly in the NGS analysis. The resulting contigs with length >700bps were then compared to sequences in the NCBI database using Blastn and the five best hits were reported. This yielded sequence identities >90% for *Naegleria* sp., *Saccamoeba* sp., *Vannella* sp., *Ripella* sp. and *Mycamoeba* sp. (Table S6).

3.8 | Phylogenetic tree of *de novo* sequences

The neighbour-joining algorithm was used to estimate the tree based on 217 common sites. The resulting tree shows that contigs clustered

together with NCBI 18s sequences from the corresponding species (Figure 7).

4 | DISCUSSION

This study identified seven amoeba strains from rainbow trout gills with NGD in Swiss freshwater aquaculture. Amoeba are free-ranging organisms in water and soil, with the potential to causing disease and death in humans and animals (Padrós & Constenla, 2021). In saltwater salmonids, *Neoparamoeba perurans* causes AGD and is accompanied by multiple other amoeba species that are far less

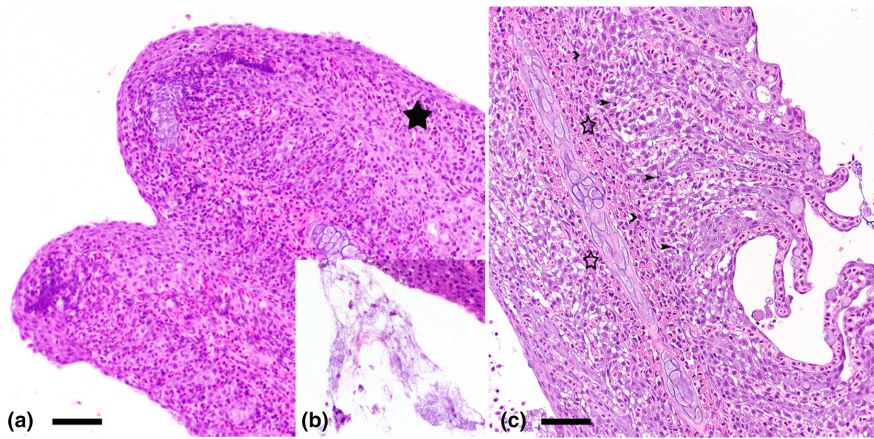


FIGURE 4 Histological section of rainbow trout gills. (a) Lamellae show epithelial hyperplasia with lamellar fusion and squamous metaplasia at the tips of the filaments (star). Bar = 100 μm . (b) Bacterial colonies of filamentous bacteria (Flavobacteriaceae). (c) Filaments are infiltrated with high amounts of eosinophilic granular cells (open stars), few lymphocytes (closed arrowheads) and macrophages (open arrowheads). Bar = 50 μm . HE stain.

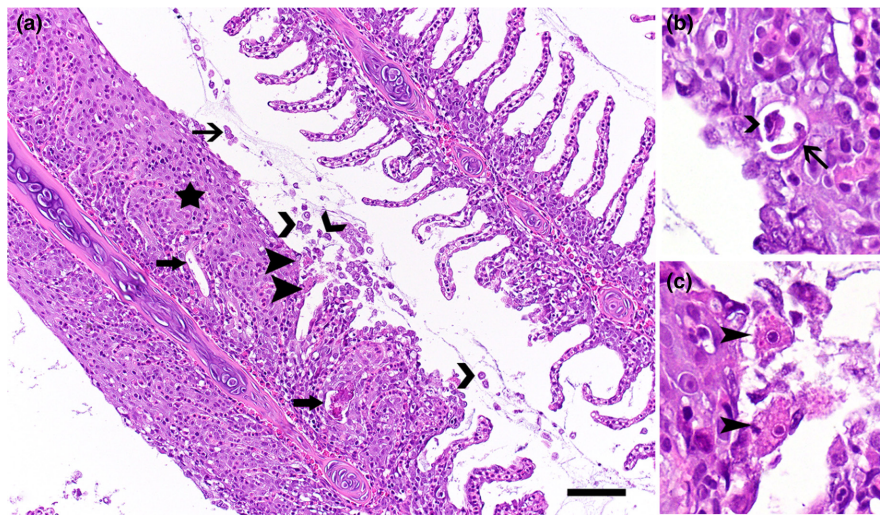


FIGURE 5 Histological section of rainbow trout gills infected with amoeba. (a) Lamellae show epithelial hyperplasia with lamellar fusion (star) and formation of pseudocysts (arrows with closed arrowhead). Hyperplastic areas are covered with different types or forms of amoeba, roundish (open arrowhead), large polymorphic (closed arrowhead) and elongated (arrow). Bar = 50 μm . (b) Higher magnification, roundish organisms, approximately 5 μm in diameter (open arrowhead); elongated organisms, 5 \times 10 μm (arrow with open arrowhead). (c) Higher magnification, large, up to 10 μm in diameter, polymorphic organisms with a dense amphophilic nucleus (closed arrowheads). HE stain.

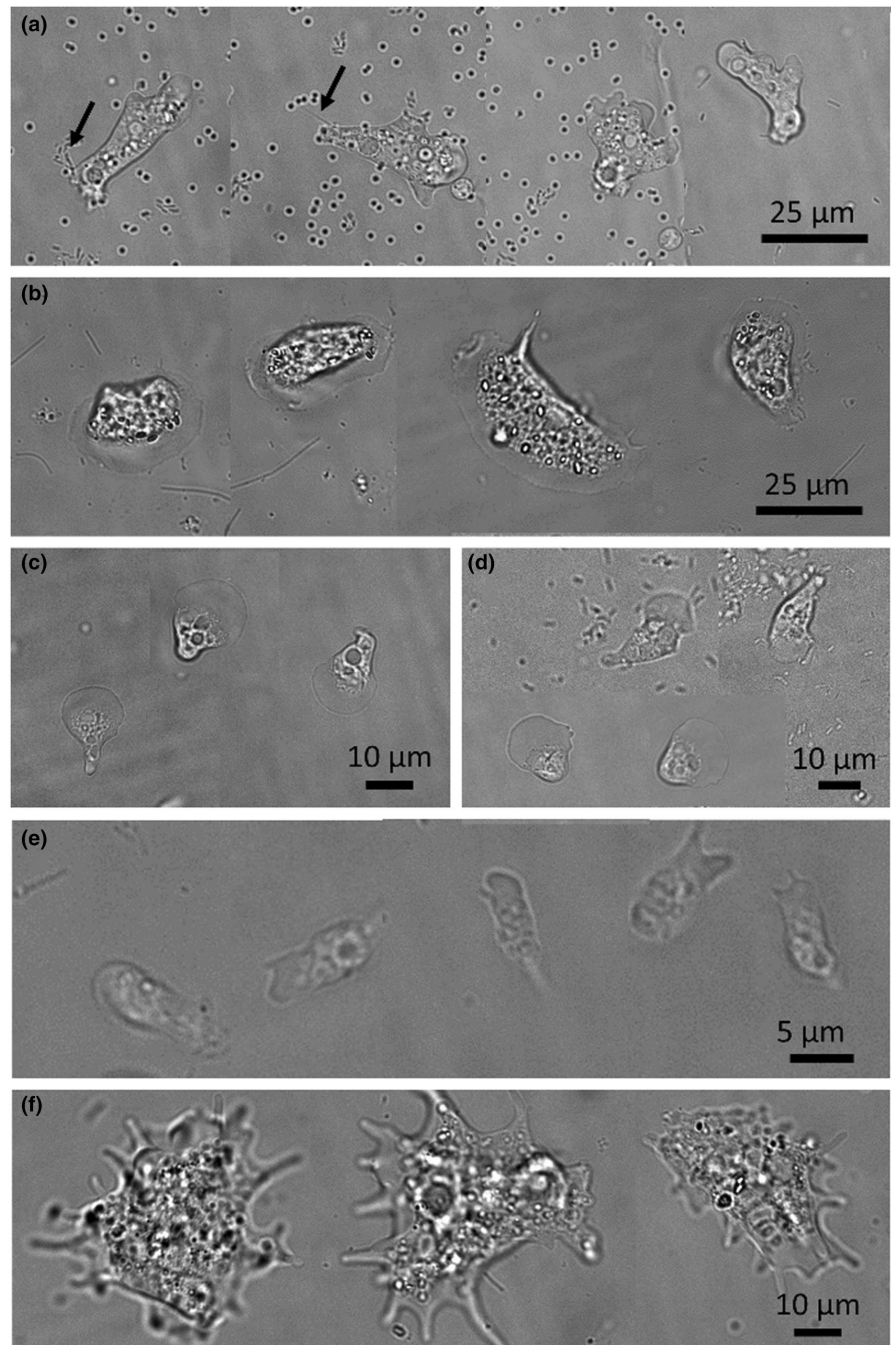
abundant on the gills than *N. perurans* (Boerlage et al., 2020; Cano et al., 2019; Crosbie et al., 2012; Dyková & Lom, 2004; English & Lima, 2020; English, Swords, et al., 2019; English, Tymł, et al., 2019; Herrero et al., 2018; Kim et al., 2017; Lima et al., 2017; Marcos-López & Rodger, 2020; Nowak et al., 2014; Padrós & Constenla, 2021; Taylor et al., 2009). The analogous disease in freshwater fish is NGD. However, the causative agent of NGD remains unclear (Padrós & Constenla, 2021) and a multi-amoeba and multifactorial aetiology has also been suggested (Dykova & Tymł, 2016). Several amoeba species have been described in NGD-affected fish farmed in Europe. The genus *Vannella* sp. was isolated from the gills of rainbow trout in Danish fish farms (Jensen et al., 2020); *Vannella* sp., *Hatmannella* sp., *Naegleria* sp., *Protacanthamoeba* sp. and *Acanthamoeba* sp. were described in German fish farms (Iva Dyková et al., 2010; Hoffmann et al., 1992). More recently, *Roghostoma minus* was postulated as the primary cause of NGD in rainbow trout farmed in the Czech Republic based on its presence in all diseased fish that were examined, whereas *Acanthamoeba*, *Vermamoeba*, *Naegleria* and *Vannella*

were also isolated from the gills of diseased fish but were less abundant (Dykova & Tymł, 2016).

In Switzerland, amoeba colonizing rainbow trout gills with lesions were found using histopathology since 2007 (Pers. Commun., fishdoc GmbH, FIWI, University of Bern). From 2007 to 2011, the number of cases was relatively low and mortality was not as high as in more recent outbreaks. Since 2012, the prevalence of diseased fish with the presence of amoeba has increased each year (Pers. Comm., fishdoc GmbH). In recent years, several fish farms experienced NGD problems. The awareness of the disease among Swiss fish farmers also increased since the start of this study. Therefore, increased numbers of reporting could be the reason for higher prevalence data.

Since amoeba feed on bacteria and cellular debris, amoeba prevalence and concentration can be correlated with the level of organic material in water (Lasjerdi et al., 2011; Loret & Greub, 2010). Likewise, soil particles and river sediments present after heavy rainfalls are favourable habitats for aquatic amoeba (Dykova &

FIGURE 6 Light microscopy of cultured amoeba strains isolated from gills of rainbow trout with signs of NGD (a) *Naegleria* sp., flagellae (arrows); (b) *Cochliopodium* sp.; (c) *Vannella* sp.; (d) *Ripella* sp.; (e) *Mycamoeba* sp.; (f) unidentified amoeba.



Tyml, 2016). Changes in weather conditions (lower average rainfall) during recent years may be the cause of higher case numbers, due to insufficient fresh water and consequently increased amounts of debris in the fish tanks.

Here, six amoeba strains plus an unidentified strain were isolated from diseased gills, including *Cochliopodium* sp., *Naegleria* sp., *Vannella* sp., *Ripella* sp., *Saccamoeba* sp., *Mycamoeba* sp. and the unidentified but morphologically distinct stain. Three of them, *Cochliopodium* sp., *Naegleria* sp. and *Vannella* sp., have already been associated with NGD (Dyková et al., 2010; Dyková & Lom, 2004; Dykova & Tyml, 2016; English & Lima, 2020). This study is the first to report *Ripella* sp., *Saccamoeba* sp. and *Mycamoeba* sp. being isolated from NGD-affected gills. However, further studies are needed

to assess the virulence of the different amoeba species and their importance in disease development. In addition, new cultures and subsequent analyses are necessary to identify the seventh amoeba strain.

Hypertrophy and hyperplasia of the lamellar epithelium are typical responses of fish gills to several non-infectious (e.g. chronic exposure to pollutants, dietary deficiency) and infectious conditions (e.g. bacterial gill disease, ciliate and flagellate parasites; Daoust & Ferguson, 1985; Speare & Ferguson, 2006). In the present study, gill infection by amoeba resulted in moderate to severe multifocal epithelial hyperplasia. However, in contrast to other conditions causing diffusely distributed hyperplasia along the gill filaments (Daoust & Ferguson, 1985), here, it affected mainly

the epithelial cells (Padrós & Constenla, 2021; Quaglio et al., 2016) and inflammatory infiltrate have also been reported to be associated with NGD (Daoust & Ferguson, 1985; Quaglio et al., 2016). However, these are not constant features of NGD (Padrós & Constenla, 2021).

The histological identification of amoeba may be challenging considering their resemblance with exfoliated cells or other cell debris, especially in less-affected gills (Frasca et al., 2018) or in the late stage of the disease (Dyková et al., 2010). Hence, wet mounts (Frasca et al., 2018), culture (Robinson, 1968) as well as PCR (Frasca et al., 2018) are essential complementary diagnostic tools.

Since 18s rRNA sequences of amoeba species have a length of approximately 2300bps and our phylogenetic tree relied on the identified common blocks with a total length of 243 sites, this tree does not fully comply with evolutionary tree gold standards. Nevertheless, this finding suggests that the assemblies yielded results similar to the 18s sequences of species of interest. For example, the samples K91_4A9_S4 and K78_S_S3 demonstrated great similarity to *Ripella* sp. Furthermore, since we performed a comparison to the NCBI database, the resulting hits cannot be used for confident species identification. However, they do suggest the presence of the corresponding species.

Culture is a valuable method to detect amoeba presence. However, the occurrence of disease, severity of the lesions, and abundance of amoeba species cannot be determined with cultures. In addition, cultures are often overgrown by bacteria or other parasites, and isolating a single amoeba is challenging. Amoeba can also be identified in direct smears under light microscopy. Here, the number of amoeba was higher at higher gill scores. Despite this, a few amoeba may be enough to cause significant gill lesions. Hence, the number of amoeba in the gills is not necessarily relevant for developing the disease. Conversely, in AGD the *N. perurans* abundance on the gills plays a role in disease severity (Bridle et al., 2010; English, Swords, et al., 2019). Other pathogenic organisms may also be involved in the development of gill lesions. For example, *Flavobacterium columnare* (Slinger et al., 2021), Salmon gill poxvirus (Gjessing et al., 2017), or concurrent infections with bacteria, viruses, or parasites (Downes et al., 2018; Herrero et al., 2018). However, whether they act as a primary or secondary pathogen in the development of the disease is unclear.

Each amoeba strain likely also plays different roles in NGD, such as non-pathogenic bystanders, opportunistic pathogens that become parasitic after a primary insult or the main disease-causing agent.

NGD-related clinical symptoms seen in Swiss fish farms were comparable to the ones previously described (Dyková et al., 2010; Dykova & Tysl, 2016; Jensen et al., 2020; Quaglio et al., 2016). Fish weighing 50–300g were mainly affected, but outbreaks in younger and older fish were also observed. Similarly, in Italy, fish with approximately 100g were primarily infected (Quaglio et al., 2016). Here, disease outbreaks were recorded when the water temperature rose in spring. In contrast, Quaglio et al. (2016) observed higher

mortality in winter months. When untreated, mortality was higher in Swiss fish farms, even under favourable husbandry conditions, as already described in other studies (Padrós & Constenla, 2021; Quaglio et al., 2016). Analysed water parameters were identified to be in acceptable ranges (SR 455.1, 2018). Even though high density has been correlated with increased stress and decreased immunity (Segner et al., 2012), in the present study, high density was not associated with increased disease outbreaks. Many other factors, like decreased water flow, may play a role in the development of the disease.

GS seems to be a useful first-line diagnostic method for NGD in fish farms, as we found that fish with lower GS tended to have a lower semi-quantitative evaluation score of amoeba than fish with a higher GS. However, gill lesions, such as epithelial hyperplasia and increased mucus production, are non-specific changes and may be caused by distinct infectious and non-infectious causes (e.g. routine handling or application of hydrogen peroxide; Declercq et al., 2015; Gjessing et al., 2017; Herrero et al., 2018). However, a typical histopathological feature in amoeba infections is the thickening of the distal tips of the filament (Dyková et al., 2010; Padrós & Constenla, 2021). Nevertheless, gill swabs, culture or other diagnostic tools are indispensable tools to detect and identify the etiological agents accurately.

5 | CONCLUSION

In Swiss aquaculture, six different amoeba species were identified by morphological characterization and by sequencing: *Cochliopodium* sp., *Naegleria* sp., *Vannella* sp., *Ripella* sp., *Saccamoeba* sp. and *Mycamoeba* sp. A further unidentified amoeba was characterized only by morphology. Signs of NGD were found in fish affected with those amoeba. Further studies are needed to assess the importance of these different species in disease development. The GS is a useful first-line tool for fish farmers in the diagnosis of NGD.

ACKNOWLEDGEMENTS

This project was financed by the Swiss Federal Food Safety and Veterinary Office (grant number 714001610) and involved fish farms. In addition, we received support from CSIRO Aquaculture. Thanks to the European Association of Fish Pathologists for the Grant Scheme. The authors thank the fish farms for their support during sampling and the NGS team at Vetsuisse Faculty, University Bern, Switzerland, for sequencing. Special thanks go to Elodie Cristina and Eliane Jemmi (FIWI, University of Bern) for their help in the laboratory. We also thank the Team of FIWI and fishdoc GmbH for their support and help during this project. We are very grateful to Tomas Tysl, DOE Joint Genome Institute and Molecular Biophysics & Integrated Bioimaging, University of South Bohemia, České Budějovice, Czech Republic for providing reference strains of different amoeba species to validate newly designed primers. Open access funding provided by Universitat Bern.

FUNDING INFORMATION

This project received financial support from the European Association of Fish Pathologists. This work was financially supported by the Swiss Fish Farmers and by the Swiss Federal Food Safety and Veterinary Office (714001610).

CONFLICT OF INTEREST STATEMENT

The authors declares that they have no conflicts of interest to disclose.

DATA AVAILABILITY STATEMENT

The data that support the findings of this study are available from the corresponding author upon reasonable request.


ETHICS STATEMENT

The project was submitted to the ethical commission (permission number BE102/2022). All examined fish in this study were sampled in the frame of diagnostic service of the Institute for Fish and Wildlife Health, Vetsuisse, Bern.

ORCID

James W. Wynne  <https://orcid.org/0000-0001-6846-757X>

Gary Delalay  <https://orcid.org/0000-0002-2537-3634>

Heike Schmidt-Posthaus  <https://orcid.org/0000-0003-2628-4454>

REFERENCES

- Altschul, S. F., Gish, W., Miller, W., Myers, E. W., & Lipman, D. J. (1990). Basic local alignment search tool. *Journal of Molecular Biology*, 215(3), 403–410. [https://doi.org/10.1016/S0022-2836\(05\)80360-2](https://doi.org/10.1016/S0022-2836(05)80360-2)
- Antychowicz, J. (2007). Study on rainbow trout nodular gill disease detected in Poland. *Bulletin of the Veterinary Institute in Pulawy*, 51, 547–551.
- Benhamed, S., Guardiola, F. A., Mars, M., & Esteban, M. Á. (2014). Pathogen bacteria adhesion to skin mucus of fishes. *Veterinary Microbiology*, 171(1–2), 1–12. <https://doi.org/10.1016/j.vetmic.2014.03.008>
- Boerlage, A. S., Ashby, A., Eze, J. I., Gunn, G. J., & Reeves, A. (2022). Field evaluation of diagnostic sensitivity (DSe) and specificity (DSp) of common tests for amoebic gill disease (AGD) and complex gill disease (CGD) in cultured Atlantic salmon (*Salmo salar*) in Scotland using Bayesian latent class models. *Preventive Veterinary Medicine*, 204, 105654. <https://doi.org/10.1016/j.prevetmed.2022.105654>
- Boerlage, A. S., Ashby, A., Herrero, A., Reeves, A., Gunn, G. J., & Rodger, H. D. (2020). Epidemiology of marine gill diseases in Atlantic salmon (*Salmo salar*) aquaculture: A review. *Reviews in Aquaculture*, 12(4), 2140–2159. <https://doi.org/10.1111/raq.12426>
- Bolger, A. M., Lohse, M., & Usadel, B. (2014). Trimmomatic: A flexible trimmer for Illumina sequence data. *Bioinformatics (Oxford, England)*, 30(15), 2114–2120. <https://doi.org/10.1093/bioinformatics/btu170>
- Bridle, A. R., Crosbie, P., Cadoret, K., & Nowak, B. F. (2010). Rapid detection and quantification of *Neoparamoeba perurans* in the marine environment. *Aquaculture*, 309(1–4), 56–61. <https://doi.org/10.1016/j.aquaculture.2010.09.018>
- Buchmann, K., Nielsen, T., Sigh, J., & Bresciani, J. (2004). Amoebic gill infections of rainbow trout in freshwater ponds. *Bulletin of the European Association of Fish Pathologists*, 24(2), 87–91.
- Cano, I., Taylor, N. G., Bayley, A., Gunning, S., McCullough, R., Bateman, K., Nowak, B. F., & Paley, R. K. (2019). In vitro gill cell monolayer successfully reproduces in vivo Atlantic salmon host responses to *Neoparamoeba perurans* infection. *Fish & Shellfish Immunology*, 86, 287–300. <https://doi.org/10.1016/j.fsi.2018.11.029>
- Crosbie, P. B. B., Bridle, A. R., Cadoret, K., & Nowak, B. F. (2012). In vitro cultured *Neoparamoeba perurans* causes amoebic gill disease in Atlantic salmon and fulfils Koch's postulates. *International Journal for Parasitology*, 42(5), 511–515. <https://doi.org/10.1016/j.ijpara.2012.04.002>
- Daoust, P. Y., & Ferguson, H. W. (1985). Nodular gill disease in rainbow trout, *Salmo gairdneri* Richardson. *Journal of Fish Diseases*, 8, 511–522.
- Daoust, P. Y., & Ferguson, H. W. (1986). Potential for recovery in nodular gill disease of rainbow trout, *Salmo gairdneri* Richardson. *Journal of Fish Diseases*, 9(4), 313–318. <https://doi.org/10.1111/j.1365-2761.1986.tb01020.x>
- Declercq, A. M., Chiers, K., van den Broeck, W., Dewulf, J., Eeckhaut, V., Cornelissen, M., Bossier, P., Haesebrouck, F., & Decostere, A. (2015). Interactions of highly and low virulent *Flavobacterium columnare* isolates with gill tissue in carp and rainbow trout. *Veterinary Research*, 46, 25. <https://doi.org/10.1186/s13567-015-0164-5>
- Downes, J. K., Yatabe, T., Marcos-Lopez, M., Rodger, H. D., MacCarthy, E., O'Connor, I., Collins, E., & Ruane, N. M. (2018). Investigation of co-infections with pathogens associated with gill disease in Atlantic salmon during an amoebic gill disease outbreak. *Journal of Fish Diseases*. Advance online publication, 41, 1217–1227. <https://doi.org/10.1111/jfd.12814>
- Dyková, I., Kostka, M., Wortberg, F., Nardy, E., & Pecková, H. (2010). New data on aetiology of nodular gill disease in rainbow trout, *Oncorhynchus mykiss*. *Folia Parasitologica*, 57(3), 157–163. <https://doi.org/10.14411/fp.2010.021>
- Dyková, I., & Lom, J. (2004). Advances in the knowledge of amphizoic amoebae infecting fish. *Folia Parasitologica*, 51(2–3), 81–97. <https://doi.org/10.14411/fp.2004.014>
- Dykova, I., & Tyl, T. (2016). Testate amoeba *Rhogostoma minus* Belar, 1921, associated with nodular gill disease of rainbow trout, *Oncorhynchus mykiss* (Walbaum). *Journal of Fish Diseases*, 39, 539–546.
- English, C. J., & Lima, P. C. (2020). Defining the aetiology of amoebic diseases of aquatic animals: Trends, hurdles and best practices. *Diseases of Aquatic Organisms*, 142, 125–143. <https://doi.org/10.3354/dao03537>
- English, C. J., Swords, F., Downes, J. K., Ruane, N. M., Botwright, N. A., Taylor, R. S., Barnes, A. C., Wynne, J. W., Lima, P. C., & Cook, M. T. (2019). Prevalence of six amoeba species colonising the gills of farmed Atlantic salmon with amoebic gill disease (AGD) using qPCR. *Aquaculture Environment Interactions*, 11, 405–415. <https://doi.org/10.3354/aei00325>
- English, C. J., Tyl, T., Botwright, N. A., Barnes, A. C., Wynne, J. W., Lima, P. C., & Cook, M. T. (2019). A diversity of amoebae colonise the gills of farmed Atlantic salmon (*Salmo salar*) with amoebic gill disease (AGD). *European Journal of Protistology*, 67, 27–45. <https://doi.org/10.1016/j.ejop.2018.10.003>
- Evans, D. H., Piermarini, P. M., & Choe, K. P. (2005). The multifunctional fish gill: Dominant site of gas exchange, osmoregulation, acid-base regulation, and excretion of nitrogenous waste. *Physiological Reviews*, 85, 97–177. <https://doi.org/10.1152/physrev.00050.2003>
- Frasca, S., Wolf, J. C., Kinsel, M. J., Camus, A. C., & Lombardini, E. D. (2018). Osteichthyes. *Pathology of Wildlife and Zoo Animals*, 993.e1–993.e17. <https://doi.org/10.1016/B978-0-12-805306-5.00039-0>
- Gianinazzi, C., Schild, M., Wüthrich, F., Ben Nour, N., Fuchsli, H.-P., Schürch, N., Gottstein, B., & Müller, N. (2009). Screening Swiss water bodies for potentially pathogenic free-living amoebae. *Research in Microbiology*, 160(6), 367–374. <https://doi.org/10.1016/j.resmic.2009.06.007>
- Gjessing, M. C., Thoen, E., Tengs, T., Skotheim, S. A., & Dale, O. B. (2017). Salmon gill poxvirus, a recently characterized infectious agent of multifactorial gill disease in freshwater- and seawater-reared Atlantic salmon. *Journal of Fish Diseases*, 40(10), 1253–1265. <https://doi.org/10.1111/jfd.12608>

- Herrero, A., Thompson, K. D., Ashby, A., Rodger, H. D., & Dagleish, M. P. (2018). Complex gill disease: An emerging syndrome in farmed Atlantic Salmon (*Salmo salar* L.). *Journal of Comparative Pathology*, 163, 23–28. <https://doi.org/10.1016/j.jcpa.2018.07.004>
- Hoffmann, R. W., El-Matbouli, M., & Flischer-Scherl, T. (1992). A proliferative gill disease (PGD) in rainbow trout (*Oncorhynchus mykiss*). *Bulletin of the European Association of Fish Pathologists*, 4(12), 139–141.
- Jensen, H. M., Karami, A. M., Mathiessen, H., Al-Jubury, A., Kania, P. W., & Buchmann, K. (2020). Gill amoebae from freshwater rainbow trout (*Oncorhynchus mykiss*): In vitro evaluation of antiparasitic compounds against *Vannella* sp. *Journal of Fish Diseases*, 43(6), 665–672. <https://doi.org/10.1111/jfd.13162>
- Kim, W.-S., Kong, K.-H., Kim, J.-O., Jung, S.-J., Kim, J.-H., & Oh, M.-J. (2017). Amoebic gill disease outbreak in marine fish cultured in Korea. *Journal of Veterinary Diagnostic Investigation*, 29(3), 357–361. <https://doi.org/10.1177/1040638717690783>
- Koressaar, T., & Remm, M. (2007). Enhancements and modifications of primer design program Primer3. *Bioinformatics (Oxford, England)*, 23(10), 1289–1291. <https://doi.org/10.1093/bioinformatics/btm091>
- Langmead, B., & Salzberg, S. L. (2012). Fast gapped-read alignment with bowtie 2. *Nature Methods*, 9(4), 357–359. <https://doi.org/10.1038/nmeth.1923>
- Lasjerdi, Z., Niyiyati, M., Haghghi, A., Zaeri, F., & Nazemalhosseini Mojarad, E. (2011). First report of vannellidae amoebae (*Vannella* spp.) isolated from biofilm source. *Iranian Journal of Parasitology*, 6(4), 84–89.
- Lima, P. C., Hartley-Tassell, L., & Wynne, J. W. (2021). The ability of *Neoparamoeba perurans* to bind to and digest non-fish-derived mucin: Insights into the amoeba's mechanism of action to overcome gill mucus production. *Journal of Fish Diseases*, 44(9), 1355–1367. <https://doi.org/10.1111/jfd.13394>
- Lima, P. C., Taylor, R. S., & Cook, M. (2017). Pseudocyst formation in the marine parasitic amoeba *Neoparamoeba perurans*: A short-term survival strategy to abrupt salinity variation. *Journal of Fish Diseases*, 40(8), 1109–1113. <https://doi.org/10.1111/jfd.12588>
- Loret, J.-F., & Greub, G. (2010). Free-living amoebae: Biological bypasses in water treatment. *International Journal of Hygiene and Environmental Health*, 213(3), 167–175. <https://doi.org/10.1016/j.ijheh.2010.03.004>
- Marcos-López, M., & Rodger, H. D. (2020). Amoebic gill disease and host response in Atlantic salmon (*Salmo salar* L.): A review. *Parasite Immunology*, 42(8), e12766. <https://doi.org/10.1111/pim.12766>
- Noble, A. C., Herman, R. L., Noga, E. J., & Bullock, G. L. (1997). Recurrent amoebic gill infestation in rainbow trout cultured in a semiclosed water recirculation system. *Journal of Aquatic Animal Health*, 9(1), 64–69. [https://doi.org/10.1577/1548-8667\(1997\)009%3C0064:RAGIIR%3E2.3.CO;2](https://doi.org/10.1577/1548-8667(1997)009%3C0064:RAGIIR%3E2.3.CO;2)
- Noga, E. J. (2010). *Fish disease: Diagnosis and treatment* (2nd ed. (2. uppl)). John Wiley & Sons.
- Nowak, B., Valdenegro-Vega, V., Crosbie, P., & Bridle, A. (2014). Immunity to amoeba. *Developmental and Comparative Immunology*, 43(2), 257–267. <https://doi.org/10.1016/j.dci.2013.07.021>
- Olson, K. R. (1991). Vasculature of the fish gill: Anatomical correlates of physiological functions. *Journal of Electron Microscopy Technique*, 19, 389–405. <https://doi.org/10.1002/jemt.1060190402>
- Padrós, F., & Constenla, M. (2021). Diseases caused by amoebae in fish: An overview. *Animals: An Open Access Journal from MDPI*, 11(4), 991. <https://doi.org/10.3390/ani11040991>
- Perolo, A., Gustinelli, A., Fioravanti, M. L., Manfrin, A., Dalla Pozza, M., Lunelli, F., Accini, A., & Quaglio, F. (2019). Occurrence of nodular gill disease in farmed brown trout (*Salmo trutta* L.). *Journal of Fish Diseases*, 42(9), 1315–1320. <https://doi.org/10.1111/jfd.13027>
- Quaglio, F., Perolo, A., Bronzatti, P., Gustinelli, A., Menconi, V., Cavazza, G., Caffara, M., Manfrin, A., Gallo, E., & Fioravanti, M. L. (2016). Nodular gill disease in farmed rainbow trout (*Oncorhynchus mykiss*) in Italy. *Journal of Fish Diseases*, 39(9), 1139–1142. <https://doi.org/10.1111/jfd.12446>
- Robinson, G. L. (1968). The laboratory diagnosis of human parasitic amoebae. *Transactions of the Royal Society of Tropical Medicine and Hygiene*, 62(2), 285–294. [https://doi.org/10.1016/0035-9203\(68\)90170-3](https://doi.org/10.1016/0035-9203(68)90170-3)
- Segner, H., Sundh, H., Buchmann, K., Douxfils, J., Sundell, K. S., Mathieu, C., Ruane, N., Jutfelt, F., Toften, H., & Vaughan, L. (2012). Health of farmed fish: Its relation to fish welfare and its utility as welfare indicator. *Fish Physiology and Biochemistry*, 38(1), 85–105. <https://doi.org/10.1007/s10695-011-9517-9>
- Slinger, J., Adams, M. B., & Wynne, J. W. (2021). Comparison of bacterial diversity and distribution on the gills of Atlantic salmon (*Salmo salar* L.): An evaluation of sampling techniques. *Journal of Applied Microbiology*, 131(1), 80–92. <https://doi.org/10.1111/jam.14969>
- Speare, D. J. (1999). Nodular gill disease (amoebic gill infestation) in Arctic Char, *Salvelinus alpinus*. *Journal of Comparative Pathology*, 121, 277–282.
- Speare, D. J., & Ferguson, H. W. (2006). *Systemic pathology of fish* (2nd ed.). Scotian.
- SR 455.1. (2018). Annex 2 animal welfare ordinance.
- Talavera, G., & Castresana, J. (2007). Improvement of phylogenies after removing divergent and ambiguously aligned blocks from protein sequence alignments. *Systematic Biology*, 56(4), 564–577. <https://doi.org/10.1080/10635150701472164>
- Taylor, R. S., Muller, W. J., Cook, M. T., Kube, P. D., & Elliott, N. G. (2009). Gill observations in Atlantic salmon (*Salmo salar*, L.) during repeated amoebic gill disease (AGD) field exposure and survival challenge. *Aquaculture*, 290(1–2), 1–8. <https://doi.org/10.1016/j.aquaculture.2009.01.030>
- Thomas, V., Herrera-Rimann, K., Blanc, D. S., & Greub, G. (2006). Biodiversity of amoebae and amoeba-resisting bacteria in a hospital water network. *Applied and Environmental Microbiology*, 72(4), 2428–2438. <https://doi.org/10.1128/AEM.72.4.2428-2438.2006>
- Tubbs, L., Wybourn, B. A., & Lumsden, J. S. (2010). Nodular gill disease causing proliferative branchitis and mortality in Chinook salmon (*Oncorhynchus tshawytscha*). *New Zealand Veterinary Journal*, 58(1), 59–61. <https://doi.org/10.1080/00480169.2010.65061>
- Untergasser, A., Cutcutache, I., Koressaar, T., Ye, J., Faircloth, B. C., Remm, M., & Rozen, S. G. (2012). Primer3—New capabilities and interfaces. *Nucleic Acids Research*, 40(15), e115. <https://doi.org/10.1093/nar/gks596>

SUPPORTING INFORMATION

Additional supporting information can be found online in the Supporting Information section at the end of this article.

How to cite this article: Vannetti, S. M., Wynne, J. W., English, C., Huynh, C., Knüsel, R., de Sales-Ribeiro, C., Widmer, M., Delalay, G., & Schmidt-Posthaus, H. (2023). Amoeba species colonizing the gills of rainbow trout (*Oncorhynchus mykiss*) in Swiss aquaculture. *Journal of Fish Diseases*, 00, 1–13. <https://doi.org/10.1111/jfd.13819>