

RESEARCH LETTER



Strategies for Treatment of Annular Rupture Complicating Transcatheter Aortic Valve Implantation: A Retrospective Analysis of the Bern TAVI Registry

Daijiro Tomii, MD; Thomas Pilgrim¹, MD, MSc; Taishi Okuno¹, MD; Jonas Lanz¹, MD, MSc; Fabien Praz¹, MD; Stefan Stortecky¹, MD; Matthias Siepe¹, MD; Stephan Windecker¹, MD; David Reineke, MD

Aortic annular rupture is a life-threatening complication of transcatheter aortic valve implantation (TAVI) requiring prompt rescue for hemodynamic stabilization. Transcatheter valve-in-valve implantation (TAV-in-TAV) has been suggested as rescue strategy to seal the site of annular rupture by increasing apposition of the first transcatheter prosthesis and extending the skirt-covered frame height by implantation of the second valve (Figure [A]).¹ Available evidence is, however, limited to anecdotal reports. In this retrospective cohort study, we aimed to systematically review the clinical course of patients with TAVI with annular rupture according to the bailout strategy.

Consecutive patients undergoing TAVI at a single institution—Bern University Hospital, Switzerland—which is part of the nationwide SwissTAVI registry (<https://www.clinicaltrials.gov>; Unique identifier: NCT01368250), were considered eligible for this study. The registry has been approved by the Bern Cantonal Ethics Committee, and patients provided written informed consent to participate. For the purpose of this study, any patient with annular rupture diagnosed by angiography or transesophageal echocardiography during TAVI was reviewed and categorized according to the management strategy: conservative management including isolated pericardial drainage and/or optimization of the coagulation status; rescue TAV-in-TAV to seal the annulus rupture site; and surgical bailout. Aortic root dimensions were evaluated in a dedicated Corelab using pre-procedural multidetector

computed tomography as previously described.² The cover index was calculated to determine the degree of valve oversizing.³ Statistical analyses were performed using R for Windows 4.0.2 (R Foundation for Statistical Computing). The data underlying this article will be shared on reasonable request to the corresponding author.

Among 3529 patients undergoing TAVI between August 2007 and May 2022 (balloon-expandable valves 52.4%; self-expanding valves 43.3%; and mechanically-expandable valves 4.2%), 18 patients (0.5%) experienced annular rupture complicating TAVI (Figure [B]). The incidence of annular rupture tended to decrease with time (0.93%, 0.56%, and 0.33%, respectively) when the study period was partitioned into tertiles (August 2007–June 2012; July 2012–May 2017; June 2017–May 2022). All TAV-in-TAV procedure were performed in 2021 and 2022. Among all patients with annular rupture, 12 patients (66.7%) were female, the median age was 84 years, and the median Society of Thoracic Surgeons Predicted Risk of Mortality score was 5.7% (reference cohort without annular rupture: 48.6% female, 81 years of age, and 5.1% Society of Thoracic Surgeons Predicted Risk of Mortality score). Moderate or greater left ventricular outflow tract calcification was observed in half of the patients with annular rupture, and 4 patients (23.5%) had multiple calcified nodules (reference cohort without

Key Words: aortic valve stenosis ■ heart rupture ■ thoracic surgery ■ transcatheter aortic valve replacement

Correspondence to: Stephan Windecker, MD, Department of Cardiology, Inselspital, Bern University Hospital, Freiburgstrasse 18, CH-3010 Bern, Switzerland. Email stephan.windecker@insel.ch

For Sources of Funding and Disclosures, see page xxx.

© 2023 The Authors. *Circulation: Cardiovascular Interventions* is published on behalf of the American Heart Association, Inc., by Wolters Kluwer Health, Inc. This is an open access article under the terms of the [Creative Commons Attribution Non-Commercial-NoDerivs](https://creativecommons.org/licenses/by-nc-nd/4.0/) License, which permits use, distribution, and reproduction in any medium, provided that the original work is properly cited, the use is noncommercial, and no modifications or adaptations are made.

Circulation: Cardiovascular Interventions is available at www.ahajournals.org/journal/circinterventions

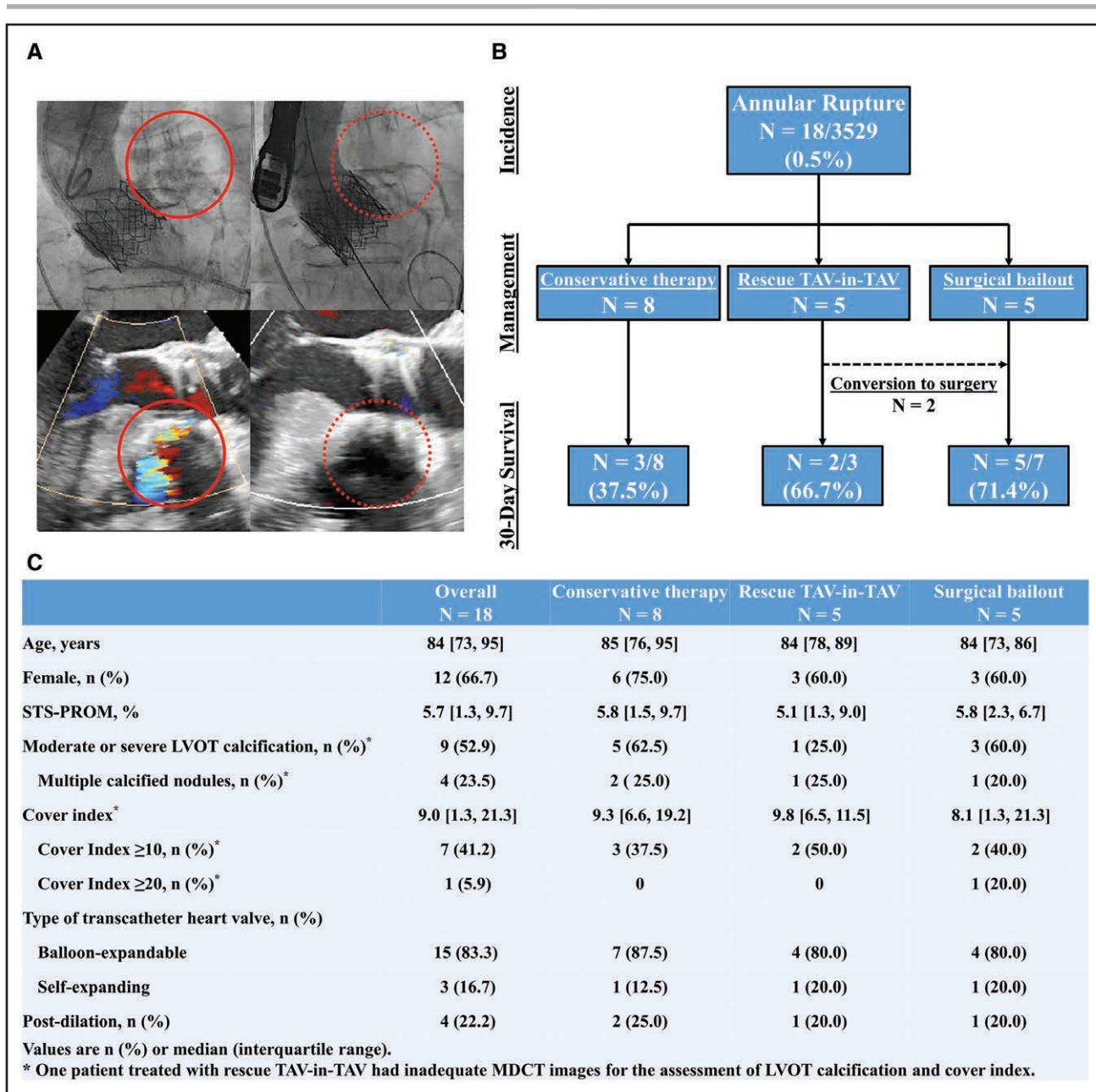


Figure. Annular rupture complicating transcatheter aortic valve implantation.

A, Angiography and transesophageal echocardiography showing extravasation indicative of annular rupture after first transcatheter heart valve deployment (solid red circle) with subsequent disappearance of the extravasation after rescue transcatheter valve-in-valve implantation (TAV-in-TAV; dotted red circle). **B**, Study flow chart. **C**, Baseline and procedural demographics in patients with annular rupture. LVOT indicates left ventricular outflow tract; MDCT, multidetector computed tomography; and STS-PROM, Society of Thoracic Surgeons Predicted Risk of Mortality score.

annular rupture: 22.3% and 6.8%, respectively). Most of the implanted transcatheter heart valves were balloon-expandable valves (83.3%). Relative oversizing of $\geq 10\%$ and $\geq 20\%$ of the cover index occurred in 7 (41.2%) and 1 (5.9%) patients, respectively (reference cohort without annular rupture: 38.8% and 4.7%, respectively). Postdilation was performed in 4 patients (22.2%; Figure [C]).

All patients were hemodynamically unstable as a consequence of annular rupture. Among 18 patients with annular rupture, 8 were managed conservatively, 5 underwent

rescue TAV-in-TAV, and 5 patients were converted to bailout surgery. Two patients were converted to surgery after rescue TAV-in-TAV (1 patient had insufficient percutaneous pericardial drainage, and 1 patient experienced type A aortic dissection with right coronary artery occlusion after TAV-in-TAV). The annular lesion, however, was in both converted patients sufficiently managed without the need to replace the valve surgically. Eight patients died within 30 days after TAVI; 5 in conservative management, 1 in rescue TAV-in-TAV, and 2 in bailout surgery, respectively (Figure [B]).

Owing to improvements in TAVI technology, implantation techniques, and increasing operator experience, the frequency of procedural complications requiring conversion to open heart surgery has declined during the past decade. Notwithstanding, annular rupture remains a feared and potentially fatal complication of TAVI requiring immediate attention. Previous studies suggested that annular rupture was associated with an increased risk for in-hospital death even among those undergoing bailout surgery.^{4,5} Moreover, patients with annular rupture may not be stabilized to undergo surgical bailout in view of rapid clinical deterioration. Our results suggest the feasibility of rescue TAV-in-TAV as a therapeutic measure to rapidly stabilize patients with annular rupture in suitable cases. This strategy, if successful, prevents hemodynamic deterioration and may obviate the need for emergent sternotomy in some cases. The results also highlight that the outcome of emergency bailout surgery was favorable suggesting that on-site surgery is useful as part of a rescue strategy.

The results should be interpreted with caution due to the small sample size and uncertainties regarding the type of rupture, patient selection, and clinical situations amenable for a TAV-in-TAV rescue strategy. Moreover, the choice between the treatment strategies was not systematic but driven at least in part by clinical context and patient condition rendering surgical conversion futile in selected cases. Therefore, a comparison of clinical outcomes between different strategies may be highly biased by the selection. Further studies are warranted to investigate the feasibility of rescue TAV-in-TAV for alternative treatment of annular rupture compared with routine surgical conversion.

ARTICLE INFORMATION

Affiliations

Department of Cardiology (D.T., T.P., T.O., J.L., F.P., S.S., S.W.), and Department of Cardiac Surgery (M.S., D.R.), Cardiovascular Center, Bern University Hospital, Inselspital, University of Bern, Switzerland.

Sources of Funding

None.

Disclosures

Dr Windecker reports research, travel or educational grants to the institution from Abbott, Abiomed, Amgen, Astra Zeneca, Bayer, Biotronik, Boehringer Ingelheim, Boston Scientific, Bristol Myers Squibb, Cardinal Health, CardioValve, Corflow Therapeutics, CSL Behring, Daiichi Sankyo, Edwards Lifesciences, Guerbet, Infracore, Janssen-Cilag, Johnson & Johnson, Medtronic, Merck Sharp & Dohm, Miracor Medical, Novartis, Novo Nordisk, Organon, OrPha Suisse, Pfizer, Polares, Regeneron, Sanofi-Aventis, Servier, Sinomed, Terumo, Vifor, V-Wave. He serves as unpaid advisory board member and/or unpaid member of the steering/executive group of trials funded by Abbott, Abiomed, Amgen, Astra Zeneca, Bayer, Boston Scientific, Biotronik, Bristol Myers Squibb, Edwards Lifesciences, Janssen, MedAlliance, Medtronic, Novartis, Polares, Recardio, Sinomed, Terumo, V-Wave and Xeltis, but has not received personal payments by pharmaceutical companies or device manufacturers. He is also member of the steering/executive committee group of several investigator-initiated trials that receive funding by industry without impact on his personal remuneration. Dr Pilgrim reports research grants to the institution from Edwards Lifesciences, Boston Scientific, and Biotronik, personal fees from Biotronik, Boston Scientific, Medtronic, Abbott, and HighLife SAS. Dr Reineke reports travel expenses from Abbott, Edwards Lifesciences, and Medtronic. Dr Stortecky reports research grants to the institution from Edwards Lifesciences, Medtronic, Boston Scientific, and Abbott and personal fees from Boston Scientific, Teleflex, and BTG. Dr Praz reports travel expenses from Abbott, Edwards Lifesciences, and Polares Medical. Dr Okuno reports speaker fees from Abbott. The other authors report no conflicts.

REFERENCES

1. Yu Y, Valley M, Ng MK. Valve-in-valve implantation for aortic annular rupture complicating transcatheter aortic valve replacement (TAVR). *J Invasive Cardiol*. 2013;25:409–410.
2. Okuno T, Asami M, Heg D, Lanz J, Praz F, Hagemeyer D, Brugger N, Gräni C, Huber A, Spirito A, et al. Impact of left ventricular outflow tract calcification on procedural outcomes after transcatheter aortic valve replacement. *JACC Cardiovasc Interv*. 2020;13:1789–1799. doi: 10.1016/j.jcin.2020.04.015
3. Detaint D, Lepage L, Himbert D, Brochet E, Messika-Zeitoun D, Lung B, Vahanian A. Determinants of significant paravalvular regurgitation after transcatheter aortic valve implantation: impact of device and annulus incongruence. *JACC Cardiovasc Interv*. 2009;2:821–827. doi: 10.1016/j.jcin.2009.07.003
4. Pineda AM, Harrison JK, Kleiman NS, Rihal CS, Kodali SK, Kirtane AJ, Leon MB, Sherwood MW, Manandhar P, Vemulapalli S, et al. Incidence and outcomes of surgical bailout during TAVR: insights from the STS/ACC TVT registry. *JACC Cardiovasc Interv*. 2019;12:1751–1764. doi: 10.1016/j.jcin.2019.04.026
5. Pasic M, Unbehaun A, Buz S, Drews T, Hetzer R. Annular rupture during transcatheter aortic valve replacement: classification, pathophysiology, diagnostics, treatment approaches, and prevention. *JACC Cardiovasc Interv*. 2015;8:1–9. doi: 10.1016/j.jcin.2014.07.020