

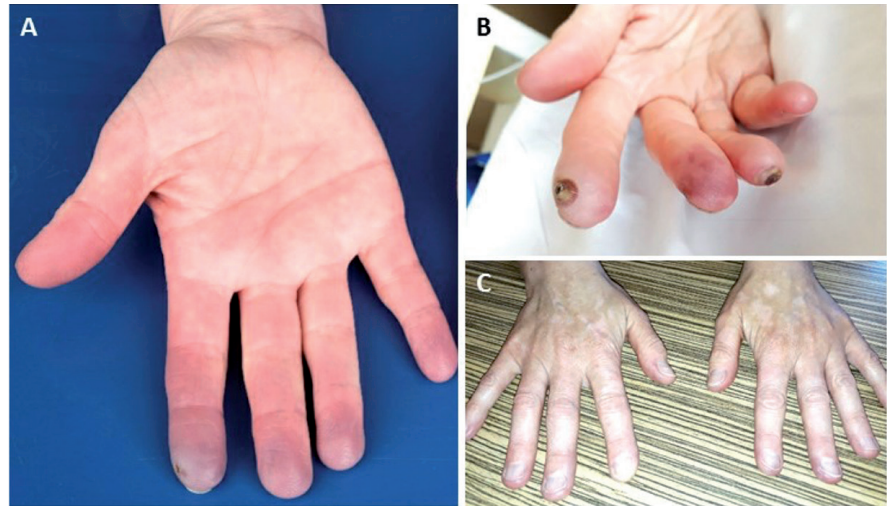
**Acrocyanosis after neoadjuvant ipilimumab plus nivolumab: a case report**

Sirs,

The introduction of immunotherapy has marked the beginning of a new era in cancer treatment resulting in a long-term benefit in several cancer types including melanoma (1). Checkpoint inhibitors targeting the cytotoxic T-lymphocyte-associated protein 4 (CTLA-4) or programmed cell death 1 (ligand) [PD-(L)1] have become standard of care for late stage disease. A wide variety of immune-related adverse events (irAE) has been described (2). Here we report a patient who presented with acrocyanosis after treatment with immune checkpoint inhibition (ICI).

In December 2018, a 55-year-old woman was diagnosed with stage III melanoma with an inguinal lymph node metastasis originating from a primary melanoma on her right calf. She had no medical history of cardiovascular or autoimmune diseases. At the Netherlands Cancer Institute she received two cycles neoadjuvant ipilimumab 1mg/kg (CTLA-4 antibody) and nivolumab 3 mg/kg (PD-1 antibody) in the setting of a clinical study [NCT02977052], followed by excision of the lymph node metastasis after 6 weeks. She achieved complete pathological remission. Two months after the last ICI infusion she developed paresthesia in her right index finger. Within 10 days the symptoms gradually increased with episodes of blue discoloration resembling the Raynaud phenomenon to persisting acrocyanosis in both hands (Fig. 1A). On suspicion of an irAE, treatment with 1 mg/kg prednisolone and 30 mg nifedipine was initiated. A skin biopsy of her right index finger showed no abnormalities. Her symptoms worsened and prednisolone treatment was intensified to 2 mg/kg.

The patient was referred to the Vasculitis Expertise Center of the Amsterdam University Medical Centre one week later. By then, additional splinter bleeds at the nail-folds were present. Laboratory assessment showed no abnormalities (Table I). Cardiac embolisms were excluded and Doppler ultrasound showed normal signals in both arms and hands (not shown). The nifedipine dose was raised to 30 mg twice daily. Due to side effects and a lack of clinical response, the corticosteroid dosage was tapered to 30mg per day. Unfortunately, the pain in the fingers progressed and the treating oncologist started mycophenolate mofetil (MMF) and aspirin. Ten days later, tacrolimus 5 mg twice daily was added. The biopsied skin area and another papercut wound showed necrotic tissue (Fig. 1B). To avoid further ischaemia the patient was admitted for intravenous iloprost while continuing the immunosuppression. During 5 subsequent days of iloprost infusions the wounds



**Fig. 1.** A: Start of acrocyanosis 8 weeks after the last infusion of checkpoint inhibitors. B: Development of ischaemic areas on the right hand after skin biopsy (index finger) and a paper cut (ring finger). C: Resolution of acrocyanosis after treatment and development of vitiligo 6 months after the last infusion with checkpoint inhibitors.

**Table I.** Lab results at the time of presentation.

Variable	Value	Reference
Sedimentation rate	2	0–30 mm/U
C-reactive protein	0.7	0–5 mg/L
Haemoglobin	9.0	7.5–10 mmol/L
Thrombocytes	392	150–400 10E9/L
Leukocytes	12.3 (H)	4.0–10.5 10E9/L
Eosinophils	0.00	0–0.5 10E9/L
Basophils	0.01	0–0.2 10E9/L
Neutrophils	11.54 (H)	1.8–7.2 10E9/L
Lymphocytes	0.47 (L)	1.5–4.0 10E9/L
Monocytes	0.12	0.1–1.0 10E9/L
Immature granulocytes	0.15 (H)	<0.06 10E9/L
Potassium	4.5	3.5–4.5 mmol/L
Calcium	2.32	2.2–2.6 mmol/L
Albumin	44	35–50 g/L
Creatinine	77	65–95 µmol/L
eGFR	75	>60 mL/min/1.73m <sup>2</sup>
Urea	7.3 (H)	2.1–7.1 mmol/L
Bilirubin	8	0–17 µmol/L
Alk.fosf.	79	40–120 U/L 37°C
Gamma-GT	19	0–40 U/L 37°C
ASAT	19	0–40 U/L 37°C
ALAT	21	0–34 U/L 37°C
LDH	251 (H)	0–247 U/L 37°C
Ferritin	88	20–250 µg/L
Folic acid	15.5	5.2–34.8 nmol/L
Cryoglobulins	Negative	0–0.1 g/L
Vitamin B12	708 (H)	150–700 pmol/L
Anti-nuclear antibodies	Negative	Negative
Scleroderma immunoblot	Negative*	Negative
Anti-β2-glycoprotein	Negative	Negative
Anti-phospholipids	Negative	Negative
Complement C3	0.95	0.9–1.8 g/L
Complement C4	0.23	0.1–0.4 g/L
TSH	0.16 (L)	0.5–5 mE/L
Free T4	18.3	12.0–22.0 pmol/L
TPO antibodies	<30	0–60 kU/L

\*Scleroderma immunoblot included antibodies against Scl-70, centromere (A and B), RNA polymerase III (11 and 155 kD), fibrillarin, NOR90, Th/To, PM-Scl100, PM-Scl75, Ku, PDGFR and Ro-52.

showed slow recovery. Three weeks later the symptoms had strongly improved. Nail-fold capillaroscopy at that time showed no abnormalities (not shown). During the two months thereafter the immunosuppressive drugs were tapered while nifedipine treat-

ment was continued. The acrocyanosis and wounds disappeared whereas a mild pain in her fingers lasted for 16 weeks longer before disappearing completely. Up until now, this patient is free of recurrence from her melanoma.

The development of acrocyanosis and/or digital ischaemia in the setting of ICI is described before but seems rare (3-8). The aetiology remains unclear because most cases – including ours – showed no biochemical markers of inflammation, nor histological signs of immune cell tissue infiltration and/or damage. This contradicts the majority of systemic autoimmune diseases where usually inflammation can be found and/or autoantibodies are present.

Acral ischaemia has previously been described as a paraneoplastic phenomenon (9) but since our patient achieved complete response and is still relapse-free, it is unlikely that the observed symptoms are a result of a paraneoplastic syndrome.

The optimal treatment for ICI-induced acrocyanosis/digital ischaemia remains unclear. Results from treatment with prostacyclin analogues or calcium channel blockers are controversial (4, 5). High-dose (methyl) prednisolone might be considered, however several cases report no efficacy (4, 5). Similar to our case, addition of MMF to prednisolone and iloprost treatment resulted in complete resolution of symptoms in another case. Thus, aggressive immune suppression combined with atrial vasodilation and platelet aggregation inhibition might be a promising therapy option for steroid-refractory acrocyanosis.

In summary, acrocyanosis as an ICI induced irAE is a rare but serious complication, which seems to require more intense therapy than other irAEs (10). It should be managed multidisciplinary to avoid digital necrosis and amputation.

### Ethics approval

The patient gave written informed consent for the anonymous publication of her case, including photographs of her hands.

I.L.M. REIJERS<sup>1,2\*</sup>  
M. HILHORST<sup>3,4\*</sup>  
M. TAN<sup>4</sup>  
P.L. KLARENBEK<sup>3</sup>  
A.E. HAK<sup>3</sup>  
C.U. BLANK<sup>1,2</sup>

\*These authors contributed equally.

<sup>1</sup>Department of Medical Oncology,  
<sup>2</sup>Division of Molecular Oncology & Immunology,  
the Netherlands Cancer Institute, Amsterdam;  
<sup>3</sup>Department of Rheumatology and Clinical  
Immunology, <sup>4</sup>Department of Internal Medicine,  
Amsterdam UMC, the Netherlands.

Please address correspondence to:  
Christian U. Blank,  
Department of Medical Oncology,  
Netherlands Cancer Institute,  
Plesmanlaan 121,  
Amsterdam 1066 CX, the Netherlands.  
E-mail: c.blank@nki.nl

Competing interests: none declared.

© Copyright CLINICAL AND  
EXPERIMENTAL RHEUMATOLOGY 2020.

### References

1. HEIGENER DF, RECK M: Giant steps and stumbling blocks. *Nat Rev Clin Oncol* 2017; 15: 71.
2. POSTOW MA, SIDLOW R, HELLMANN MD: Immune-related adverse events associated with immune checkpoint blockade. *New Engl J Med* 2018; 378: 158-68.
3. KHADDOUR K, SINGH V, SHAYUK M: Acral vascular necrosis associated with immune-check point inhibitors: case report with literature review. *BMC Cancer* 2019; 19: 449.
4. GAMBICHLER T, STRUTZMANN S, TANNAPFEL

A, SUSOK L: Paraneoplastic acral vascular syndrome in a patient with metastatic melanoma under immune checkpoint blockade. *BMC Cancer* 2017; 17: 327.

5. PADDA A, SCHIOPU E, SOVICH J, MA V, ALVA A, FECHER L: Ipilimumab induced digital vasculitis. *J Immunother Cancer* 2018; 6: 12.
6. THOREAU B, GOUAILLIER-VULCAIN F, MACHET L *et al.*: Acute lower limb ischaemia and diabetes in a patient treated with anti-PD1 monoclonal antibody for metastatic melanoma. *Acta Derm Venereol* 2017; 97: 408-9.
7. LE BUREL S, CHAMPIAT S, ROUTIER E *et al.*: Onset of connective tissue disease following anti-PD1/PD-L1 cancer immunotherapy. *Ann Rheum Dis* 2018; 77: 468.
8. FRANCO F, MÉNDEZ M, GUTIERREZ L, SANZ J, CALVO V, PROVENCIO M: Nivolumab-associated digital small-vessel vasculitis in a patient with an advanced renal cell carcinoma. *Immunotherapy* 2019; 11: 379-84.
9. RODRIGUES T, BARCELOS A: Digital ischemia as a paraneoplastic phenomenon. *Acta Reumatol Port* 2016; 41: 378-79.
10. HAANEN JBAG, CARBONNEL F, ROBERT C *et al.*: Management of toxicities from immunotherapy: ESMO Clinical Practice Guidelines for diagnosis, treatment and follow-up. *Ann Oncol* 2018; 29 (Suppl. 4): iv264-iv6.