

Effects of a mixed administration of selenium and diazinon on the ultrastructure of hepatocytes in rat

by Józef Szarek, Barbara Przybylska-Gornowicz^{*}, Arkadiusz Zasadowski^{***} & Jacek Fabczak.

Department of Forensic Veterinary Medicine and Veterinary Medicine Administration, ^{*}Department of Histology and Embryology, ^{**}Department of Veterinary and Environmental Toxicology, Faculty of Veterinary Medicine, Olsztyn University of Agriculture and Technology, Oczapowskiego Str. 13, 10-717 Olsztyn, Poland.

Introduction

The indiscriminate use of pesticides can be considered as one of the factors altering the environment and causing several imbalances in the ecosystem (Chu and Lau 1994, Ferrando et al. 1992, Spinato 1991, Walker et al. 1993). In view of this it is important to identify not only the xenobiotics, but also to estimate their effects on animal and human organisms. An increasing number of researchers have pointed out that the effects of toxic substances depend not only on their administration levels, but also on the interaction with other substances (Johnston et al. 1994, Romis and Badger 1995, Szarek et al. 1994, 1995, Walker et al. 1993).

Some elements and pesticides, selenium and diazinon inclusive, are of considerable importance in agriculture and veterinary medicine (Oldfield 1987, Beker et al. 1992, Khan et al. 1993 a, Khan and Gilani 1980).

Selenium, an essential micronutrient, has a narrow safety margin as it becomes a metabolic poison at dietary levels of more than 10 ppm (Oldfield 1987). Intoxication with selenium in areas of selenium-rich soils usually results from ingestion of seleniumiferous plants, whereas in aquatic birds the embryotoxic and teratogenic effects of selenium leached from soil into irrigation drain water has been reported (Ohlendorf et al. 1986, 1988).

Selenium concentration exceeded 300 ppm in some samples of submerged vegetation, insects and fish from Kestoron Reservoir, California (Saiki and Lowe 1987). Selenium will either increase or decrease toxicity of various xenobiotics, in this of pesticides, depending on its amounts introduced into an organism (Hamdy and Gissel-Nielsen 1976, Khan et al. 1993 b, Nakonieczny 1993, Ohlendorf et al. 1986, 1988, Oldfield 1987, Szarek et al. 1993, 1994, 1995).

Diazinon, a phosphoro-organic compound, was also used in our studies. This substance was taken into consideration due to its wide application in agriculture and horticulture as well as in veterinary medicine, where it is used to control external parasites of domestic animals (Damayanti and Yuningsih 1994, Ferrando et al. 1992, Jabbar et al. 1994, Johnston et al. 1994, Mbuthia et al. 1993, Spinato 1991). Moreover, there are no investigations on mutual effects of selenium and diazinon on the ultrastructure of liver.

Materials & Methods

The experiments were conducted on 120 Wistar male rats (body mass 170 to 210 g). The animals were given a pelleted feed "Murigram". Drinking water was available *ad libitum*. The rats were kept in cages measuring 45 cm x 35 cm x 20 cm in groups of 5. Wood scrapings were used for bedding. The room temperature was about 22°C, the relative humidity about 30-40 %, and the daylight regime 12 h. The animals were allocated into four groups (Table 1), each of 30 rats. Sodium selenite

Table 1. Outline of the experiment.

Group	Treatment	
	sodium selenite* (ppm)	diazinon** (mg/kg b.m.)
I	0	0
II	0.40	0
III	0	40
IV	0.40	40

* over 12 days given in drinking water.

** administered per os by a tube inserted into the stomach.

(Na_2SeO_3 ; POCH, Polish Chemical Reagents, Gliwice) was administered in drinking water over 12 days. Diazinon (Ciba, Geigy) 81.4 % solution inazole oil was administered *per os* by gavage on the 6th and 12th day. The doses and the administration time were the same as in earlier experiments (Szarek *et al.* 1994, 1995). During the experiment the rats were examined for clinical symptoms twice daily, and consumption of feed and water was monitored daily.

Six animals from each group were weighed and anaesthetised by ethyl ether on the 1st, 3rd, 7th, 24th and 28th day post the intoxication (p.i.). Liver samples for ultrastructural examination were collected immediately after the animal death. They were fixed in a mixture of 1% paraformaldehyde and 2.5% glutaraldehyde in 0.2 M osmium tetroxide buffer (pH 7.4) at 4°C, followed by post-fixation in 2% osmium tetroxide and embedded in Epon 812. Ultra-thin sections were prepared with an LKB ultramicrotome, stained with uranyl acetate and lead citrate and examined with a Tesla BS 500 TEM operating at 60 kV.

Results

Clinical examination of rats from groups III and IV indicated an occurrence of periodic depressions with partially decreased feed intake. A decrease of the animal body mass in all treatment groups was observed compared with the controls. These results have been described elsewhere (Szarek *et al.* 1994). Hepatocytes of rats in the control (group I) were characterised by a typical structure, with well developed endoplasmatic reticulum (Fig. 1). Rough endoplasmatic reticulum (RER) formed numerous

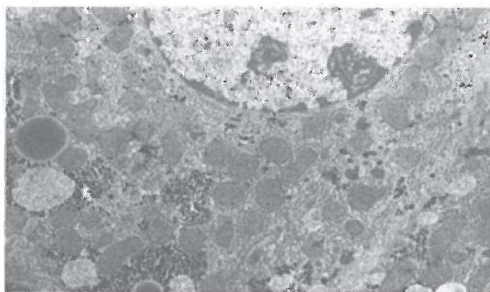


Fig. 1. Fragment of a rat hepatocyte. Control group; typical structure. Magn. x 4170.

foci of from a few to several membranes running parallel to each other, while smooth endoplasmatic reticulum (SER) was in form of single follicle forms or scattered in the cytoplasm. Numerous round or oval mitochondria (MIT) were noted, with abundant matrix and a few crista. Glycogen in form B was very abundant, especially in the cells close to Disse's space. About 5-10 % of the cells contained numerous lipid droplets of different diameter. Lamellar structures were observed in some droplets. A few primary lysosomes were usually present in hepatocyte sections, while secondary lysosomes and dense bodies were very rare. Cell surfaces contacting the Disse's space, and cell surfaces directed towards the intralobule tubules contained numerous microvilli.

Part of the hepatocytes of rats intoxicated with selenium (group II) contained empty follicles; they were probably formed in course of the fragmenta-

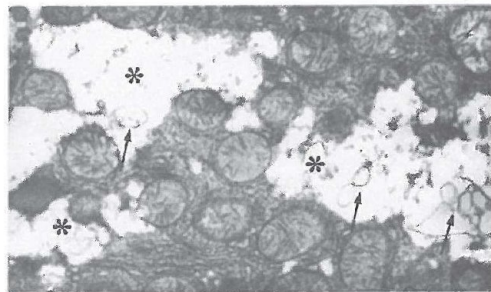
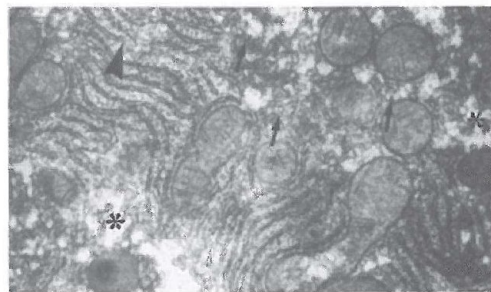


Fig. 2. Fragments of rat hepatocytes from group II, 24 hours p.i.

A. Fragmentation of the smooth endoplasmatic reticulum (arrows), rough endoplasmatic reticulum (arrow head) and foci of the degradation of membranous structures (asterisks). Magn. x 10 590.

B. Electron empty spaces (asterisks) with irregular outline and myelin-like structures (arrows). Magn. x 8470.

tion and proliferation of SER and RER (Fig. 2A). The percentage of these damaged cells ranged from about 20 to about 35 depending on the animal. Such a pattern was characteristic most of all of rats 24 days after sodium selenite administration. It persisted, but much less intensively, 72 hours p.i. Degradation of the described membrane structure of the follicles was observed already 24 hours p.i., so that electron empty spaces were formed in these cells (Fig. 2B). Cytoplasm of these hepatocytes contained membrane fragments which sometimes formed myelin-like structures. This process was accompanied by intumescence of the mitochondria and their degradation. These changes extended over different cell area, but glycogen atrophy was always noted in these cases. The described picture was most noticeable 72 hours p.i. In addition to this about 5 % of the hepatocytes contained very numerous small electron light follicles 72 hours p.i.

and on day 7 p.i. Two weeks after selenium administration almost all hepatocytes resembled liver cells of the control rats.

Hepatocyte structure of the rats receiving diazinon (group III) was very similar to that observed in group II animals. However, in these cases there were more cells with very numerous SER and RER follicles than in the previous group and total degradation of the cytoplasm fragments (Fig. 3). These damaged cells usually contained MIT with symptoms of internal structure degradation. The retrogressive changes were noticeable already 24 hours p.i., but they were most pronounced 72 hours p.i. Some were sporadically observed also on day 7 p.i. Hepatocytes of rats subjected to a mixed intoxication with selenium and diazinon (group IV) were characterised by the presence of numerous follicles and degrading membranous structures, resulting in electronic empty spaces in the cytoplasm (Fig. 4).

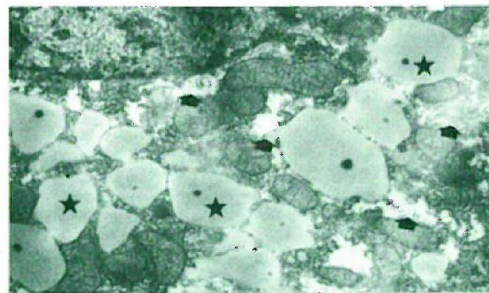
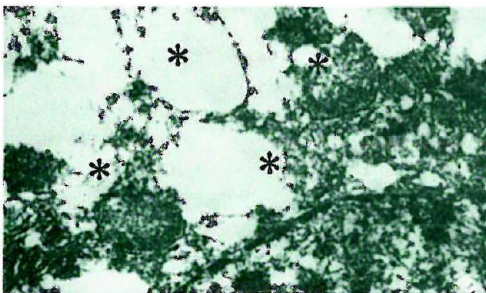

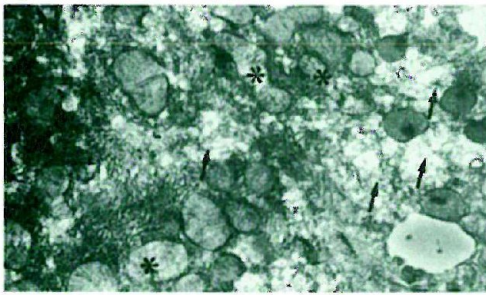


Fig. 3. Fragments of rat hepatocytes from group III, 72 hours p.i.

A. Necrosis of the cytoplasm fragments (arrows) and of internal structures of the mitochondria (asterisks). Magn. x 8340.

B. Necrosis of large cytoplasmic areas (asterisks). Magn. x 10 430.

Fig. 4. Fragments of rat hepatocytes from group IV, 24 hours p.i.

A. Initial process of the degradation of cytoplasmic structure and formation of electron empty spaces in the cytoplasm (arrows). Magn. x 8470.

B. Necrosis of the cytoplasm (arrows) and numerous lipid droplets (asterisks). Magn. x 8470.




Fig. 5. Fragment of hepatocytes with degradation of the cytoplasmic structures. Group IV, 14 days p.i. Magn. x 6260.

On days 1 and 3 p.i. such changes were observed in from about 20 to about 40 % of the liver cells (depending on the animal). They were most frequently accompanied by changes in the mitochondria consisting of the atrophy of crista structures. Quite frequently the empty spaces contained myelin-like structures. In addition to this, cells with numerous electron empty spaces and vacuoles were found. Golgi complex had swollen sacs compared with the control and the other intoxicated groups of animals. Sporadically, electron dense bodies of irregular size and shape were observed in the mitochondria. These changes were characteristic of the animals 24 hours and 3 days p.i. Majority of the liver cells had normal structure 14 days after selenium and diazinon administration. In this period about 2-5 % of the hepatocytes showed necrosis (Fig. 5).

Discussion

We observed that selenium as well as diazinon administered in doses as in this experiment caused dilatation and necrosis of RER and SER, and retrogressive changes in the mitochondria. Similar changes were noted after selenium toxicosis of chickens and guinea pigs (Dini *et al.* 1982, Khan *et al.* 1980). Description of macroscopic and histopathological disturbances observed in rat and chicken liver following diazinon administration suggests that a submicroscopic response similar to the one observed in course of this experiment is quite possible (Damayanti and Yuningsih 1994, Hill *et al.* 1994, Szarek *et al.* 1994).

In view of the literature data on the subject it may be assumed that damage to the endoplasmic reti-

culum and mitochondria was caused by an accumulation of selenium and diazinon in the animal liver, and by enzymatic disturbances (Garcia-Repetto *et al.* 1995, Jabbar *et al.* 1994, Khan and Gilani 1980, Khan *et al.* 1993 a, Matin *et al.* 1990a, b, Nakonieczny 1993, Saigal *et al.* 1987).

The described morphological changes in rat liver were most intensive 24 hour post selenium intoxication and 72 hours post diazinon intoxication. In both cases abnormal cells were observed as late as 7 days p.i. Changes noted after the intoxication with diazinon were somewhat more intensive than in the case of selenium administration.

In the case of mixed intoxication with selenium and diazinon the ultrastructural changes were even more intensive than those induced by one factor only. They also occurred in a higher number of hepatocytes and were more diversified (intumescence of Golgi complex, vacuoles). The submicroscopic changes were most noticeable 1 and 3 days p.i. In addition to this some of them persisted until 14 days p.i. This morphological pattern of a mixed intoxication, compared with the one caused by selenium or diazinon only, suggests an interaction between the two toxicants. Selenium interaction with various substances was suggested also by other authors (Khan *et al.* 1993a, b, Nakonieczny 1993, Szarek and Khan 1993, Szarek *et al.* 1995). This may be of practical importance in view of the observed animal poisonings caused by selenium as well as diazinon (Chu and Lau 1994, Damayanti and Yuningsih 1994, Hill *et al.* 1994, Mbuthia *et al.* 1993, Ohlendorf *et al.* 1986, 1988, Oldfield 1987). Hence, it is necessary to perform studies on selenium levels in animals as well as in soil and plants (Beker *et al.* 1992, Ekholm *et al.* 1991, Hamdy and Gissel-Nielsen 1976, Kantola and Vartianen 1991, Lindberg and Bingerfors 1970, Walker *et al.* 1993).

Summary

Sodium selenite administered to rats in drinking water, at a dose of 0.40 ppm for 12 days, caused proliferation of the rough and smooth endoplasmic reticulum and their necrosis. These changes were most intensive 24 hours p.i. and persisted until 72 hours p.i. They were accompanied by mitochondria intumescence, their partial degradation and glycogen atrophy, most noticeable 72 hours p.i.

Diazinon administered *per os* at a dose of 40 mg/kg

b.m. twice at 6-day intervals caused necrosis of the rough and smooth endoplasmatic reticulum. The changes set in at a slower pace than following selenium administration and none were observed 14 days p.i.

Treatment with sodium selenite and subsequent exposure to diazinon induced ultrastructural changes in the rat hepatocytes, which were more intensive and accompanied by an intumescence of Golgi complex and cell vacuolisation. In these cases the submicroscopic changes were most noticeable 1 and 3 days p.i. Necrotic hepatocytes were observed 14 days p.i.

References

- Beker D, Z Romic, H Krsnjavi & Z Zima:* A contribution to the world selenium map. *Biol. Trace El. Res.* 1992, 33, 43-49.
- Chu KH & PY Lau:* Effects of diazinon, malathion, and paraquat on the behavioral response of the shrimp *Metapenaeus ensis* to chemoattractants. *Bull. Environ. Contam. Toxicol.* 1994, 53, 127-133.
- Damayanti R & C Yuningsih:* Pathological changes of organophosphate diazinon insecticide poisoning in chicken. *Penyakit Hewan.* 1994, 26, 53-56.
- Dini G, M Flavio, S Stendardi, F Bernardini & F Franconi:* Time course of sodium selenite induced ultrastructural alterations in guinea pig hearts. *Expl. Molec. Path.* 1982, 36, 326-332.
- Ekholm P, M Ylinen, M Euroola, P Koivistoinen & P Varo:* Effects of general soil fertilization with sodium selenite in Finland on the selenium content of milk, cheese and eggs. *Milchwissenschaft* 1991, 46, 547-550.
- Ferrando MD, V Alarcon, A Fernandez-Casalderey, M Gamon & E Andreu-Moliner:* Persistence of some pesticides in the aquatic environment. *Bull. Environ. Contam. Toxicol.* 1992, 48, 747-755.
- Garcia-Repetto R, D Martinez & M Repetto:* Coefficient of distribution of some organophosphorus pesticides in rat tissue. *Vet. Hum. Toxicol.* 1995, 37, 226-229.
- Hamdy AA & G Gissel-Nielsen:* Relationship between soil factors and selenium content in Danish soils and plants. *Riso Rapport* 1976, 349, 1-16.
- Hill DL, CI Hall, JE Sander, OJ Fletcher, RK Page & SW Davis:* Diazinon toxicity in broilers. *Avian Dis.* 1994, 38, 393-396.
- Jabbar A, A Iqbal, SA Malik, M Ahmad & AR Shakoori:* Hepatotoxic effects of organophosphate insecticides. *Proceedings of Twelfth Pakistan Congress of Zoology, Lahore, 1992, pressed 1994, 579-587.*
- Johnston G, CH Walker & A Dawson:* Interactive effects between ebi fungicides (prochloraz, propiconazole and penconazole) and op insecticides (dimethoate, chlorpyrifos, diazinon and malathion) in the hybrid red-legged partridge. *Environ. Toxicol. Chem.* 1994, 13, 615-620.
- Kantola M & T Vartanen:* Selenium content of breast milk in Finland, after fertilization of soil with selenium. *J. Trace Elem. Electrolytes Health Dis.* 1991, 5, 283-284.
- Khan MZ, J Szarek & K Markiewicz:* Concurrent oral administration of monensin and selenium to broiler chickens: Effects on concentration of different elements in the liver. *Acta Vet. Hung.* 1993 a, 41, 365-380.
- Khan MZ, J Szarek & K Markiewicz:* Effects of oral administration of toxic levels of lead and selenium upon concentration of different elements in the liver of broiler chicks. *J. Vet. Med.* A 1993 b, 40, 652-664.
- Khan MY & SH Gilani:* Selenium poisoning and embryogenesis: light and electron microscopic studies of the heart. *Envir. Res.* 1980, 23, 98-109.
- Lindberg P & S Bingerfors:* Selenium levels in forages and soils in different regions of Sweden. *Acta Agric. Scand.* 1970, 20, 133-136.
- Main MA, K Husain & SN Khan:* Modification of diazinon - induced in carbohydrate metabolism by adrenalectomy in rats. *Biochem. Pharmacol.* 1990 a, 39, 1781-1786.
- Main MA, S Sattar & K Husain:* The role of adrenals in diazinon - induced changes in carbohydrate metabolism in rats. *Arch. Hig. Rada Toxicol.* 1990 b, 41, 347-356.
- Mbuthia PG, REN Runyenje, TA Ngatia & C Mulei:* Occurrence of poultry chemical poisoning in Kenya. *Bull. Anim. Health Prod. Africa* 1993, 41, 45-50.

- Nakoneczny M*: Functional aspects of cadmium and selenium interactions in insect digestive tract. *Enzyme studies. Sc. Total environ.* 1993, 40, 667-675.
- Ohlendorf HM, AW Kilness, JL Simmons, RK Stroud, DJ Hoffman & JF Moore*: Selenium toxicosis in wild aquatic birds. *J.Toxic. Envir. Hlth.* 1988, 24, 67-92.
- Ohlendorf HM, DJ Hoffman, MK Saiki & TW Aldrich*: Embryonic mortality and abnormalities of aquatic birds: Apparent impact of selenium from irrigation drain water. *Sci. Tot. Environ.* 1986, 52, 49-63.
- Oldfield JE*: The two facies of selenium. *J.Nutr.* 1987, 117, 2002-2008.
- Romis MJ & TM Badger*: Toxic interactions between fungicides that inhibit biosynthesis and phosphorothioate insecticides in the male rat and bobwhite quail (*Colinus virginianus*). *Toxicol. Appl. Pharmacol.* 1995, 130, 221-228.
- Saigal S, VK Bhatnagar & VS Singh*: Toxicity of pesticides lindane and diazinon after repeated oral administration to rats. *Environ. Ecol.* 1987, 5, 733-735.
- Saiki MK & TP Lowe*: Selenium in aquatic organisms from subsurface agricultural drainage water. San Joaquin Valley, California. *Arch. Environ. Contamin. Toxicol.* 1987, 16, 657-670.
- Spinato MT*: Diazinon toxicity in Canada geese. *Can. Vet. J.* 1991, 32, 627.
- Szarek J & MZ Khan*: Concurrent exposure to lead, selenium or monensin effects on hepatic porphyrin levels in broiler chickens during acute toxicosis. *Scand. J. Lab. Anim. Sci.* 1993, 20, 231-235.
- Szarek J, A Zasadowski, J Fabczak, D Barski & B Przybylska*: Hepatic and kidney pathomorphological changes in rats exposed to sodium selenite and subsequent interaction with diazinon. *Proceedings of the 6th International Congress of European Association for Veterinary Pharmacology and Therapeutic, Edinburgh 1994*, 130.
- Szarek J, A Zasadowski, J Fabczak & D Barski*: Effect of mixed administration of selenium and fenitrothion on pathomorphological pattern in internal organs in rats. *Scand. J. Lab. Anim. Sci.* 1995, 22, 321- 325.
- Walker CH, GO Johnston & A Dawson*: Enhancement of toxicity due to the interaction of pollutants at the toxicokinetic level in birds. *Sc. Total Environ.* 1993, suppl. part 1, 525-531.

SCANBURS JULEKONKURRENCE: 1 uges ophold i Scanburs sommerhus på La Gomera (Kanariske øer) er vundet af:

SCANBUR'S CHRISTMAS COMPETITION: 1 week's holiday in Scanbur's summer house on La Gomera (Canary Islands) was won by:

Jan-Erik Dahlerus, Uppsala Biomedicinska Centrum, Sverige/Sweden