

# Successful Treatment for Idiopathic Thrombocytopenic Purpura in a Japanese Monkey

by *Tohru Kimura*\*

Center for Experimental Animals, National Institutes of Natural Sciences, Aichi, Japan

## Summary

In human beings and dogs, idiopathic thrombocytopenic purpura (ITP) is a well-known disease in which antibodies bound to the surface platelets result in premature platelet destruction by macrophages. However, there is a paucity of information dealing with ITP in non-human primates, especially the Japanese monkey (*Macaca fuscata*). The case is described of a female Japanese monkey suffering from ITP in the Center for Experimental Animals. Physical examinations revealed characteristic findings such as mucosal and cutaneous petechiae, ecchymoses and purpura, epistaxis and mucous membrane pallor. The monkey had severe thrombocytopenia (10,000/ $\mu$ l) on initial hematological examination. Immunosuppressive glucocorticoid therapy had remarkable effects on this condition, with the platelet count rapidly reaching the normal range. On tapering the dose of prednisolone, the number of platelets decreased and the monkey suffered a relapse of ITP. Although immunosuppressive therapy was resumed with the initial dose of prednisolone, the monkey was relatively slow to respond. The initial treatment revealed an apparently faster increase in platelet count than the second treatment following the recurrence of ITP. The monkey remained in complete remission for more than one year after cessation of prednisolone treatment. In blood coagulation profiles and serum biochemical findings, there were no marked changes throughout this investigation. Neither endoscopy nor the stool antigen test provided evidence that natural infection with *Helicobacter pylori* caused ITP in this monkey. This is the first case of successful treatment for idiopathic thrombocytopenic purpura in a Japanese monkey.

## Introduction

Idiopathic thrombocytopenic purpura (ITP) is a disease in which antibodies bound to the surface platelets result in premature platelet destruction by macrophages (Lewis & Meyers, 1996a; Lewis & Meyers, 1996b; Scott & Lewis, 2000; Scott et al., 2002). ITP is well recognized in both human and veterinary medicine and this disease is the most common bleeding disorder in humans and dogs. Clinically, ITP in humans manifests as an acute and chronic disorder. Acute ITP is primarily found in children and has an abrupt onset. This type of ITP is often preceded by viral infection and

is usually self-limiting. Chronic ITP is primarily a disease of adults, and rarely resolves spontaneously (Jain, 1993). Canine ITP most frequently affects middle-aged female dogs and its genetic predisposition is known. Environmental factors including infectious agents, pollutants and stress also play some role in the occurrence of ITP (Scott & Lewis, 2000). However, there is a paucity of information dealing with ITP in non-human primates, especially the Japanese monkey (*Macaca fuscata*). Except for experimental drug-induced thrombocytopenia, ITP has not been described previously in a non-human primate (Ferguson et al., 1979; Petersen et al., 1988; Untch et al., 2002).

In humans, *Helicobacter pylori* (*H. pylori*) infection causes gastritis and peptic ulcer and is also associated with upper gastrointestinal lesions. There are increasing data on the association between *H. pylori* infection and ITP (Gasbarrini et al., 1998; Franchini & Veneri, 2004; Franchini & Veneri,

\*Correspondence: Tohru Kimura

Center for Experimental Animals, National Institutes of Natural Sciences, 38, Nishigo-naka, Myodaiji, Okazaki, Aichi, 444-8585, Japan

Tel +81-564-55-7882

Fax +81-564-55-7881

E-mail kimura@nips.ac.jp

2006; Campuzano-Maya, 2007; Franceschi & Gasbarrini, 2007). Recent studies have demonstrated that eradication of *H. pylori* infection might result in the significant increase of platelet counts in *H. pylori*-positive patients with ITP, thus including *H. pylori* among the possible causes of ITP (Emilia et al., 2007; Tsumoto et al., 2009). In veterinary medicine, however nothing is known about a possible association between *H. pylori* infection and ITP.

A Japanese monkey was suffering from ITP in the Center for Experimental Animals. The purpose of the study reported here was to identify clinically and clinicopathologically this disease in the Japanese monkey. The association between *H. pylori* infection and ITP was also investigated using the *H. pylori* stool antigen test and upper gastrointestinal system endoscopy. Most importantly, successful treatment with prednisolone was achieved for simian ITP, although this was preceded by an initial relapse.

## Materials and Methods

### Animals

A 4-year-old, female Japanese monkey (*Macaca fuscata*) developed idiopathic thrombocytopenic purpura in the course of regular menstruation. This Japanese monkey was one of 12 monkeys, which were purchased from a commercial supplier (Hamri Co., Ltd., Ibaraki, Japan).

The monkeys were individually housed in stainless steel cages (60 × 70 × 160 cm) in an animal room controlled at 25 ± 1 °C and 50 ± 10 % relative humidity with 10 to 15 exchanges of 100 % fresh air/h and a 12-hr light (6AM to 6PM), 12-hr dark (6PM to 6AM) cycle. They were fed a commercial primate diet (PS, Oriental Yeast Co., Ltd., Tokyo, Japan), provided *ad libitum* and supplemented with a variety of fresh fruit, vegetables and other treats daily. Water was provided through an automatic watering system furnished to each cage.

### Immunosuppressive glucocorticoid therapy

Prednisolone (1.0 mg/kg, i. m., Prednisolone Injection, Fujita Pharmaceutical Co. Ltd., Tokyo, Japan) was considered a first-line drug of choice

for the monkey presenting with marked ITP. Immunosuppressive glucocorticoid therapy was continued until the platelet count normalized. This initial therapy lasted 2 weeks and was followed by dose tapering (by 25% per week) for three weeks.

### Procedures

The monkey was anesthetized with the medetomidine (30 µg/kg, Domitol, Meiji Seiyaku Co., Ltd., Tokyo)-midazolam (0.3 mg/kg, Midazolam Injection 0.5 % [F], Fuji Pharmaceutical, Co., Ltd., Tokyo, Japan)-ketamine (2.5 mg/kg, Ketalar 50, San-kyo Co., Ltd., Tokyo, Japan) combination. Complete physical examinations were also performed and blood was drawn for hematology, blood coagulation and serum biochemistry. These investigations were done at the onset of ITP and every week after the beginning of prednisolone therapy. Additionally, the *H. pylori* antigen test and endoscopic examinations were also carried out after clinical manifestations of this disease.

### Blood sample collection

Blood samples were collected weekly from the cephalic vein of the animal using no anticoagulant. At 30 minutes after collection of blood samples, sera were separated by centrifugation at 1,500 g for 10 minutes for biochemical examination. For hematological samples, blood was collected into tubes containing K<sub>2</sub>EDTA. Additionally, citrated blood samples were immediately analyzed for the blood coagulation examinations.

### Hematology

The following parameters were examined using an automated cell counter pocH-iV (Sysmex Co. Ltd, Kobe, Japan): red blood cell count (RBC), hemoglobin concentration (Hb), packed cell volume (PCV), mean corpuscular volume (MCV), mean corpuscular hemoglobin (MCH), mean corpuscular hemoglobin concentration (MCHC), white cell count (WBC) and platelet count (PLT).

Aggregate reticulocytes only were counted on the supravitaly stained blood smear (brilliant cresyl

blue method). The number of reticulocytes was expressed as the reticulocyte count. The reticulocytes were recorded as the incidence (%) per 1,000 RBCs.

A differential WBC count was performed by staining a blood smear with a Romanowsky stain and then examining and classifying 200 WBCs. The classification of WBCs was as follows: neutrophils (band cells (Band) and segmented cells (Seg)), lymphocytes (Lym), monocytes (Mono), eosinophils (Eos) and basophils (Baso).

#### *Blood coagulation*

All blood coagulation values were determined using a semi-automated clotting analyzer (CA-50, Sysmex Co. Ltd, Kobe, Japan). The following measurements were made in plasma: prothrombin time (PT), fibrinogen (Fib) concentrations and activated partial thromboplastin time (APTT).

#### *Serum biochemistry*

The following parameters were measured using a blood chemistry analyzer (Dry Chem 3500: Fuji Film Co. Ltd, Tokyo, Japan): total protein (TP), albumin (Alb), albumin : globulin (A/G) ratio, total bilirubin (T-Bil), blood urea nitrogen (BUN), creatinine (Cre), glucose (Glu), triglycerides (TG), total cholesterol (T-Cho), aspartate aminotransferase (AST), alanine aminotransferase (ALT), alkaline phosphatase (ALP), lactate dehydrogenase (LDH), creatine kinase (CK), amylase (AMS), C-reactive protein (CRP), electrolytes (Mg, Na, K, Cl, Ca) and inorganic phosphorus (IP).

#### *Stool antigen tests*

The *H. pylori* stool antigen test was carried out using the enzyme immunoassay (EIA). This test provides a non-invasive method for the detection of *H. pylori*. Fresh stool specimens were collected from the monkey before any therapy was given. These samples were quickly tested for *H. pylori* using EIA.

#### *Endoscopic examination*

Upper gastrointestinal system endoscopy (Olympus

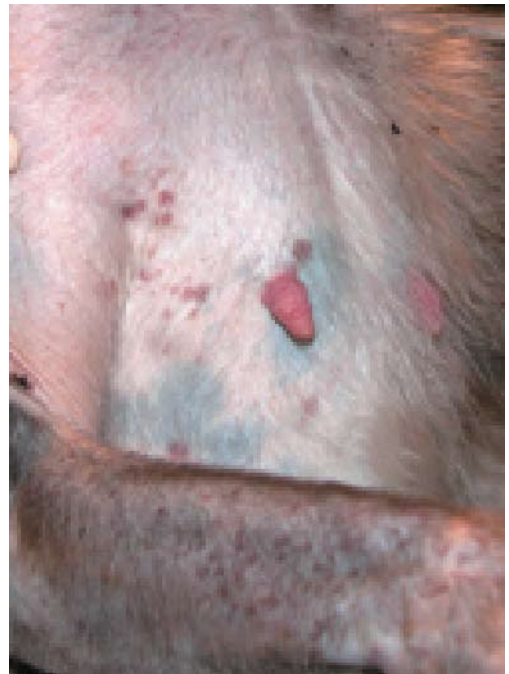VES: AVS Co. Ltd, Tokyo, Japan) was performed in the monkey under general anesthesia. Endoscopic examination was undertaken before the monkey received prednisolone therapy.

## **Results**

### *Clinical findings*

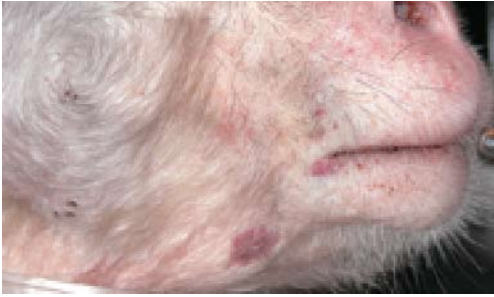The initial signs of the monkey were mild subcutaneous hemorrhage and subsequent purpura. The monkey developed clinical findings such as anorexia, lethargy, weakness and reluctance to move. There was also prolongation of bleeding from venipuncture sites.

By 2 weeks after the onset of the symptoms, physical examinations revealed characteristic findings such as mucosal and cutaneous petechiae, ecchymoses and purpura, epistaxis and mucous membrane pallor (Figures 1 & 2). Petechiae were seen in the oral, gingival, nasal and vaginal mucous mem-



**Figure 1.** Appearance of the Japanese monkey with ITP.

Cutaneous petechiae are seen in the body surface.



**Figure 2.** Appearance of the Japanese monkey with ITP.

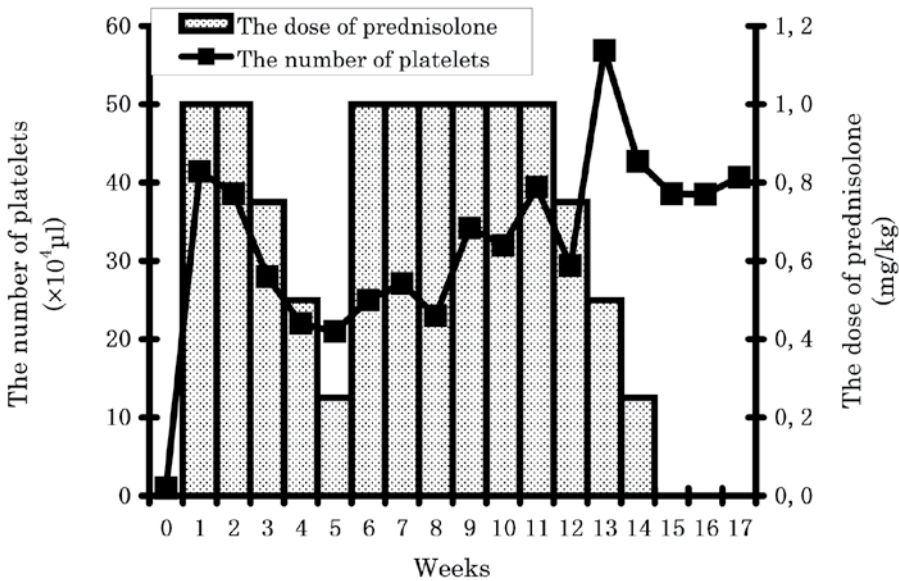
Ecchymoses and epistaxis are seen.

branes. With ecchymoses, these lesions appeared on the skin over the thoracic and abdominal areas, inner aspects of the thighs and forelimbs and in the ear canal. Multiple purpura spread over the entire body. Bleeding tendency from the body orifices was apparent and the monkey revealed excessive hemorrhage during her menstruation period.

*Clinical course*

Immunosuppressive glucocorticoid therapy began immediately after a tentative diagnosis of ITP was made. Based upon diagnostic examination results and suspicion that marked thrombocytopenia was due to an immune-mediated process, the monkey was intramuscularly treated with prednisolone. The dose of prednisolone (1.0 mg/kg) used in the monkey was the same as that used for dogs with ITP. Over the next 2 weeks, the monkey became more alert and active, with a good appetite and normal feces. And then, petechial hemorrhages resolved completely in the skin overlying the body. The monkey attained a PLT to more than  $40 \times 10^4 / \mu\text{l}$  within 1 week of commencing immunosuppressive glucocorticoid therapy.

Although tapering to the minimal effective maintenance dose was dictated by clinical findings, ITP recurred 3 weeks after the beginning of this tapering treatment. ITP relapse (petechial rash) occurred over the entire body surface. Immunosuppressive therapy was resumed using the initial dose of pre-



**Figure 3.** Changes in the number of platelets during prednisolone therapy.

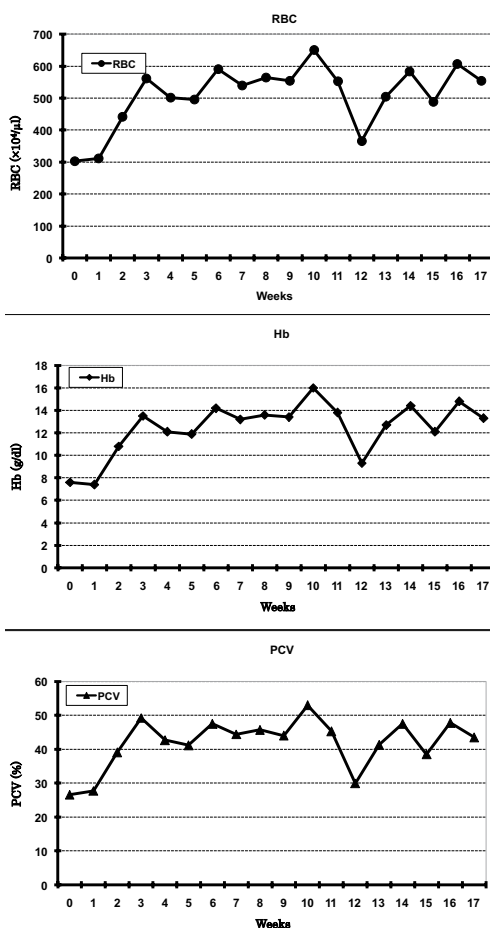
donisolone. Nevertheless, the monkey was relatively slow to respond to prednisolone therapy. After 6 weeks, the dosage of prednisolone was reduced gradually approximately every week for 3 weeks by one-fourth of the former dosage. PLTs were monitored frequently while tapering prednisolone therapy. Tapering therapy continued as long as the PLTs did not decline below the reference range. The monkey showed no recurrence of clinical signs of ITP for more than one year after discontinuation of the drug. Petechial hemorrhages were no longer visible on the monkey's skin with complete remission of ITP. The monkey has remained clinically stable without further therapy.

### Hematology

Sequential analysis of PLTs under immunosuppressive glucocorticoid therapy is shown in Figure 3. The monkey had severe thrombocytopenia ( $10,000/\mu\text{l}$ ) on initial hematological examination. One week after beginning glucocorticoid immunosuppressive therapy, the PLT rapidly reached the normal range ( $414,000/\mu\text{l}$ ) in response to this treatment. With tapering dose of prednisolone, the number of platelets decreased to approximately  $20 \times 10^4/\mu\text{l}$  within 4 weeks.

The monkey suffered a relapse of ITP. In order to cope with the recurrence of this disease, the initial dose of prednisolone was administered to the monkey for 6 weeks. Thrombocytopenia began to subside and the PLTs gradually increased to the normal range. Although the dose of prednisolone was tapered in the aforementioned way, the number of platelets remained unaffected. And then, withdrawal of the drug was followed by complete remission of ITP. For more than 1 year after the discontinuation of prednisolone therapy, the number of the platelets remained stable at the order of  $40 \times 10^4/\mu\text{l}$ .

Erythrocytic profiles (RBCs, Hb concentrations and PCV) under prednisolone therapy are shown in Figure 4. Erythrocytic parameters revealed moderate regenerative anemia on the initial hematological examination. The initial data were as follows: RBCs ( $303 \times 10^4/\mu\text{l}$ ), Hb concentrations (7.6 g/dl), PCV



**Figure 4.** Changes in the erythrocytic parameters (RBCs, Hb concentrations and PCV).

(26.6%) and reticulocytes (217%). These parameters began to increase from 2 weeks after treatment with prednisolone. Although there was a transient decrease in erythrocytic profiles at 12 weeks, the test results were well within normal limits after 3 weeks of prednisolone therapy. There were no abnormal findings in WBCs and in the classification of WBCs throughout the study. The initial data were as follows: WBCs ( $84 \times 10^3/\mu\text{l}$ ), Band (8%), Seg (50%), Lym (27%), Mono (12%), Eos (3%) and Baso (0%).

*Blood coagulation*

Blood coagulation profile is shown in Table 1. PT, APTT and Fib levels remained unaffected at the onset of ITP. There were no alternations for any blood coagulation parameter throughout this study.

**Table 1.** Blood coagulation findings at the onset of ITP

Parameters (units)	Results
PT (sec.)	11.1
APTT (sec.)	25.1
Fib concentrations (mg/dl)	191

**Table 2.** Serum biochemical findings at the onset of ITP

Parameters (units)	Results
TP (g/dl)	5.3
Alb (g/dl)	3.2
A/G ratio	1.5
T-Bil (mg/dl)	0.2
BUN (mg/dl)	13.6
Cre (mg/dl)	0.7
Glu (mg/dl)	102
T-Cho (mg/dl)	98
TG (mg/dl)	84
CRP (mg/dl)	< 0.3
AST (U/l)	25
ALT (U/l)	34
ALP (U/l)	378
LDH (U/l)	426
AMS (U/l)	145
CPK (U/l)	73
Ca (mg/dl)	8.1
IP (mg/dl)	4.2
Mg (mg/dl)	1.9
Na (mEq/l)	135
Cl (mEq/l)	97
K (mEq/l)	3.3

*Serum biochemistry*

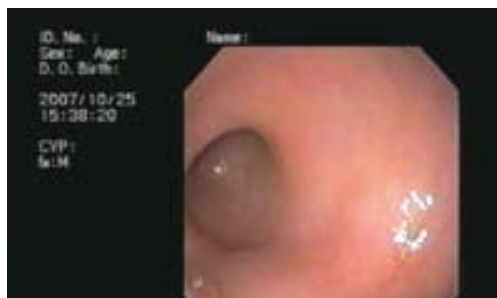Serum biochemical results at the onset of ITP are summarized in Table 2. Excluding slight increases in TP and Alb concentrations, there were no abnormal findings at the onset of ITP. A series of biochemical examinations showed no severe changes during the course of this disease.

*Stool antigen tests*

The *H. pylori* stool antigen test was negative. After the relapse of this disease, the monkey was again negative for the *H. pylori* stool antigen test.

*Endoscopic examination*

Endoscopic observation of the upper gastrointestinal surface is shown in Figure. 5. No upper gastrointestinal lesions including erosion, ulcer and bleeding episode were found.



**Figure 5.** Endoscopic observation of the upper gastrointestinal surface.

No lesions resulting from *H. pylori* are observed.

**Discussion**

Subcutaneous hemorrhages (petechiae, ecchymoses and purpura) resulting from thrombocytopenia were clinically and clinicopathologically investigated in the Japanese monkey. The diagnosis of ITP was made by excluding other etiologies such as neoplasia, infectious disease and drug-associated immune mediated thrombocytopenia. Clinical signs of ITP in the Japanese monkey were in close agreement with those described in humans and dogs (Clark et al., 1980; Williams & Maggio-Price, 1984; Sulliv-

ian et al., 1992; Northern & Tvedten, 1992; Kristensen et al., 1994; Woods et al., 1995; Cohn, 1997; Middleton, 2005; Bianco et al., 2007; ; Gershwin, 2007; Vargo et al., 2007; Putsche & Kohn, 2008). Gender predisposition to ITP is recognized and sex hormones are believed to be more important than X chromosome-associated genes in the tendency (Lewis & Meyers, 1996b). Chronic ITP in humans is more prevalent in females, with a female: male ratio of 3: 1 (Jain, 1993). ITP occurs in female dogs approximately twice as frequently as in male dogs (Lewis & Meyers, 1996b). Clinical findings in this female monkey became more apparent during her menstruation period. The incidence of simian ITP was likely to be governed by the estrous cycle.

Specific therapy for ITP generally begins with immunosuppressive glucocorticoid administration, and then recovery from ITP occurs within a week (Tsumoto et al., 2009). Some 26 to 47% of dogs treated for ITP have recurrence of clinical signs of ITP (Williams & Maggio-Price, 1984; Lewis & Meyers, 1996b; Cohn, 1997; Putsche & Kohn, 2008). The response of this monkey to prednisolone administration agreed with that reported in humans and dogs with ITP. Tapering too gradually is associated with greater glucocorticoid-induced side effects and morbidity, whereas tapering too rapidly causes disease recurrence. Initial glucocorticoid therapy should have been continued until the condition of ITP completely stabilized.

Several studies reported that dogs with ITP developed a high incidence of anemic complications (Williams & Maggio-Price, 1984; Putsche & Kohn, 2008). At the onset of ITP, the monkey exhibited moderate regenerative anemia with apparently increased number of reticulocytes. The recovery of erythrocytic profiles (RBCs, Hb concentrations and PCV) was delayed by approximately a week relative to that of PLTs in response to prednisolone therapy. This finding indicated that regenerative anemia resulted from systemic subcutaneous hemorrhages. Dogs with ITP usually have marked thrombocytopenia (< 30,000/ $\mu$ l) (Scott & Lewis, 2000). An increased bleeding tendency can be observed in

dogs with PLTs < 30,000 to 50,000/ $\mu$ l (Williams & Maggio-Price, 1984). Surprisingly, some dogs have PLTs of < 10,000/ $\mu$ l without evidence of hemorrhages (Lewis & Meyers, 1996b). The present data in the monkey resembled these clinicopathological findings observed in dogs with ITP.

Glucocorticoids are the initial therapy of choice for humans and dogs with ITP. The initial beneficial effect of glucocorticoids is primarily inhibition of macrophage destruction of antibody-sensitized platelets. Autoantibody production is impaired by this therapy and glucocorticoids stimulate platelet production in some patients. Glucocorticoids also increase capillary resistance to hemorrhage, often reducing the severity of hemorrhage before PLTs increase (Campuzano-Maya, 2007). A recent clinical study reported that dogs with ITP (PLTs < 50,000/ $\mu$ l) receiving prednisolone therapy reached normal PLTs after  $6 \pm 2.2$  days (mean  $\pm$  standard deviation). Most relapses occur after reduction of prednisolone dosage. Its dosage is decreased by 0.3 to 0.5 mg/kg body weight per day for 7 to 16 days before recurrence of ITP (Gershwin, 2007). The relapse findings in the monkey were in close agreement with those described in the studies in dogs with ITP.

Immunosuppressive glucocorticoid therapy was resumed as early as 24 hours after recurrence of this disease. In response to immunosuppressive glucocorticoid therapy, the initial treatment revealed an apparently faster increase in PLTs than the second treatment following the recurrence of ITP. Humans and dogs with ITP have increased antiplatelet antibodies bound to platelet surface. Disappearance of platelet-bound antibodies has been detected after immunosuppressive treatment, along with an increase in PLT (Lewis et al., 1995). It is probable that the second prednisolone treatment was less effective in impairing the macrophage-mediated destruction of the opsonized target platelets.

Both in humans and dogs with ITP, blood coagulation profiles are usually within the reference range as long as disseminated intravascular coagulation does not complicate this disease (Clark et al., 1980; Lewis & Meyers, 1996b). Assessment of coagula-

tion pathway (PT and APTT) generally shows no abnormality if the PLT is > 10,000/ $\mu$ l (Day, 1998). The results for the monkey agreed with the above-mentioned clinical reports in humans and dogs with ITP.

Serum biochemical findings revealed slight hypo-proteinemia and hypoalbuminemia at the onset of ITP. TP and Alb levels returned to normal, immediately after the treatment with prednisolone. These changes were attributable to subcutaneous hemorrhages over the entire body surface. Apart from these two parameters, there were no characteristic findings in the monkey with ITP.

A large number of studies have reported the presence of *H. pylori* in patients with autoimmune diseases, particularly with ITP (Gasbarrini *et al.*, 1998; Campuzano-Maya, 2007; Franchini & Veneri, 2004; Franchini & Veneri, 2006; Emilia *et al.*, 2007; Franceschi & Gasbarrini, 2007; Tsumoto *et al.*, 2009). Recently, different invasive and noninvasive diagnostic tests for *H. pylori* have been applied mainly in emerging countries (Cirak *et al.*, 2007; Granstrom *et al.*, 2008). Additionally, ITP in dogs occasionally develops a severe condition and approximately 30% of dogs die during the initial episode, largely from extensive gastrointestinal hemorrhage (Williams & Maggio-Price, 1984; Putsche & Kohn, 2008). The endoscopic method is used to observe directly the lesions on the upper gastrointestinal surface (Cirak *et al.*, 2007; Granstrom *et al.*, 2008). The stool antigen test is considered to be a valuable noninvasive alternative to diagnose *H. pylori* infection before and after its eradication treatment. Neither endoscopy nor the stool antigen test provided evidence that natural infection with *H. pylori* caused ITP in this monkey.

The goal of treatment in dogs with ITP is to withdraw all therapy while maintaining remission. Absence of clinical signs and PLTs of 60,000/ $\mu$ l, 100,000/ $\mu$ l, or 200,000/ $\mu$ l have all been endpoints by which to gauge therapeutic success. In idiopathic immune-mediated disorders, dogs that had markedly increased reticulocytes had significantly lower mortality, as compared with those with mild to poor

regenerative response (Klag *et al.*, 1993; Goggs *et al.*, 2008). The degree of reticulocytosis appeared to be a useful prognostic indicator for animals with ITP. Successful management of this exacerbation was achieved medically with the aid of monitoring laboratory examinations. This monkey suffering from ITP was in complete remission for over 1 year after the cessation of prednisolone treatment.

These results revealed that ITP in the Japanese monkey was clinicopathologically similar to chronic ITP in humans and dogs affected with ITP. Conventional glucocorticoid therapy had a favorable effect on simian ITP and the monkey showed marked improvement on this therapy. After the recurrence of ITP, there was some decreased response of prednisolone. It is important that prednisolone should continue to be administered until the number of platelets is well maintained within the reference range.

## References

- Clark HC, RD Childress & NC Coleman: Idiopathic thrombocytopenic purpura: a review and case report. *Vet Med Small Anim Clin.*, 1980, 75, 427-430.
- Lewis DC, KM Meyers, MB Callan, J Bücheler & U Giger: Detection of platelet-bound and serum platelet-bindable antibodies for diagnosis of idiopathic thrombocytopenic purpura in dogs. *J Am Vet Med Assoc.*, 1995, 206, 47-52.
- Lewis DC & KM Meyers: Studies of platelet-bound and serum platelet-bindable immunoglobulins in dogs with idiopathic thrombocytopenic purpura. *Exp Hematol.*, 1996a, 24, 696-701.
- Lewis DC & KM Meyers: Canine idiopathic thrombocytopenic purpura. *J Vet Intern Med.*, 1996b, 10, 207-218.
- Scott MA & DC Lewis: Immune-mediated thrombocytopenia: Schalm's Veterinary Hematology 5th edn., (Feldman BF, Zinkl JG & Jain NC, eds.), 2000, 478-486, 807-814 (Lippincott Williams & Wilkins, Baltimore).
- Scott MA, L Kaiser, JM Davis & KA Schwartz: Development of a sensitive immunoradiometric



- assay for detection of platelet surface-associated immunoglobulins in thrombocytopenic dogs. *Am J Vet Res.*, 2002, 63, 124-129.
- Jain NC*: Immunohematology: Essentials of Veterinary Hematology. 1993, 381-407 (Lea & Febiger, Philadelphia).
- Ferguson PW, JH Anderson & RI Krieger*: Secondary thrombocytopenia following Phenobarbital treatments in a rhesus monkey (*Macaca mulatta*). *Lab Anim Sci.*, 1979, 29, 94-96.
- Petersen BH, MC Heim & JF White*: Experimental drug-induced immune thrombocytopenia in monkeys. *Diagn Clin Immunol.*, 1988, 5, 349-354.
- Untch B, Ahmad S, Messmore HL, Schultz CL, Ma Q, Hoppensteadt DA, Walenga JM & J Fareed*: Development of a non-human primate sub-clinical model of heparin-induced thrombocytopenia: platelet responses to human anti-heparin-platelet factor 4 antibodies. *Thromb Res.*, 2002, 106, 149-156.
- Gasbarrini A, F Franceschi, R Tartaglione, R Landolfi, P Pola & G Gasbarrini*: Regression of autoimmune thrombocytopenia after eradication of *Helicobacter pylori*. *Lancet*, 1998, 352, 878.
- Campuzano-Maya G*: Proof of an association between *Helicobacter pylori* and idiopathic thrombocytopenic purpura in Latin America. *Helicobacter*, 2007, 12, 265-273.
- Franceschi F & A Gasbarrini*: *Helicobacter pylori* and extragastric diseases. *Best Pract Res Clin Gastroenterol.*, 2007, 21, 325-334.
- Franchini M & D Veneri*: *Helicobacter pylori* infection and immune thrombocytopenic purpura : an update. *Helicobacter*, 2004, 9, 342-346.
- Franchini M & D Veneri*: *Helicobacter pylori*-associated immune thrombocytopenia. *Platelets*, 2006, 17, 71-77.
- Emilia G, M Luppi, P Zucchini, M Morselli, L Potenza, F Forghieri, F Volzone, G Jovic, G Leonardi, A Donelli & G Torelli*: *Helicobacter pylori* infection and chronic immune thrombocytopenic purpura: long-term results of bacterium eradication and association with bacterium virulence profiles. *Blood*, 2007, 110, 3833-3841.
- Tsumoto C, K Tominaga, H Okazaki, T Tanigawa, H Yamagami, K Watanabe, T Nakao, K Koh, T Watanabe, Y Fujiwara, T Yamane, N Oshitani, M Hino, K Higuchi & T Arakawa*: Long-term efficacy of *Helicobacter pylori* eradication in patients with idiopathic thrombocytopenic purpura: 7-year follow-up prospective study. *Ann Hematol.*, 2009, 88, 789-793 .
- Williams DA & L Maggio-Price*: Canine idiopathic thrombocytopenia: clinical observations and long-term follow-up in 54 cases. *J Am Vet Med Assoc.*, 1984, 185, 660-663.
- Sullivan PS, K Arrington, R West & TP McDonald*: Thrombocytopenia associated with administration of trimethoprim/sulfadiazine in a dog. *J Am Vet Med Assoc.*, 1992, 201, 1741-1744.
- Northern J Jr & HW Tvedten HW*: Diagnosis of microthrombocytosis and immune-mediated thrombocytopenia in dogs with thrombocytopenia: 68 cases (1987-1989). *J Am Vet Med Assoc.*, 1992, 200, 368-372.
- Kristensen AT, DJ Weiss & JS Klausner*: Platelet dysfunction associated with immune-mediated thrombocytopenia in dogs. *J Vet Intern Med.*, 1994, 8, 323-327.
- Woods JP, IB Johnstone, D Bienzle, G Balson & CJ Gartley*: Concurrent lymphangioma, immune-mediated thrombocytopenia, and von Willebrand's disease in a dog. *J Am Anim Hos Assoc.*, 1995, 31, 70-76.
- Middleton SM*. Immune-mediated thrombocytopenia in a 4-month-old German shepherd dog. *Can Vet J.*, 2005, 46, 443-445.
- Vargo CL, SM Taylor & DM Haines*: Immune mediated neutropenia and thrombocytopenia in 3 giant schnauzers. *Can Vet J.*, 2007, 48, 1159-1163.
- Gershwin LJ*: Veterinary autoimmunity: autoimmune diseases in domestic animals. *Ann N Y Acad Sci.*, 2007, 1109, 109-116.
- Putsche JC & B Kohn*: Primary immune-mediated thrombocytopenia in 30 dogs (1997-2003). *J*

- Am Anim Hosp Assoc., 2008, 44, 250-257.
- Bianco D, PJ Armstrong & RJ Washabau*: Treatment of severe immune-mediated thrombocytopenia with human IV immunoglobulin in 5 dogs. *J Vet Intern Med.*, 2007, 21, 694-699.
- Cohn LA*: Glucocorticosteroids as immunosuppressive agents. *Semin Vet Med Surg (Small Anim)*, 1997, 12, 150-156.
- Day MJ*: Immune-mediated thrombocytopenia. *Vet Q.*, 1998, 20 Suppl. S43-44.
- Granstrom M, P Lehours, C Bengtsson & F Mégraud*: Diagnosis of *Helicobacter pylori*. *Helicobacter*, 2008, 13 Suppl. 1, 7-12.
- Cirak MY, Y Akyön & F Mégraud*: Diagnosis of *Helicobacter pylori*. *Helicobacter*, 2007, 12 Suppl. 1, 4-9.
- Klag AR, U Giger & FS Shofer*: Idiopathic immune-mediated hemolytic anemia in dogs: 42 cases (1986-1990). *J Am Vet Med Assoc.*, 1993, 120, 783-788.
- Goggs R, AK Boag & DL Chan*: Concurrent immune-mediated hemolytic anaemia and severe thrombocytopenia in 21 dogs. 2008, *Vet Rec.*, 163, 323-327.