



ELSEVIER

Contents lists available at [ScienceDirect](https://www.sciencedirect.com)

Respiratory Medicine Case Reports

journal homepage: www.elsevier.com/locate/rmcr

Case report

Successful removal of distal persistent foreign body airway with CO₂ cryotherapy in a childRoser Ayats-Vidal ^{a,*}, Amalui Vázquez-Pérez ^b, Miguel Gallego-Díaz ^c, Antoni Rosell ^d, Laura Valdesoiro-Navarrete ^a, Rachid Tazi-Mezalek ^e^a Paediatric Pulmonology and Allergy Department, Parc Taulí Hospital Universitari, Institut d'Investigació i Innovació Parc Taulí I3PT, Universitat Autònoma de Barcelona, Sabadell, Spain^b Paediatric Pulmonology Department, Hospital Universitari Joan XXIII, Universitat Rovira i Virgili, Institut d'Investigació Sanitària Pere Virgili, Spain^c Department of Respiratory Medicine, Parc Taulí Hospital Universitari, Institut d'Investigació i Innovació Parc Taulí I3PT, Universitat Autònoma de Barcelona, Sabadell, Spain^d Centro de Investigación Biomédica en Red- Instituto Carlos III (isciii-CIBERES), Institut de Recerca Germans Trias i Pujol (IGTP), Universitat Autònoma de Barcelona (UAB), Thorax Institute, Pulmonology Department, Hospital Germans Trias i Pujol, Badalona, Barcelona, Spain^e Head of the Interventional Pulmonology Program, Bronchoscopy and Pleural disease Unit, Respiratory Department, Thorax Clinic Institute, Hospital Universitari Germans Trias i Pujol, Badalona, Barcelona, Spain

ARTICLE INFO

Keywords:

Foreign body aspiration
Flexible bronchoscopy
Granulation tissue
Cryotherapy
Child
Case report

ABSTRACT

We report a case of a nine-year-old boy with clinical evidence of foreign body (FB) aspiration with 3 months of delay in diagnosis. The bronchoscopy found soft tissue FB with surrounding inflamed granulation tissue at the entrance to the lateral segmental bronchus. Repeated attempts to remove the FB with flexible forceps were unsuccessful due to friable FB and granulation tissue. Ablation of the granulation tissue using nitrous oxide cryotherapy was then successfully performed and the distal and organic FB was extracted. Early diagnosis is important for minimizing granulation tissue development which complicates FB removal. Cryotherapy with a flexible bronchoscope is an option if organic FB cannot be removed using conventional bronchoscopic instrumentation.

1. Introduction

Foreign body (FB) aspiration (FBA) in the tracheobronchial tree is a clinical emergency that can be fatal [1]. Delayed diagnosis of FBA can cause a significant mucosal reaction with edema, granulation tissue formation, post-obstructive bronchopneumonia, bronchiectasis, and chronic pulmonary symptoms [2].

We report the case of a child with delayed diagnosis of FBA for whom conventional bronchoscopy was unsuccessful due to the presence of granulation tissue and the distal location of the FB. The FB was eventually removed using cryotherapy and a flexible bronchoscope.

Abbreviations: FB, foreign body; FBA, foreign body aspiration.

* Corresponding author. Department of Paediatric Pulmonology and Allergy, Parc Taulí Hospital Universitari, Parc Taulí, 1, 08208, Sabadell, Barcelona, Spain.

E-mail address: rayatsv@tauli.cat (R. Ayats-Vidal).

<https://doi.org/10.1016/j.rmcr.2022.101594>

Received 20 July 2021; Received in revised form 23 January 2022; Accepted 24 January 2022

Available online 1 February 2022

2213-0071/© 2022 The Authors. Published by Elsevier Ltd. This is an open access article under the CC BY-NC-ND license

(<http://creativecommons.org/licenses/by-nc-nd/4.0/>).

2. Case presentation

A nine-year-old boy was admitted to the Pediatric Pulmonology Unit after three months of intermittent harsh cough and pulmonary congestion.

The boy's family reported a choking episode with cuttlefish three months earlier. At that time, they had visited the Emergency Department with symptoms of cough and respiratory distress. On examination, the boy's vital signs were stable with normal oxygen saturation on room air. Chest auscultation revealed bilateral wheezes. Chest X-ray was normal. Despite his history of choking, the patient was diagnosed with acute bronchitis and prescribed inhaled salbutamol. Although he experienced relative symptomatic relief, his symptoms continued. This led to multiple visits to the physician over time and his receiving oral corticosteroids, bronchodilators and oral azithromycin.

As the patient's symptoms remained, he was finally referred to a specialist. Physical examination reported bilateral rhonchi and isolated intermittent wheezing. On suspicion of FBA, a flexible bronchoscopy was performed under general anesthesia. Lots of copious secretion was observed in the left main bronchus and, after gentle suctioning, granulomas were observed in the left lower lobe. Respiratory physiotherapy, oral methylprednisolone and co-amoxicillin were prescribed during fifteen days. Endoscopic control detected diffuse mucous secretion and, at the entrance to the lateral segmental bronchus (B9) and in subsegment B9b, a soft tissue FB (cuttlefish) with surrounding inflamed granulation tissue (Fig. 1). Repeated attempts to remove the FB with forceps were unsuccessful due to the friable nature of the FB and the presence of granulation tissue, which meant that only small pieces were removed. An airway balloon and basket also could not be passed distally due to the obstructing granulation tissue. Oral antibiotics and corticosteroids were ordered following the procedure.

The patient was referred to an adult Interventional Pulmonology Unit for management purposes. A bronchoscopy was performed under general anesthesia and assisted ventilation. A combined technique with flexible forceps and a 1.9mm ERBE cryoprobe was performed to reduce the granulation tissue and extract a fragment of the FB (Fig. 2a). Fortunately, the more distal fragments were extracted using a 4Fr Fogarty Catheter (Fig. 2b). Finally, the distal bronchi were free but with inflammatory bronchial mucosa from long-term contact with the FB. Antibiotics and corticosteroids were again ordered before and after the procedure. The patient was discharged the next day with no complications. Two months later, a control flexible bronchoscopy revealed no granulomas or residual bronchial stenosis (Fig. 3).

3. Discussion

FBA occurs frequently in pediatric practice. However, it is not always diagnosed immediately. The accurate history of an acute choking episode followed by coughing or wheezing (usually unilateral) helps to diagnose FBA. Chest radiography should be performed before suspecting FBA. Positive chest x-ray findings are increased radiolucency of one lung or lobe, consolidation, collapse and sometimes pneumothorax. In up to 30% of FBA cases, no obvious abnormality is visible in chest X-rays [3,4] and is one reason for a delayed diagnosis [5]. In our case, a normal chest X-ray and bilateral wheezing made it difficult to initially consider FBA.

Rigid bronchoscopy is still the safest and most reliable method of FB extraction [6]. However, flexible bronchoscopes can reach more distal bronchial divisions thanks to their better navigational properties and smaller size. This capability is especially important when fragments of FB lodge in distal portions of the lower airway that cannot be reached by rigid equipment [7].

Delayed diagnosis and retrieval of FB have been correlated with greater rates of major complications [5]. Bronchoscopy should

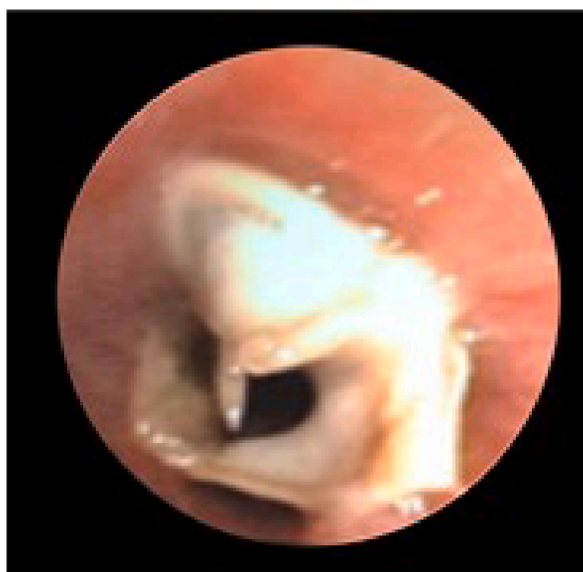

Fig. 1. Bronchoscopy image of inhaled foreign body (cuttlefish) in the left lower lobe with granulation tissue formed.

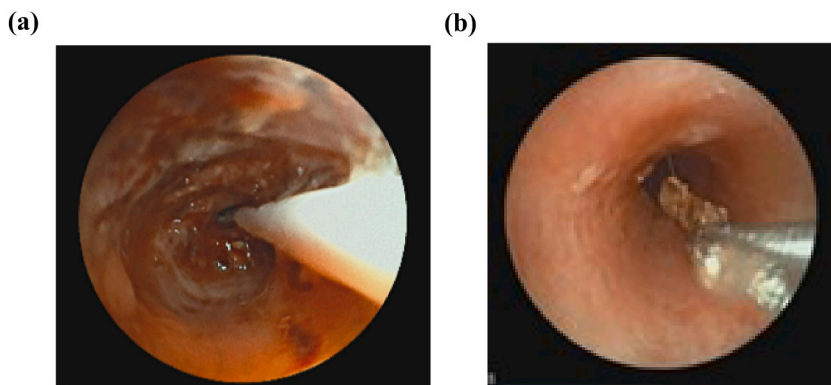


Fig. 2. A: Flexible bronchoscopic image showing cryotherapy applied to ablate the residual granulation tissue. B: Biopsy forceps applied to trim off the FB.

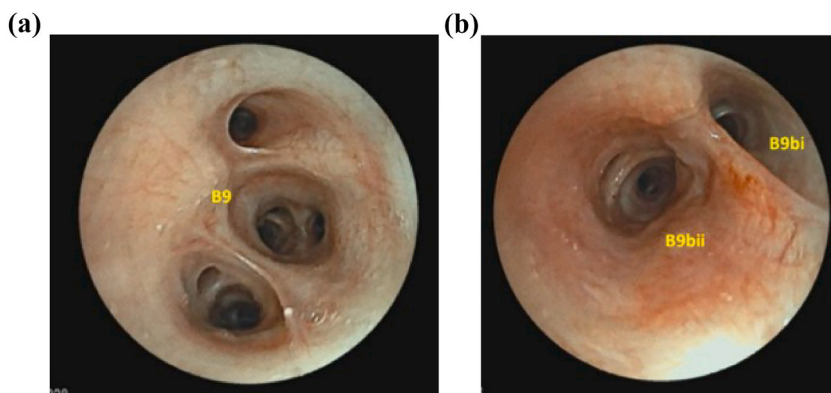


Fig. 3. Flexible bronchoscope image taken two months after removal of the foreign body and illustrating no complications. A: The entrance to the lateral segmental bronchus (B9). B: The subsegment B9b, where it was the foreign body and the granulation tissue.

therefore be performed early after admission to avoid serious complications. Generally, small granuloma resolve spontaneously after the FB is removed or after a course of oral corticosteroids. However, long-standing FB can provoke intense inflammatory reactions and extensive granulation [8]. In our case, the delayed diagnosis of FBA led to the formation of significant granulation tissue whose size and shape made it difficult to grasp the FB with flexible forceps. As the FB was too distal from the airway, we were unable to use rigid bronchoscopy for extraction.

Although interventional bronchoscopic therapies potentially offer an alternative [9], such procedures have not been widely used in pediatric patients and no standardized guidelines exist for treating FB granulation tissues.

Shu et al. described successful alternative resections of granulation tissues during FB removal by flexible bronchoscopy by applying concomitant argon plasma coagulation in nine children [10]. Ni et al. reported bronchoscopic electrocoagulation treatment as a safe therapeutic method in five pediatric patients with granulation tissue hyperplasia caused by FB in the bronchus [11]. Shuxian Li et al. reported different therapeutic modalities in granulation tissue removal from children's deep bronchi by interventional procedures via flexible bronchoscopy (four patients received forceps and CO₂ cryotherapy, one received forceps only and three received holmium laser combined with CO₂ cryotherapy) [8].

Despite the promising results reported in adults [12–21], the use of a cryoprobe during flexible bronchoscopy in children with FBA or granulation tissues caused by FB is largely limited to case reports and small case series [8,22,23]. Cryoprobes come in both flexible and rigid forms [14]. By using the flexible cryoprobe through a flexible bronchoscope, the cryoprobe tip can be more precisely guided to its target and avoid unintentional contact with the surrounding airway [24]. Until recently, most cryoprobes were unsuitable for pediatric flexible bronchoscopy simply because of the probe size relative to the channel size. To our knowledge, the smallest commercially available cryoprobe is 1.9 mm in diameter, which is too large for many pediatric flexible bronchoscopes equipped with a 1.2 mm channel. However, newer bronchoscopes (e.g., MP160, Olympus) whose insertion diameter is suitable for use in young children are now equipped with a 2.0 mm working channel that can accommodate existing cryoprobes.

Adverse events due to bronchoscopy cryoablation occur in approximately 5% of cases or less, with delayed haemorrhage and airway edema being the most common. Airway wall ulceration and perforation is less common with cryoablation than with other ablative techniques including laser and electrocautery [25].

Depending on their nature and characteristics, FB can also be removed effectively by cryoadhesion. Those containing sufficient water for freezing and adhering to the cryoprobe and that are friable and difficult to remove en bloc with standard forceps are ideal for

this procedure [15,17–20,22,23].

4. Conclusion

- FB aspiration is not uncommon in children. Bronchoscopy should be performed at the earliest opportunity when FB aspiration is suspected, even if chest radiography is negative.
- Delayed diagnosis of FBA can result in significant granulation tissue, which can make it difficult to grasp the FB with flexible forceps. In an expert's hands, cryotherapy with a flexible bronchoscope can be useful for removing granulation tissue and extracting FBs and can save patients from enduring more aggressive approaches.

Formatting of funding sources

This research did not receive any specific grant from funding agencies in the public, commercial, or not-for-profit sectors.

Author statement

Roser Ayats and Amalví Vásquez: conceptualization, methodology, writing-Original draft preparation. Rachid Tazi: data curation, supervision, and validation. Miguel Gallego, Dr. Antoni Rosell, Dra. Laura Valdesoiro: Writing-Reviewing and Editing.

All authors approved the final manuscript as submitted and agree to be accountable for all aspects of the work.

Declaration of competing interest

The authors declare that they have no known competing financial interests or personal relationships that could have appeared to influence the work reported in this paper.

Acknowledgments

We thank you to English Editing Service supplied by Linguistic Service form Universitat Rovira i Virgili.

References

- [1] H. Dodson, J. Cook, Foreign Body Airway Obstruction, 2020.
- [2] J.A. Lima, G.B. Fischer, Foreign body aspiration in children, *Paediatr. Respir. Rev.* 3 (4) (2002) 303–307.
- [3] P. Koşucu, et al., Low-dose MDCT and virtual bronchoscopy in pediatric patients with foreign body aspiration, *AJR Am. J. Roentgenol.* 183 (6) (2004) 1771–1777.
- [4] D. Blair, et al., A heuristic approach to foreign bodies in the paediatric airway, *Int. J. Pediatr. Otorhinolaryngol.* 78 (12) (2014) 2262–2266.
- [5] L. Mu, P. He, D. Sun, The causes and complications of late diagnosis of foreign body aspiration in children. Report of 210 cases, *Arch. Otolaryngol. Head Neck Surg.* 117 (8) (1991) 876–879.
- [6] M. Oncel, G.S. Sunam, S. Ceran, Tracheobronchial aspiration of foreign bodies and rigid bronchoscopy in children, *Pediatr. Int.* 54 (4) (2012) 532–535.
- [7] K. Kim, et al., Foreign body removal by flexible bronchoscopy using retrieval basket in children, *Ann. Thorac. Med.* 13 (2) (2018) 82–85.
- [8] S. Li, et al., Interventional therapy via flexible bronchoscopy in the management of foreign body-related occlusive endobronchial granulation tissue formation in children, *Pediatr. Pulmonol.* 56 (1) (2021) 282–290.
- [9] L. Donato, et al., Pediatric interventional Pulmonology, *Clin. Chest Med.* 39 (1) (2018) 229–238.
- [10] L. Shu, Y. Hu, R. Wei, Argon plasma coagulation combined with a flexible electronic bronchoscope for treating foreign body granulation tissues in children's deep bronchi: nine case reports, *J. Laparoendosc. Adv. Surg. Tech.* 26 (12) (2016) 1039–1040.
- [11] C. Ni, et al., Clinical analysis of bronchoscopic electrocoagulation in pediatric patients, *Int. J. Clin. Exp. Med.* 7 (12) (2014) 5657–5662.
- [12] S.M. Abdel Hady, et al., Is surgical resection superior to bronchoscopic resection in patients with symptomatic endobronchial hamartoma? *Interact. Cardiovasc. Thorac. Surg.* 24 (5) (2017) 778–782.
- [13] A. Öztürk, et al., A case of tracheal leiomyoma misdiagnosed as asthma, *Tuberk Toraks* 64 (4) (2016) 306–309.
- [14] J.C. Hewlett, et al., Foreign body aspiration in adult airways: therapeutic approach, *J. Thorac. Dis.* 9 (9) (2017) 3398–3409.
- [15] C. Schumann, et al., Removal of an aspirated foreign body with a flexible cryoprobe, *Respir. Care* 55 (8) (2010) 1097–1099.
- [16] I.S. Sehgal, et al., Use of cryoprobe for removal of a large tracheobronchial foreign body during flexible bronchoscopy, *Lung India* 33 (5) (2016) 543–545.
- [17] N. Sriratanaviriyakul, et al., Safety and clinical utility of flexible bronchoscopic cryoextraction in patients with non-neoplasm tracheobronchial obstruction: a retrospective chart review, *J. Bronchology Interv. Pulmonol* 22 (4) (2015) 288–293.
- [18] E. Rubio, et al., Cryoextraction: a novel approach to remove aspirated chewing gum, in: *Ann Thorac Med*, 2013, pp. 58–59.
- [19] J.C. Seaman, et al., The mean green popsicle: using cryotherapy to remove aspirated foreign bodies, *J. Bronchology Interv. Pulmonol* 17 (4) (2010) 348–350.
- [20] C.M. Kinsey, et al., Evaluation and management of pill aspiration: case discussion and review of the literature, *Chest* 143 (6) (2013) 1791–1795.
- [21] O. Fruchter, M.R. Kramer, Retrieval of various aspirated foreign bodies by flexible cryoprobe: in vitro feasibility study, *Clin. Res. J* 9 (2) (2015) 176–179.
- [22] L. Zhang, et al., Removal of foreign bodies in children's airways using flexible bronchoscopic CO₂ cryotherapy, *Pediatr. Pulmonol.* 51 (9) (2016) 943–949.
- [23] A.P. David, et al., Cryoprobe retrieval of an airway foreign body: a case report and literature review, *Int. J. Pediatr. Otorhinolaryngol.* 125 (2019) 79–81.
- [24] D.M. DiBardino, A.R. Lanfranco, A.R. Haas, Bronchoscopic cryotherapy. Clinical applications of the cryoprobe, cryospray, and cryoadhesion, *Ann Am Thorac Soc* 13 (8) (2016) 1405–1415.
- [25] C. Schumann, et al., Endobronchial tumor debulking with a flexible cryoprobe for immediate treatment of malignant stenosis, *J. Thorac. Cardiovasc. Surg.* 139 (4) (2010) 997–1000.