



Original Article

In Vivo Comparison of the Efficiency of En-Masse Retraction Using Temporary Anchorage Devices With and Without Orthodontic Appliances on the Posterior Teeth

Sanjam Oswal¹, Sonali V. Deshmukh¹, Sanket S. Agarkar², Sachin Durkar¹, Chaitra Mastud¹, Jayesh S. Rahalkar¹

¹Department of Orthodontics and Dentofacial Orthopaedics, Dr. D.Y. Patil Vidyapeeth, Pimpri, Pune, Maharashtra, India

²Private Practice, Pune, Maharashtra, India

Cite this article as: Oswal S, Deshmukh SV, Agarkar SS, Durkar S, Mastud C, Rahalkar JS. In vivo comparison of the efficiency of en-masse retraction using temporary anchorage devices with and without orthodontic appliances on the posterior teeth. *Turk J Orthod.* 2022;35(2):112-119.

Main Points

- This study aimed to compare the effectiveness of en-masse retraction of maxillary anterior teeth with and without orthodontic appliances on the posterior teeth using mini-implants.
- Among the various factors evaluated, a greater amount of retraction is achieved at a faster rate when the posterior teeth are not included during retraction.
- A greater amount of bodily movement is achieved when the posterior teeth are not included during retraction.
- This newer approach to en-masse retraction using mini-implants will provide efficiency in treating bimaxillary protrusion cases with a good Class I molar relationship and optimal intercuspation of posterior teeth.

ABSTRACT

Objective: To compare the effectiveness of en-masse retraction of maxillary anterior teeth using temporary anchorage devices with and without orthodontic appliances on the posterior teeth.

Methods: In the study, 20 participants (18.25 ± 4.07 years) meeting the inclusion criteria were randomly divided into 2 groups using the sequentially numbered opaque sealed envelopes method. In group I (control group, $n = 10$), en-masse retraction was carried out with conventional high hooks soldered to the retraction wire and posterior teeth were included. In group II (experimental group, $n = 10$), the en-masse retraction was carried out without an orthodontic appliance on posterior teeth and a modified retraction wire was incorporated. In both groups, mini-implants were placed bilaterally between the maxillary second premolar and maxillary first molar, and a retraction force of 6 ounces (180 g) was applied using power chains. Lateral cephalograms and study models were taken before retraction and 4 months after retraction. All statistical analyses were performed with Statistical Package for the Social Sciences software with a statistically significant level of 5%. We used unpaired *t*-tests for the comparison, and the error of the method was assessed using intraclass correlation coefficients and the Bland–Altman method.

Results: The maxillary incisor apex retraction, change in maxillary incisor in the vertical plane, and its inclination showed statistically significant differences ($P < .05$). The rate of retraction was significantly greater in the experimental group when evaluated clinically and in the study models ($P < .05$).

Conclusion: The rate/amount of retraction evaluated clinically and in the study models was significantly faster/greater when the posterior teeth were not included during anterior retraction. Also, a greater amount of bodily retraction of anterior teeth was achieved.

Keywords: En-masse retraction, mini-implants, without posterior dental anchorage

INTRODUCTION

Malocclusions characterized by bimaxillary protrusion are commonly encountered in orthodontic practice all over the world. Treatment protocol followed for such cases often involves extraction of all the primary bicuspids,

shadowed by the closure of spaces by retracting the anterior teeth. This enhances patients' esthetic by correcting the malocclusion and in turn improving the soft tissue profile. However, the extraction of bicuspids requires an increase in anchorage reinforcement.¹

Orthodontic anchorage has always been an integral aspect of treatment planning and execution, and several appliances have been designed to fulfill the anchorage demands. These involve transpalatal arches, the Nance buttons, and extraoral traction using headgears in addition to the posterior anchor teeth. It is also advocated to use light, continuous forces for retraction to eliminate possible side effects.^{2,3} However, these appliances possess a few disadvantages such as complex designs, increased patient compliance, and extensive wire bending.⁴ Recently, titanium alloy mini-screws have been suggested as a source of absolute anchorage due to their various advantages.^{3,5}

In the majority of the clinical cases with a bimaxillary protrusion, it is seen that the patient has a good Class I molar relationship and acquires optimal intercuspation of teeth in the posterior segments. But involving the posterior teeth during orthodontic treatment disturbs the pre-existing ideal occlusion, requiring further orthodontic treatment.³

Few authors have efficiently carried out en-masse retraction using mini-implants without bonding the posterior teeth and have named it biocreative therapy.^{3,4,6-10} This therapy provides more simplified orthodontic biomechanics and aids in reducing orthodontic visit time. In their protocol, they have carried out en-masse retraction without bonding the posterior teeth and achieved significant and favorable results making the overall orthodontic experience easy and comfortable for the patients.

Therefore, our study aimed to evaluate and compare the efficiency of en-masse retraction of maxillary anterior teeth using temporary anchorage devices (TADs) with and without orthodontic appliances on the posterior teeth. The null hypothesis was that there is no difference in the rate of retraction, amount of retraction, and the type of tooth movement in both the treatment modalities.

METHODS

This study was reviewed and approved by the Research and Recognition Committee and the Ethics Committee (ethical approval No -DYPDCH/IEC/1262/19/18) of Dr. D.Y. Patil Vidyapeeth, Pune University.

The inclusion criteria involved participants with skeletal Class I malocclusion, Angles Class I bimaxillary protrusion requiring absolute or high anchorage, participants requiring extraction of both the maxillary first premolars, and participants with good periodontal health and oral hygiene. Participants with any known systemic diseases, with a history of previous orthodontic treatment, and with extracted or missing teeth in the maxillary arch except the third molars were excluded. After evaluating the pre-treatment diagnostic records, all participants who met the inclusion criteria were selected and written consent was obtained for the same.

Sample size of 10 participants per group was calculated using convenience sampling technique and the formula used was: $\{N = [(z1-a - zb)s/d] 2 = [(1.96+0.84) 0.7/0.5] = 15\}$

A total of 20 participants (5 males and 15 females) with a mean age of 18.25 ± 4.07 years who met the inclusion criteria were selected and randomly allocated by using sequentially numbered opaque sealed envelopes method into the following groups:

Group I (G-I, control group): En-masse retraction of maxillary anterior teeth using TADs with the orthodontic appliance on posterior teeth (n = 10, mean age = 19.0 ± 4.2 years, 1 male and 9 females) (Figure 1A).

Group II (G-II, experimental group): En-masse retraction of maxillary anterior teeth using TADs without orthodontic appliance on posterior teeth (n = 10, mean age = 17.5 ± 4.0 years, 4 males and 6 females) (Figure 1B).

All participants were strapped up with 0.018" MBT prescription (Gemini series, 3M-UNITEK, USA). In G-I, Dentos™ SH1615-08 mini-implants, and in G-II, Dentos™ TH1817-08 mini-implants were placed bilaterally.

Initial leveling and alignment were carried out using 0.014", 0.016", and 0.016 × 0.022" NiTi wires. The retraction of the anterior teeth was carried out on 0.017 × 0.025" SS wire in both the groups using power chains, and a force of 6 ounces (180 g) was applied using a Dontrix gauge.

In G-I, conventional crimpable hooks were positioned between the lateral incisor and canine bilaterally. The hooks were placed as closely as possible in the line with the center of resistance of maxillary anterior dentition and parallel to the occlusal plane (Figure 2).

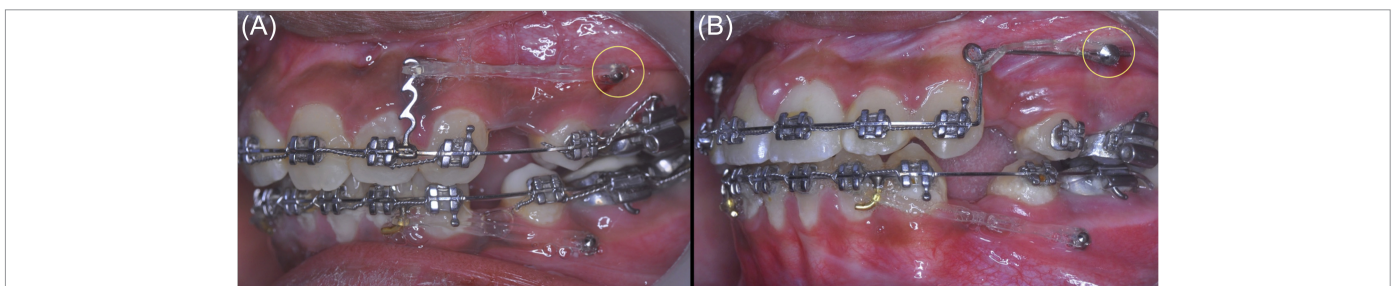


Figure 1. A, B. Retraction design in G-I, control group (A) and retraction design in G-II, experimental group (B). G-I, group I; G-II, group II

In G-II, the retraction wire was modified in its shape to exclude the posterior teeth and a step-up bend was given distal to the canine in line with the TADs and passing through the head of the TADs and the center of resistance of maxillary anterior dentition (Figure 3).

In both the groups, TADs were positioned between the maxillary first molar and maxillary second bicuspid bilaterally in line with the center of resistance of maxillary anterior dentition to achieve bodily retraction of the anterior dentition.

To achieve this, all lateral cephalograms were traced by the first author (S.O.), and a vector diagram was drawn to locate the exact height at which the implant would be placed. The center of resistance of the 6 maxillary anterior teeth group was determined at 13.5 mm superior and 14.0 mm distal to the incisal edge of the maxillary central incisor.¹¹

In all of the participants, mini-implants were placed by the same examiner (S.O.). We did not experience any implant failures, that is, loosening of implants, inflammation at the implant site, or fracture of the implant during mini-implant placement during the 4 months of our experimental study.

Lateral cephalograms and study models (SM) were taken for each participant before retraction (pre-retraction) and 4 months after the start of retraction (post-retraction). Also, the retraction space was clinically evaluated using Vernier calipers intraorally every 3 weeks.

The measurements on pre- and post-retraction lateral cephalogram are shown in Figure 4.

Evaluation of the retraction space was carried out as follows:

1. Clinical evaluation

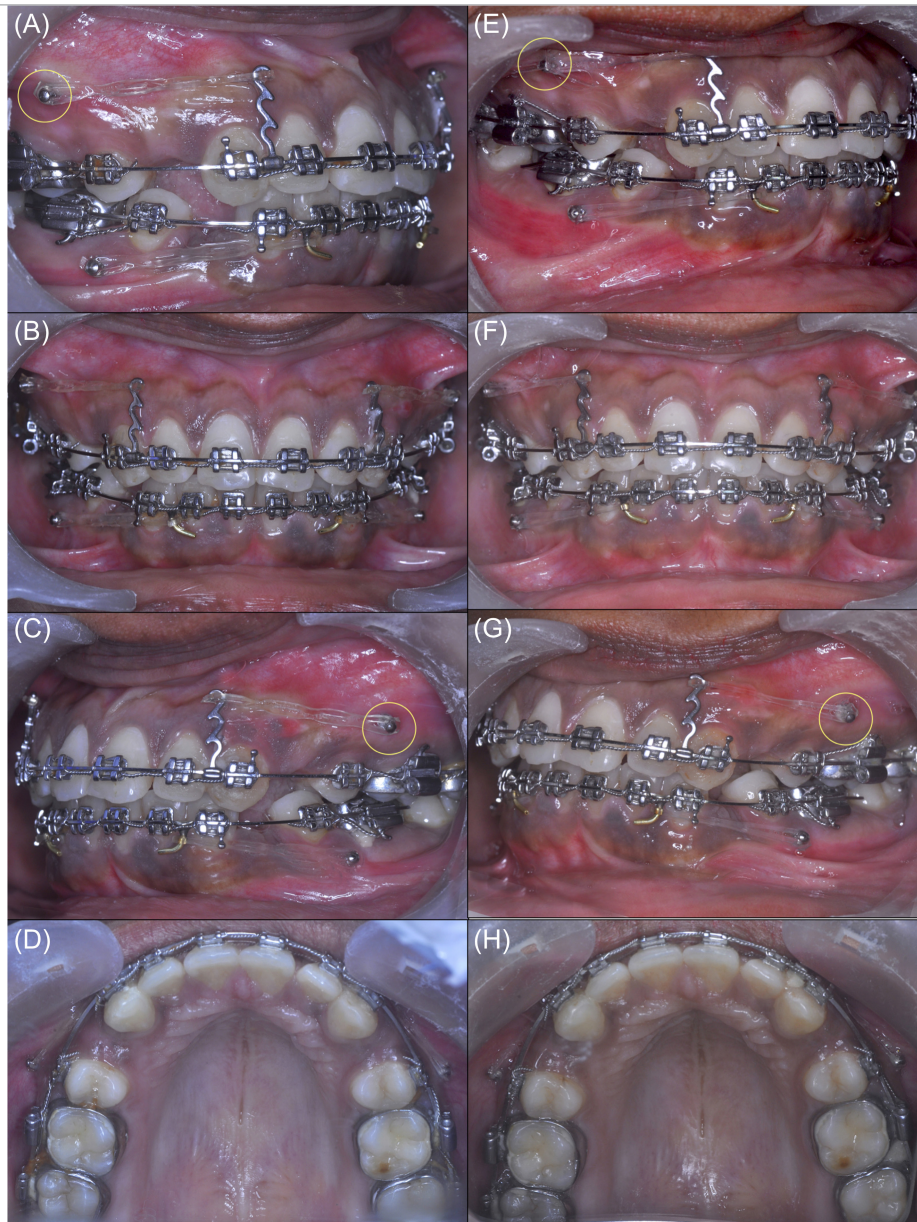

Figure 2. A-H. Pre-retraction (A-D) and post-retraction (E-H) intraoral photographs of G-I (control group). G-I, group I

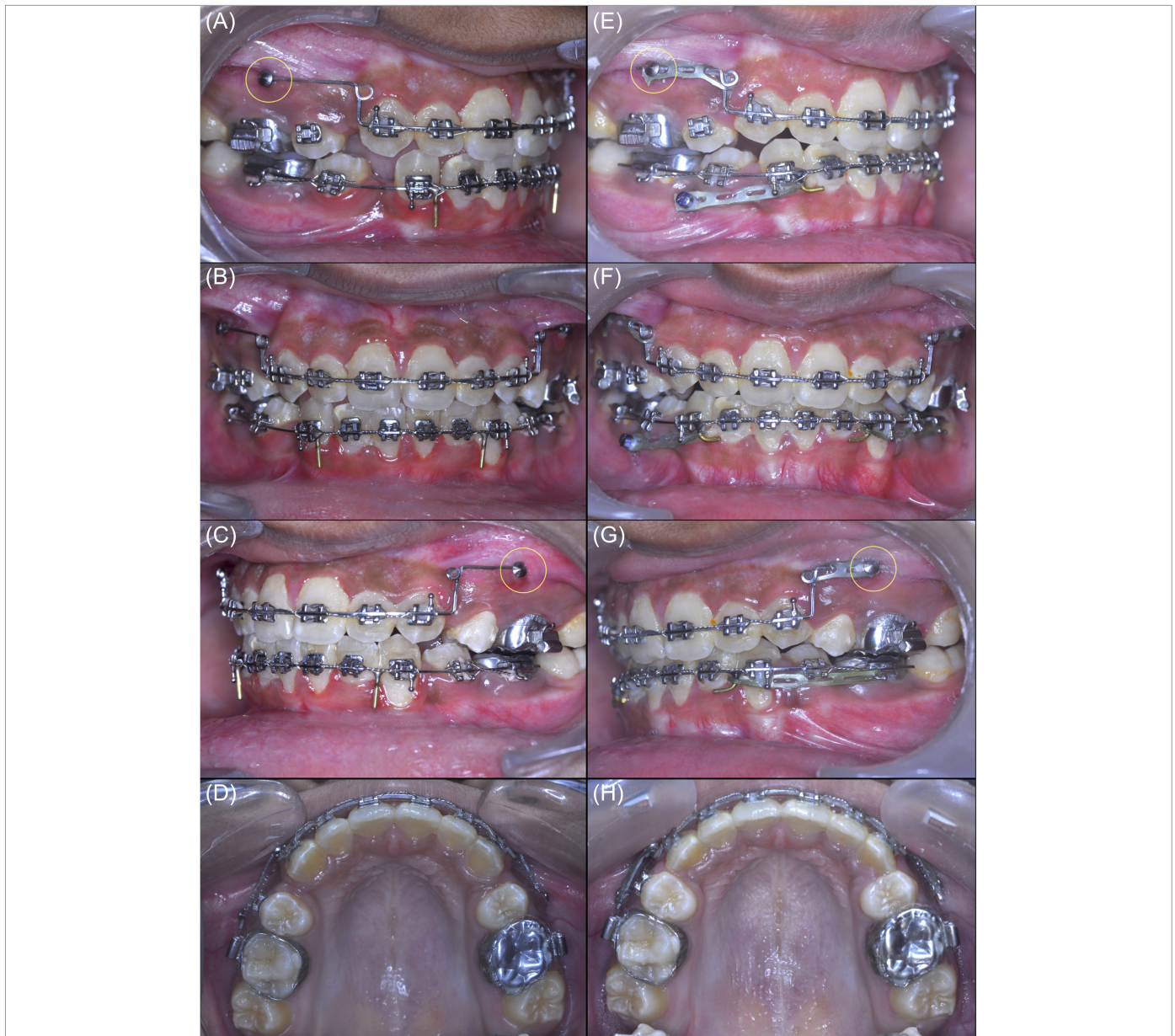

Figure 3. A-H. Pre-retraction (A-D) and post-retraction (E-H) intraoral photographs of G-II (experimental group). G-II, group II

The rate of retraction was evaluated clinically using Vernier calipers at a 3-week interval on both the right and left sides in both groups by the same author (S.O.). These measurements were recorded intraorally from the distal-most point on the maxillary canine to the mesial-most point on the maxillary second premolar.

Each measurement was repeated 3 times, and the mean of the 3 readings was used for statistical analysis.

2. On study models

Pre-retraction (T0) and 4 months from the start of retraction (T1), SM were obtained by the first author (S.O.).

On each initial maxillary cast, an acrylic palatal jig was made with a reference wire (0.021 × 0.025" SS) fixed in the acrylic. One arm was extended to the mesial pit of maxillary first molar and the

other arm to the distal surface of the canine bilaterally as reference landmarks as shown in Figure 5.¹³

Each measurement was repeated 3 times, and the mean of the 3 readings was used for statistical analysis.

Statistical Analysis

All statistical analyses were performed with Statistical Package for the Social Sciences for Windows, Version 19; SPSS Inc. Chicago, Ill, USA. The mean and standard deviation for each cephalometric variable were determined. We used parametric statistical tests (unpaired *t*-tests) to determine the differences between the 2 groups. Power analysis showed that a sample size of at least 10 subjects per group would give an 80% probability of detecting a real difference between the groups at a statistically significant level of 5%. A confidence level larger than 5% was considered statistically insignificant.

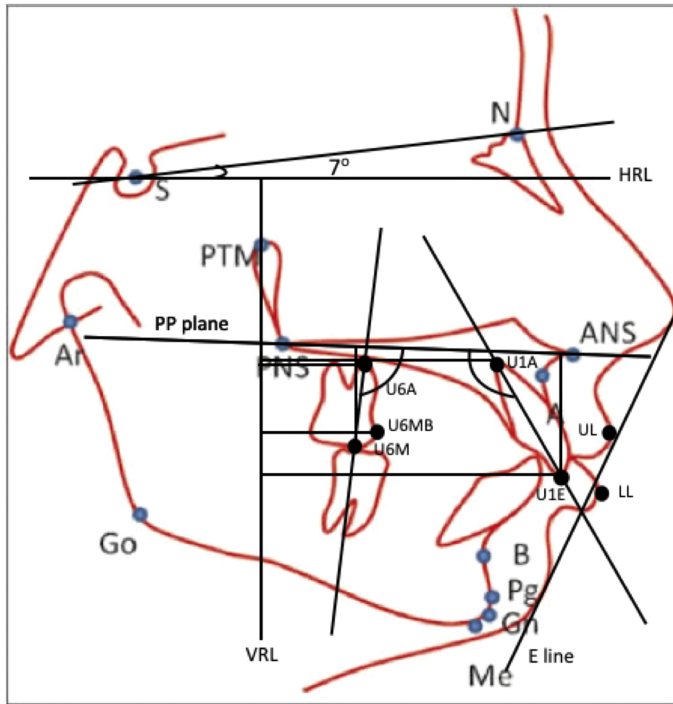


Figure 4. Cephalometric parameters evaluated on lateral cephalogram. HRL, horizontal reference line; VRL, vertical reference line; U6M, maxillary first molar crown; U6A, maxillary first molar apex; U1E, maxillary incisor edge; U1A, maxillary incisor apex; ANS, anterior nasal spine; PNS, posterior nasal spine; PP, palatal plane; U6MB, mesiobuccal cusp tip of maxillary first molar; UL, highest point on upper lip; LL, highest point on lower lip

116

All cephalometric measurements were performed by the first author (S.O.). The same examiner repeated all the cephalometric measurements at a 4-week interval. The error of the method for all variables was assessed using intraclass correlation coefficients and the Bland-Altman method.^{14,15}

RESULTS

The intraoperator agreement for the variables was excellent, with intraclass correlation coefficients ranging from 0.83 to 0.98. The greatest limits of agreement were seen in the linear

measurement value of the variable U6M-VRL (mm), which were -4.41 and 4.71.

The mean age of the participants included in G-I (19.00 ± 4.22) and G-II (17.50 ± 4.01) did not show any statistically significant difference.

Table 1 depicts the intergroup comparison of the means of all cephalometric parameters. We found a statistically significant difference in the following parameters: U1A-VRL (mm, $P = .002$), U1-PP (mm, $P = .019$), and U1-PP (degrees, $P = .031$), whereas no statistically significant difference was found in the following parameters: U1E-VRL (mm), U6M-VRL (mm), U6A-VRL (mm), U6MB-PP (mm), UM-PP (degrees), UL-E-line (mm), and LL-E-line (mm).

When evaluating the rate of retraction clinically, the mean retraction score in G-I was 0.56 ± 0.08 mm/month and 0.52 ± 0.05 mm/month, and in G-II, it was 1.15 ± 0.312 mm/month and 0.94 ± 0.19 mm/month on right and left side, respectively. The mean difference in both the groups was -0.58 ($t = -5.72$, $P < .001$) and -0.41 ($t = -6.55$, $P < .001$) on right and left sides, respectively, and both were found to be statistically significant. (Table 2)

Similarly, when evaluating the rate of retraction on SM, the mean retraction score in G-I was -1.85 ± 0.24 mm and -1.90 ± 0.21 mm, and in G-II, it was -3.80 ± 1.22 mm and -3.40 ± 1.04 mm on right and left sides, respectively. The mean difference in both the groups was 1.95 ($t = 4.92$, $P < .001$) and 1.50 ($t = 4.43$, $P < .001$) on right and left sides, respectively, and both were found to be statistically significant (Table 3).

DISCUSSION

Our study aimed to evaluate and compare the efficiency of en-masse retraction of maxillary anterior teeth using TADs with and without orthodontic appliances on the posterior teeth. The null hypothesis was proven to be wrong.

We found that there was a greater amount of incisor crown retraction in G-II (5.50 ± 1.78 mm) when compared to G-I ($4.80 \pm$

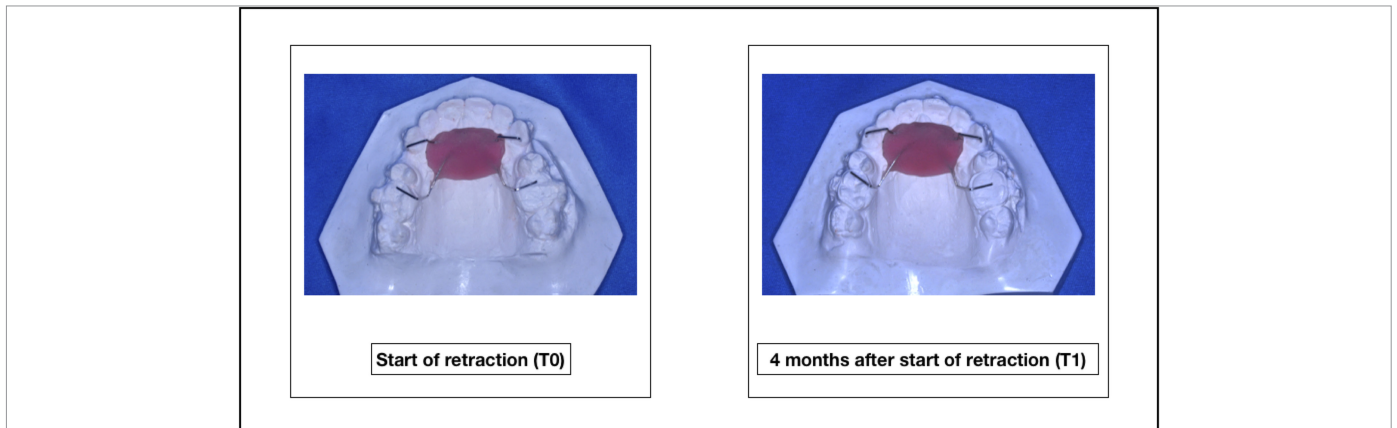


Figure 5. Palatal jig to evaluate retraction

Table 1. Intergroup comparison of the means of all cephalometric parameters using unpaired *t*-Tests

Parameters	Group	Mean Pre-Retraction	Standard Deviation	Mean Post-Retraction	Standard Deviation	Difference	Standard Deviation	<i>P</i>
U1E-VRL (mm)	G-I	52.0	4.83	47.2	3.97	4.80	2.04	.425
	G-II	55.2	4.84	49.7	4.49	5.50	1.78	
U1A-VRL (mm)	G-I	44.3	4.76	42.5	3.91	1.80	1.32	.002
	G-II	44.3	4.45	40.1	3.65	4.20	1.69	
U6M-VRL (mm)	G-I	26.5	3.56	26.4	3.34	0.10	.57	.660
	G-II	29.4	2.79	29.2	2.78	0.20	.42	
U6A-VRL (mm)	G-I	25.5	2.41	25.7	2.26	-0.20	.79	.279
	G-II	26.9	2.60	26.8	2.65	0.10	.32	
U6MB-PP (mm)	G-I	21.8	1.87	22.0	2.05	-0.20	.42	.151
	G-II	21.7	1.82	21.6	1.81	0.10	.32	
U1-PP (mm)	G-I	27	3.85	27.2	3.03	-0.20	0.79	.019
	G-II	26.3	3.40	25.4	2.36	0.90	1.10	
U6-PP (degrees)	G-I	99	4.76	96.2	5.67	2.80	1.55	.749
	G-II	94.2	4.70	91.8	2.57	2.40	3.57	
U1-PP (degrees)	G-I	114.7	5.22	108.8	3.95	5.90	1.10	.031
	G-II	119.4	7.35	111.5	7.12	7.90	2.47	
UL-E line (mm)	G-I	0.15	1.65	-0.62	1.40	0.77	0.89	.369
	G-II	-0.25	1.58	-1.35	1.95	1.10	0.70	
LL-E line (mm)	G-I	3.5	1.77	1.3	1.15	2.20	1.14	.379
	G-II	2.9	4.09	1.2	3.29	1.70	1.34	

Bold font indicates a significant change (*P* < .05).

2.05 mm). This finding did not show any statistically significant difference but, however, may prove to be clinically significant. On the contrary, there was an extensively greater amount of incisor apex retraction in G-II (4.20 ± 1.69 mm) when compared to G-I (1.80 ± 1.32 mm) suggesting a more bodily movement of 4.2 mm when the posterior teeth were not included. Monga et al.¹² in their study found that the maxillary incisor crown and apex were retracted by 5.47 ± 1.65 mm and 2.47 ± 2.07 mm, respectively. Al-Sibaie and Hajeer¹⁶ in their RCT found that the maxillary incisor crown and apex were significantly retracted by 5.92 mm and 4.56 mm, respectively and intruded (1.53 mm and 1.16 mm), which are similar to the results achieved in our study. Seven millimeters of translatory movement was achieved by Park and Kwon,¹⁷ whereas Yao et al.¹⁸ in their study found a greater amount of translatory movement in the mini-implant group. Upadhyay et al.¹⁹ in their study have reported only 1 mm of bodily movement.

The maxillary molar crown in G-II and G-I moved distally by 0.20 ± 0.42 mm and 0.10 ± 0.57 mm, respectively, with no statistically significant difference. Upadhyay et al.¹ in their study found that the maxillary first molars in the implant group intruded by 0.22 ± 0.65 mm and were distalized by 0.78 ± 1.35 mm, and Al-Sibaie and Hajeer¹⁶ found that the maxillary molars were significantly distalized by 0.89 mm after en-masse retraction with mini-implants. These findings are similar to the results achieved in our study. However, several studies have demonstrated the mesial advancement of maxillary molars despite the use of mini-implants to conserve anchorage.^{18,20,21} Kim et al.²⁰ and Monga et al.¹² in their studies found that the maxillary molars were mesialized by 0.74 ± 1.01 mm and 1.27 ± 0.82 mm and extruded by 0.72 ± 0.91 mm and 0.20 ± 1.10 mm, respectively.

A statistically significant difference was seen in the maxillary central incisor when evaluated in the vertical plane. In

Table 2. Intergroup comparison of clinical space evaluation using unpaired *t*-Tests

Side	Group	Mean	Standard Deviation	<i>P</i>
Right side (mm/month)	G-I	0.56	0.09	<.001
	G-II	1.15	0.31	
Left side (mm/month)	G-I	0.53	0.053	<.001
	G-II	0.94	0.19	

Bold font indicates a significant change (*P* < .05).

Table 3. Intergroup comparison of space evaluated on study models using unpaired *t*-Tests

Side	Group	Mean	Standard Deviation	<i>P</i>
Right side	G-I	-1.85	0.24	<.001
	G-II	-3.80	1.23	
Left side	G-I	-1.90	0.21	<.001
	G-II	-3.40	1.05	

Bold font indicates a significant change (*P* < .05).

G-II, the maxillary central incisor intruded significantly by 0.90 ± 1.101 mm, whereas in G-I, it extruded by 0.20 ± 0.79 mm. Monga et al.¹² in their study found that the maxillary incisor was intruded by 2.43 ± 1.31 mm. This is a crucial finding observed in our study suggesting that simultaneous retraction and intrusion can be achieved by omitting the need to include the posterior teeth.

We also evaluated the changes in the upper and lower lip to Rickett's E-line and found that there was no statistically significant difference observed among both groups. Drobocky and Smith²² have concluded that 95% of the cases with all 4 first bicuspid extraction had a reduction in lip protrusion to the E-line. Kusnoto et al.²³ in their study concluded that the upper lip is retracted by 0.4 mm and the lower lip is retracted by 0.6 mm with every millimetric retraction of the lower incisor tip. Talass et al.²⁴ in their study have shown lower lip retraction and escalation in lower lip length and nasolabial angle when the maxillary anterior segment is retracted. Roos²⁵ in his study has concluded that the shape and the position of the lower lip are dependent on the lower incisor position.

118

The mean extraction space available clinically on right and left side was 5.8 ± 1.14 mm and 6.1 ± 1.91 mm in G-I, whereas the mean extraction space available clinically on the right and left side was 6.1 ± 1.19 mm and 5.5 ± 1.43 mm in G-II. The difference in the mean extraction space available on both sides in both the groups necessitated calculating the rate of retraction on either side differently. The mean rate of retraction found in our study was 0.54 mm/month and 1.04 mm/month in G-I and G-II, respectively. Thiruvengkatachari et al.²⁶ have reported the rate of canine retraction using the mini-implant as 0.93 mm/month, and Davis et al.²⁷ in their study have reported the rate of canine retraction using mini-implants as 0.95 mm/month. The rate of retraction evaluated clinically in our study was significantly greater in G-II on both the right and left sides when compared to G-I. With our findings, we can conclude that the rate of retraction evaluated clinically in G-II was more than 2 times faster on the right side and more than 1.5 times faster on the left side when compared to G-I.

Similarly, we calculated the amount of retraction on the right and left sides separately in both the groups on SM. With our findings, we can conclude that the amount of retraction evaluated on SM in G-II was more than 2 times greater on the right side and more than 1.5 times greater on the left side when compared to G-I. This may be because of the difference in the available space on the right and left sides and/or excessive masticatory forces exerted on the right buccal occlusion.

Nienkemper et al.²⁸ have reported the movement of mini-implants in the direction of the applied force. We considered the mini-implants to have a stabilized position and continued with the same retraction force and direction of the force vector. Another limitation of our study was the variation in the mini-implant height. The aim was to insert the mini-implants in line with the center of resistance. But due to biological limitations, it was not possible to place the mini-implants beyond a certain

level in a few of the participants. The design used in the experimental group is technique sensitive and may lead to differing results between different operators and the results achieved in this study.

In our study, when the posterior teeth were not included during retraction, we found that the maxillary incisor apex and crown retracted and intruded at a significantly faster rate with a greater amount of retraction suggesting more of a bodily movement. The upper lip retraction was clinically significant and the maxillary molar crown tipped distally and intruded. Whereas, when the posterior teeth were included, the amount of maxillary incisor apex retraction was significantly less suggesting controlled tipping. The maxillary molar crown was distalized, and there was extrusion seen with the maxillary incisor and molars.

CONCLUSION

The null hypothesis was proven to be wrong, and the following conclusions can be drawn from our study:

- The rate of retraction and amount of retraction was more than 2 times faster/greater on the right side and more than 1.5 times faster/greater on the left side when the posterior teeth were not included.
- The type of movement achieved when the posterior teeth were not included during retraction was more bodily movement (4.2 mm) and when the posterior teeth were included it was more of a tipping movement.
- From the results of this study, it can be concluded that mini-implant-supported en-masse retraction of anterior teeth proves to be more efficient when the posterior teeth are not included during retraction.

Ethics Committee Approval: Ethical committee approval was received from the Research and Recognition Committee and the Ethics Committee of Dr. D. Y. Patil Vidyapeeth, Pune University (Ethical approval No -DYPDCH/IEC/1262/19/18).

Informed Consent: Written consent was obtained from all the participants included in the study.

Peer-review: Externally peer-reviewed.

Author Contributions: Concept - S.O., S.S.A.; Design - J.S.R., S.V.D.; Data Collection and/or Processing - S.O.; Analysis and/or Interpretation - S.O., S.V.D., S.S.A., J.S.R.; Writing - S.D., C.M.; Critical Review - S.V.D., S.S.A., J.S.R.

Acknowledgments: We like to thank Dr. Ravindra Manerikar and Dr. Sandeep Jetha for their constant guidance and support during the entire course of our study.

Declaration of Interests: The authors have no conflict of interest to declare.

Funding: The authors declared that this study has received no financial support.

REFERENCES

1. Upadhyay M, Yadav S, Nagaraj K, Patil S. Treatment effects of mini implants for en-masse retraction of anterior teeth in bialveolar dental protrusion patients: a randomized controlled trial. *Am J Orthod Dentofacial Orthop.* 2008;134(1):18-29.e1. [\[CrossRef\]](#)
2. Renfro EW. The factor of stabilization in anchorage. *Am J Orthod.* 1956;42(12):883-897. [\[CrossRef\]](#)
3. Jee JH, Ahn HW, Seo KW, et al. En-masse retraction with a preformed nickel-titanium and stainless steel archwire assembly and temporary skeletal anchorage devices without posterior bonding. *Korean J Orthod.* 2014;44(5):236-245. [\[CrossRef\]](#)
4. Chung KR, Jeong DM, Kim SH, Ko YI, Nelson G. En-masse retraction dependent on a temporary skeletal anchorage device without posterior bonding or banding in an adult with severe bidentoalveolar protrusion: seven years posttreatment. *Am J Orthod Dentofacial Orthop.* 2012;141(4):484-494. [\[CrossRef\]](#)
5. Costa A, Raffaini M, Melsen B. Miniscrews as orthodontic anchorage: a preliminary report. *Int J Adult Orthodon Orthognath Surg.* 1998;13(3):201-209.
6. Chung KR, Choo H, Lee JH, Kim SH. Atypical orthodontic extraction pattern managed by differential en-masse retraction against a temporary skeletal anchorage device in the treatment of bimaxillary protrusion. *Am J Orthod Dentofacial Orthop.* 2011;140(3):423-432. [\[CrossRef\]](#)
7. Chung KR, Cho JH, Kim SH, Kook YA, Cozzani M. Unusual extraction treatment in class II division 1 using C-orthodontic mini-implants. *Angle Orthod.* 2007;77(1):155-166. [\[CrossRef\]](#)
8. Chung KR, Kim YS, Linton JL, Lee YJ. The miniplate with the tube for skeletal anchorage. *J Clin Orthod.* 2002;36(7):407-412.
9. Chung KR, Kim SH, Kook YA, Son JH. Anterior torque control using partial osseointegrated mini-implants: biocreative therapy type I technique. *World J Orthod.* 2008;9(2):95-104.
10. Chung KR, Kim SH, Kook YA, Choo H. Anterior torque control using partial osseointegrated mini-implants: bio-creative therapy type II technique. *World J Orthod.* 2008;9(2):105-113.
11. Jeong GM, Sung SJ, Lee KJ, Chun YS, Mo SS. Finite-element investigation of the center of resistance of the maxillary dentition. *Korean J Orthod.* 2009 April;39(2):83-94. [\[CrossRef\]](#)
12. Monga N, Kharbanda OP, Samrit V. Quantitative and qualitative assessment of anchorage loss during en-masse retraction with indirectly loaded miniscrews in patients with bimaxillary protrusion. *Am J Orthod Dentofacial Orthop.* 2016;150(2):274-282. [\[CrossRef\]](#)
13. Bhat ZI, Naik CR, Rahalkar JS. Comparison of canine retraction using single and Siamese edgewise brackets: an in vivo study. *APOS Trends Orthod.* 2013;3(4):91-98. [\[CrossRef\]](#)
14. Shrout PE, Fleiss JL. Intraclass correlations: uses in assessing rater reliability. *Psychol Bull.* 1979;86(2):420-428. [\[CrossRef\]](#)
15. Bland JM, Altman DG. Statistical methods for assessing agreement between two methods of clinical measurement. *Lancet.* 1986;1(8476):307-310. [\[CrossRef\]](#)
16. Al-Sibaie S, Hajeer MY. Assessment of changes following en-masse retraction with mini-implants anchorage compared to two-step retraction with conventional anchorage in patients with class II division 1 malocclusion: a randomized controlled trial. *Eur J Orthod.* 2014;36(3):275-283. [\[CrossRef\]](#)
17. Park HS, Kwon TG. Sliding mechanics with micro screw implant anchorage. *Angle Orthod.* 2004;74(5):703-710. [\[CrossRef\]](#)
18. Yao CC, Lai EH, Chang JZ, Chen I, Chen YJ. Comparison of treatment outcomes between skeletal anchorage and extraoral anchorage in adults with maxillary dentoalveolar protrusion. *Am J Orthod Dentofacial Orthop.* 2008;134(5):615-624. [\[CrossRef\]](#)
19. Upadhyay M, Yadav S, Patil S. Mini-implant anchorage for en-masse retraction of maxillary anterior teeth: a clinical cephalometric study. *Am J Orthod Dentofacial Orthop.* 2008;134(6):803-810. [\[CrossRef\]](#)
20. Kim SH, Hwang YS, Ferreira A, Chung KR. Analysis of temporary skeletal anchorage devices used for en-masse retraction: a preliminary study. *Am J Orthod Dentofacial Orthop.* 2009;136(2):268-276. [\[CrossRef\]](#)
21. Kuroda S, Yamada K, Deguchi T, Kyung HM, Takano-Yamamoto T. Class II malocclusion treated with miniscrew anchorage: comparison with traditional orthodontic mechanics outcomes. *Am J Orthod Dentofacial Orthop.* 2009;135(3):302-309. [\[CrossRef\]](#)
22. Drobocky OB, Smith RJ. Changes in facial profile during orthodontic treatment with extraction of four first premolars. *Am J Orthod Dentofacial Orthop.* 1989;95(3):220-230. [\[CrossRef\]](#)
23. Kusnoto J, Kusnoto H. The effect of anterior tooth retraction on lip position of orthodontically treated adult Indonesians. *Am J Orthod Dentofacial Orthop.* 2001;120(3):304-307. [\[CrossRef\]](#)
24. Talass MF, Talass L, Baker RC. Soft-tissue profile changes resulting from retraction of maxillary incisors. *Am J Orthod Dentofacial Orthop.* 1987;91(5):385-394. [\[CrossRef\]](#)
25. Roos N. Soft-tissue profile changes in class II treatment. *Am J Orthod.* 1977;72(2):165-175. [\[CrossRef\]](#)
26. Thiruvengkatachari B, Ammayappan P, Kandaswamy R. Comparison of rate of canine retraction with conventional molar anchorage and titanium implant anchorage. *Am J Orthod Dentofacial Orthop.* 2008;134(1):30-35. [\[CrossRef\]](#)
27. Davis D, Krishnaraj R, Duraisamy S, et al. Comparison of rate of canine retraction and anchorage potential between mini-implant and conventional molar anchorage: an in vivo study. *Contemp Clin Dent.* 2018;9(3):337-342. [\[CrossRef\]](#)
28. Nienkemper M, Handschel J, Drescher D. Systematic review of mini-implant displacement under orthodontic loading. *Int J Oral Sci.* 2014;6(1):1-6. [\[CrossRef\]](#)