



Original Article

# Comparison of Dentoskeletal Changes, Esthetic, and Functional Efficacy of Conventional and Novel Esthetic Twin Block Appliances among Class II Growing Patients: A Pilot Study

Tulika Tripathi , Navneet Singh , Priyank Rai , Prateek Gupta 

Department of Orthodontics and Dentofacial Orthopedics, Maulana Azad Institute of Dental Sciences, Bahadur Shah Zafar Marg, New Delhi, India

Cite this article as: Tripathi T, Singh N, Rai P, Gupta P. Comparison of Dentoskeletal Changes, Esthetic, and Functional Efficacy of Conventional and Novel Esthetic Twin Block Appliances among Class II Growing Patients: A Pilot Study. Turk J Orthod 2020; 33(2): 77-84.

## ABSTRACT

**Objective:** A twin block appliance used for correction of skeletal Class II malocclusion suffers from undesirable dental effects and bulkiness. To overcome these limitations and the need for more esthetic appearance of this appliance, an esthetic twin block was designed and used in patients. This study aimed to compare dentoskeletal changes and esthetic and functional efficacy in patients treated with conventional and newly designed esthetic twin block (CTB and ETB) appliances using cephalometric measurements and a questionnaire.

**Methods:** A pilot study with a 2-arm parallel-randomized double-blind clinical trial was conducted on 24 patients (20 males, 4 females) in the age group of 11-13 years. Subjects were treated with CTB (group 1 [G1]: n=12; mean age=11.67±0.49 years) and ETB (group 2 [G2]: n=12; mean age=11.75±0.62 years) appliances. A modified Pancherz analysis was performed to evaluate skeletal and dental changes. The esthetic and functional efficacy was evaluated by a questionnaire using Likert scale. Wilcoxon and Mann-Whitney U tests were employed for intra and intergroup comparisons respectively (p<0.05).

**Results:** In G1, a significant increase in lower incisor inclination was observed (p<0.05) whereas it was insignificant in G2. The changes were predominantly skeletal in G2 whereas they were both skeletal and dental in G1. ETB was found to be esthetically and functionally acceptable in all the patients while CTB patients were esthetically conscious, lacked confidence and had discomfort and difficulty in eating, chewing and speaking.

**Conclusion:** ETB had greater skeletal effects with a reduced tendency of lower incisor proclination, was esthetically acceptable, and functionally more comfortable than the CTB.

**Keywords:** Class II malocclusion, modified Pancherz analysis, twin block

### Main points:

- Esthetic twin Block (ETB) has been found to be better in terms of esthetic and functional efficacy compared to the conventional twin block (CTB).
- ETB has a better control over lower incisor inclination compared to CTB.
- ETB should be preferred over CTB for mandibular advancement in growing Class II patients.

## INTRODUCTION

Patients with skeletal Class II malocclusion involving retruded mandible demand orthodontic care mostly due to their desire for facial esthetic improvement. Twin block (TB) is one of the most popular functional appliances to treat this condition in the growing phase over the last two decades and yields satisfactory results (1). Since the use of this appliance allows regular functional activities like mastication, it can be worn continuously resulting in faster treatment results compared to those with other functional appliances (2). Despite excellent treatment results with TB, its acceptance and compliance may be hampered by its bulky nature (3). Furthermore, it has an inherent limitation of causing the proclination of lower incisors, which reduces the potential to attain complete skeletal change (4). The position and inclination of the lower incisors in alveolar bone determines the stability

of anterior occlusal contacts and avert gingival recession (5). Various modifications were proposed to circumvent lower incisors proclination, such as southered clasp, acrylic labial bow, ball clasps, and acrylic capping but had no significant effect (6-10). A recent modification suggested the use of a mini-implant to control lower incisor proclination (11). However, its use is limited by the invasive nature of the miniscrew placement.

The success of any appliance depends upon the comfort and esthetic acceptability, which ensures good patient compliance. Moreover, the hallmarks of treatment acceptance have changed contemporarily as the patients emphasize more on esthetics and comfort rather than only on mechanical or biological superiority (12, 13). Hence, in order to enhance esthetic appearance, alleviate bulkiness, and overcome the disadvantages of a conventional TB (CTB), a novel esthetic TB (ETB) was fabricated from a biocryl sheet (Duran® SCHEU Dental Technology, Germany) using a pressure molding device and cold cure acrylic bite blocks. This study was envisaged to compare the dentoskeletal changes and esthetic and functional efficacy of ETB with CTB using cephalometric measurements and a questionnaire.

78

## METHODS

### Study Design

The present study was conducted as a pilot initiative designed in a single clinical establishment as a 2-arm parallel, non-pharmacological, randomized double-blind clinical trial.

### Study Subjects and Inclusion Criteria

This study was conducted among individuals in the age group 11-13 years who reported to the Department of Orthodontics and Dentofacial Orthopaedics, Maulana Azad Institute of Dental Sciences, New Delhi, India, from July to December 2017 (six months). The subjects, who were recruited, had Angle's Class II division 1

malocclusion with a retrognathic mandible, a positive visual treatment objective (VTO), average to horizontal growth pattern along with cervical vertebrae maturation index (CVMI) in transition stage. A written informed consent was obtained from the parents of the subjects. The study was approved by the Institutional Research Ethical Committee (reference no. MAIDS 2015).

### Sample Size Calculation

The sample size was calculated using software G\* Power (Universität Düsseldorf, Germany). In order to have a power of study of 0.95 with an alpha error of 0.05, a minimum of 22 subjects was required (11 in each group) to detect a significant difference of 1.5mm in the lower incisor protrusion (14). Considering a dropout rate of 10% during the study period, 24 subjects were recruited.

### Randomization and Allocation

Patients were equally divided into CTB (group 1, G1; 10 males, 2 females with a mean age of  $11.67 \pm 0.49$  years) and ETB (group 2, G2; 10 males, 2 females with a mean age of  $11.75 \pm 0.62$  years) groups. A simple randomization method was performed using identical, sequentially numbered opaque sealed envelopes to ensure an allocation ratio of 1:1.

### Interventions

#### CTB Appliance

CTB comprised of maxillary and mandibular removable appliances having the labial bow, delta clasps, and ball end clasps with incisal capping and expansion screw.

#### ETB Appliance

The expansion screw (Leone® Italy) was positioned in the midline of maxillary cast with the help of cold cure acrylic (Figure 1a). Thereafter, 1-mm biocryl sheet was adapted separately on maxillary and mandibular casts with help of pressure molding Biostar machine

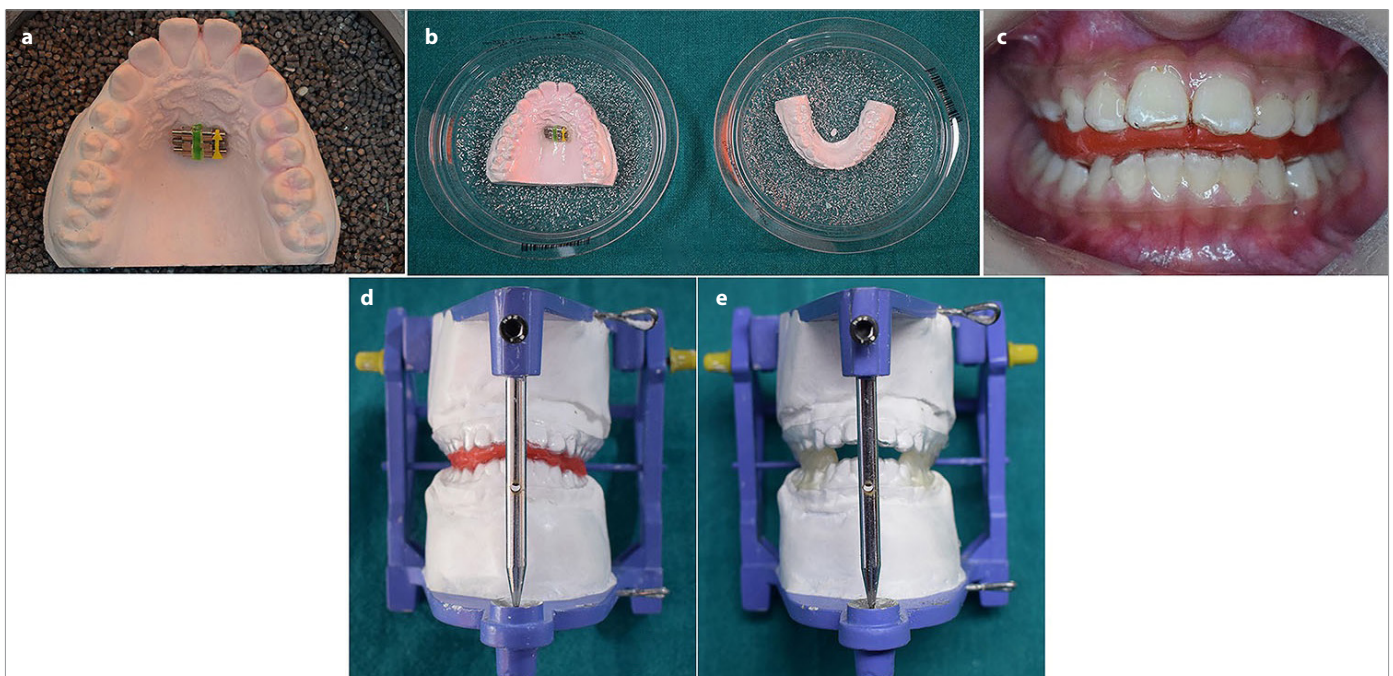


Figure 1. a-e. Steps in fabrication of ETB

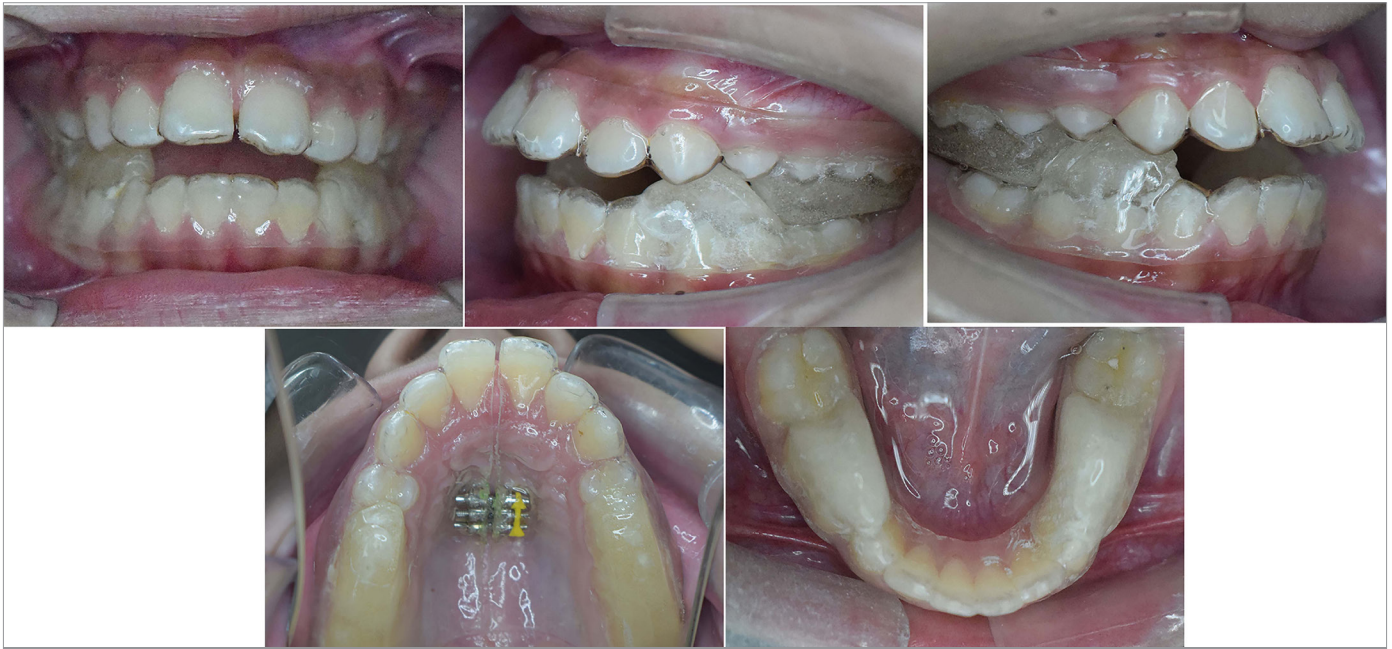

Figure 2. Intraoral photographs with ETB

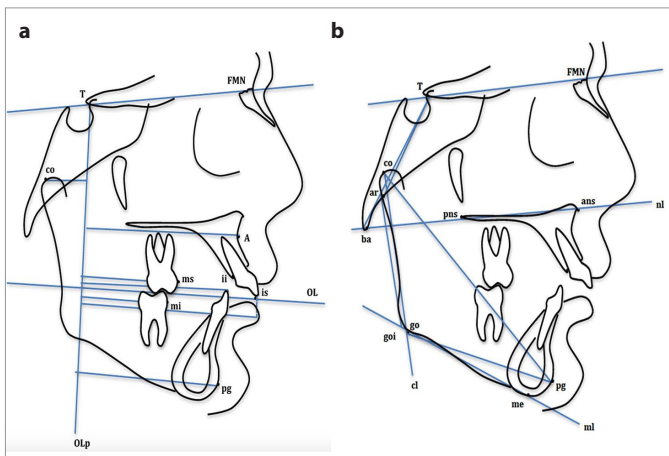


Figure 3. a, b. (a) Modified Pancherz analysis (Linear Dimensions). (b) Modified Pancherz analysis (Angular Dimensions). A, point A; ans, anterior nasal spine; ar, articulare; ba, basion; cl, condylar line; co, condyion; FMN, frontomaxillary nasal suture; go, goi, gonion; ii, incision inferius; is, incision superius; me, menton; mi, molar inferius; ml, mandibular line; ms, molar superius; nl, nasal line; OL, occlusal line; OLp, occlusal line perpendicular; pg, pogonion; pns, posterior nasal spine; T, tuberculum sella

(SCHEU Dental Technology, Germany). This ensured that the expansion screw got incorporated in the maxillary biocryl sheet (Figure 1b). The bite was registered with maxillary and mandibular adapted biocryl sheets in the mouth in a single-step mandibular advancement (Figure 1c). Working models having registered bite along with upper and lower adapted sheets were mounted on the articulator (Figure 1d). Acrylic bite blocks with the inclined plane were fabricated on biocryl sheets similar to CTB (Figure 1e) and the maxillary appliance was split midpalatally (Figure 2).

All the subjects in G1 & G2 were instructed to wear the appliance 24 hours per day including while eating. Regular wear of the appliance by the patient was subjectively assessed by the achieve-

ment of the pterygoid response wherein it became painful for the patient to retract the mandible due to the formation of a tension zone. The trimming was initiated in both groups after achieving a pterygoid response. However, in ETB, the biocryl sheet was relieved from the lower appliance in the first molar region bilaterally before proceeding with bite block trimming. The duration of myofunctional therapy in both groups was 9-12 months.

### Assessment of Treatment Changes

#### 1. Cephalometric evaluation

Lateral cephalograms of all patients were taken in a natural head position on the same cephalostat with teeth in centric occlusion at two stages - pretreatment (T0) and post myofunctional therapy (T1) (15). The cephalograms were traced and evaluated using modified Pancherz analysis to assess the skeletal and dental changes with myofunctional therapy by superimposing the tracings (at T0 and T1) on T-FMN line, with T point as the registration point (Figure 3a, b) (16). Ten randomly selected cephalograms were retraced and evaluated by the same examiner (NS) after a week to check for intra-examiner reliability.

#### 2. Esthetic and functional evaluation

##### a. Preparation of questionnaire

The questionnaire was prepared based on two aspects: measuring esthetic and functional dimensions. Initially, twenty questions from each dimension were generated by a panel of experienced orthodontists (TT & PR) based on a previous similar study (17). Questions which were double negatives, unclear in meaning, and doubtful were removed. Finally, only five questions in each dimension were included (Table 1). Aesthetic acceptance of the subject was evaluated by assessing their routine functions such as smiling and talking to peers. The functional dimension was assessed by chewing efficiency and appliance discomfort.

The esthetic acceptability of CTB and ETB was ascertained by responses to questions 1 to 5 where 1-3 represented consciousness, 4 denoted confidence, and 5 depicted look of the appliance. The response to questions 6 to 10 ascertained the functional efficacy of two appliances.

A five-point Likert scale was used for each question ranging from strong disagreement to strong agreement.

Table 1. Questionnaire for esthetic and functional evaluation	
<b>After wearing the appliance,</b>	
Q1	I can show my teeth while smiling.
Q2	I feel people are staring at me.
Q3	I am afraid of bullying by my peers.
Q4	I avoid looking at myself in the mirror.
Q5	I feel satisfied with the look of the appliance.
Q6	It can easily be worn and removed.
Q7	It caused discomfort.
Q8	It caused difficulty in eating and chewing.
Q9	I felt difficulty in speaking.
Q10	It fitted in my mouth snugly.
Likert scale was used for responses as follows: 1=strongly disagree, 2=disagree, 3=neutral, 4=agree, and 5=strongly agree.	

**b. Translating the questionnaire**

The questionnaire was translated initially from English language to Hindi which was then back translated to English to ensure the accuracy of the translation.

**c. Determination of readability**

Readability of the questionnaire was assessed using Microsoft Word 2010. Questionnaire had a Flesch Reading Score of 76.9, which is equivalent to a reading age of 12 years. The Flesch-Kincaid Grade Level score (4.5) showed a good level of readability.

**d. Test-retest reliability**

Each patient was asked to fill the questionnaire in the fourth week of their regular visit regarding their experience with the appliance. The patient filled the same questionnaire in the sixth week in order to assess the test-retest reliability of the questionnaire. Pearson product-moment correlation coefficient was found to be 0.989-1.000, which indicates good test-retest reliability of the questionnaire.

**e. Ease of Administration**

The questionnaires were checked for completeness and the time taken by each patient to fill the questionnaire was found to be 5-7 min using a stopwatch.

Table 2. Comparative cephalometric changes between Conventional (Group 1) and Esthetic (Group 2) twin block groups.					
Parameters	Treatment changes				Group 1 vs Group 2
	Group 1 (T1-T0) (n=12)		Group 2 (T1-T0) (n=12)		
	Mean±SD	p	Mean±SD	p	
Overjet (mm)	-6.54±1.67	0.002*	-6.54±1.23	0.002*	0.903
Molar relation (mm)	-6.00±0.85	0.002*	-5.79±0.58	0.002*	0.580
Maxillary base (mm)	-0.42±0.51	0.025*	-0.63±0.48	0.007*	0.311
Mandibular base (mm)	2.92 ±0.79	0.002*	4.67 ±0.78	0.002*	0.000*
Condylar head (mm)	0.42±0.67	0.059	-0.17±0.72	0.414	0.059
Composite mandibular length (mm)	3.33±1.07	0.002*	4.5±0.52	0.002*	0.006*
Maxillary incisor (mm)	-0.92±0.67	0.005*	-1.08±0.56	0.013*	0.517
Mandibular incisor (mm)	2.25±0.50	0.001*	0.17±0.32	0.102	0.000*
Maxillary molar (mm)	-0.42±0.51	0.025*	-0.33±0.49	0.039*	0.745
Mandibular molar (mm)	2.25±0.58	0.002*	0.17±0.32	0.102	0.000*
FMN-T ptba (°)	-0.96±0.86	0.010*	-0.25±0.62	0.180	0.048*
FMN-T ptar (°)	-0.83±1.11	0.046*	-0.50±0.80	0.206	0.206
co-pg (mm)	4.92±1.73	0.002*	5.5±2.19	0.002*	0.578
co-go (mm)	2.79±1.5	0.002*	3.17±1.13	0.002*	0.334
go-pg (mm)	2.79±1.07	0.002*	3.75±1.60	0.002*	0.127
cl-ml (°)	1.17±1.11	0.011*	1.17±0.83	0.006*	0.856
ar-goi-me (°)	1.08±0.79	0.003*	1.00±0.60	0.003*	0.945
nl-(FMN-T line) (°)	0.33±2.35	0.565	0.25±0.75	0.257	0.852
ml-(FMN-T line) (°)	1.17±0.54	0.002*	0.88±0.80	0.010*	0.282
nl-ml (°)	0.83±2.24	0.210	0.63±0.93	0.037*	0.677

Superscript (\*) indicates significant changes (p<0.05).  
 SD, Standard Deviation; FMN-T ptba, Frontomaxillary nasal suture-tuberculum sella-basion; FMN-T ptar, Frontomaxillary nasal suture-tuberculum sella-articulare; co-pg, condylion-pogonion; co-go, condylion-gonion; go-pg, gonion-pogonion; cl-ml, condylar line-mandibular line; ar-goi-me, articulare-gonion-menton; nl-(FMN-T line), nasal line-(Frontomaxillary nasal suture-tuberculum sella line); ml-(FMN-T line), mandibular line-(Frontomaxillary nasal suture-tuberculum sella line); nl-ml, nasal line-mandibular line.

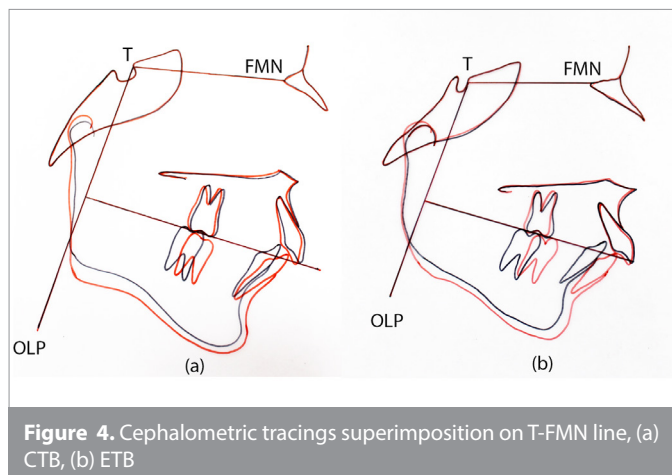
The content validity of the questionnaire was evaluated by a panel of experienced orthodontists (TT & PR), and it was further checked by test-retest reliability and back translation.

### Statistical Analysis

Data were analyzed using The Statistical Package for Social Sciences version 23.0 software (IBM Corp.; Armonk, NY, USA). Intra-examiner reliability was determined by the intra-class correlation coefficient. Non-parametric tests were employed based on the assessment of normality by the parameters of skewness and kurtosis and the Shapiro-Wilk test. Pre- and post-treatment changes in each group were evaluated using the Wilcoxon matched-pair sign test. Intergroup comparison of pre- and post-cephalometric differences and questionnaire items was evaluated by the Mann-Whitney U test. Statistical significance was set at  $p < 0.05$ .

### RESULTS

No patients dropped out during the study. There was no significant difference in baseline data of G1 and G2 patients. The intra-examiner reliability was found to be 0.997-1.000, which showed very good agreement.



**Figure 4.** Cephalometric tracings superimposition on T-FMN line, (a) CTB, (b) ETB

### Cephalometric Evaluation

The cephalometric superimposition on the T-FMN line for CTB and ETB is shown in Figure 4.

The post-treatment outcome in both groups revealed significant change in overjet reduction, molar relation, movement of the maxillary base, mandibular base advancement, maxillary incisors retroclination, maxillary molars distalization, and increase in composite mandibular length ( $p < 0.05$ ) (Table 2).

G1 showed the significant mesial movement of mandibular incisors (2.25 mm;  $p < 0.05$ ) and molars ( $p < 0.05$ ) whereas insignificant change was observed in G2 (0.17 mm).

Intergroup comparison demonstrated statistically significant mandibular base advancement and composite mandibular length increase in G2 ( $p < 0.05$ ) while the change in positions of mandibular incisors ( $p < 0.05$ ) and molars ( $p < 0.05$ ) were statistically significantly more in G1.

### Esthetic and Functional Evaluation

Based on the responses to the questionnaire, the esthetic and functional efficacy of both appliances was evaluated. Significant differences were observed between the groups for all the questions (Table 3).

Approximately 17% of G1 patients and all the patients of G2 agreed that they can show their teeth while smiling after wearing the appliance. As depicted by the response to questions 2-4, patients of G2 were not conscious and more confident as compared to G1. All the patients in G2 were satisfied with the look of the appliance whereas 75% were dissatisfied in G1 (Table 4).

In G2, all patients experienced the ease of wearing and removal of an appliance whereas 83.33% of G1 patients disagreed. All G2 patients found the appliance to be snugly fitting and did not experience any discomfort or difficulty in eating, chewing, or speaking. All G1 patients either agreed or were neutral about discomfort and difficulty in speaking and eating while 33.33% felt a snug fit of the appliance (Table 4).

**Table 3.** Likert scale rating of questionnaire

Questions	Group 1 (n=12) Mean±SD	Group 2 (n=12) Mean±SD	Group 1 vs Group 2
After wearing the appliance,			
1 I can show my teeth while smiling	2.42±0.79	4.75±0.45	0.000*
2 I feel people are staring at me	3.83±0.57	1.42±0.67	0.000*
3 I am afraid of bullying by my peers	3.67±0.49	1.42±0.51	0.000*
4 I avoid looking at myself in the mirror	3.67±0.49	1.42±0.51	0.000*
5 I feel satisfied with the look of the appliance.	2.25±0.45	4.17±0.39	0.000*
6 It can easily be worn and removed.	2.08±0.51	4.67±0.49	0.000*
7 It caused discomfort.	3.58±0.51	1.92±0.67	0.000*
8 It caused difficulty in eating and chewing.	3.83± 0.57	1.58±0.51	0.000*
9 I felt difficulty in speaking.	4.00±0.60	1.33±0.49	0.000*
10 It fitted in my mouth snugly.	3.25±0.87	4.75±0.45	0.000*

Superscript (\*) indicates significant changes ( $p < 0.05$ ).

**Table 4.** Percentage of affirmative responses to the questionnaire

Question	Group	Strongly Disagree	Disagree	Neutral or Unclear	Agree	Strongly Agree
1	1	0	75	8.33	16.67	0
	2	0	0	0	25	75
2	1	0	0	25	66.67	8.33
	2	66.67	25	8.33	0	0
3	1	0	0	33.33	66.67	0
	2	58.33	41.67	0	0	0
4	1	0	0	33.33	66.67	0
	2	58.33	41.67	0	0	0
5	1	0	75	25	0	0
	2	0	0	0	83.33	16.67
6	1	8.33	75	16.67	0	0
	2	0	0	0	33.33	66.67
7	1	0	0	41.67	58.33	0
	2	25	58.33	16.67	0	0
8	1	0	0	25	66.67	8.33
	2	41.67	58.33	0	0	0
9	1	0	0	16.66	66.67	16.67
	2	66.67	33.33	0	0	0
10	1	0	16.67	50	25	8.33
	2	0	0	0	25	75

## DISCUSSION

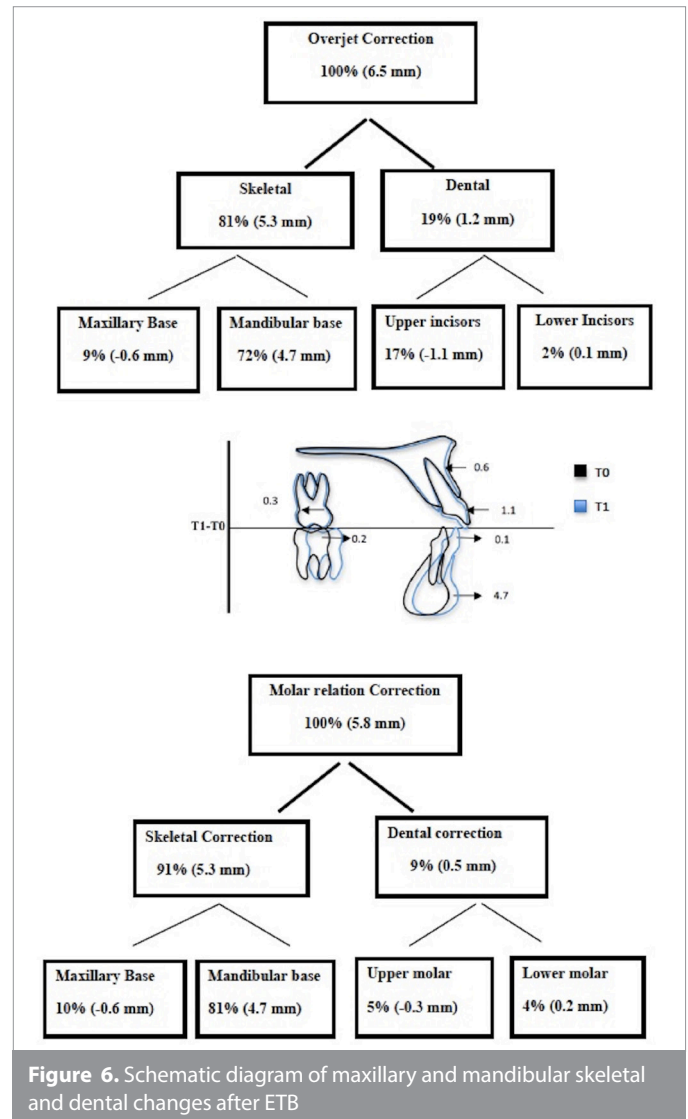
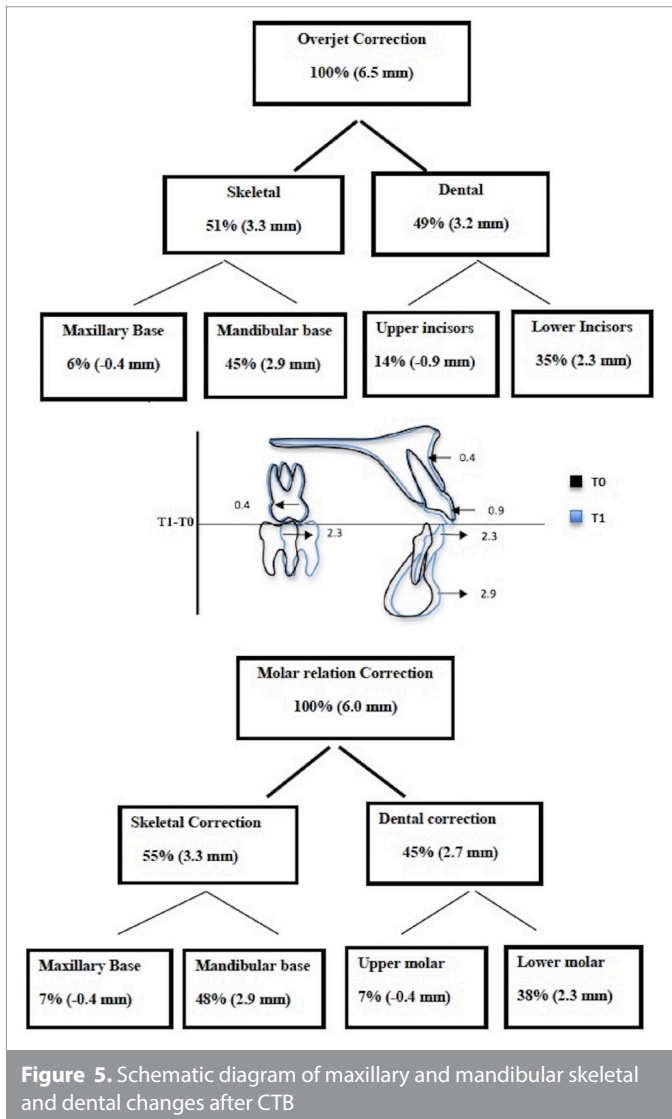
The present study intends to introduce an esthetically viable, functionally competent twin-block appliance in subjects with Class II malocclusion. With the growing demand for esthetic treatment alternatives, orthodontists are developing appliances which are indiscernible (18, 19). The functional appliances in growing patients are conspicuous and bulky, which often makes the patient reluctant and less compliant towards the treatment (3, 19). Hence, a novel ETB was developed with an intention to overcome these drawbacks of CTB. The concept of ETB formed from the biocryl sheet was based on the study by Bechir et al. (20) who observed better esthetics from biocryl sheet as compared to acrylic resin. Thus, this study was conducted to compare dentoskeletal changes and esthetic and functional efficacy of CTB and ETB. The patients enrolled in the study were in the CVMI transition stage as peak mandibular growth is observed in this stage (21). Further, all patients showed positive VTO where the patients' profile improved by a forward repositioning of the mandible and predicted the likely benefit from functional appliance therapy. Modified Pancherz analysis was used for structural superimposition in both groups for quantitative evaluation of dental and skeletal changes. According to You and Hagg (22), the modified Pancherz method has been observed to be the most suitable amongst all other superimposition methods, viz. Ricketts and Bjork.

Patients treated with CTB showed significant reduction in overjet and change in molar relation but the observed change in both the parameters was equally contributed by skeletal and dental effects (Figure 5) which were commensurable with earlier studies (1, 6, 23). The observed skeletal changes were mainly due to statistically significant increment in mandibular base length (2.92 mm), and the amount of increment in mandibular length

(1.46-3.52 mm) also corresponded to previous studies (6-8, 23, 24). Dental changes involving lower incisor proclination and retroclination of maxillary incisors undermine the potential of CTB in achieving the desired skeletal change.

With the use of ETB, a statistically significant reduction in overjet and molar relation were seen which was mainly due to skeletal changes (81%) attributed to significant increment in mandibular base length, whereas no significant change in position of mandibular incisors was seen (Figure 6). The insignificant proclination of lower incisors extended the scope of skeletal correction. The control of the lower incisors proclination could be attributed to the wide coverage of biocryl sheet on all teeth cervically, which further reinforced anchorage, imparting greater stability in the sagittal dimension (25). Skeletal and dentoalveolar contribution to molar relation were almost similar as observed with overjet correction. The increment in mandibular base length (4.67 mm) observed in the present study was greater than that seen in the previous studies involving CTB (6, 7, 23, 24). However, significant retroclination of upper incisors in the ETB group was observed which may possibly be due to a reduction in rigidity caused by splitting of the appliance by expansion screw. Moreover, the retroclination of the upper incisor is desirable and is an advantage in Class II division 1 patients who present with proclined upper anterior teeth (26).

The patient's acceptance and compliance with orthodontic appliances determine their satisfaction while undergoing myofunctional therapy. Hence, the questionnaire was designed to evaluate and compare the patients' experience with CTB and ETB. The questions were composed for easy comprehension and appropriate response by the patients.



**Figure 5.** Schematic diagram of maxillary and mandibular skeletal and dental changes after CTB

**Figure 6.** Schematic diagram of maxillary and mandibular skeletal and dental changes after ETB

The esthetic assessment revealed the acceptance of the appliance by the patient in terms of consciousness, confidence, and facade of the appliance. ETB was more acceptable to the patients as compared to CTB due to the absence of wire components and transparent biocryl sheet, which rendered it inconspicuous in appearance, leading to reduced apprehension during social interactions. Similar findings were observed by Kumar et al. (27) with Essix retainers.

In our study, the insertion and removal were easier with ETB as compared to the CTB. The functional efficacy is governed primarily by the fit and thickness of the appliance. The complete encapsulation of dentition in ETB and better mechanical properties of thermoformed biocryl sheet over cold cure acrylic resin made it more comfortable during eating and chewing. A similar observation was projected by Sheridan et al.(28) Further, the speech was also not affected which was found to be in accordance with the results of Atik et al. (29), who observed less speech difficulty with Essix retainer as compared to that with Hawley retainers. Moreover, the reduced thickness of the biocryl sheet compared to acrylic in the anterior palatal area causes less change in phonetics (30).

ETB was observed to render better treatment results and was superior with respect to the appearance and functional efficacy of

the appliance. Apparently, there was no significant difference in cost-effectiveness between the two appliances. This was a preliminary study of a novel modification, which requires further investigation evaluating gender variation with a larger sample size to corroborate the present results.

**CONCLUSION**

A novel appliance for correction of Class II correction in growing patients with better esthetics was studied for its clinical efficacy. It was found to bring about 81% skeletal and 19% dental changes as compared to 51% skeletal and 49% dental changes with CTB. The ETB showed better lower incisor control as compared to CTB. Moreover, ETB was perceived to be superior in terms of esthetics and function in contrast to CTB, which caused greater discomfort and speech interference besides inferior esthetics. Hence, ETB appliance should be preferred over CTB for mandibular advancement in Class II growing patients.

**Ethics Committee Approval:** The study was approved by Institutional research ethical committee of Maulana Azad Institute of Dental Sciences, New Delhi (Reference no. MAIDS 2015).

**Informed Consent:** Written informed consent was obtained from the patients who agreed to take part in the study.

**Peer-review:** Externally peer-reviewed.

**Author Contributions:** Conception - T.T., P.R.; Design - T.T., P.R.; Supervision - T.T.; Data Collection and/or Processing - N.S., P.G.; Analysis and/or Interpretation - T.T., N.S., P.G.; Writing Manuscript - T.T., P.R., N.S., P.G.; Critical Review - T.T., P.R.; Literature Search - N.S., P.G.

**Conflict of Interest:** The authors have no conflict of interest to declare.

**Financial Disclosure:** The authors declared that this study has received no financial support.

## REFERENCES

- Sidlauskas A. The effects of the Twin-block appliance treatment on the skeletal and dentolaveolar changes in class II division 1 malocclusion. *Medicina (Kaunas)* 2005; 41: 392-400.
- Dauravu LM, Vannala V, Arafath M, Singaraju GS, Cherukuri SA, Mathew A. The assessment of sagittal changes with twin block appliance in patients with decelerating growth phase. *J Clin Diagn Res* 2014; 8: ZC81-4. [\[Crossref\]](#)
- Smailienė D, Intienė A, Dobradziejutė I, Kušleika G. Effect of treatment with twin-block appliances on body posture in class II malocclusion subjects: a prospective clinical study. *Med Sci Monit* 2017; 23: 343-52. [\[Crossref\]](#)
- Al-Anezi SA. Class II malocclusion treatment using combined twin block and fixed orthodontic appliances - a case report. *Saudi Dent J* 2011; 23: 43-51. [\[Crossref\]](#)
- Joss-Vassali I. Orthodontic therapy and gingival recession: a systematic review. *OrthodCraniofac Res* 2010; 13: 127-41. [\[Crossref\]](#)
- Baccetti T, Franchi L, Toth LR, McNamara JA Jr. Treatment timing for twin block therapy. *Am J Orthod Dentofacial Orthop* 2000; 118: 159-70. [\[Crossref\]](#)
- Toth LR, McNamara JA Jr. Treatment effects produced by the twin-block appliance and the FR-2 appliance of Fränkel compared with an untreated class II sample. *Am J Orthod Dentofacial Orthop* 1999; 116: 597-609. [\[Crossref\]](#)
- O'Brien K, Wright J, Conboy F. Effectiveness of early orthodontic treatment with the Twin-block appliance: a multicenter, randomized, controlled trial. Part 1: dental and skeletal effects. *Am J Orthod Dentofacial Orthop* 2003; 124: 234-43. [\[Crossref\]](#)
- Trenouth MJ, Desmond S. A randomized clinical trial of two alternative designs of twin-block appliance. *J Orthod* 2012; 39: 17-24. [\[Crossref\]](#)
- van der Plas MC, Janssen KI, Pandis N, Livas C. Twin block appliance with acrylic capping does not have a significant inhibitory effect on lower incisor proclination. *Angle Orthod* 2017; 87: 513-8. [\[Crossref\]](#)
- Tripathi T, Singh N, Rai P, Gupta P. Mini-implant-supported twin-block appliance: an innovative modification. *Niger J Clin Pract* 2019; 22: 432-38.
- Ziuchkovski JP, Fields HW, Johnston WM, Lindsey DT. Assessment of perceived orthodontic appliance attractiveness. *Am J Orthod Dentofacial Orthop* 2008; 133: 68-78. [\[Crossref\]](#)
- Rosvall MD, Fields HW, Ziuchkovski J, Rosenstiel SF, Johnston WM. Attractiveness, acceptability, and value of orthodontic appliances. *Am J Orthod Dentofacial Orthop* 2009; 135: 276.e1-e12. [\[Crossref\]](#)
- Jena AK, Duggal R. Treatment effects of twin-block and mandibular protraction appliance-IV (MPA-IV) in the correction of class II malocclusion. *Angle Orthod* 2010; 80: 485-91. [\[Crossref\]](#)
- Clark WJ. *Twin block functional therapy: applications in dentofacial orthopedics*. 2nd ed. London: Mosby; 2002.
- Franchi L, Baccetti T, McNamara JA, Jr. Treatment and post-treatment effects of acrylic splint Herbst appliance therapy. *Am J Orthod Dentofacial Orthop* 1999; 115: 429-38. [\[Crossref\]](#)
- Serfl H, Klages U, Pempera J. On the prediction of dentist-evaluated patient compliance in orthodontics. *Eur J Orthod* 1992; 14: 463-68. [\[Crossref\]](#)
- Scott P, Fleming P, DiBiase A. An update in adult orthodontics. *Dent Update* 2007; 34: 427-36. [\[Crossref\]](#)
- Livas C. The Hybrid Aesthetic Functional (HAF) appliance: a less visible proposal for functional orthodontics. *Case Rep Dent* 2013; 298671. [\[Crossref\]](#)
- Bechir A, Pacurar M, Bechir ES, Comaneanu MR, Cires MC, Maris M, et al. Aesthetic importance of resin based dental materials used for orthodontic appliances. *Mater Plast* 2014; 51: 57-61.
- Baccetti T, Franchi L, McNamara JA Jr. The cervical vertebral maturation (CVM) method for the assessment of optimal treatment timing in dentofacial orthopedics. *Semin Orthod* 2005; 11: 119-29. [\[Crossref\]](#)
- You QL, Hägg U. A comparison of three superimposition methods. *Eur J Orthod* 1999; 21: 717-25. [\[Crossref\]](#)
- Baysal A, Uysal T. Dentoskeletal effects of twin block and herbst appliances in patients with class II division 1 mandibular retrognathia. *Eur J Orthod* 2014; 36: 164-72. [\[Crossref\]](#)
- Tümer N, Gültan AS. Comparison of the effects of mono-block and twin-block appliances on the skeletal and dentoalveolar structures. *Am J Orthod Dentofacial Orthop* 1999; 116: 460-8. [\[Crossref\]](#)
- Demira A, Babacanb H, Nalcacic R, Topcuoglu T. Comparison of retention characteristics of essix and hawley retainers. *Korean J Orthod* 2012; 42: 255-62. [\[Crossref\]](#)
- Spalj S, MrozTranesen K, Birkeland K, Katic V, Pavlic A, Vandevska-Radunovic V. Comparison of Activator-Headgear and Twin Block Treatment Approaches in Class II Division 1 Malocclusion. *BioMed Res Int* 2017; 2017: 4861924. [\[Crossref\]](#)
- Kumar AG, Bansal A. Effectiveness and acceptability of Essix and Begg retainers: a prospective study. *Aust Orthod J* 2011; 27: 52-6.
- Sheridan JJ, Ledoux W, Mcminn R. Essix retainers: fabrication and supervision for permanent retention. *J Clin Orthod* 1993; 27: 37-45.
- Atik E, Esen Aydinli F, Kulak Kayikçi ME, Ciger S. Comparing the effects of essix and hawley retainers on the acoustics of speech. *Eur J Orthod* 2017; 39: 440-5. [\[Crossref\]](#)
- Wan J, Wang T, Pei X, Wan Q, Feng W, Chen J. Speech effects of hawley and vacuum-formed retainers by acoustic analysis: a single-center randomized controlled trial. *Angle Orthod* 2017; 87: 286-92. [\[Crossref\]](#)