



## Review

# Pain and/or Discomfort During Debracketing: A Review

Selma Elekdağ Türk 

Department of Orthodontics, Ondokuz Mayıs University School of Dentistry, Samsun, Turkey

Cite this article as: Elekdağ Türk S. Pain and/or Discomfort During Debracketing: A Review. Turk J Orthod 2019; 32(4): 236-40.

## ABSTRACT

The topic of bracket removal and enamel integrity has been extensively investigated. Nevertheless, bracket removal, as far as pain and/or discomfort are concerned, is poorly delineated in the orthodontic literature, i.e., the scarcity of reports in this area is conspicuous. In fact, only six studies were retrieved upon a PubMed search. These clinical studies performed with metal brackets are presented in a chronological order in the present review. Pain and/or discomfort during bracket removal are urgently in need of additional studies. The orthodontists have to be well-informed and updated to convey all the aspects of this procedure to the patient.

**Keywords:** Pain, discomfort, debracketing, orthodontics

*“Whatever words we utter should be chosen with care for people will hear them and be influenced by them for good or ill.”*  
Buddha

## INTRODUCTION

The International Association for the Study of Pain described pain as “an unpleasant sensory and emotional experience associated with actual or potential tissue damage, or described in terms of such damage.” The final phrase of this definition, i.e., “or described in terms of such damage,” was intended to acknowledge the complaints of individuals experiencing pain without evidence of tissue stress or damage, despite a thorough investigation (1). The definition of pain as presented in 1979 is still considered valid today (2).

The multifaceted and biopsychosocial phenomenon of pain is a subjective, complex response, which demonstrates large individual variation (3, 4). It has been emphasized that the perception of pain may be linked to a large number of factors, such as age, individual pain threshold, gender, cultural differences, present emotional state and stress, previous pain experiences, and genetic, as well as epigenetic mechanisms (3-5).

In orthodontics, the terms “pain” and “discomfort” are frequently used to describe an unpleasant feeling or experience. These two terms are often used interchangeably in orthodontics; yet, they do by no means imply the same intensity or magnitude (6). For example, the use of burs and discs, as well as rubber cups, with pumice for adhesive remnant removal, subsequent to debracketing of healthy teeth, might cause some discomfort; however, not pain. The lack of a clear-cut distinction between these two terms does create ambiguity.

Furthermore, the term “debonding” needs to be defined. Debonding is the removal of orthodontic brackets (debracketing) and the residual adhesive from the enamel at the completion of active orthodontic treatment (7).

A considerable amount of studies whether orthodontic patients experience pain and/or discomfort during treatment have been published (3, 4, 6, 8-12). Nevertheless, little has been reported regarding pain and/or discomfort

in relation to bracket removal, i.e., debracketing (4). A PubMed database search revealed only six clinical studies on this topic. These studies were all performed with labial metal brackets (13-18). The scarcity of studies in this area is conspicuous (Table 1). These studies are presented chronologically (13-18).

In 1992, the first study regarding this topic was conducted (13). This pilot study was composed of 15 (10 female and 5 male) patients and assessed the discomfort threshold immediately before bracket removal. The discomfort threshold was described as the point just before the feeling of pain during force application. These forces, such as intrusive, mesial, distal, lingual, buccal, extrusive, and torque (a shear-torsion force), were applied to the bracket or to the enamel surface after archwire removal. The shear-torsion force was applied with a forked lever arm, 87.6 mm in length, grasping the mesial and distal sides of the metal bracket. A force meter able to record the forces ranging from 100 to 1000 g was used. No attempt was made to remove the metal brackets during this testing.

The previous study concluded that the discomfort threshold is significantly influenced by the direction of force application and the mobility of the tooth (13). Teeth with increased mobility demonstrated increased sensitivity. Intrusive forces were the best tolerated type (mean average 934 g) of force application, whereas extrusive forces were the least tolerated (mean average 827 g). Teeth were most sensitive to the application of shear-torsion force. Nevertheless, a mean average value in g could not be obtained for this type of force application, since the force gauge could not record forces <100 g. Thus, the previous study cautioned that this type of force, applied with a long lever arm, should be avoided during bracket removal (13).

Gender and tooth type differences also had an effect on the discomfort threshold, but to a lesser degree (13). Data regarding the age of the participants were not given.

This study's clinical implications were highlighted, namely the clinician should apply finger pressure or ask the patient to firmly bite into a piece of cotton roll to provide an intrusive, stabilizing force during bracket removal (13). The better stabilized the teeth, the better they are able to withstand the debracketing forces. Discomfort during bracket removal can be minimized in this manner (13).

In 2010, a split-mouth study assessed the level of discomfort and pain during debracketing (14). A total of 37 (25 female and 12 male) patients composed this study. The age of the patients ranged from 12 years and 9 months to 44 years and 2 months. Two instruments, the lift-off debracketing instrument (LODI; 3M Unitek, Monrovia, CA, USA) and a ligature cutter plier, were used. With the LODI method, a piston grip plier was positioned over the bracket, and a pulling force was applied on the bond through a pull-wire placed under the bracket tie-wing, thereby pulling the bracket directly away from the tooth surface. With the ligature cutter plier method, the pliers grabbed the bracket wings and applied gentle pressure mesially and distally. All metal brackets were removed by the same professional. The archwire was removed prior to debracketing.

Discomfort was determined by asking the patients to assess, on a scale of 0–4, the level of sensitivity at the time each bracket was removed. The scale is rated as follows: 0, total absence of pain; 1, mild discomfort with no pain; 2, mild pain; 3, considerable pain, yet tolerable, pain; and 4, intolerable pain.

No pain and mild discomfort were the most frequently reported scores for both methods. Yet, 12.8% of the patients reported pain (score  $\geq 2$ ) with the LODI, whereas 24.3% of the patients reported pain (score  $\geq 2$ ) with the ligature cutting plier. Therefore, the LODI is the preferred method.

The amount of composite remaining on the tooth surface after debracketing was determined with a minor modification of the original Adhesive Remnant Index (ARI) (19). Interestingly, the ARI was the same for both debracketing methods. These researchers underlined that the ideal bracket removal should be free of pain, as well as free of harm to the enamel (14).

The author of this review believes that a comment regarding the wide age range at the time of bracket removal, from 12 years and 9 months to 44 years and 2 months, of this study is appropriate (14). A systematic review and meta-analysis concluded that there is insufficient evidence regarding age and pain perception (20). Interestingly, another systematic review and meta-analysis (21) published within the same year as the study by El Tumi et al. (20) stated that aging reduces pain sensitivity, i.e., the pain threshold increases with age. In light of these

**Table 1.** Summary of the publications (PubMed) on pain and discomfort during debracketing

Authors	Year	Country	Bracket type	No. of patients	Age range (year/month)	Archwire at debracketing	Pain assessment
Williams and Bishara (13)	1992	USA	Metal	15 (10 females and 5 males)	Not given	Ex situ	Discomfort threshold (the point just before feeling pain during force application)
Normando et al. (14)	2010	Brazil	Metal	37 (25 females and 12 males)	12/9–44/2	Ex situ	Pain and discomfort evaluation with a scale from 0 to 4
Mangnall et al. (15)	2013	UK	Metal	90 (51 females and 39 males)	12/0–18/0	In situ	VAS
Pithon et al. (16)	2015	Brazil	Metal	70 (70 females)	14/3–45/11	Ex situ	VAS
Bavbek et al. (17)	2016	Turkey	Metal	63 (32 females and 31 males)	13/0–21/0	In situ	VAS
Kilınç and Sayar (18)	2019	Turkey	Metal	120 (84 females and 36 males)	12/0–18/0	In situ	NRS

findings, even though not consistent, a narrower age range for future studies on pain perception during debracketing might be prudent (20, 21).

Furthermore, the author of this review believes that some facts about the LODI will be beneficial for the reader, since this instrument is not routinely used by orthodontic clinicians (Figure 1). The instructions for use state that the even contact of this instrument's plastic rests with the enamel surface stabilizes the tooth (22). It is also indicated that for hypersensitive or mobile teeth, the application of an intrusive force with a finger on the incisal edge/occlusal surface reduces discomfort during debracketing. The pull-wire of this instrument is engaged under one gingival or occlusal bracket wing with full-size brackets, whereas the pull-wire is engaged under two gingival or occlusal bracket wings with miniature brackets for debracketing. Finally, it is pointed out that this instrument is only appropriate for the removal of metal brackets.

Normando et al. (14) did not give any information whether such an intrusive force was applied.

238

In 2013, a randomized controlled trial evaluated the patients' expectations of pain prior to fixed appliance removal and whether biting into a 3-millimeter thick, U-shaped, soft acrylic bite wafer minimizes pain during this procedure (15). A total of 90 (51 female and 39 male) patients with pre-coated metal brackets composed this study. The age of the patients ranged from 12 to 18 years. The patients were randomly allocated to the control group or to the wafer group. The bite wafers were manufactured "in-house." The control group had their teeth out of occlusion during bracket removal.

The archwire was left in situ during bracket removal for both groups. Bracket removal was performed by one investigator. A bracket removal plier (BRP) with right-angled beaks for easy

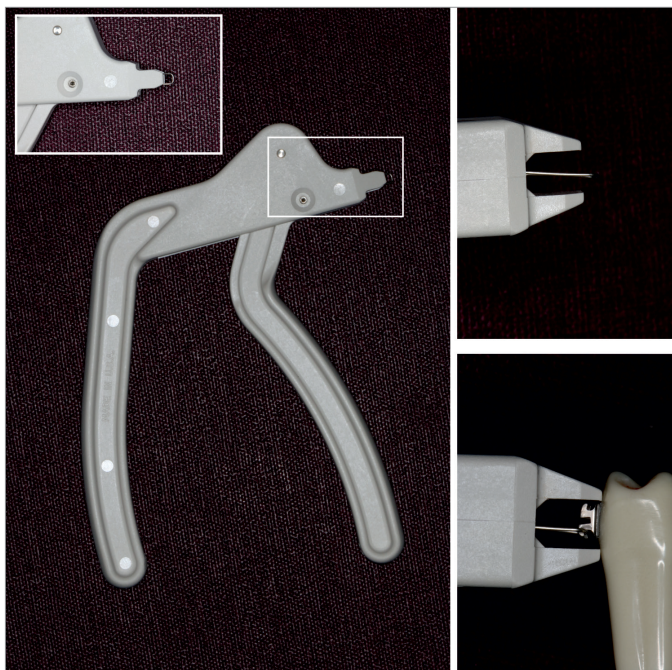


Figure 1. The lift-off debracketing instrument

access was used. The beaks of this plier were placed under the occlusal and gingival bracket tie-wings applying a peeling force for bracket removal. A visual analog scale (VAS) was used for pain assessment (23).

Overall, the results of this study implied that the use of bite wafers, applying an intrusive and stabilizing force, renders bracket removal more comfortable (15). In this manner, any shear/peel and rotational forces applied to the periodontal ligament during debracketing are counteracted. Nevertheless, the debracketing of the lower anterior teeth (central incisor, lateral incisor, and canine teeth) was reported as most painful for both groups. The authors explained this outcome by the greater debracketing force per unit surface area of the roots of the lower anterior teeth (15).

These authors recommend that reiterating the steps of bracket removal to alleviate any potential anxiety prior to this procedure is important, since the pain expected was found to be significantly greater than the actual pain experienced (15).

The author of this review would like to add that an effective communication in health care is of utmost importance. Clear communication, such as thoughtfully walking a patient through a procedure that is being performed or one that will be conducted in the future, will render patients less anxious and more optimistic. Health care is a shared endeavor, and communication is its sine qua non (24, 25).

In 2015, a clinical investigation was published with the aim to compare the level of discomfort during the removal of metal brackets with different hand instruments (16). This split-mouth study was composed of 70 female patients. The age of the patients ranged from 14 years and 3 months to 45 years and 11 months. Only canine and premolar teeth were evaluated for standardization. The discomfort of the procedure was evaluated by the VAS at the completion of debracketing.

Four different methods, i.e., hand instruments, were used. The first method was performed with the LODI. The second method was performed with a straight cutter (SC) plier, i.e., a ligature cutter plier. The SC was used to apply pressure to the mesial and distal sides of the bracket base, i.e., the blades of the SC were placed at the adhesive interface. The third method was performed with a How plier (HP), i.e., pressing the mesial and distal wings of the bracket. The fourth method was performed with a BRP. The blades of the BRP were placed below the mesial and distal wings of the bracket for pressure application. The archwire was removed prior to debonding. The brackets were removed by one clinician.

The authors concluded that the use of the LODI caused lower levels of pain or discomfort, whereas the SC method presented the highest discomfort. The HP and the BRP methods showed similar mean discomfort values, which were located between the discomfort levels of the SC and LODI. The result reported for the LODI is in agreement with the result reported by Normando et al. (14).

Following debracketing, the adhesive remaining on the enamel was evaluated using a portable digital microscope (Vehs, Hong Kong, China). The ARI scores for the SC were noticeably less than those of the other debracketing methods (19). This indicates a higher risk for enamel injury with the SC than the other debracketing methods. Pithon et al. (16) point out that the ideal method for debracketing should cause no harm to the enamel surface, as well as no pain to the patient. This point has also been emphasized by Normando et al. (14).

Pithon et al. (16) only enrolled female patients for standardization. The wide age range of these participants is apparent.

The author of this review believes that some remarks about gender and pain perception will be useful. A meta-analysis performed by Riley et al. (26) stated that there is a general consensus of a gender difference in response to pain. Nevertheless, Riley et al. (26) underlined the ambiguity of these findings. Thus, it might be plausible to believe that gender differences in pain behavior may reflect the influence of cultural patterns, as well as cultural variations, in the verbalization of pain experience rather than differences in physiology (6).

In 2016, a clinical study aimed to evaluate the level of pain during debracketing, as well as the assessment of three pain control methods (17). A total of 63 (32 female and 31 male) patients composed this study. The age of the patients ranged from 13 to 21 years. Three groups were formed according to the pain control method. These groups were the finger pressure (FP) group, elastomeric wafer (EW) group, and stress relief (SR) group. The FP and EW groups were set up to evaluate the effect of intrusive forces on debracketing.

In the FP group, pressure was applied from the occlusal surface in a gingival direction with a thumb. A cotton pad was interposed between the thumb and the occlusal surface to eliminate the occlusal morphological differences. In the EW group, an elastomeric wafer fabricated from a heavy-body silicone impression material and 5–6 mm thick was used. Patients were instructed to bite firmly into this wafer during debracketing. In the SR group, the patients were instructed not to occlude, i.e., open mouth position. For SR, the patients were told that bracket removal would not cause harm or serious pain.

Debracketing was performed by the same orthodontist with the same hand instrument (Direct Bond Metal Bracket Remover, 001-346E; American Orthodontics, Sheboygan, WI, USA) for all groups. The dual chisel tips of these pliers were wedged between the bracket base and the tooth, i.e., the adhesive interface. The pliers were applied occlusal-gingivally. The archwire was left in situ during debracketing. The patients were asked to record their VAS scores after each metal bracket was removed (23).

Furthermore, this study employed the Pain Catastrophizing Scale (PCS) to assess the relationship of the participants' personal traits and the actual pain experience during bracket removal (27). The tendency to catastrophize influences pain perception by heightening the emotional responses to pain, i.e., the individual experi-

ences pain as more intense (28). The PCS was completed 1 week after the debonding procedure during routine retainer control.

As expected, pain catastrophizers reported higher pain levels (higher VAS scores) during bracket removal. Higher VAS scores were also obtained for female patients. For all groups, higher VAS scores were obtained for the anterior regions (central and lateral incisors) in the upper, as well as the lower, jaw. Interestingly, neither FP nor EW was superior to SR in reducing the perceived pain during debracketing.

These authors stated that the finishing archwires were present for at least 2 months (17). This is the only study presenting some information on finishing archwire duration. Unfortunately, these authors did not discuss this point (17). Might this period have caused a decrease in tooth mobility? Teeth with increased mobility demonstrate increased sensitivity and vice versa (13).

In 2019, a study evaluating the patients' pain levels using four different approaches for bracket removal was published (18). A total of 120 (84 female and 36 male) orthodontic patients composed this study. The age of the patients ranged from 12 to 18 years. These patients were enrolled into four equal groups. In Group 1, debracketing was performed with an open mouth position. In Group 2, a single dose of pain reliever (acetaminophen 500 mg tablet) was given 1 h before debracketing, which was performed with an open mouth position. In Group 3, each patient was asked to bite into a soft bite wax (Ormco, Glendora, CA, USA) during debracketing. In Group 4, the patient was asked to bite into a soft acrylic bite wafer (3M Unitek). Debracketing was performed with the same hand instrument, the Weingart plier, in all groups. The plier beaks squeezed the mesial and distal tie-wings for debracketing. Debracketing was performed by the same clinician. The archwire was in situ during the debracketing procedure. After bracket removal, the Numerical Rating Scale (NRS) was used for the assessment of pain perception (29).

The null hypothesis of this study was that the patients' pain perception of the four groups would not present a statistically significant difference (18). Interestingly, this null hypothesis was accepted.

The author of this review would like to make some final comments before proceeding to a succinct conclusion. Personally, the word "pain" (Latin: poena, a fine, a penalty) should never be mentioned prior to the debonding procedure (30). The bright side of the completion of active orthodontic treatment should be reinforced, i.e., spotlighted. Nonthreatening words, such as "discomfort," should be used for this unique and long-awaited procedure. The patients' responses are profoundly colored and molded by their expectations (24, 25, 31).

The scales used in the aforementioned studies all employ the word "pain." The use of the word "pain" by the orthodontist may inadvertently evoke the phenomenon of pain (13-18). Orthodontists might have to devise a "Debracketing Discomfort Scale" due to the sui generis nature of this procedure.

## CONCLUSION

- An assessment of the published literature demonstrates a very poor documentation of the level of discomfort experienced during bracket removal. Thus, further investigation in this area is obligatory.
- Ceramic bracket removal with debracketing instruments specifically designed for their bracket brand should be investigated (32).

**Peer-review:** Externally peer-reviewed.

**Conflict of Interest:** The author has no conflict of interest to declare.

**Financial Disclosure:** The author declared that this study has received no financial support.

## REFERENCES

1. International Association for the Study of Pain. Pain terms: a list with definitions and notes on usage. *Pain* 1979; 6: 249-52.
2. Treede RD. The International Association for the Study of Pain definition of pain: as valid in 2018 as in 1979, but in need of regularly updated footnotes. *Pain Rep* 2018; 3: e643. [\[CrossRef\]](#)
3. Bergius M, Kiliaridis S, Berggren U. Pain in orthodontics. A review and discussion of the literature. *J Orofac Orthop* 2000; 61: 125-37. [\[CrossRef\]](#)
4. Krishnan V. Orthodontic pain: from causes to management - a review. *Eur J Orthod* 2007; 29: 170-9. [\[CrossRef\]](#)
5. James S. Human pain and genetics: some basics. *Br J Pain* 2013; 7: 171-8. [\[CrossRef\]](#)
6. Kiliaridis S, Bergius M. Pain and discomfort in orthodontics. Graber TM, Eliades T, Athanasiou AE, editors. *Risk management in orthodontics: experts' guide to malpractice*. Chicago: Quintessence Publishing Inc; 2004. p. 131-43.
7. Oliver RG. The effect of different methods of bracket removal on the amount of residual adhesive. *Am J Orthod Dentofacial Orthop*. 1988; 93: 196-200. [\[CrossRef\]](#)
8. Erdinç AM, Dinçer B. Perception of pain during orthodontic treatment with fixed appliances. *Eur J Orthod* 2004; 26: 79-85. [\[CrossRef\]](#)
9. Caniklioglu C, Oztürk Y. Patient discomfort: a comparison between lingual and labial fixed appliances. *Angle Orthod*. 2005; 75: 86-91.
10. Polat Ö. Pain and discomfort after orthodontic appointments. *Semin Orthod* 2007; 13: 292-300. [\[CrossRef\]](#)
11. Rahman S, Spencer RJ, Littlewood SJ, O'Dwyer L, Barber SK, Russell JS. A multicenter randomized controlled trial to compare a self-ligating bracket with a conventional bracket in a UK population: part 2: pain perception. *Angle Orthod* 2016; 86: 149-56. [\[CrossRef\]](#)
12. White DW, Julien KC, Jacob H, Campbell PM, Buschang PH. Discomfort associated with Invisalign and traditional brackets: a randomized, prospective trial. *Angle Orthod* 2017; 87: 801-8. [\[CrossRef\]](#)
13. Williams OL, Bishara SE. Patient discomfort levels at the time of debonding: a pilot study. *Am J Orthod Dentofacial Orthop* 1992; 101: 313-7. [\[CrossRef\]](#)
14. Normando TS, Calçada FS, Ursi WJ, Normando D. Patients' report of discomfort and pain during debonding of orthodontic brackets: a comparative study of two methods. *World J Orthod* 2010; 11: e29-34.
15. Mangnall LA, Dietrich T, Scholey JM. A randomized controlled trial to assess the pain associated with the debond of orthodontic fixed appliances. *J Orthod* 2013; 40: 188-96. [\[CrossRef\]](#)
16. Pithon MM, Santos Fonseca Figueiredo D, Oliveira DD, Coqueiro Rda S. What is the best method for debonding metallic brackets from the patient's perspective? *Prog Orthod* 2015; 16: 17. [\[CrossRef\]](#)
17. Bavbek NC, Tuncer BB, Tortop T, Celik B. Efficacy of different methods to reduce pain during debonding of orthodontic brackets. *Angle Orthod* 2016; 86: 917-24. [\[CrossRef\]](#)
18. Kılınc DD, Sayar G. Evaluation of pain perception during orthodontic debonding of metallic brackets with four different techniques. *J Appl Oral Sci* 2019; 27: DOI: 10.1590/1678-7757-2018-0003. [\[CrossRef\]](#)
19. Årtun J, Bergland S. Clinical trials with crystal growth conditioning as an alternative to acid-etch enamel pretreatment. *Am J Orthod*. 1984; 85: 333-40. [\[CrossRef\]](#)
20. El Tumi H, Johnson MI, Dantas PBF, Maynard MJ, Tashani OA. Age-related changes in pain sensitivity in healthy humans: a systematic review with meta-analysis. *Eur J Pain* 2017; 21: 955-64. [\[CrossRef\]](#)
21. Lautenbacher S, Peters JH, Heesen M, Scheel J, Kunz M. Age changes in pain perception: a systematic-review and meta-analysis of age effects on pain and tolerance thresholds. *Neurosci Biobehav Rev* 2017; 75: 104-13. [\[CrossRef\]](#)
22. 3M Unitek Orthodontic Products. Debracketing Instrument (REF 444-761): Instructions for Use. Monrovia, CA, USA; 2013.
23. Todd KH, Funk KG, Funk JP, Bonacci R. Clinical significance of reported changes in pain severity. *Ann Emerg Med* 1996; 27: 485-9. [\[CrossRef\]](#)
24. Ofri D. *What patients say, what doctors hear*. Boston: Beacon Press; 2017.
25. Mistiaen P, van Osch M, van Vliet L, Howick J, Bishop FL, Di Blasi Z, et al. The effect of patient-practitioner communication on pain: a systematic review. *Eur J Pain*. 2016; 20: 675-88. [\[CrossRef\]](#)
26. Riley JL 3rd, Robinson ME, Wise EA, Myers CD, Fillingim RB. Sex differences in the perception of noxious experimental stimuli: a meta-analysis. *Pain* 1998; 74: 181-7. [\[CrossRef\]](#)
27. Sullivan MJL, Bishop SR, Pivik J. The Pain Catastrophizing Scale: development and validation. *Psychol Assess* 1995; 7: 524-32. [\[CrossRef\]](#)
28. de Boer MJ, Struys MM, Versteegen GJ. Pain related catastrophizing in pain patients and people with pain in the general population. *Eur J Pain* 2012; 16: 1044-52. [\[CrossRef\]](#)
29. Hjermstad MJ, Fayers PM, Haugen DF, Caraceni A, Hanks GW, Loge JH, et al. Studies comparing numerical rating scales, verbal rating scales and visual analogue scales for assessment of pain intensity in adults: a systematic literature review. *J Pain Symptom Manage* 2011; 41: 1071-93. [\[CrossRef\]](#)
30. *Illustrated Stedman's Medical Dictionary*, 24th edition. Baltimore: Williams&Wilkins; 1982. p. 1015.
31. Minden P. The importance of words: suggesting comfort rather than pain. *Holist Nurs Pract* 2005; 19: 267-71. [\[CrossRef\]](#)
32. Available from: <https://www.intechopen.com/online-first/ceramic-brackets-revisited/>