



This article has been retracted. You may access the details of retraction via
DOI: 10.5152/TurkJOrthod.2020.80240

Case Report

Interdisciplinary Management of an Adult Bilateral Cleft Lip and Palate Patient with Excessive Incisor Display - A Case Report

Ashish Prasad , Om Prakash Kharbanda 

Department of Orthodontics and Dentofacial Deformities, All India Institute of Medical Sciences, Centre for Dental Education and Research, New Delhi, India

Cite this article as: Prasad A, Kharbanda OP. Interdisciplinary Management of an Adult Bilateral Cleft Lip and Palate Patient with Excessive Incisor Display - A Case Report. Turk J Orthod 2019; 32(3): 176-81.

176

ABSTRACT

This case report shows a successful orthodontic treatment of an operated adult bilateral cleft lip and palate subject with short upper lip and excessive incisor display. The patient underwent cleft lip repair at an early age of 2.5 years, followed by palatoplasty at the age of 21 years. She presented with malaligned teeth, inability to close the lips, excessive upper incisor display, and difficulty in speech.

She was treated with upper and lower arch alignment and intrusion of the upper incisors, followed by prosthetic replacement of the missing right lateral incisor and left lateral incisor and canine. Normal dental occlusion was achieved using orthodontic procedures, followed by prosthodontic rehabilitation that resulted in significant improvement in facial aesthetics and psychosocial benefit to the individual.

Keywords: Cleft lip and palate, orthodontic treatment, incisor intrusion

INTRODUCTION

Bilateral cleft lip and palate deformity has a wide degree of variability with regard to the severity of the cleft (incomplete vs. complete) and, most importantly, the premaxilla. The deformity is characterized by a protruding premaxilla, prolabium lacking muscle fibers with a blunted white roll, vertically long lateral lip elements widely spaced due to discontinuity of the orbicularis oris, short columella, flattened nose, and abnormally positioned alar cartilages (1).

Cephalometric studies of the bilateral cleft lip and palate showed that in complete bilateral clefts of the lip and alveolus with intact palates, the premaxilla was protrusive, but the palatal size was well within normal limits (2).

Adult patients with bilateral cleft lip and/or palate display malocclusion characterized by anterior deep bite, protruded maxilla, and a bilateral collapse of the buccal maxillary segments (3). The extrusion of upper incisors and/or short upper lip causes serious aesthetic problems.

The amount of incisor display greatly influences the facial aesthetic at rest and during smile (4). Three-quarters of upper incisors' crown height to 2 mm of gingival display is considered a normal/ideal exposure during smile (5).

The static and dynamic smile is severely compromised in bilateral cleft lip and palate patients. The maxillary incisors should be moved toward the alveolus in the vertical direction that improves their relationship to the normal lip position. In addition, the premaxilla gets repositioned during orthodontic intrusion of the maxillary incisors. A greater Morley's ratio in bilateral cleft lip and palate patients is a significant problem as the lip shrinks due to surgical scarring (6).

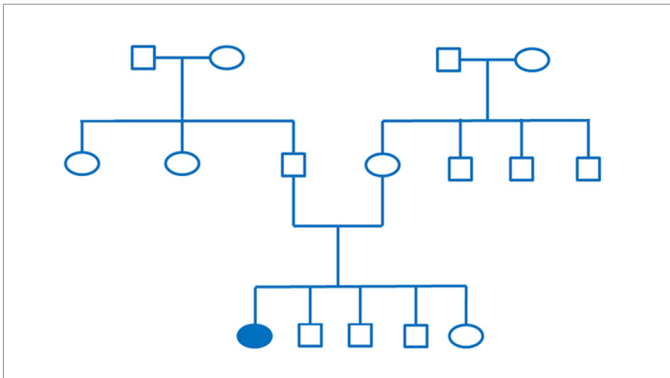


Figure 1. Pedigree chart, showing non-familial, sporadic occurrence of BCLP

An intrusion of maxillary incisors is a difficult tooth movement to perform in an adult. We report a case of a successful treatment of a 23-year-old female patient with operated bilateral cleft lip and palate with excessive incisor display.

CASE PRESENTATION

A 23-year-old female patient with operated bilateral cleft lip and palate with complaints of an inability to close the lips, irregular teeth, and difficulty in speech reported to us for improvement in her aesthetic and function. The patient was the first child of a non-consanguineous marriage with a non-relevant history of cleft deformity in her family (Figure 1). The child was delivered at term, and pregnancy was healthy except for congenital bilateral cleft lip.

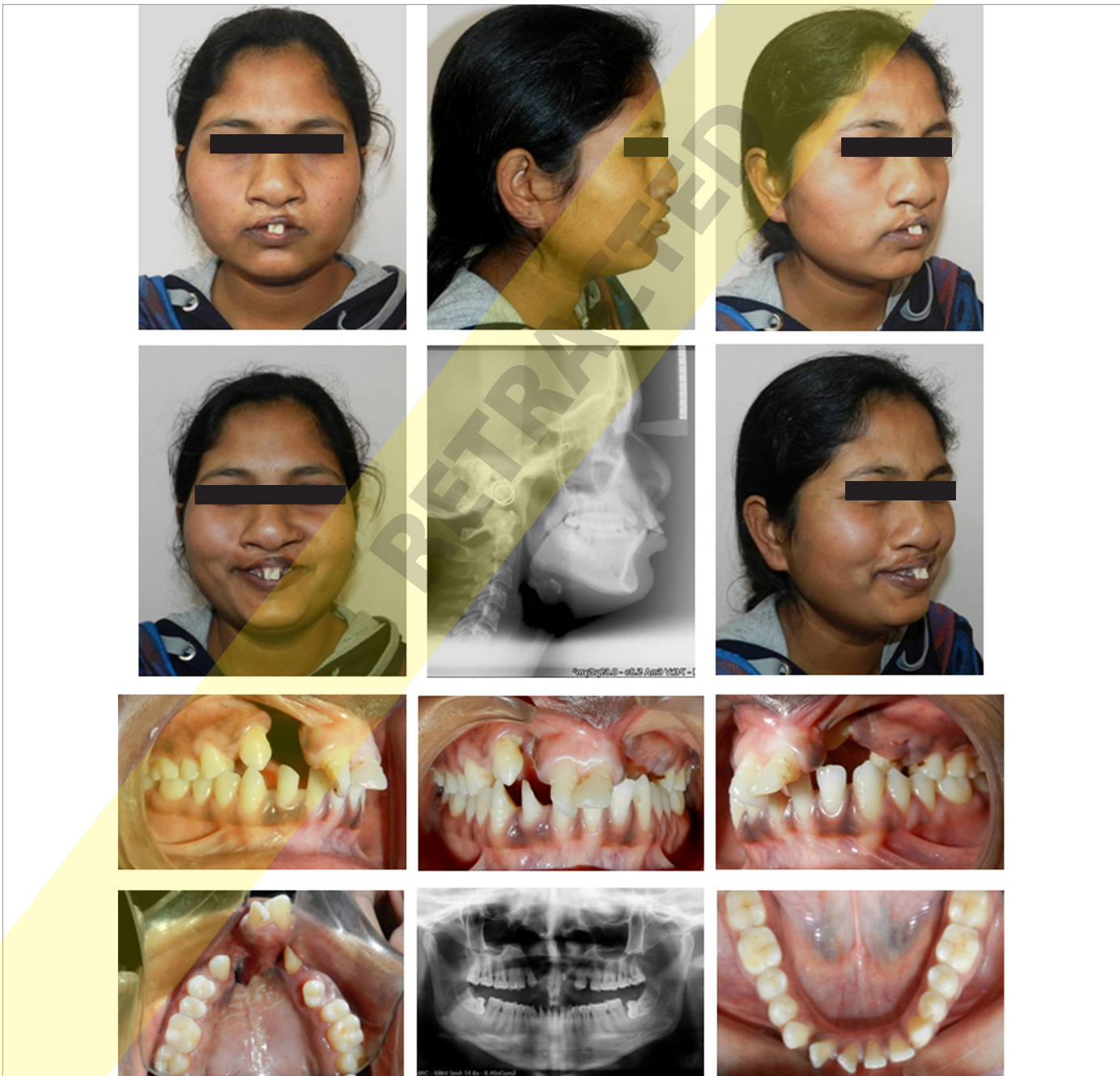

Figure 2. Pre-treatment extraoral and intraoral photographs and radiographs showing malaligned mandibular incisors and extrusion of maxillary incisors

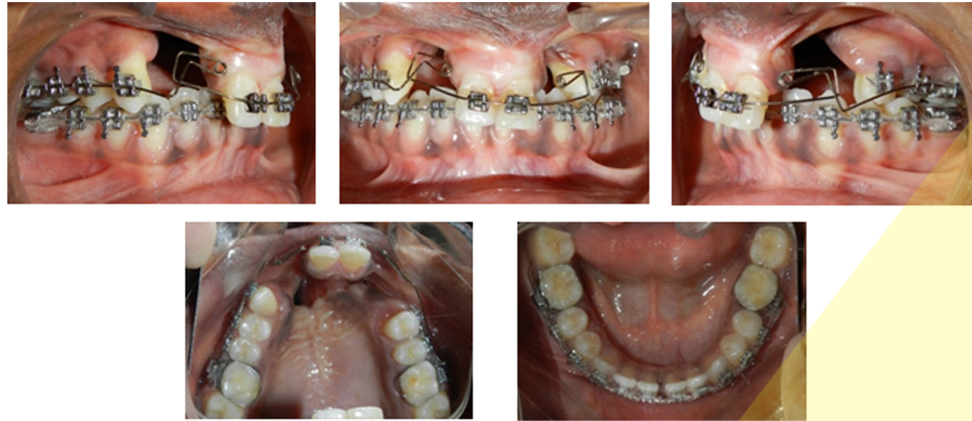

Figure 3. Mid treatment intraoral photographs showing rigid rectangular wire in the mandibular arch and intrusion cum retraction horizontal loops in the maxillary arch

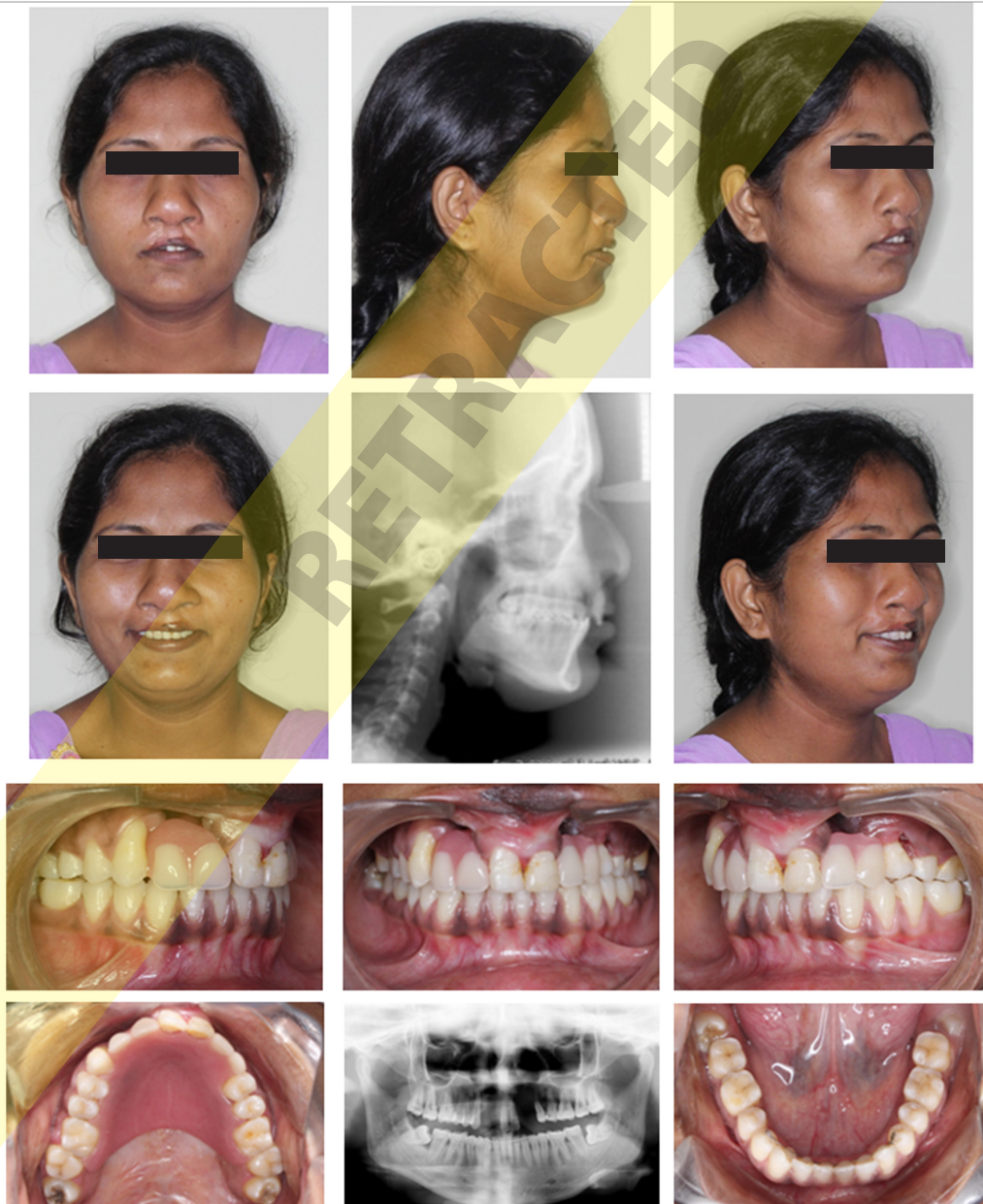

Figure 4. Post-treatment extraoral and intraoral photographs and radiographs showing removable partial denture serving as a retainer and obturator plate

The patient underwent a bilateral cleft lip repair at an early age of 2.5 years, followed by palatoplasty at the age of 21 years. The patient had a mesoprosopic face, an orthognathic profile, and incompetent lips with an asymmetrical nose and a bilateral scar extending from the vermilion border of the lip to the base of the nose with an excessive incisor display at rest and during smile.

Intraorally, the upper arch was narrow in the anterior region and asymmetric with a protruding premaxilla. Two oronasal fistulae were present distal to the right and left central incisors. Maxillary right lateral incisor and left lateral incisors and canine were missing. A supernumerary tooth was present in the left cleft area. Spacing in the lower anterior teeth was present. The maxillary central incisors and maxillary left first premolar were rotat-

ed. Maxillary right canine and left supernumerary tooth were in crossbite. The mandibular right and left third molars were horizontally impacted. An overjet of 10 mm with an overbite of 5 mm was present (Figure 2).

The patient had a nasal twang in her voice, oronasal breathing, and a typical swallowing pattern. Cephalometric analysis showed Class II skeletal base and average growth pattern with proclined upper and lower incisors.

Ideally, distraction histogenesis would be the best option to close the maxillary defects, followed by alveolar bone grafts to receive the implant prosthesis to replace the missing teeth. However, the patient declined any more surgery. Therefore, alignment of the mandibular arch and maxillary arch together

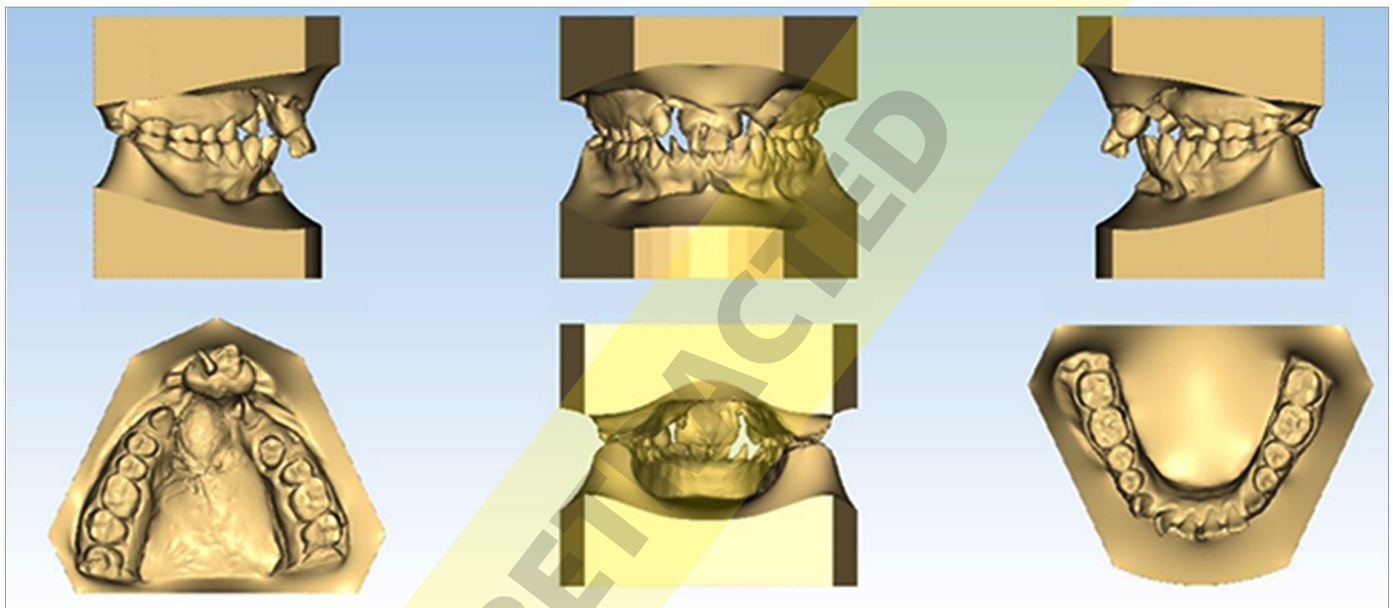


Figure 5. Pre-treatment digital models

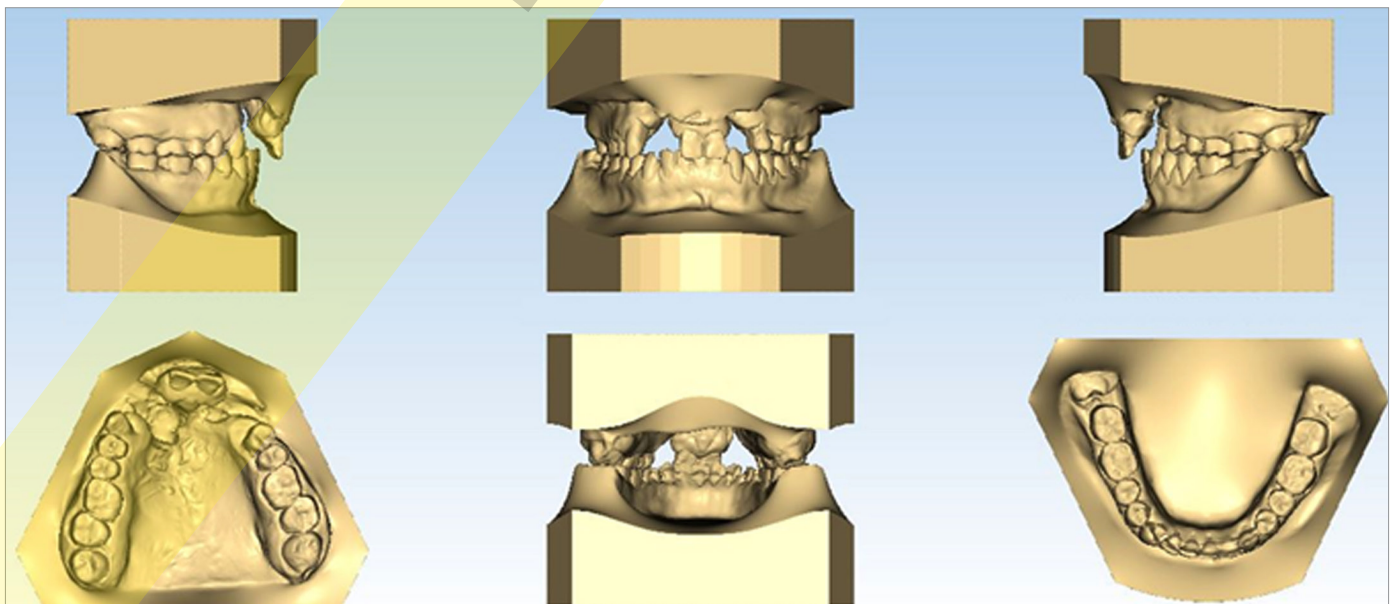


Figure 6. Post-treatment digital models

with an intrusion of maxillary incisors and replacement of the missing teeth with a removable prosthesis were performed. The treatment plan and outcome were explained in detail to the patient. Written consent was obtained from the patient. Before starting the orthodontic treatment, the supernumerary tooth with respect to the left maxillary canine region was extracted as it had a short root and poor bone support, indicating a poor prognosis. After the initial oral prophylaxis and restorative procedures were performed, banding and bonding were completed using a preadjusted Roth 0.022-inch×0.028-inch prescription appliance. A sectional 0.014-inch NiTi wire was ligated in the maxillary incisors, and sectional 0.016-inch NiTi wires were ligated in the maxillary right and left posterior regions for alignment. Following the initial alignment, intrusion cum retraction horizontal loops were ligated with respect to the maxillary central incisors using a 0.016-inch stainless steel wire. In the lower arch, initial leveling and alignment was performed using 0.016-inch NiTi wires, and the archwires were sequentially changed to higher dimensions (Figure 3).

After intrusion of the maxillary incisors, a 0.018-inch stainless steel wire was ligated in the upper arch with a step-up bend with respect to the central incisors. After debonding, a removable partial denture in relation to the maxillary right and left lateral incisors was placed, which in addition to prosthesis also served as a retainer and obturator. Retention was provided by a flexible spiral wire retainer in the mandibular arch (Figure 4, 5 and 6).

DISCUSSION

Patients with cleft lip and palate often suffer from aesthetic, morphological, and functional problems in the dentofacial region (7). A large number of patients suffer from poor self-esteem due to an unaesthetic facial appearance and unintelligible speech (8).

Management of protruded premaxilla and excessive incisor display can be a confounding problem in adult bilateral cleft lip and palate cases. Many techniques have been proposed to deal with this problem. These techniques include extraoral traction, premaxillary surgical setback, premaxillary excision, and incisor intrusion (6). Excessive incisor display may be due to the scarring, shrinkage, and shortening of the upper lip after surgery and/or due to the extrusion of upper incisors (6). The facial appearance of the patient with short upper lip improved due to the intrusion of upper front teeth.

Generally, adult patients undergoing orthodontic intrusion are more likely to have apical root resorption (9). Treatment duration, magnitude of applied force, method of force application, roots with developmental abnormalities, alveolar bone density, patient age, and sex are risk factors for root resorption (9).

The gingival recession evident in the upper right canine was present before initiation of fixed orthodontic treatment and was exaggerated by the orthodontic tooth movement and poor bone support.

180

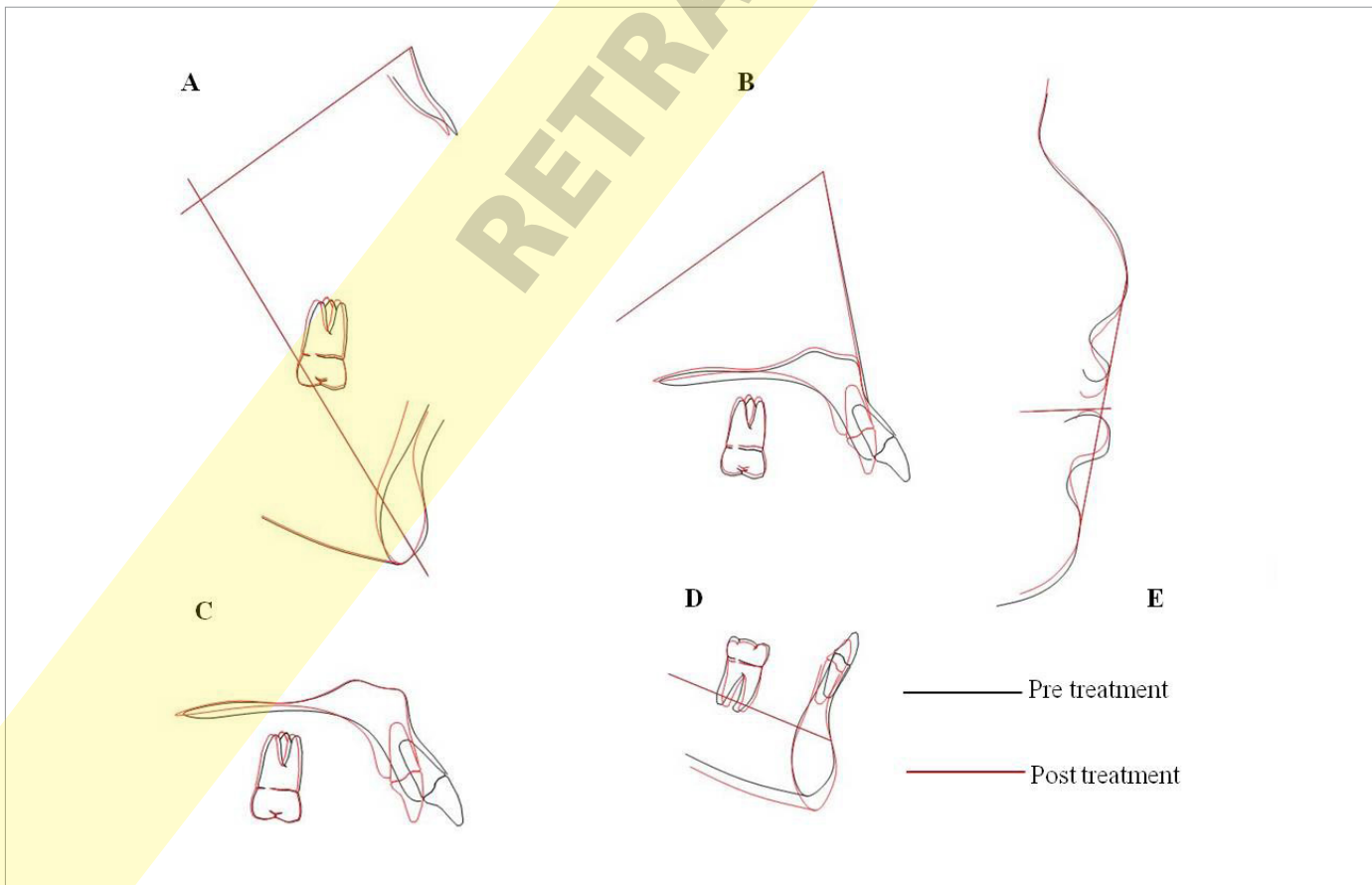


Figure 7. Rickett's five-step superimposition

Incisor intrusion was performed with mild activation of horizontal loops in a 0.016-inch stainless steel wire that provided lighter force for a longer duration to prevent root resorption in this adult patient. The orthodontic procedures and prosthetic rehabilitation resulted in a near normal dental occlusion with significant improvement in aesthetics and psychosocial benefits to the individual.

Surgical repair of the oronasal fistulas was avoided because the patient did not provide consent as she had already undergone multiple surgeries.

The removable denture poses a problem to hygiene, leading to the initiation of caries in contact areas. A slight problem with clarity of speech that usually lasts for a few days can be seen. The removable denture is also a cause of social embarrassment. In our clinical practice, we have seen that the patients very well manage with the appliance, serving as a removable partial denture, an obturator, and a retainer and also providing support to the nasal flange (Figure 7).

CONCLUSION

This case report shows a successful interdisciplinary treatment of an adult bilateral cleft lip and palate patient.

Informed Consent: Written informed consent was obtained from the patient who participated in this study.

Peer-review: Externally peer-reviewed.

Author Contributions: Concept - O.P.K., A.P.; Design - O.P.K.; Data Collection and/or Processing - A.P.; Analysis and/or Interpretation - A.P., O.P.K.; Literature Search - O.P.K., A.P.; Writing Manuscript - A.P., O.P.K.; Critical Review - O.P.K.

Conflict of Interest: The authors have no conflict of interest to declare.

Financial Disclosure: The authors declared that this study has received no financial support.

REFERENCES

1. Khosla KR, McGregor J, Kelly PK, Gruss JS. Contemporary Concepts for the Bilateral Cleft Lip and Nasal Repair. *Semin Plast Surg* 2012; 26: 156-63. [CrossRef]
2. Berkowitz S. Complete Bilateral Cleft Lip and Palate. In: Berkowitz S, editor. *Cleft Lip and Palate, Diagnosis and Management*. 2nd edition. Florida: Springer; 2006. P. 99-102. [CrossRef]
3. Aburezq H, Daskalogiannakis J, Forrest C. Management of the prominent Premaxilla in Bilateral Cleft Lip and Palate. *Cleft Palate Craniofac J* 2006; 43: 92-5. [CrossRef]
4. Sarver DM, Ackerman MB. Dynamic smile visualisation and quantification: Part 1. Evolution of the concept and dynamic records for smile capture. *Am J Orthod Dentofacial Orthop* 2003; 124: 4-12. [CrossRef]
5. Kharbanda OP. Clinical evaluation. In: Kharbanda OP, editor. *Diagnosis and Management of Malocclusion and Dentofacial Deformities*. 2nd edition. New Delhi: Elsevier India; 2013. p.159
6. Phadkule SS, Shivaprakash G, Kumar GA, Shamnur N. Customised Appliance for Intrusion and Retraction of Premaxilla in Bilateral Cleft Palate Patient. *J Indian Orthod Soc* 2014; 48: 561-5.
7. Fukunaga T, Honjo T, Sakai Y, Sasaki K, Yamamoto TT, Yamashiro T. A Case Report of Multidisciplinary Treatment of an Adult Patient with Bilateral Cleft Lip and Palate. *Cleft Palate Craniofac J* 2014; 51: 711-21. [CrossRef]
8. Ferrari Júnior FM, Ayub PV, Capelozza Filho L, Pereira Lauris JR, Garib DG. Esthetic Evaluation of the Facial Profile in Rehabilitated Adults with Complete Bilateral Cleft Lip and Palate. *J Oral and Maxillofac Surg* 2015; 73: 169.e1-6. [CrossRef]
9. Weltman B, Vig KW, Fields HW, Shanker S, Kaizar EE. Root Resorption associated with orthodontic tooth movement: A systematic review. *Am J Orthod Dentofacial Orthop* 2010; 137: 462-76. [CrossRef]