



CASE REPORT

Orthognathic Treatment of Skeletal Class III Malocclusion with Severe Facial Asymmetry

Ezgi Atik¹, Ersoy Konaş², İlken Kocadereli¹

¹Department of Orthodontics, Hacettepe University School of Dentistry, Ankara, Turkey

²Department of Plastic, Reconstructive and Aesthetic Surgery, Hacettepe University School of Medicine, Ankara, Turkey

ABSTRACT

A 26-year, 9-month-old woman had chief complaints of mandibular protrusion and facial asymmetry. Extraoral examination indicated mandibular deviation to the left side, severe facial asymmetry, and a concave profile. Because the patient had a vertical maxillary height difference and an occlusal plane cant together with maxillary retrusion, a differential downgraft and advancement surgery with Lefort I osteotomy was planned. To correct the facial asymmetry and mandibular protrusion, concurrent bilateral sagittal split osteotomy was performed. Double-jaw surgical procedures, including maxillary and mandibular movements, are effective in correcting severe facial asymmetry and skeletal Class III malocclusion.

Keywords: Facial asymmetry, orthognathic surgery, class III malocclusion

INTRODUCTION

Facial asymmetry is one of the most challenging problems to correct in orthodontics. Congenital anomalies, temporomandibular disorders, and trauma to the face are the main factors to predispose patients to facial asymmetry^{1,2}; including mandibular deviation to the right or left side, which is also usually associated with a cant of the maxillary occlusal plane.³ The severity of the skeletal asymmetry determines the treatment model. In most cases, mandibular asymmetry is usually associated with an occlusal cant and cannot be treated without double-jaw orthognathic surgery.⁴ The improvement of dentofacial deformities usually requires a combination of surgical and orthodontic treatment.⁵

This case report presents the treatment of an adult woman with mandibular asymmetry, vertical maxillary asymmetry, and severe midline deviation. The treatment included a differential maxillary downgraft and advancement surgery with Lefort I osteotomy and mandibular rotation and set-back surgery with bilateral sagittal split osteotomy.

CASE PRESENTATION

A 26-year, 9-month-old woman had chief complaints of mandibular protrusion and facial asymmetry. The facial photographs of the patient indicated severe facial asymmetry with a mandibular deviation and a concave profile (Figure 1). Transverse canting of the maxillary occlusal plane seemed to be the cause of the facial asymmetry (Figure 2).

The mandibular dental midline was deviated 10 mm toward the left side according to the maxillary dental midline, and the patient had both anterior and left posterior crossbites (Figure 1, 2). Intraoral examination showed Class III canine and molar relationships on the right side and Class II canine and Class I molar relationships on the left side. The overjet and overbite were -1.4 and 1 mm, respectively. According to Hayes-Nance analysis, there was a +4.5 mm arch length discrepancy on the maxillary arch and +8 mm arch length discrepancy on the mandibular arch.

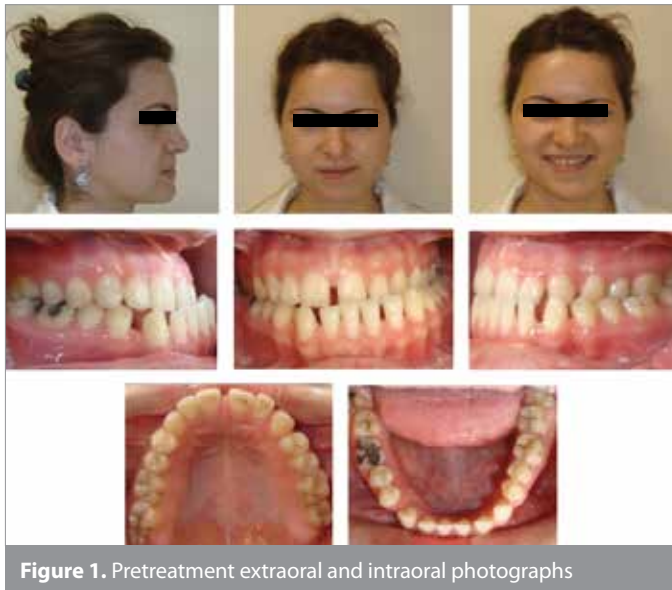

Figure 1. Pretreatment extraoral and intraoral photographs

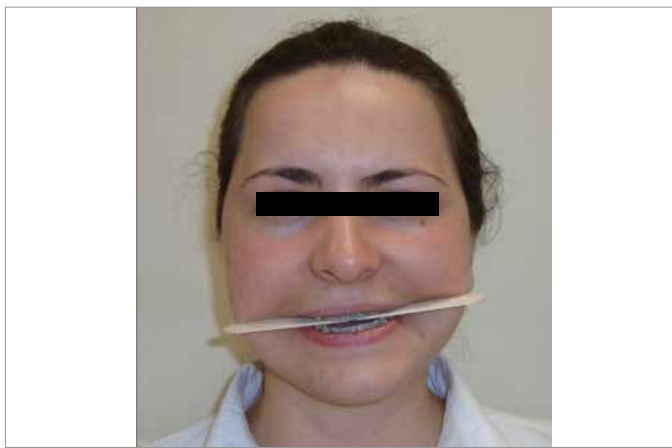

Figure 2. Pretreatment extraoral photograph showing the occlusal cant

In the posteroanterior cephalometric radiograph evaluation, the mesial border of the maxillary right central incisor was compatible, according to the facial midline. However, the mandibular dental midline was deviated 10 mm to the left side according to the facial midline, while the chin was deviated with a 10° angle. The maxillary occlusal plane inclined downward on the right side. Cephalometric analysis indicated Class III relationship (ANB, -4.8°), including maxillary retrusion (SNA, 78.9°) and mandibular protrusion (SNB, 83.7°), and a normal mandibular plane angle (FH-MP, 24.6°). The upper incisors were proclined (U1 to FH, 123.2°), whereas the lower incisors were retroclined (IMPA, 78.8°) (Table 1). The panoramic radiograph showed a dimension discrepancy between the right and left condyle. In addition, the patient was missing her maxillary left second molar because of a case of caries about 6 years ago (Figure 3).

Treatment Planning

The treatment objectives were as follows: (1) to correct the skeletal discrepancy between the maxilla and mandibula; (2) to improve the skeletal and dental midlines; (3) to achieve good facial esthetics and symmetry; (4) to obtain Class I canine and molar relationships, including a normal overjet and overbite.

Table 1. Cephalometric variables at pretreatment (T0) and posttreatment (T1)

Measurement	Pretreatment (T0)	Posttreatment (T1)
SNA°	78.9°	81.4°
SNB°	83.7°	80.4°
ANB°	-4.8°	1°
Max. Depth°	87.2°	89°
Convexity (mm)	-5.2 mm	1 mm
MP-FH°	24.6°	27.9°
GoGnSn°	32.8°	35°
Mx1-FH°	123.2°	117.8°
Mx1-NA°	36°	29.3°
IMPA°	78.8°	83.9°
Md1-NB°	15.3°	19.2°
Overjet (mm)	-1.4 mm	3.1 mm
Overbite (mm)	1 mm	2.1 mm
Low.Lip-E (mm)	-3.9 mm	-2.3 mm
Upp.Lip-E (mm)	-5.8 mm	-3.2 mm

The orthognathic surgery was unavoidable because of severe skeletal mandibular asymmetry. Therefore, we planned double-jaw surgery for the patient. Owing to the vertical maxillary height difference between the right and left side and an occlusal plane cant together with maxillary retrusion, a differential downgraft and advancement surgery with Lefort I osteotomy was planned. To correct the facial asymmetry and mandibular protrusion, concurrent bilateral sagittal split osteotomy was performed.

Treatment Progress

The patient was referred to a periodontologist for evaluation before orthodontic treatment. Since the lower incisors were retroclined, a gingival graft was performed at the lower anterior region to avoid gingival recession after orthodontic treatment. The impacted maxillary right and mandibular right and left third molars were extracted before surgery so as not to interfere with the surgical procedures. Full fixed 0.018-inch Roth prescribed appliances (Forstadent; Pforzheim, Germany) were placed on the teeth in both arches. Leveling and aligning was initiated by 0.016-inch nickel-titanium archwire and continuing up to 0.016x0.022-inch stainless steel archwire placed just before surgery. During the 0.016x0.016-inch stainless steel archwire placement, it was started to close the spaces in both arches. In the maxillary arch, the spaces were closed with moderate anchorage using rectangular archwires with closing loops. In the mandibular arch, two orthodontic miniscrews of 8 mm length and 1.4 mm dimensions (Medizintechnik GmbH; Tuttlingaen, Germany) were inserted distal to the right and left lateral incisors for the protraction of the posterior segments in order to close the spaces without retracting the anterior teeth with an indirect minimum anchorage method. After presurgical orthodontic treatment

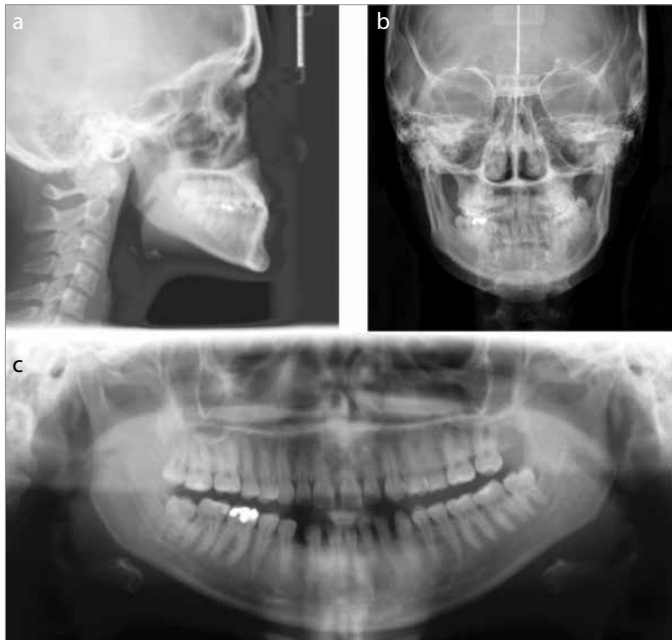


Figure 3. a-c. Pretreatment radiographs: (a) lateral cephalogram; (b) posteroanterior cephalogram; (c) panoramic radiograph

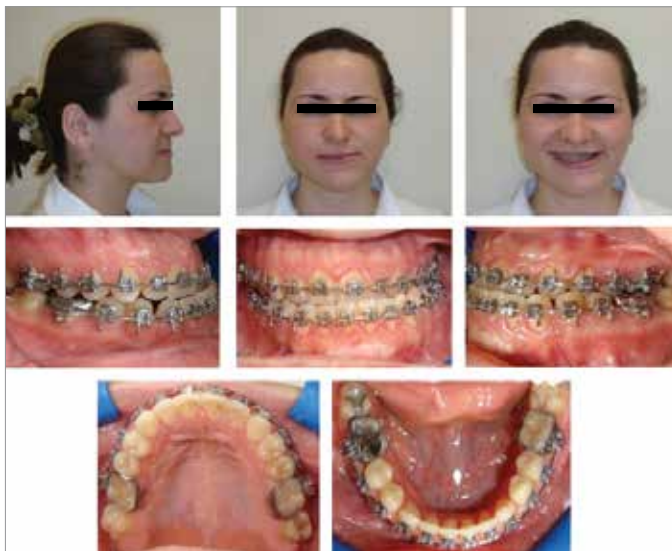

Figure 4. Preorthognathic surgery extraoral and intraoral photographs

(Figure 4) for 1 year and 2 months, orthognathic surgery involving maxillary Lefort I osteotomy and mandibular bilateral sagittal split osteotomy was performed. The maxilla was downgrafted 3 mm on the left posterior segment and advanced 2 mm. The mandibula was asymmetrically set back 6.5 mm on the right side and 3 mm on the left side with rotational movement to the right side. Orthodontic treatment was started 6 weeks post-surgery and was completed after 5 months. Occlusal settling was performed with vertical elastics. The total treatment period was 20 months. For the retention protocol, fixed retainers and Hawley appliances were applied to both the maxillary and mandibular arches for about 1 year.

Treatment Results

As a result of advancement of the maxilla, setback, and transverse rotation of the mandible, the facial esthetics were im-

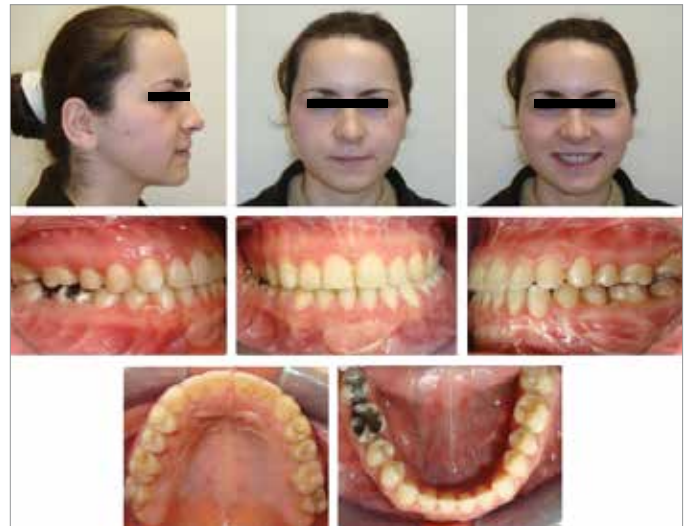

Figure 5. Posttreatment extraoral and intraoral photographs

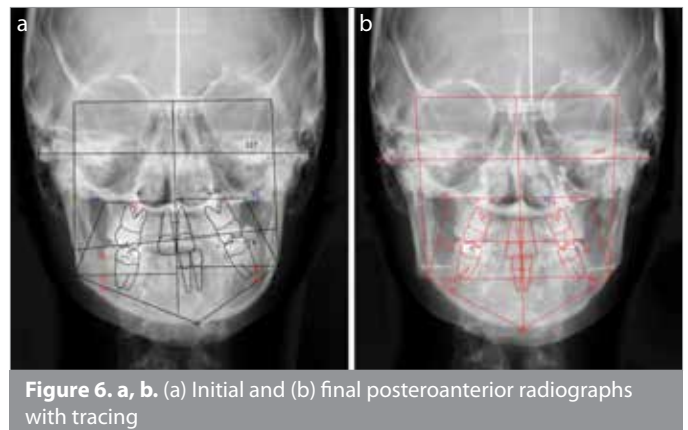


Figure 6. a, b. (a) Initial and (b) final posteroanterior radiographs with tracing

proved (Figure 5). The anterior and left posterior crossbites were corrected, and the maxillary and mandibular midline was made coincident with each other. The posttreatment posteroanterior cephalometric radiograph indicated the correction of the canted occlusal plane and improvement of the mandibular symmetry (Figure 6). Class I canine and molar relationships were obtained at the end of the treatment. The posttreatment panoramic radiograph showed no alveolar bone loss or apical root resorption (Figure 7). The posttreatment analysis revealed backward movement of the mandible and anterior displacement of the maxilla (Figure 8) (Table 1).

DISCUSSION

The aims of the treatment in Class III malocclusion are to improve the facial esthetics and correct the malocclusion.^{6,7}

Facial asymmetry is one of the most challenging problems in orthodontic treatment. Dental asymmetries without occlusal cant can be treated by orthodontic mechanics, including diagonal and midline elastics or using asymmetric tooth-extraction sequences.^{8,9} However, severe skeletal asymmetries, especially in Class III malocclusions, usually require a series of complex surgical procedures combined with orthodontic treatment.^{8,10,11}

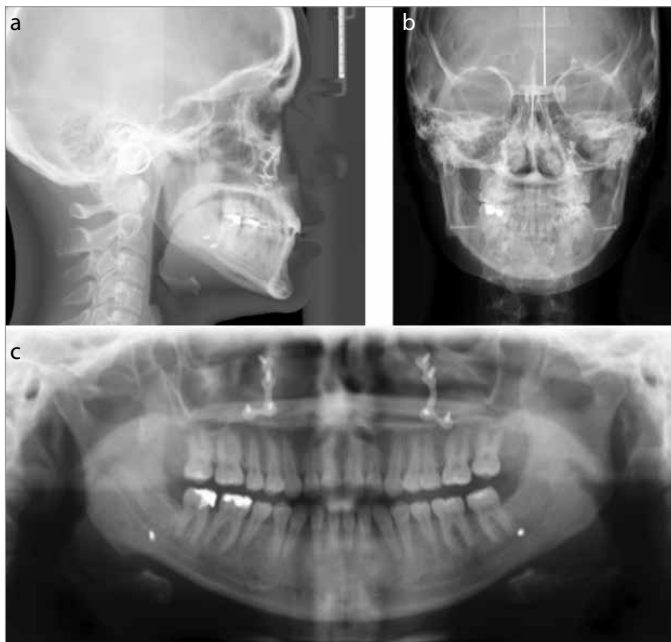


Figure 7. a-c. Posttreatment radiographs: (a) lateral cephalogram; (b) posteroanterior cephalogram; (c) panoramic radiograph

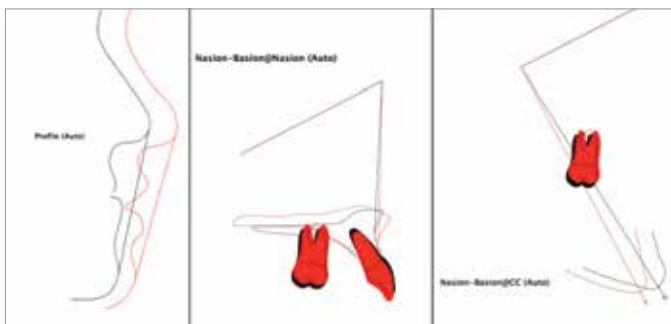


Figure 8. Cephalometric superimpositions. Black line, pretreatment; red line, posttreatment

Facial asymmetry frequencies are in the upper, middle, and lower thirds of the face, respectively, with 5%, 36%, and 74% according to the report of Severt and Proffit.¹² Improvement of the facial profile in cases with severe facial asymmetry occurs with surgery to the mandibula. Bilateral sagittal split osteotomy is the most common procedure to surgically correct mandibular deformity.¹³ However, in such cases, it is usually necessary to correct the maxillary cant. In conclusion, treatment exactly includes both Lefort I osteotomy and bilateral sagittal split ramus osteotomy, such as we carried out in our case.¹⁴

Because an association between proclination of the mandibular incisors and gingival recession has been shown by some studies^{15,16}, we referred the patient to periodontology for a free gingival graft at the lower anterior region to avoid gingival recession at the end of the treatment. Before orthognathic surgery, decompensation of the teeth and dental arches was necessary to manage the surgical phase, including sagittal movement and the asymmetric correction of the maxilla and mandible.¹⁷ Therefore, the spaces in the maxillary and mandibular arches were closed, respectively, with moderate and minimum anchorage methods. In this manner, the inclinations of the maxillary and

mandibular incisors were improved and decompensation was achieved before the orthognathic surgery. This allowed us to achieve a negative overjet to manage the manipulation of the jaws in the preoperative phase.

When double-jaw surgery is planned for an asymmetric case, the positioning of the maxilla is considered more crucial than the repositioning of the mandibula.¹⁸ In our patient, the maxillary complex was vertically asymmetric between the right and left posterior segments. Besides this, our patient showed a normal mandibular plane angle. Therefore, we decided to reposition the left posterior segment of the maxilla inferiorly by almost 3 mm in order to eliminate the vertical asymmetry. Comparison of the initial and final posteroanterior cephalometric tracings (Figure 6) showed the improvement of the occlusal cant and vertical asymmetry. Since the pretreatment cephalometric measurements (Table 1) indicated both maxillary retrusion and mandibular protrusion, the Class III malocclusion was corrected by a combination of mandibular setback plus maxillary advancement. The mandibula was set back 6.5 mm on the right side and 3 mm on the left side to achieve rotational movement while the maxilla was advanced 2 mm.

CONCLUSION

Double-jaw surgical procedures, including maxillary and mandibular movements, were effective to correct severe facial asymmetry and skeletal Class III malocclusion both in the horizontal and vertical directions, as shown in our case report.

Informed Consent: Written informed consent was obtained from patient who participated in this case.

Peer-review: Externally peer-reviewed.

Author Contributions: Concept - E.A., İ.K.; Design - İ.K.; Supervision - İ.K.; Resources - E.A., E.K.; Materials - E.A., E.K.; Data Collection and/or Processing - E.A.; Analysis and/or Interpretation - E.A.; Literature Search - E.A.; Writing Manuscript - E.A.; Critical Review - E.K., İ.K.

Conflict of Interest: No conflict of interest was declared by the authors.

Financial Disclosure: The authors declared that this study has received no financial support.

REFERENCES

1. Proffit WR. Surgical-orthodontic Treatment. In: Louis S, ed: Mo: Mosby Year Book; 1991:24-70.
2. Pirttiniemi PM. Associations of mandibular and facial asymmetries--a review. *Am J Orthod Dentofacial Orthop* 1994; 106: 191-200. [CrossRef]
3. Haraguchi S, Takada K, Yasuda Y. Facial asymmetry in subjects with skeletal Class III deformity. *Angle Orthod* 2002; 72: 28-35.
4. Cheong YW, Lo LJ. Facial asymmetry: etiology, evaluation, and management. *Chang Gung Med J* 2011; 34: 341-51.
5. Kolokitha OE. Validity of a manual soft tissue profile prediction method following mandibular setback osteotomy. *Eur J Dent* 2007; 1: 202-11.
6. Sforza C, Peretta R, Grandi G, Ferronato G, Ferrario VF. Three-dimensional facial morphometry in skeletal Class III patients. A non-invasive study of soft-tissue changes before and after orthognathic surgery. *Br J Oral Maxillofac Surg* 2007; 45: 138-144. [CrossRef]

7. Chou JI, Fong HJ, Kuang SH, Gi LY, Hwang FY, Lai YC, et al. A retrospective analysis of the stability and relapse of soft and hard tissue change after bilateral sagittal split osteotomy for mandibular setback of 64 Taiwanese patients. *J Oral Maxillofac Surg* 2005; 63: 355-61. [\[CrossRef\]](#)
8. Bishara SE, Burkey PS, Kharouf JG. Dental and facial asymmetries: a review. *Angle Orthod* 1994; 64: 89-98.
9. Joondeph DR. Mysteries of asymmetries. *Am J Orthod Dentofacial Orthop* 2000; 117: 577-9. [\[CrossRef\]](#)
10. Tehranchi A, Behnia H. Treatment of mandibular asymmetry by distraction osteogenesis and orthodontics: a report of four cases. *Angle Orthod* 2000; 70: 165-74.
11. Ferguson JW. Definitive surgical correction of the deformity resulting from hemimandibular hyperplasia. *J Craniomaxillofac Surg* 2005; 33: 150-7. [\[CrossRef\]](#)
12. Severt TR, Proffit WR. The prevalence of facial asymmetry in the dentofacial deformities population at the University of North Carolina. *Int J Adult Orthodon Orthognath Surg* 1997; 12: 171-6.
13. Dolanmaz D, Karaman AI, Gurel HG, Kalayci A, Kucukkolbasi H, Usmez S. Correction of Mandibular Retrognathia and Laterognathia by Distraction Osteogenesis: Follow up of 5 cases. *Eur J Dent* 2009; 3: 335-42.
14. Burstone CJ. Diagnosis and treatment planning of patients with asymmetries. *Semin Orthod* 1998; 4: 153-64. [\[CrossRef\]](#)
15. Hollender L, Ronnerman A, Thilander B. Root resorption, marginal bone support and clinical crown length in orthodontically treated patients. *Eur J Orthod* 1980; 2: 197-205. [\[CrossRef\]](#)
16. Dorfman HS. Mucogingival changes resulting from mandibular incisor tooth movement. *Am J Orthod* 1978; 74: 286-97. [\[CrossRef\]](#)
17. McNeil C, McIntyre GT, Laverick S. How much incisor decompensation is achieved prior to orthognathic surgery? *J Clin Exp Dent* 2014; 6: e225-9. [\[CrossRef\]](#)
18. Parbatani R, Williams AC, Ireland AJ, Sandy JR. The process of orthognathic care in an NHS region. *Ann R Coll Surg Eng* 2010; 92: 34-9. [\[CrossRef\]](#)