

Case Report

Short- and Long-Term Evaluation of a Condylar Hyperplasia: A Case Report

Sirin Nevzatođlu, DDS, PhD;^{1,*} Evin Koç, DDS;² Toros Alcan, DDS, PhD;³ and Zeki Güzel, MD⁴

ABSTRACT

Objective: This case report presents the diagnosis and short- and long-term treatment results of an orthodontically and surgically treated patient with condylar hyperplasia.

Materials and Methods: Condylar hyperplasia was diagnosed in an 18-year-old patient. In the clinical and radiologic examination, asymmetrical face, overdevelopment of the head and lengthening of the neck of the right condyle, deviation of the menton to the opposite side, temporomandibular joint pain, occlusal canting, slight open bite in the affected side, and an impacted upper right premolar were detected. Technetium-99 radioisotope scanning was made in 6-month intervals, and surgery was planned and performed. Changes were measured on the cephalograms taken at the beginning of orthodontic treatment, before and after surgery, at the end of fixed treatment, and in 4 years 6 months follow-up period.

Results: Skeletal and dental Class I relationship was established and the profile improved. Slight increase of the vertical dimension was observed in the finishing and follow-up cephalograms.

Conclusion: In order to decide the appropriate time for surgery for condylar hyperplasia patients in which osteoblastic activity continues, isotope-scanning examination is a must. Short-term results achieved with the orthodontic and surgical treatment were satisfactory and were maintained in the long term. (*Turkish J Orthod* 2013;26:103–113)

KEY WORDS: Condylar Hyperplasia, High Condylectomy, Long-term Stability, Orthognathic surgery

INTRODUCTION

Condylar hyperplasia (CH) of the mandible is a rare condition that causes overdevelopment of the condylar head and leads to facial asymmetry, deviation of the skeletal menton to the unaffected side, malocclusion, pain, and articular dysfunction. Prominent features include an enlarged mandibular condyle, outward bowing, and downward growth of the body and ramus of the mandible on the affected side, causing fullness of the face on that side and flattening of the face on the contralateral side.¹

Condylar hyperplasia was first described by Adams² in 1836 as a complication of rheumatic arthritis. The cause is unknown, but circulatory problems, endocrine disturbances, trauma, inflammation, and intrauterine influences (incorrect uterine position causing squeezing of the mandible) can be

the possible etiologic factors.^{3–5} Epidemiologically, the incidence between men and women seems similar. CH manifests itself in patients with ages ranging from 11–30 years, showing no predilection for the left or right side.^{6–8}

Differential diagnosis includes hemifacial hypertrophy (enlargement of all soft and hard tissues on one side), unilateral macrognathia (includes condyle, ramus, and ends at the midline), laterognathia, chondroma, and osteochondroma. Conditions that initiate after the age of 20 are most often related to some type of proliferative pathology. Anamnesis, previous medical and dental history, clinical and radiologic examination, and bone scintigraphy are

***Corresponding author:** Marmara Üniversitesi, Diş Hekimliği Fakültesi, Ortodonti AD, Teşvikiye mah. Büyükciftlik sok. No:6 k.3, 34365, Nişantaşı, Şişli, İstanbul, Türkiye. Tel: +90-212-231 9120 – 418 E-mail: sirin2288@hotmail.com, sirin.nevzatoglu@marmara.edu.tr

To cite this article: Nevzatođlu S, Koç E, Alcan T, Güzel Z. Short and long term evaluation of a condylar hyperplasia: a case report. *Turkish J Orthod*. 2013;26:103–113 (DOI: http://dx.doi.org/10.13076/j.tjo.2013.26.01_103)

Date Submitted: October 2012. Date Accepted: January 2013.

Copyright 2013 by Turkish Orthodontic Society

¹Assistant Professor, University of Marmara, School of Dentistry, Department of Orthodontics, Istanbul, Turkey

²PhD student, University of Marmara, School of Dentistry, Department of Orthodontics, Istanbul, Turkey

³Associate Professor, private practice, Istanbul, Turkey

⁴Professor, Plastic and Reconstructive Surgeon, private practice Istanbul, Turkey

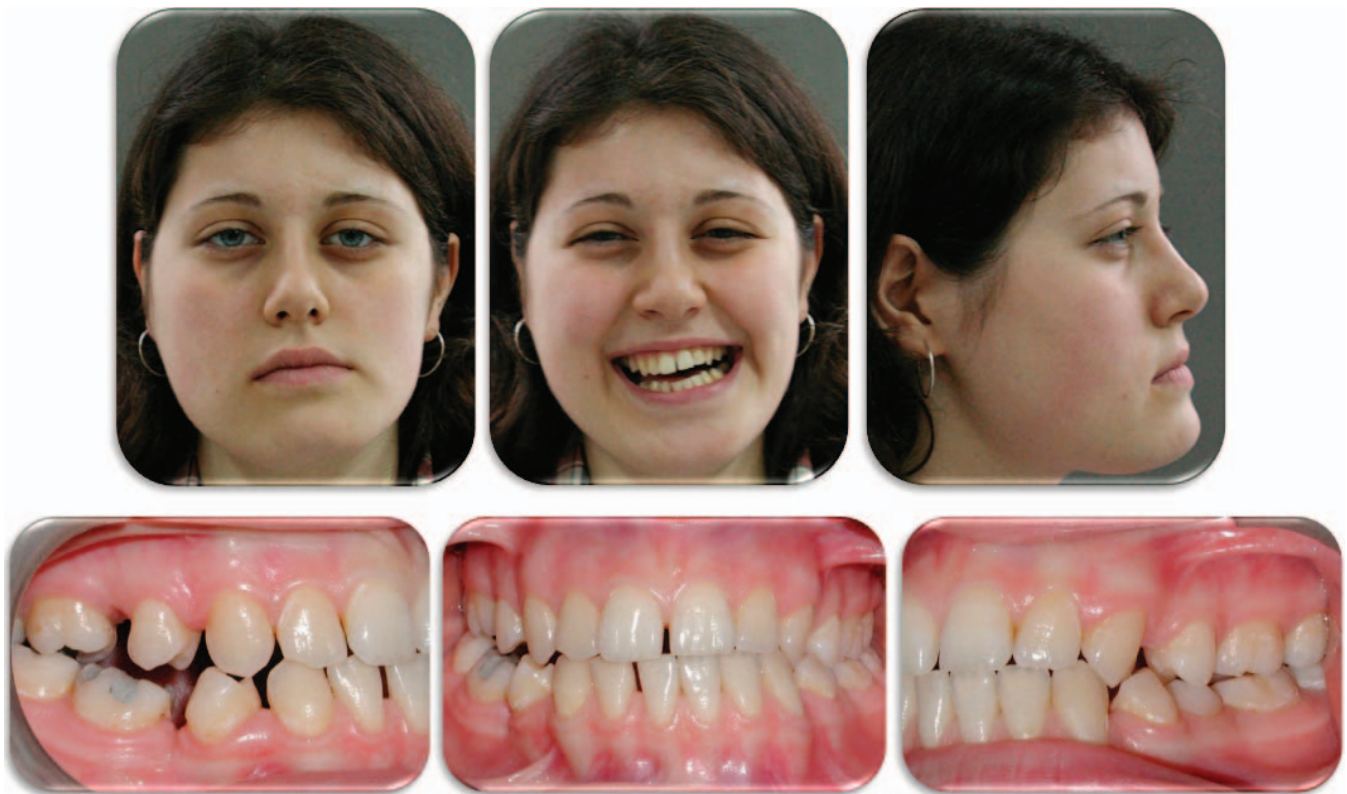

Figure 1. Initial extraoral and intraoral pictures.

important tools for correct diagnosis. The radioactive isotope in scintigraphy is technetium-99 methylene bisphosphonate. Increased radionuclide uptake by the hyperplastic condyle can be an indication of continued abnormal growth. It has been reported that a difference in uptake of 55% : 45% or more between the affected and healthy condyles can be indicative of CH because the affected condyles had a relative uptake of 55% or more.⁹

Treatment depends on the degree of severity and the status of condylar growth. Different surgical options have been proposed such as high condylectomy, orthognathic surgery, or both. There is also controversy with respect to the time of surgery, either performing the surgeries as soon as possible or waiting for cessation of growth.

In this case report, the combined surgical treatment of a patient with severe facial asymmetry secondary to CH and 4-year follow-up is presented.

Diagnosis and Etiology

An 18-year-old girl was referred to our department complaining of facial asymmetry and temporomandibular joint (TMJ) pain. She had deviation of the skeletal menton to the left side, prognathic

mandible, severe occlusal cant, and mild open bite on the right side. There was also concomitant soft tissue alteration: the right side labial commissure was lowered, with consequent inclination of the oral rim (Fig. 1). Panoramic view revealed enlarged condylar head and elongated condylar neck on the right side with downward projection of the mandibular angle and compensatory changes in the maxilla and impacted upper right premolar (Fig. 2). Upper and lower dental midlines were shifted 8 mm and 10 mm to the left respectively, whereas skeletal menton was deviated 17 mm according to PA tracings (Fig. 3). Even though the growth was completed and the radius fusion was detected on hand-wrist radiograph, the affected condyle continued to grow (Fig. 4). Scintigraphy using technetium-99 methylene bisphosphonate was advocated as a method for distinguishing the growing condyle from nongrowing one.⁷ Phosphates are metabolized by bone cells in 3 hours and are incorporated in the areas of new bone formation.¹⁰ After 3 years and 4 months of isotope examination with 6-month intervals, growth of the condyle decelerated and the patient was ready for the surgery (Fig. 4).

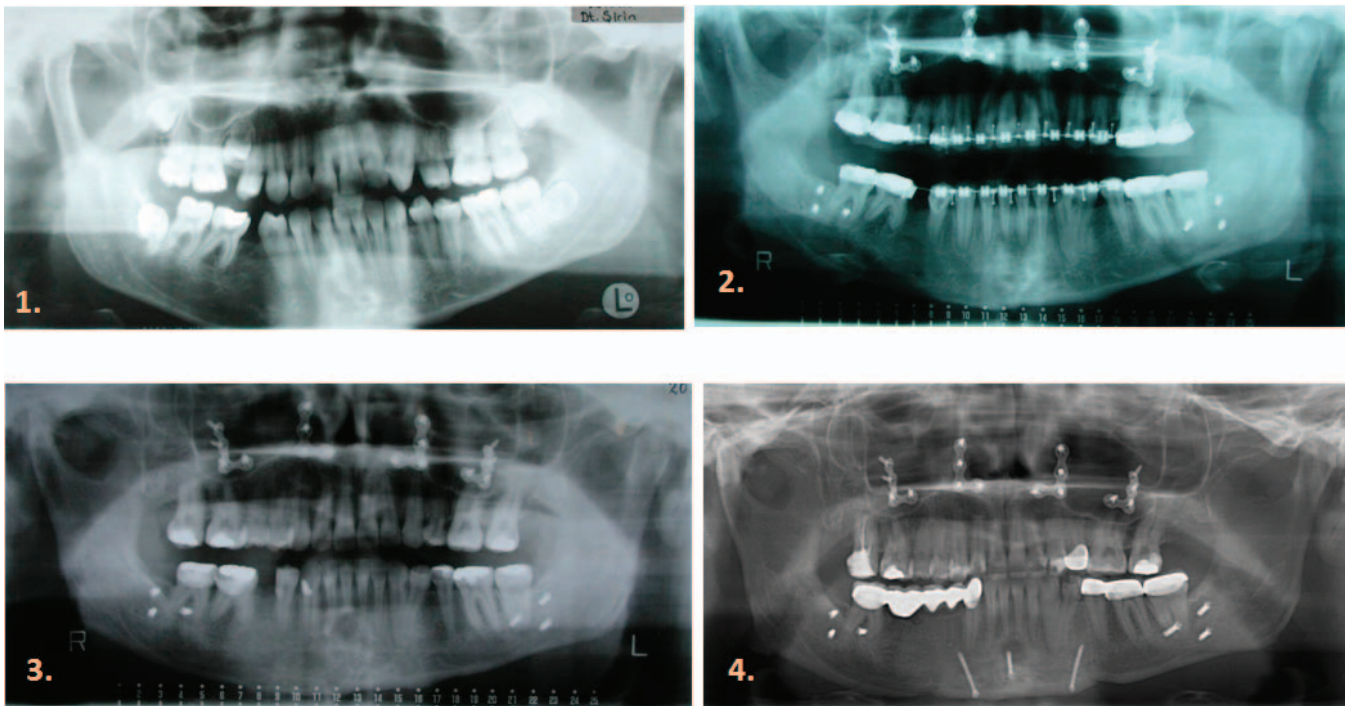


Figure 2. Initial (1), postoperation (2), final (3), and recall OPTGs (4).

Treatment Objectives

Our treatment objectives were to correct the occlusal canting, slight open bite, upper and lower midlines, overjet-overbite, asymmetry, and deviation of the menton and to erupt the impacted upper right premolar.

Treatment Alternatives

The traditional surgical methods, which have consisted primarily of orthognathic surgery for correction of the asymmetry when further growth is not anticipated, can be used as an alternative treatment plan to the combined surgery.

Treatment Progress

While waiting for the surgery, the impacted premolar on the right side was erupted and whole upper and lower teeth were aligned. The upper midline shifting was not corrected by orthodontics since it was an axial shift due to the skeletal cant (Fig. 5). The lower dental and skeletal midlines were not coinciding with each other in the beginning. The lower dental shifting was corrected with the rotation during surgery. On the other hand, the skeletal shifting was improved with a genioplasty. The casts were mounted on a semi-adjustable articulator for model surgery, and also a stereolithographic (SL) model was made to assist in the planning of the

orthognathic surgery (Fig. 6). The surgery plan included 6-mm impaction of the right side of the maxilla without any sagittal movement, bilateral sagittal split osteotomies for rotating the mandible 10 mm and setting it back, and high condylectomy. Since the height of the mandibular body was greatly increased, facial symmetry was further improved by reducing the right inferior border of corpus. The surgical splints were obtained from plaster models on articulators, and afterwards the surgical trial was done on the SL models. The reason for preparing SL models was to decide the amount of bone to be removed from the condylar head and from the inferior border of the corpus. During surgery, unilateral impaction of the right side of the maxilla was performed for elimination of severe maxillary cant as a result of compensation. High condylectomy was performed through preauricular approach and 15 mm of the condylar head was removed; the articular disc repositioning was performed without anchor placement. Great care was taken not to injure the surrounding anatomic structures.

The patient underwent clinical and radiographic examination at the following intervals: initial consultation (T1), immediately presurgical (T2), immediately postsurgical (T3), final (T4), and 4 years follow-up (T5) (Figs. 1 through 3, 5, and 7 through 9).

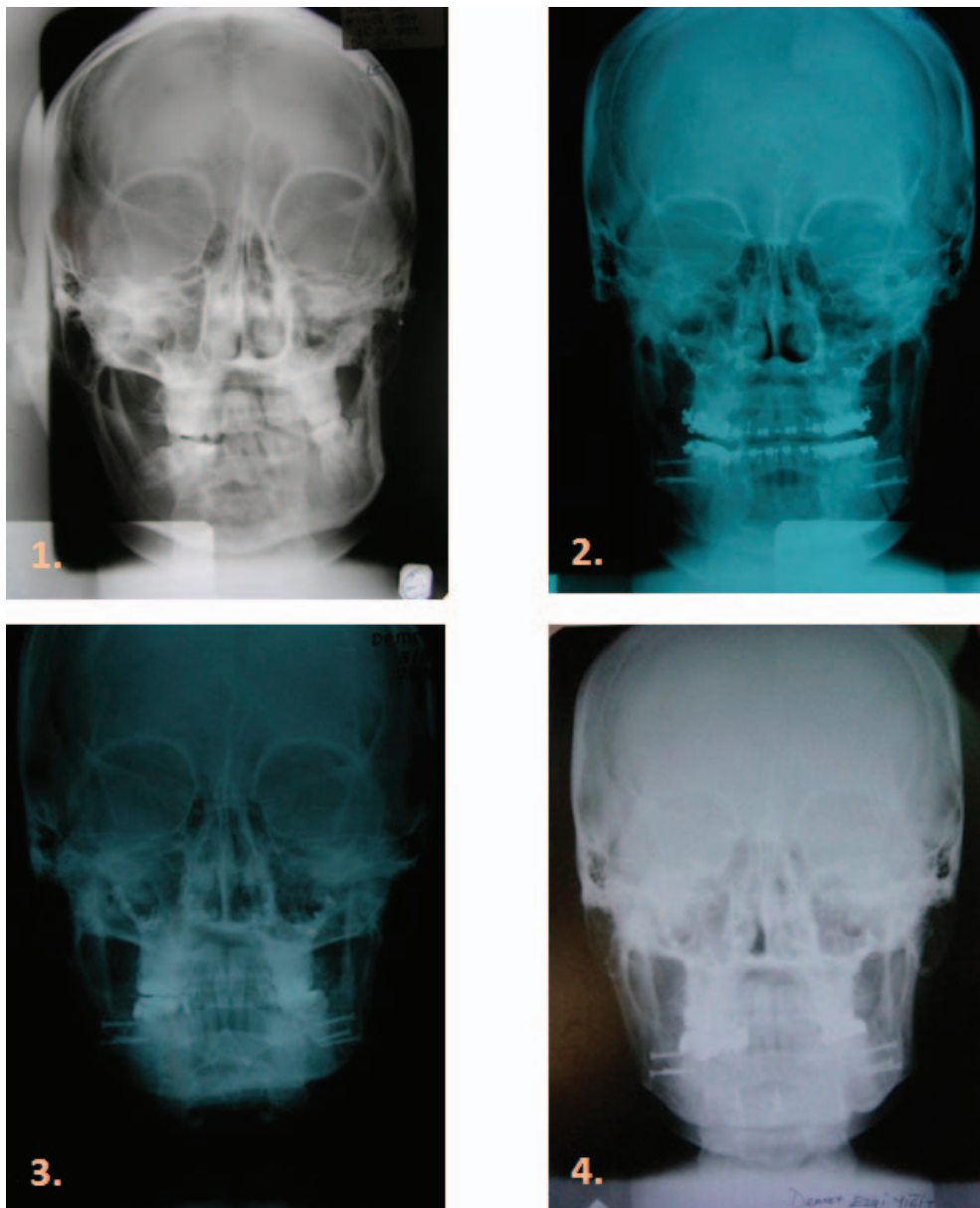


Figure 3. Initial (1), postoperation (2), final (3), and recall PA (4).

The patient had some additional surgeries in the following 2 years after the initial surgery for accomplishing the symmetry of the chin and soft tissue. The residual 7 mm of shifting of the skeletal menton was corrected by the genioplasty, and she had liposuction on the right side cheek for further proportioning of the soft tissues.

RESULTS

Lateral cephalograms at T1, T2, T3, T4, and T5 were traced and superimposed to calculate presurgical change (T2–T1), surgical change (T3–T2), and

long-term stability (T5–T4) (Fig. 10). The lateral cephalometric radiographs were assessed for (1) vertical measurements, (2) sagittal measurements, (3) dental measurements, and (4) soft tissue measurements (Table 1).

She had a decrease of 8° in the Frankfort horizontal-mandibular plane angle from T1 to T3 and no change from T3 to T5. She also had decrease of 7° in the GoMe-SN angle from T1 to T3 and 2° from T3 to T5, which proves the long-term stability in the vertical plane. The ACB/corpus length changed from T3 to T5, which can be

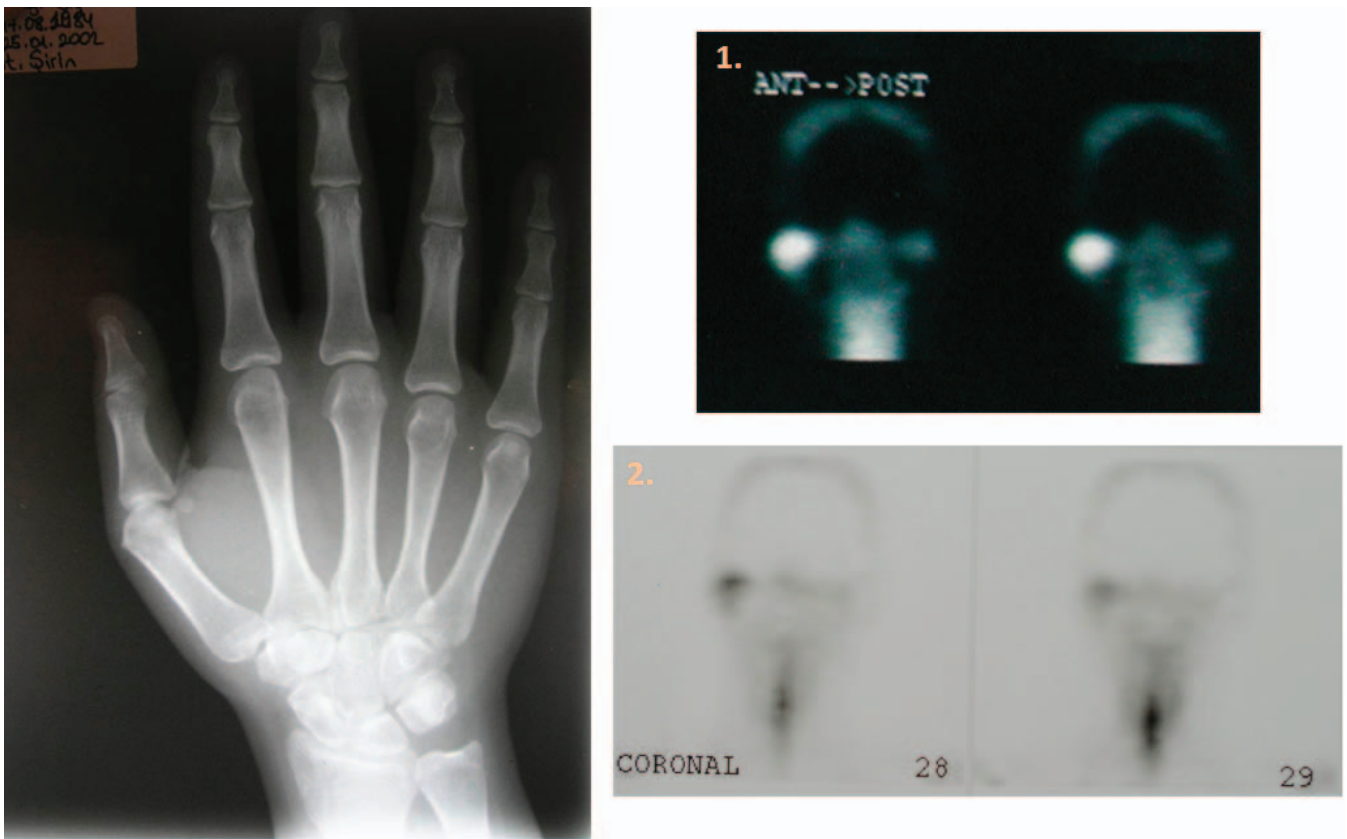

Figure 4. Initial hand and wrist x-ray with initial (1) and final scintigraphies (2).

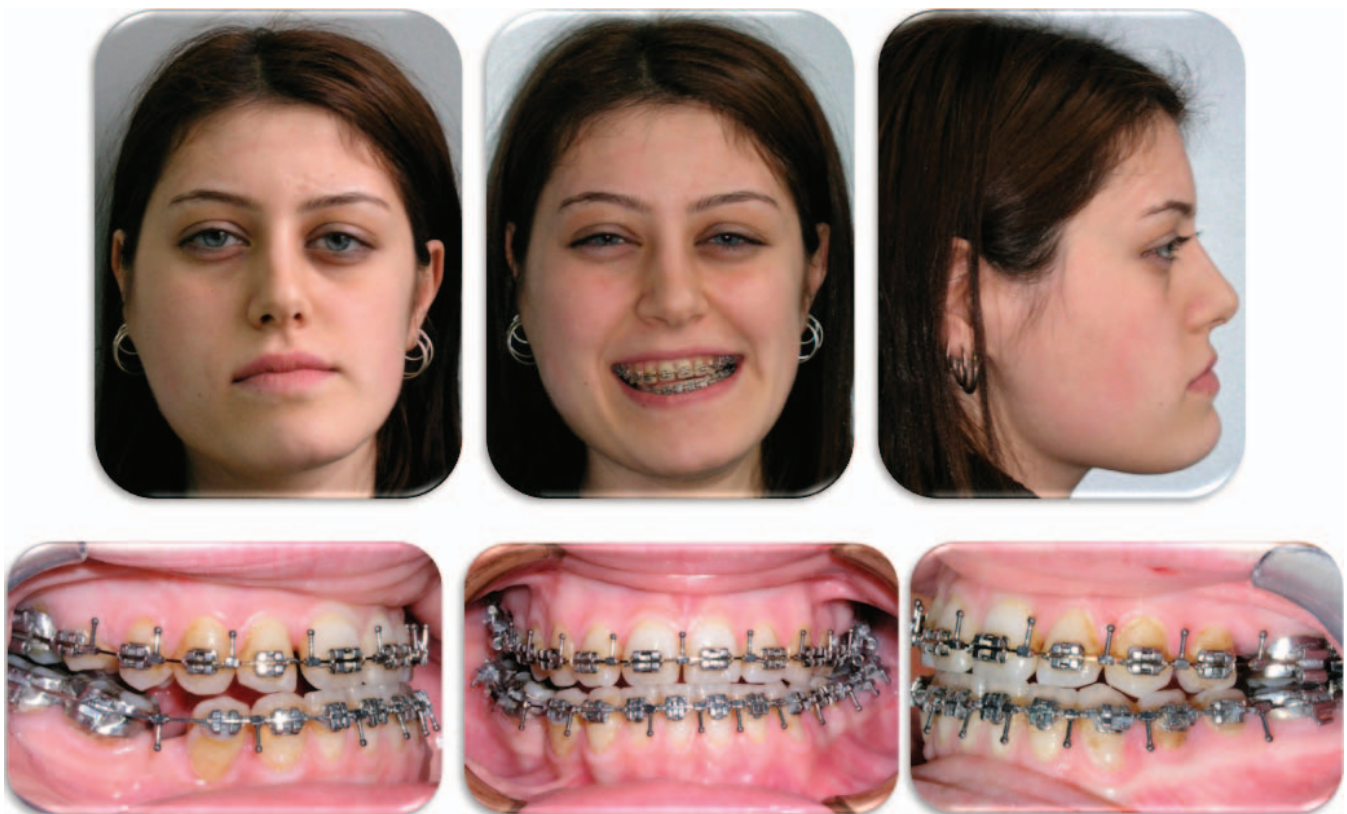

Figure 5. Presurgical extraoral and intraoral pictures.

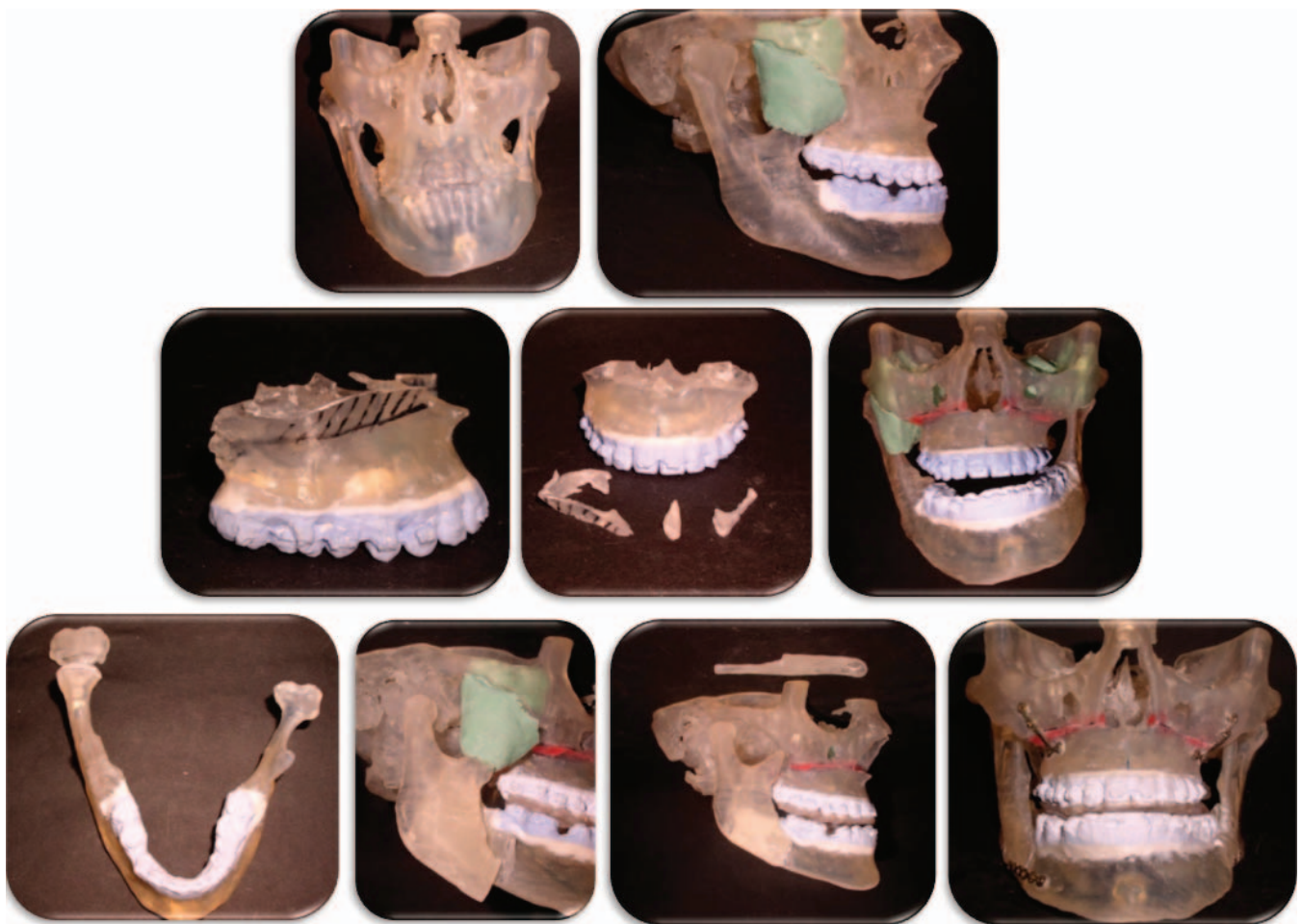

Figure 6. Stereolithographic model.

explained by change of the position of menton after the additional genioplasty. Lower incisor inclination, which was increased for decompensation before surgery, decreased in the follow-up period (Table 1).

Five years after the surgery and 4 years after the fixed treatment, there has been no recurrence, no TMJ pain, no constriction of the opening of the mouth, and the patient has a good occlusion and facial esthetics. The panoramic radiograph shows readaptation of the right condyle to the fossa (Fig. 2).

DISCUSSION

Accurate diagnosis is the utmost important part of the treatment of CH. Anamnesis, clinical and radiologic examination, and three-dimensional (3D) models and bone scintigraphy are essential for the evaluation and assistance in the surgery planning of the cases. It is difficult to predict the time when abnormal condylar growth began. To determine this, previous photographs of the patients are necessary

(Fig. 11). It also should be kept in mind that, even though scintigraphy is highly sensitive, it is nonspecific and does not always correlate with the active growth. It can have a false positive result due to the inflammations, healing after traumatic injuries, displaced articular disc, and neoplastic lesions. Hand-wrist films are also nonspecific since the mandible and especially the condyle can continue to grow beyond the normal years of growth.

The objectives of presurgical orthodontics are to ascertain the type and extent of the surgery to be performed, so that teeth can be surgically aligned and dental midlines end up matching with the facial midlines.¹¹ In our case, we paid attention to the fact that after the unilateral impaction of the right side of the maxilla, upper dental midline would be self-corrected, so we did not try to change it during the presurgical orthodontic treatment.

Traditionally, the surgical methods used have consisted primarily of orthognathic surgery for correction of the asymmetry when further growth is

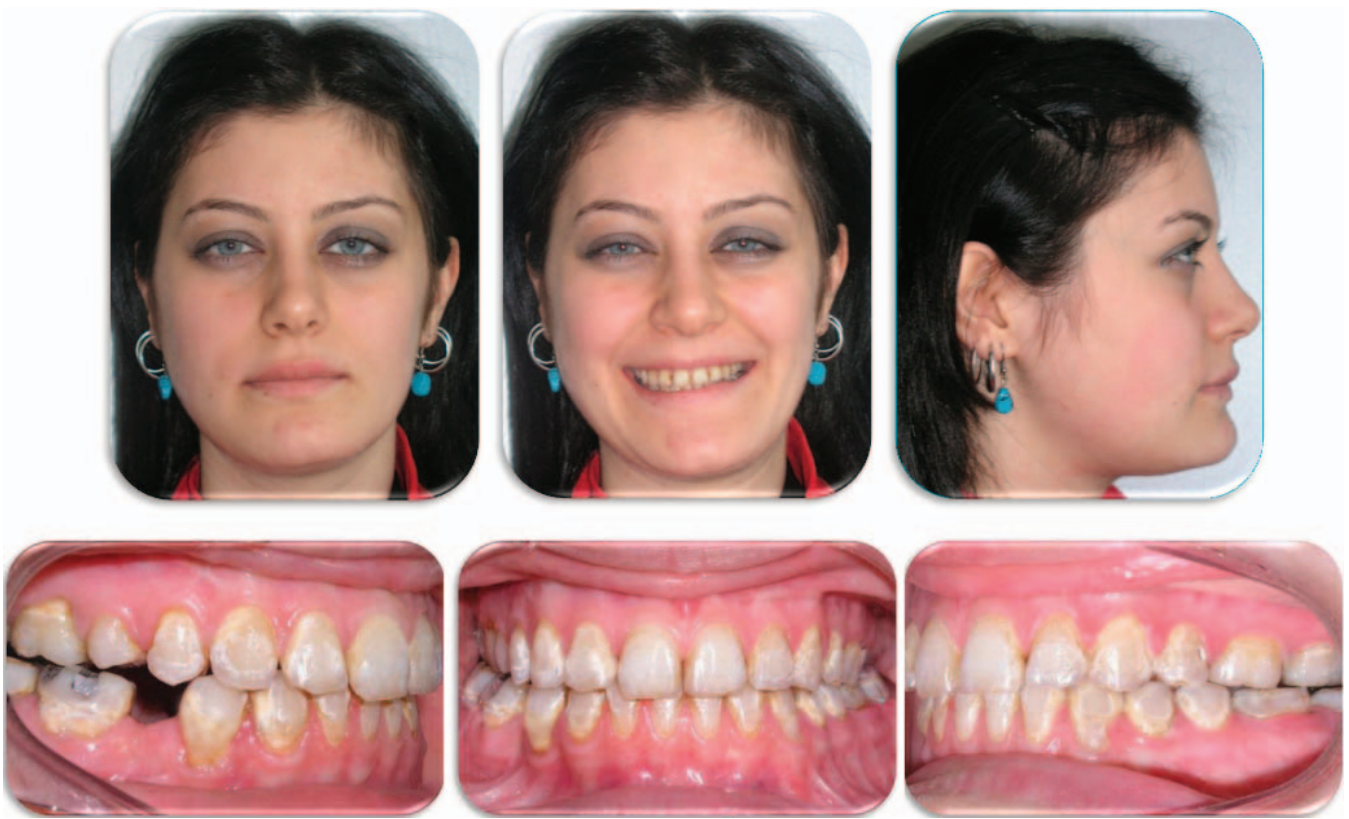

Figure 7. Final extraoral and intraoral pictures.

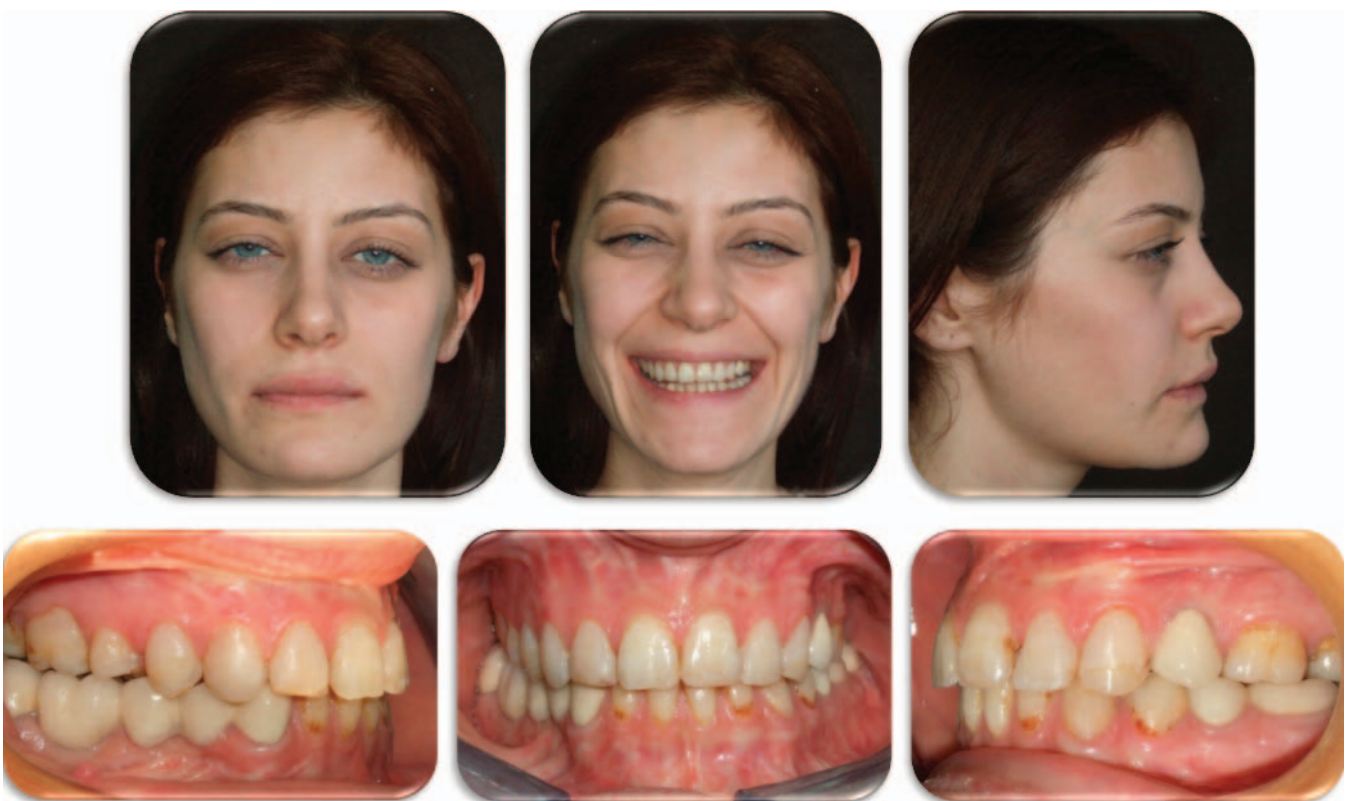

Figure 8. Recall extraoral and intraoral pictures.

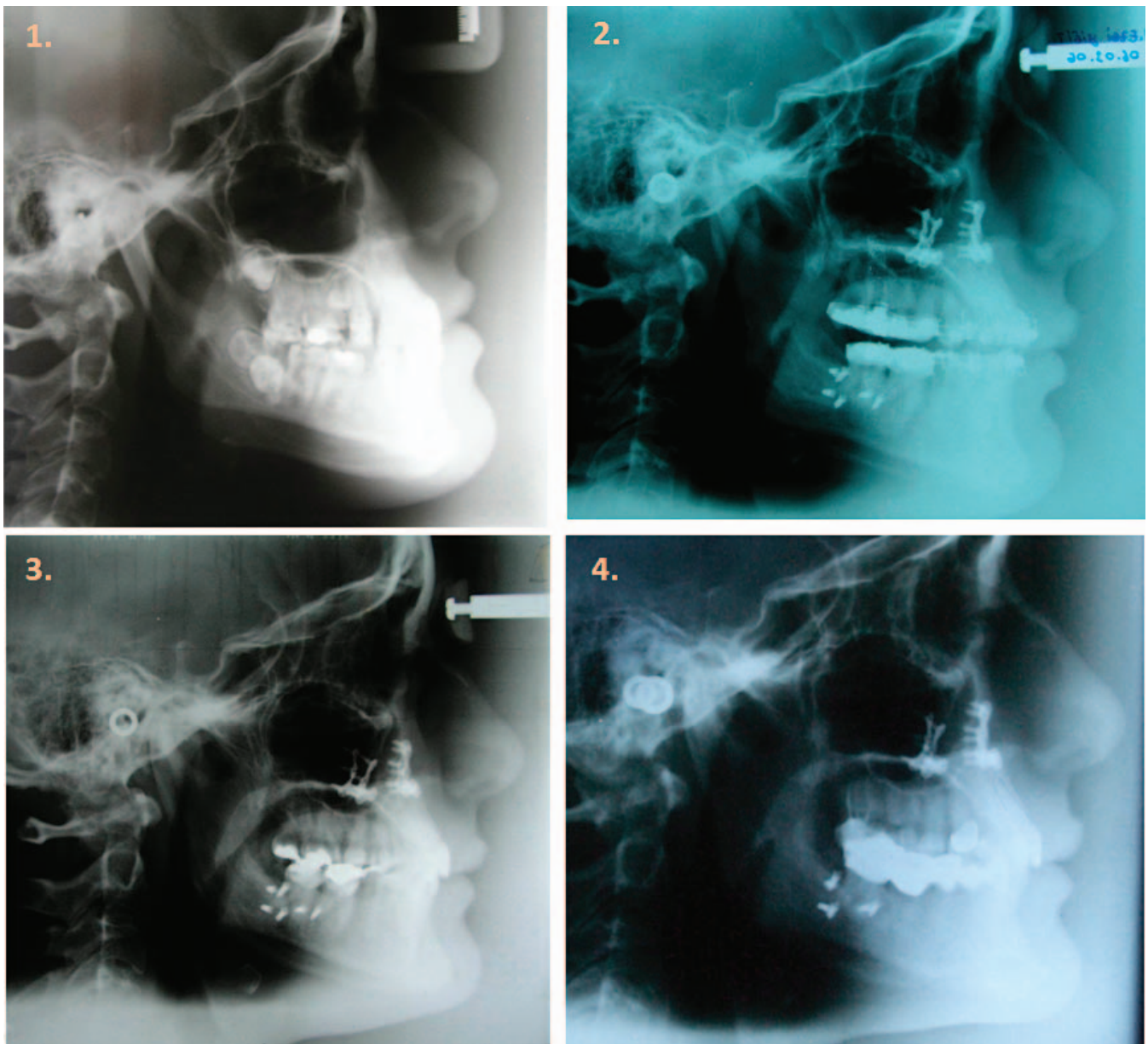


Figure 9. Initial (1), postoperation (2), final (3), and recall cephalograms (4).

not anticipated. However, it has been emphasized that performing orthognathic surgery only on patients with coexisting TMJ pathology can lead to relapse, jaw and facial deformities, pain, headaches, myofascial pain, and masticatory dysfunction.¹² Some authors perform a bimaxillary operation including resection of the involved condyle in the same procedure for actively growing patients. Wolford *et al.*¹³ proposed orthognathic surgery and simultaneous high condylectomy to correct the asymmetry. It is expected that the removal of the condyle will arrest the excessive growth of the mandible, with only normal appositional growth remaining at pogonion. High condylectomy (removal

of 4 to 5 mm of the condyle) instead of condylar shaving (removal of 2 to 3 mm of the condyle) is the preferred method since the presence of cartilage islands in the cancellous bone shows that the pathology is not limited to the cartilage surface. Therefore, not only the cartilage surface but also the subchondral bone should be removed in order to eliminate the growth center.¹⁴ For our patient, a combined surgical plan was chosen even though the rate of growth decelerated, because she had swelling and pain on the preauricular region that would make it impossible to achieve esthetics and function without removing the excess condylar mass. And later, the latent or continuous hyperplas-

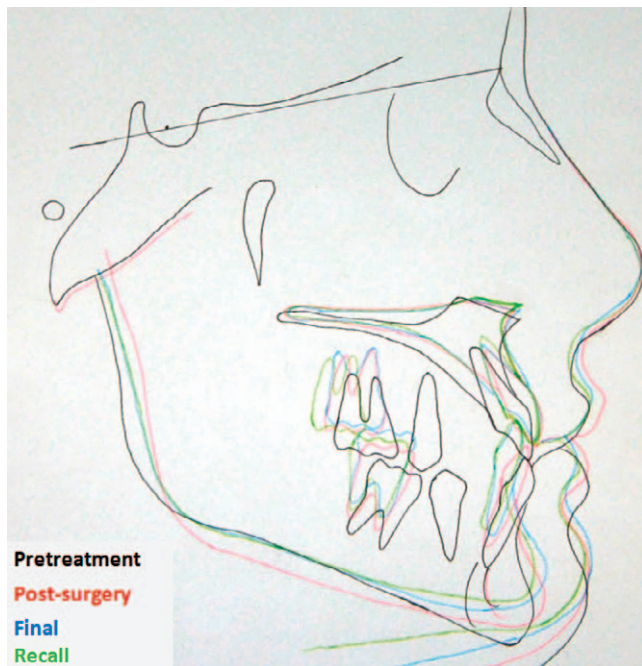


Figure 10. Superimposition showing skeletal, dental, and soft tissue changes of the patient.

tic growth of the affected condyle can manifest itself with asymmetry again.

Biomodels generated by SL have been confirmed to have a higher accuracy compared with milled

models and 3D computed tomography visual models.^{15,16} When plastic models are used, surgical simulation can be performed using actual surgical instruments. Such models are also much more convenient for explaining the surgical plan to the patient to obtain informed consent. The amount of bone to be removed can be determined by measurements obtained before surgery, and if needed an appropriate resin stent can be produced easily. The main disadvantages of stereo-modeling techniques are the manufacturing time and cost. The simulation of surgery on SL models made it easier for both orthodontist and surgeon to visualize the amount of resection and rotation. However, in our case we obtained the surgical splints from conventional plaster model surgery done on articulators and afterwards made a surgical trial using splint on the SL models.

Li *et al.*¹⁷ investigated the TMJ function of the condylar hyperplasia patients after condylectomy and detected dramatic improvement in facial asymmetry and TMJ function. Our patient also benefitted from the surgeries. She reported relief of pain in the TMJ region, improvement in the amount of mouth opening, and psychologic relaxation due to the improvement of the asymmetry.

Table 1. Short- and long-term skeletal, dental, and soft tissue changes

	Standard	Initial	Preop	Postop	Final	Recall
Skeletal Evaluation						
Vertical						
Σ	396 ± 3	395	386	387	389	387
GoMe-SN (°)	32 ± 7	34	27	27	28	25
Maxillary height (°)	60	60	60.5	58	57	56
FMA (°)	25	24	19	16	19	16
Jarabak (%)	59–62	63	70	72	69	72
ANSMe-NMe (%)	55	56	56	56	56	56
Sagittal						
SNA (°)	82±2	79.5	80	79	80	79
SNB (°)	80±2	81	82.5	81	81	80
ANB (°)	2	-1.5	-2.5	-2	-1	-1
NperA (mm)	-1	-1	-2	-1	-1	-1
Maxillary depth (°)	90	89	88	89	89	89
ACB/Corpus	x/x	78/85	78/85	78/76	78/76	78/77
Witts (mm)	-1, 0	-11	-5	-6	-3	-3
SL (mm)	51	63	67	61	63	63
Dental Evaluation						
I-SN (°)	103	107	108	106	108	105
IMPA (°)	90	88	98	95	93	90
Holdaway	1/1	2/3	4/5	2.5/5.5	2/7	2/6
Soft Tissue Profile						
Nasolabial angle (°)	90–110	74	110	110	116	105
Upper lip-E line (mm)	-4	-7	-8	-3	-7	-6



Figure 11. Previous photographs of the patient.

At the time of debonding, generalized white spot lesions and demineralization were seen. The patient refused to have any kind of treatment related with this problem (Fig. 7). As it was seen in the intraoral recall pictures, remineralization occurred spontaneously (Fig. 8).

CONCLUSION

Appropriate treatment of CH must take into account the patient's age, the rate of deformity, whether or not active growth is present, the severity of asymmetry, and if there are functional constraints or not. Afterwards, one of the surgical options among high condylectomy, orthognathic surgery alone, or combination surgeries can be chosen.

The present patient showed the establishment and maintenance of the facial balance together with the occlusal stability. The long-term results prove that the combination of high condylectomy and orthognathic surgery in the treatment of CH patients arrests the excessive growth, and the results are stable in the follow-up period.

REFERENCES

1. Motamedi MH. Treatment of condylar hyperplasia of the mandible using unilateral ramus osteotomies. *J Oral Maxillofac Surg.* 1996;54:1161–1169.
2. Adams R. The disease in the temporomandibular articulation or joint of the lower jaw. In: *A treatise on rhematic joint or chronic rhematic of all the joints.* 2nd ed. London: Churchill; 1873:271.

3. Cervelli V, Bottini DJ, Arpino A, Trimarco A, Cervelli G, Mugnaini F. Hypercondylia: problems in diagnosis and therapeutic indications. *J Craniofac Surg*. 2008;19:406–410.
4. Egyedi P. Aetiology of condylar hyperplasia. *Aust Dent J*. 1969;14:12–17.
5. Muñoz MF, Monje F, Goizueta C, Rodríguez-Campo F. Active condylar hyperplasia treated by high condylectomy: report of case. *J Oral Maxillofac Surg*. 1999;57:1455–1459.
6. Nitzan DW, Katsnelson A, Bermanis I, Brin I, Casap N. The clinical characteristics of condylar hyperplasia: experience with 61 patients. *J Oral Maxillofac Surg*. 2008;66:312–318.
7. Saridin CP, Raijmakers P, Becking AG. Quantitative analysis of planar bone scintigraphy in patients with unilateral condylar hyperplasia. *Oral Surg Oral Med Oral Pathol Oral Radiol Endod*. 2007;104:259–263.
8. Eslami B, Behnia H, Javadi H, Khiabani KS, Saffar AS. Histopathologic comparison of normal and hyperplastic condyles. *Oral Surg Oral Med Oral Pathol Oral Radiol Endod*. 2003;96:711–717.
9. Bohuslavizki KH, Brenner W, Kersch A, Fleiner B, Tinnemeyer S, et al. The value of bone scanning in the pre-operative decision-making in patients with progressive facial asymmetry. *Nucl Med Commun*. 1996;17:562–567.
10. Robinson PD, Harris K, Coghlan KC, Altman K. Bone scans and the timing of treatment for condylar hyperplasia. *Int J Oral Maxillofac Surg*. 1990;19:243–246.
11. Slootweg PJ, Müller H. Condylar hyperplasia. A clinico-pathological analysis of 22 cases. *J Maxillofac Surg*. 1986;14:209–214.
12. Yamada K, Hanada K, Fukui T, Satou Y, Ochi K, et al. Condylar bony change and self-reported parafunctional habits in prospective orthognathic surgery patients with temporomandibular disorders. *Oral Surg Oral Med Oral Pathol Oral Radiol Endod*. 2001;92:265–271.
13. Wolford LM, Mehra P, Reiche-Fischel O, Morales-Ryn CA, Garcia-Morales P. Efficacy of high condylectomy for management of condylar hyperplasia. *Am J Orthod Dentofacial Orthop*. 2002;121:136–150.
14. Villanueva-Alcojol L, Monje F, González-García R. Hyperplasia of the mandibular condyle: clinical, histopathologic, and treatment considerations in a series of 36 patients. *J Oral Maxillofac Surg*. 2011;69:447–455.
15. Lill W, Solar P, Ulm C, Watzek G, Blahout R, Matejka M. Reproducibility of three-dimensional CT-assisted model production in the maxillofacial area. *Br J Oral Maxillofac Surg*. 1992;30:233–236.
16. Klein HM, Schneider W, Alzen G, Voy ED, Günter RW. Pediatric craniofacial surgery: comparison of milling and stereolithography 3D model manufacturing. *Pediatr Radiol*. 1992;22:458–460.
17. Li J, Long X, Yang XW, Li XD, Cheng Y, Deng MH. Evaluation of temporomandibular joint function after condylectomy for condylar hyperplasia [in Chinese]. *Zhonghua Zheng Xing Wai Ke Za Zhi*. 2006;22:175–179.