

# The Surgical Predictability of Maxillary Advancement and Impaction in Le Fort I Osteotomy

Sıdıka Sinem Soydan, DDS, PhD;<sup>1</sup> Çağla Şar, DDS, PhD;<sup>2,\*</sup> Ayça Arman-Özçırpıcı, DDS, PhD;<sup>3</sup> and Sina Uçkan, DDS, PhD<sup>4</sup>

## ABSTRACT

**Objective:** The aim of this study was to evaluate and compare the amount of preoperatively planned surgical movement of the maxilla and postoperatively obtained maxillary repositioning.

**Materials and Method:** Thirty-one patients (16 female and 15 male) were included in this study. Fifteen combined maxillary advancement and impaction, 5 isolated maxillary impaction, and 11 isolated maxillary advancement surgeries were performed by the same surgical team. The 31 patients were divided into 2 groups: group 1 (GoGnSN $\leq$ 38°) and group 2 (GoGnSN $>$ 38°). Various measurements from the horizontal and vertical reference lines were used to compare the predicted maxillary movement and the postoperatively obtained maxillary position. All variables were evaluated by Student's 2-tailed paired *t* tests.

**Results:** There were statistically significant differences between the preoperatively planned and surgically obtained impaction movements of all evaluated landmarks, but no significant difference was seen between the planned and obtained advancement movement. For the differences between the planned and acquired maxillary advancement movements, 51% were within 2 mm of prediction. For the differences between the planned and the acquired maxillary anterior impaction movements, 51% were within 1 mm of the prediction. The difference was 35% for the impaction of posterior maxilla.

**Conclusion:** The predictability of vertical movement of the maxilla via Le Fort I osteotomy was lower than that for sagittal movement. The difference between planned surgical movement and actual surgical outcome should be taken into consideration during treatment planning. (*Turkish J Orthod* 2013;26:1–6)

**Key Words:** Cephalometric Prediction, Maxillary Advancement, Maxillary Impaction, Orthognathic Surgery

## INTRODUCTION

Le Fort I osteotomy has been performed to correct maxillary skeletal discrepancies for more than 40 years. Positioning of the maxilla with Le Fort I osteotomy can lead to a significant improvement not only for the smile and but also for incompetent lips.<sup>1</sup>

Accurate prediction of results of surgical treatment can provide surgeons and orthodontists with information regarding the amount and direction of the surgical movement of the hard tissue, which also leads to a change in the soft tissue profile. Accuracy of orthognathic surgery predictions have been discussed in the literature.<sup>2–5</sup> Pospisil<sup>4</sup> reported that

33% of inaccurate outcomes occurred when surgery deviated from the treatment plan, whereas in 17% of cases, the surgery was satisfactory but the treatment plan was not accurate. Moreover, in 50% of the surgical procedures, the final outcome was not accurate for uncertain reasons.

Maxillary osteotomies can be very complex and variable. The vertical and horizontal displacement of the maxilla determines the amount of mandibular autorotation and the need for mandibular movement. Kretschmer *et al.*<sup>6</sup> demonstrated that the most important differences between planned and achieved movements generally occur in the vertical dimension.

**\*Corresponding author:** Çağla Şar, Baskent Üniversitesi Dishekimliği Fakültesi, 11. sok. No:26, Bahçelievler-Ankara, 06490, Turkey. Tel: +903122151336 E-mail: caglasar@yahoo.com

To cite this article: Soydan SS, Şar C, Arman-Özçırpıcı A, Uçkan S. The Surgical Predictability of Maxillary Advancement and Impaction in Le Fort I Osteotomy. *Turkish J Orthod* 2013;26:1–6 (doi: [http://dx.doi.org/10.13076/j.tjo.2013.26.01\\_1](http://dx.doi.org/10.13076/j.tjo.2013.26.01_1))

Date Submitted: August 2012. Date Accepted: October 2012.

Copyright 2013 by Turkish Orthodontic Society

<sup>1</sup>Postdoctoral Fellow, Başkent University, Faculty of Dentistry, Department of Oral and Maxillofacial Surgery, Ankara, Turkey

<sup>2</sup>Assistant Professor, Başkent University, Faculty of Dentistry, Department of Orthodontics, Ankara, Turkey

<sup>3</sup>Professor, Başkent University, Faculty of Dentistry, Department of Orthodontics, Ankara, Turkey

<sup>4</sup>Professor, Başkent University, Faculty of Dentistry, Department of Oral and Maxillofacial Surgery, Ankara, Turkey

The predictability of maxillary osteotomies is mainly affected by the surgeon's ability, stable fixation of the maxilla, and the response of the soft tissue to hard tissue changes.<sup>1</sup> Different prediction ratios for sagittal and vertical maxillary movements have been documented, and the accuracy of the surgery is still controversial.<sup>7</sup> Therefore, the purpose of this study was to evaluate and compare the amount of preoperatively planned surgical movement of the maxilla and postoperatively obtained maxillary repositioning.

## MATERIALS AND METHODS

The preoperative and postoperative lateral cephalometric radiographs and the hand-generated surgical prediction tracings of 31 young adult patients (16 female and 15 male) with a mean age of 24.3 years were included in this retrospective study. The inclusion criteria were patients receiving Le Fort I osteotomy alone or combined with sagittal split ramus osteotomy or genioplasty by the same surgical team. Furthermore, good quality preoperative and 6-month postoperative lateral cephalometric radiographs formed the material of this study.

The distribution of skeletal discrepancies in the study was six Class 2 and twenty-five Class 3. 31 patients were divided into 2 groups: group 1 consisted of 15 patients who had normal or low angle ( $\text{GoGnSN} \leq 38^\circ$ ) vertical pattern and group 2 consisted of 16 patients who had high angle ( $\text{GoGnSN} > 38^\circ$ ) vertical pattern. Of the patients, 27 had undergone bimaxillary surgery and 4 had undergone isolated Le Fort I surgery. Furthermore, 15 combined maxillary advancement and impaction, 11 isolated maxillary advancement, and 5 isolated maxillary impaction surgeries were performed. The amount of anterior and posterior impaction was determined and evaluated separately.

The stone models of the patients were mounted on a semiadjustable articulator (SAM 3 articulator, Great Lakes Orthodontics, Tonawanda, NY, USA) after face-bow transfer in order to demonstrate the surgical movements of the maxilla and the mandible. The amount of surgical movement was determined with the aid of cephalometric setup. Model setup was performed subsequent to cephalometric setup, and surgical splints were prepared. The surgical prescriptions were made on the basis of prediction tracings and stone model surgery, which was performed by an orthodontist.

Intraoral reference points were constituted with a bur on the lateral wall of the maxillary bone at the canine and first molar teeth levels during the operation to determine the amount of maxillary advancement or impaction. Vertical and horizontal maxillary positioning was performed according to the surgical splint. After the maxillary repositioning and fixation, mandibular surgery was performed in bimaxillary procedures.

## Cephalometric Method

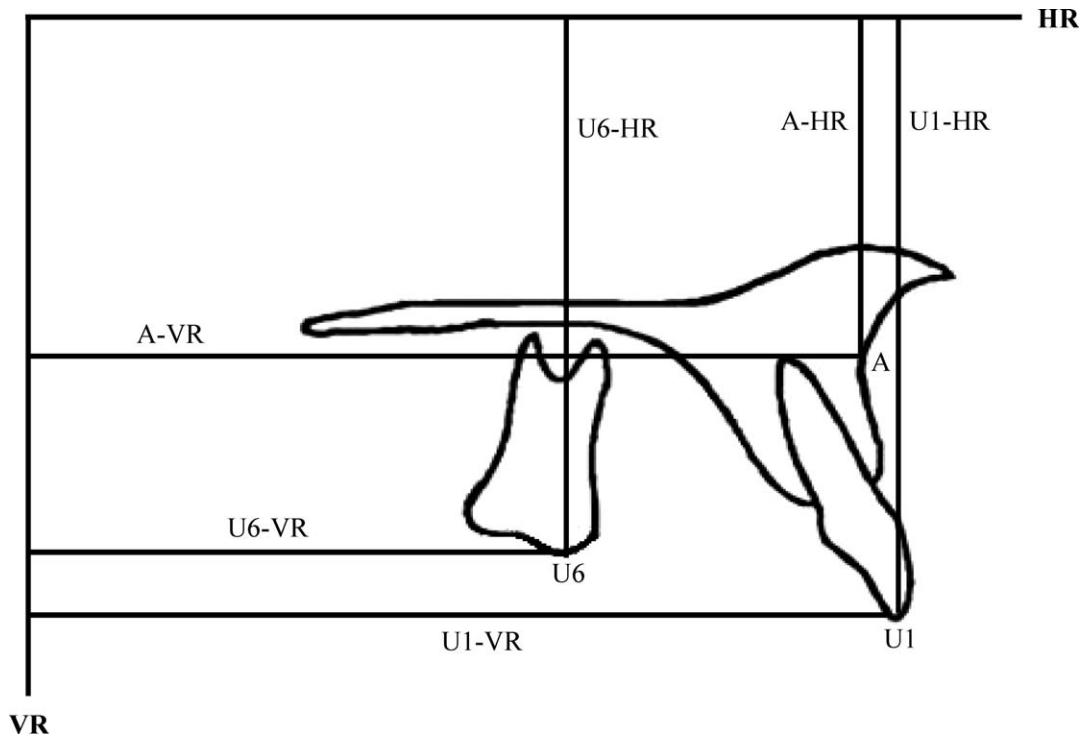
Presurgical and 6-month postsurgical radiographs, taken under same circumstances, were used to determine the position changes of the maxilla. The presurgical radiograph was traced onto orthodontic tracing paper, and maxillary landmarks—A-point (A), maxillary incisor tip (U1), and maxillary molar cusp tip (U6)—were marked to evaluate the changes in maxillary position. Structures such as the maxilla, the mandible, and the cranial base were drawn on the tracing paper and duplicated on another transparent paper. The tracings of the maxillae were superimposed and then the movable one was positioned and fastened sagittally and vertically according to the prediction.

Horizontal and vertical reference lines were constructed in order to perform the measurements from the determined landmarks. A horizontal line constructed by reducing  $7^\circ$  from the Sella-Nasion line was used as the horizontal reference plane and to assess the amount of maxillary impaction. A vertical line passing through the Sella and perpendicular to the horizontal reference plane served as the vertical reference plane and was used to assess the amount of maxillary advancement. The reference planes and measurements are shown in Figure 1.

First cephalometric measurements were performed on presurgical lateral cephalometric radiographs. Second cephalometric measurements were performed after cephalometric setup based on the predicted position of the maxillae. The final measurements were performed on 6-month postsurgical cephalometric radiographs by the same researcher (Ç.Ş.) under optimal conditions.

## Method Error

Three weeks after the first measurements, lateral cephalometric films from 10 randomly selected patients were analyzed, and the measurements were repeated by the same examiner (Ç.Ş.). Intra-class correlation coefficients ( $r$ ) were calculated on pretreatment and posttreatment cephalometric films



**Figure 1.** Horizontal and vertical reference planes and measurements used in the study.

to evaluate reliability. The intraclass correlation coefficients (*r*) calculated for each variable ranged between 0.950 and 1.000 and were considered statistically reliable.

**Statistical Method**

A discrepancy of less than 1 mm between the preoperatively planned and postoperatively achieved maxillary impaction and a discrepancy of less than 2 mm between the preoperatively planned and postoperatively obtained maxillary advancement were considered accurate. Student’s 2-tailed paired *t* test was used for statistical analysis of the differences between planned and observed horizontal and vertical movements. A 95% CI of the difference was used to interpret the level of the significance.

**RESULTS**

The overall discrepancy between the predicted and actual outcome was measured. The mean desired amount of impaction of upper incisors was 2.33 mm, whereas 0.74 mm of impaction was obtained. The mean planned impaction of upper first molars was 2.74 mm, and 1.54 mm of this amount was achieved surgically. The mean planned impaction of A-point was 2.41 mm; however, actual impaction was 1.22 mm. There were statistically significant differences between the desired and obtained maxillary impaction movements of all evaluated anatomic landmarks. The discrepancy between the planned and obtained maxillary impaction movement was more remarkable at U1

**Table 1.** Mean planned and gained maxillary surgical movements of the A-point, U1, and U6 in all subjects (n=31)<sup>a</sup>

Landmark	Mean Planned Surgical Movement (mm)	Mean Gained Surgical Movement (mm)	Significance
U1 in the HR	2.33	0.74	0.002**
U1 in the VR	4.87	4.96	0.874
U6 in the HR	2.74	1.54	0.003**
U6 in the VR	5.01	4.72	0.729
A in the HR	2.41	1.22	0.01*
A in the VR	5.22	5.14	0.888

<sup>a</sup> HR indicates horizontal reference plane; VR, vertical reference plane.

\* *p* < .05; \*\* *p* < .01.

**Table 2.** Mean planned and gained maxillary surgical movements of the A-point, U1, and U6 in group 1 (GoGnSN $\leq$ 38°) (n=15)

Landmark	Mean Planned Surgical Movement (mm)	Mean Gained Surgical Movement (mm)	Significance
U1 in the HR	0.70	-0.76	0.024*
U1 in the VR	6.23	6.06	0.847
U6 in the HR	1.13	0.33	0.125
U6 in the VR	6.33	4.96	0.184
A in the HR	0.86	0.26	0.186
A in the VR	6.43	5.73	0.301

<sup>a</sup> HR indicates horizontal reference plane; VR, vertical reference plane.

\*  $p < .05$ ; \*\*  $p < .01$ .

( $p < 0.01$ ) and U6 ( $p < 0.01$ ) than at the A-point ( $p < 0.05$ ) (Table 1).

The mean planned amount of forward displacement of upper incisors was 4.87 mm, whereas the actual amount achieved was 4.96 mm. The difference was not statistically significant. The mean preoperatively planned advancement of upper first molars was 5.01 mm, and 4.72 mm advancement was obtained surgically. The mean planned advancement of the A-point was 5.22 mm, and 5.14 mm of this amount was achieved. There were no statistically significant differences between the planned and surgically obtained positions of the maxilla (Table 2).

The predictability of maxillary surgical movement in group 1 and group 2 were also evaluated separately. Statistically significant relationship was observed only on the impaction of upper incisors in group 1 (Table 2). Moreover, differences between planned and obtained impaction movements of the A-point ( $p < 0.05$ ), U1 ( $p < 0.05$ ), and U6 ( $p < 0.01$ ) were significant in group 2 (Table 3).

According to the results of this study, 35% of posterior and 51% of anterior impaction results were within 1 mm of prediction. Furthermore, 51% of the overall maxillary advancement was within 2 mm and 29% was within 1 mm of prediction.

## DISCUSSION

Combined orthodontic and orthognathic treatment is a complicated protocol, and predicting the outcome is difficult. The present study aimed to predict the final outcome of the positional changes on the hard tissue due to the combined orthodontic and orthognathic surgical treatment. The 6-month postoperative lateral cephalometric radiographs were evaluated to determine the long-term outcome. During this period, only vertical intraoral elastics from upper canines were applied; vertical/sagittal intraoral elastics from upper first molars were not used, which indicates the reliability of the measurements from upper molars.

The basic orthodontic factors that affect the surgical outcome are errors in cephalometric technique, method of surgical splint fabrication, exact fit before surgery, or inaccurate prediction of the autorotation of the mandible.<sup>8-10</sup> Planning for orthognathic model surgery requires the surgeon, orthodontist, and laboratory technician to work together with a full understanding of the mechanical and biological principles of jaw repositioning. However, some remarkable factors need to be analyzed. The 7° difference between anatomic Frankfort horizontal plane and determined Frankfort horizontal

**Table 3.** Mean planned and gained maxillary surgical movements of the A-point, U1, and U6 in group 2 (GoGnSN $>$ 38°) (n=16)

Landmark	Mean Planned Surgical Movement (mm)	Mean Gained Surgical Movement (mm)	Significance
U1 in the HR	3.87	2.15	0.038*
U1 in the VR	3.59	3.93	0.703
U6 in the HR	4.25	2.68	0.010**
U6 in the VR	3.78	4.50	0.589
A in the HR	3.87	2.12	0.03*
A in the VR	4.09	4.59	0.591

<sup>a</sup> HR indicates horizontal reference plane; VR, vertical reference plane.

\*  $p < .05$ ; \*\*  $p < .01$ .

plane was reported during face bow transfer. Using dental cast models and articulators for planning the surgery would be inaccurate because of the inaccurate orientation of the maxillary model to the articulator.<sup>11</sup> This discrepancy is generally disregarded when planning surgical movement; however, it might affect the surgical outcome.

The prescribed displacements of the models are made relative to the axes based on the cross member of the articulator during the model setup; however, laboratory movement does not demonstrate the exact Le Fort I osteotomy procedure. This incompatibility can lead to an inaccuracy between the planned and obtained surgical movement of maxilla. Gateno *et al.*<sup>12</sup> reported that when there is a discrepancy between the actual and model setup osteotomy line, a 6 mm impaction of the maxilla would produce 1 mm of unwanted advancement.

Possible surgical factors that affect surgical outcome are anatomic obstacles, unintended malpositioning of the mandibular condyle, mistakes in measuring intraoral reference points, experience and skill of the surgeon/surgical team, and difference of the mandibular position in upright and supine positions.<sup>7</sup> Furthermore, careful planning and model setup are required for successful treatment. Model setup should be done by the team, and the surgeon and orthodontist should plan the surgery together. Three-dimensional modeling of the surgery and stereolithographic splint fabrication might diminish the difference between the model surgery and actual surgery. Although computer-assisted models can help to improve the accurate fit of the interocclusal splints, they cannot control the maxilla in the vertical dimension because of the unpredictable autorotation of the mandible.<sup>13</sup>

The technique of posterior maxillary impaction is more difficult than that for the anterior part because the anatomic limitations, and the orthodontist should be aware of this limitation during the surgical planning.<sup>7</sup> The results of our study also showed that the predictability of posterior maxillary impaction is lower than predictability for the anterior part. Stable reference points should be used to determine the amount of impaction. Some clinicians perform mandibular surgical procedures before the maxillary surgery to achieve more stable fixation, and this technique may be used in patients who need severe maxillary impaction.

The mean amount of planned or obtained maxillary advancement was higher than maxillary impaction.

Therefore, 2 mm of prediction of maxillary advancement and 1 mm of prediction of maxillary impaction were accepted as successful. The 51% of the maxillary advancement and anterior impaction and 35% of the posterior impaction were found to be accurate in this study. Jacobson and Sarver<sup>1</sup> reported that 43% of the cases were within 1 mm of prediction in maxillary advancement and impaction, and Steven and Goonewardene<sup>7</sup> found that 26% of the cases were within 1 mm of prediction in elongation, impaction, and advancement of the maxilla. Our results were compatible with these results.

Choi *et al.*<sup>14</sup> reported statistically significant differences between the predicted and actual maxillary molar vertical position. According to the results of our study, there was a statistically significant difference between the planned and obtained position of the upper first molars overall and in high-angle patients and patients treated with combined maxillary impaction and advancement. To improve the predictability of the vertical repositioning of the posterior maxilla, surgeons should use a reliable and accurate method to measure the vertical position of the maxilla.<sup>14</sup>

Extraoral reference points are accepted as more reliable than intraoral reference points for accurate vertical positioning of the maxilla.<sup>15-18</sup> Studies with extraoral bony reference points have shown better results than skin points.<sup>19</sup> However, intraoral bony reference points were preferred in this study because of the invasiveness of extraoral ones.

## CONCLUSIONS

1. Le Fort I osteotomy is an accurate procedure but has a wide range of predictability.
2. The accuracy of vertical movements was lower than the accuracy of horizontal movements.
3. Prediction of advancement and impaction movements in the anterior maxilla were more accurate than for the posterior part of the maxilla.
4. The difference between the planned surgical movements and the actual surgical outcome should be taken into consideration during treatment planning and final evaluation of the patient.

## REFERENCES

1. Jacobson R, Sarver DM. The predictability of maxillary repositioning in LeFort I orthognathic surgery. *Am J Orthod Dentofacial Orthop.* 2002;122:142-154.
2. Sharifi A, Jones R, Ayoub A, Moos K, Khambay B, McHugh

- S. How accurate is model planning for orthognathic surgery? *Int J Oral Maxillofac Surg.* 2008;37:1089–1093.
3. McCance AM, Moss JP, James DR. Le Fort I maxillary osteotomy: is it possible to accurately produce planned pre-operative movements? *Br J Oral Maxillofac Surg.* 1992;30:369–76.
  4. Pospisil OA. Reability and feasibility of prediction tracing in orthognathic surgery. *J Craniomaxillofac Surg.* 1987;15:79–83.
  5. Polido WD, Ellis E III, Sinn DP. An assessment of the predictability of maxillary repositioning. *Int J Oral Maxillofac Surg.* 1991;20:349–352.
  6. Kretschmer WB, Zoder W, Baciut G, Bacuit M, Wangerin K. Accuracy of maxillary positioning in bimaxillary surgery. *Br J Oral Maxillofac Surg.* 2009;47:446–449.
  7. Steven S, Goonewardene MS. Accuracy of a LeFort I maxillary osteotomy. *Angle Orthod.* 2005;75:964–973.
  8. Brayn DC, Hunt NP. Surgical accuracy in orthognathic surgery. *Br J Oral Maxillofac Surg.* 1993;31:343–349.
  9. Friede H, Kahnberg KE, Adell R, Ridell A. Accuracy of cephalometric prediction in orthognathic surgery. *J Oral Maxillofac Surg.* 1987;45:754–760.
  10. Olszewski R, Reychler H. Les Limites de la chirurgie orthognathique: implications theoretiques et pratiques. *Rev Stomatol Chir Maxillofac.* 2004;105:165–169.
  11. Barbenel JC, Paul PE, Khambay BS, Walker FS, Moos KF, Ayoub AF. Errors in orthognathic surgery planning: the effect of inaccurate study model orientation. *Int J Oral Maxillofac Surg.* 2013;39:1103–1108.
  12. Gateno J, Forrest KK, Camp B. A comparison of 3 methods of face-bow transfer recordings: implications for orthognathic surgery. *J Oral Maxillofac Surg.* 2001;59:635–640.
  13. Song KG, Baek SH. Comparison of accuracy of the three dimensional virtual method and the conventional manual method for model surgery and intermediate wafer fabrication. *Oral Surg Oral Med Oral Pathol Oral Radiol Endod.* 2009;107:13–21.
  14. Choi JY, Choi JP, Baek SH. Surgical accuracy of maxillary repositioning according to type of surgical movement in two-jaw surgery. *Angle Orthod.* 2009;79:306–311.
  15. Gil JN, Claus JDP, Manfro R, Lima SM Jr. Predictability of maxillary repositioning during bimaxillary surgery: accuracy of a new technique. *Int J Oral Maxillofac Surg.* 2007;36:296–300.
  16. Wangerin K. One-stage procedure for bimaxillary correction of extremely severe malocclusions. Pretreatment, planning and operation methods with functionally stable fixation of upper and lower jaws. *Dtsch Z Mund Kiefer Gesichtschir.* 1990;14:424–431.
  17. Perkins SJ, Newhouse RF, Bach DE. A modified Boley gauge for accurate measurement during maxillary osteotomies. *J Oral Maxillofac Surg.* 1992;50:1018–1019.
  18. Polido WD, Ellis E III, Sinn DP. An assessment of the predictability of maxillary repositioning. *Int J Oral Maxillofac Surg.* 1991;20:349–352.
  19. Ferguson JW, Lucky NH. Control of vertical dimension during maxillary orthognathic surgery. A clinical trial comparing internal and external fixed reference points. *J Craniomaxillofac Surg.* 1992;20:333–336.