

2023-01

Stability of palatal rugae after orthodontic/orthopaedic expansion: a scoping review

Tey, SN

<https://pearl.plymouth.ac.uk/handle/10026.1/21062>

10.2478/aoj-2023-0018

Australasian Orthodontic Journal

Sciendo

All content in PEARL is protected by copyright law. Author manuscripts are made available in accordance with publisher policies. Please cite only the published version using the details provided on the item record or document. In the absence of an open licence (e.g. Creative Commons), permissions for further reuse of content should be sought from the publisher or author.

Stability of palatal rugae after orthodontic/orthopaedic expansion: a scoping review

Sock Nee Tey,^{*†} Yen Ming Lin[‡] and Alizae Marny Fadzlin Syed Mohamed^{*}

Discipline of Orthodontics, Department of Family Oral Health, Faculty of Dentistry, University Kebangsaan Malaysia, Jalan Raja Muda Abdul Aziz, Kuala Lumpur, Malaysia^{*}

Ministry of Health, Kedah Darul Aman[†]

Peninsula Dental School, University of Plymouth, Portland Square, Plymouth, United Kingdom[‡]

Objective: The palatal rugae are connective tissue located in the anterior third of the hard palate and present asymmetrically on each side of the palatine raphe. The stability and individualistic features of the palatal rugae have been suggested as an alternative human identification method in forensic medicine. However, there are different views about the tissue's stability and reliability in individuals undergoing orthodontic expansion, as the palatal mucosa is stretched which likely alters palatal rugal morphology. The present review aims to summarise the available evidence regarding the stability of the palatal rugae after orthodontic expansion.

Method: Following the PRISMA-Scr guidelines, an extensive search was conducted using three databases (PubMed, Web of Science, and Scopus). Only studies that had control groups were included to allow for comparison.

Results: A total of six studies were identified. One report did not mention the type of expansion used, another used slow maxillary expansion (SME), and the other four used rapid maxillary expansion (RME). The results related to rugal length, morphological shape, and root mean square were inconclusive, likely because of data heterogeneity in expansion mechanics, the age of inclusion, and measurement outcomes.

Conclusion: More high-quality research is needed to substantiate the importance of palatal rugae in forensic medicine. (Aust Orthod J 2023; 39: 158 - 170. DOI: 10.2478/aoj-2023-0018)

Received for publication: February, 2023

accepted: April, 2023.

Sock Nee Tey: sockneetey@gmail.com; Yen Ming Lin: yen.lin@plymouth.ac.uk; Alizae Marny Fadzlin Syed Mohamed: alizaemarny@ukm.edu.my

Introduction

The palatal rugae, also known as *plicae palatinae transversae* or rugae palatine, are located in the anterior third of the hard palate and arranged transversely on each side of the palatine raphe. Their number, shape, length, width, prominence, and orientation vary on each side of the midline in each individual, even in identical twins.¹ The growth and development of the palatal rugae are controlled by epithelial-mesenchymal interactions, similar to the teeth.² The rugae are accepted as a stable structure because of the protection afforded by the surrounding soft and hard tissues such as lips, bones, tongue, teeth

and cheeks.³ Previously published papers theorised that, following rugae formation, they remain stable and can resist morphological changes induced by tooth extraction or orthodontic treatment.^{4,5} In addition, they are also able to withstand degenerative changes up to seven days after death.⁶

The palatal rugae have also been widely studied in a forensic context to determine individual identification as an alternative to fingerprinting.^{5,7} Different population groups have demonstrated varying patterns of palatal rugal anatomy.⁸ Therefore, the structure can be used to identify population groups in the event of mass casualties. The differences

in morphology have been attributed to the genes that control the orientation of the rugae during development.⁹ Chong et al. (2020) also claimed that similarities in the palatal rugae were present in close sibling groups, which suggested heritability traits.¹⁰

The stability of the palatal rugae has also been utilised in orthodontic treatment as a stable landmark to measure the movement of teeth. Generally, orthodontists have used lateral cephalograms to measure skeletal, dental, and soft tissue changes as well as the inclination and anteroposterior movement of teeth. However, radiographs raise concerns about radiation exposure and the difficulty in finding a stable reference plane or point to perform superimposition. This is usually attributed to the vagary of images and anatomical structures.¹¹ Therefore, Allen (1889) suggested the use of the palatal rugae as an alternative comparison method, commonly incorporating the entire rugal area for superimposition.^{12–14} Past studies have postulated that the third medial rugae are stable reference points to quantify tooth movement after orthodontic treatment that involves extraction.^{5,15–18}

However, there are conflicting results regarding the stability of the palatal rugae after orthodontic treatment involving maxillary expansion required in dental transverse discrepancy cases.^{19,20} The palatal rugae that are thin and those near the teeth tend to follow tooth movement more easily as they are stretched.²¹ If the palatal rugae are altered due to orthodontic expansion, they may no longer be used to identify individuals or as a reference landmark for orthodontic purposes. Therefore, the aim of the current review was to assess the available research regarding the stability of the palatal rugae after orthodontic expansion. It was expected that this would provide confirmation regarding the reliability of the palatal rugae for forensic identification and to investigate whether the rugae are a stable landmark for those who have received orthodontic expansion for superimposition purposes.

Materials and methods

The present review utilised the methodological framework based on the Preferred Reporting Items for Systemic Reviews and Meta-Analysis extension for scoping reviews (PRISMA-Scr) guidelines. The research question for this review was: “Do the palatal rugae remain stable after orthodontic expansion”?

The published literature until July 2022 was searched using three databases, PubMed, Web of Science, and Scopus, without language restriction. The following search terms were applied: (palatal rugae) OR (rugae) AND (palatal expansion) OR (expansion) OR (rapid palatal expansion) OR (slow palatal expansion) OR (orthodontic expansion) OR (maxillary expansion) OR (rapid maxillary expansion) OR (slow maxillary expansion). The protocol was registered in the Open Science Framework for scoping review protocol registration at the following link: <https://osf.io/8dfj3>

Criteria for study selection

The inclusion criteria for published article selection were defined according to the participants, concept, and context domains (PCC). Participants (P): Patients who had undergone orthodontic expansion. Concept (C): All types of orthodontic expansion. Context (C): Change of palatal rugae and Types of sources: All descriptive, prospective, and retrospective studies except case reports were included. In addition, only studies that had a control group were included.

Data extraction

A total of 188 articles were initially identified. After the screening of titles and abstracts by two independent reviewers (SNT and YML), 165 irrelevant articles and 13 duplicates were excluded. Disagreements between reviewers were resolved by a third reviewer (AMFSM). According to the inclusion and exclusion criteria, ten potentially eligible full-text articles were considered for screening. After assessment, four articles were excluded because they did not satisfy the inclusion criteria (no control group). A total of six articles were therefore included in this review. A summary of the screening process is shown in Figure 1.

Results

Study characteristics

After evaluating their titles, abstracts, and full text, the main characteristics of the included studies are described in Table I. The papers were grouped based on study design (sample size and age group, materials used, inclusion and exclusion criteria), patient intervention, methods of analysis, and primary outcomes regarding changes in the palatal rugae region after orthodontic treatment.

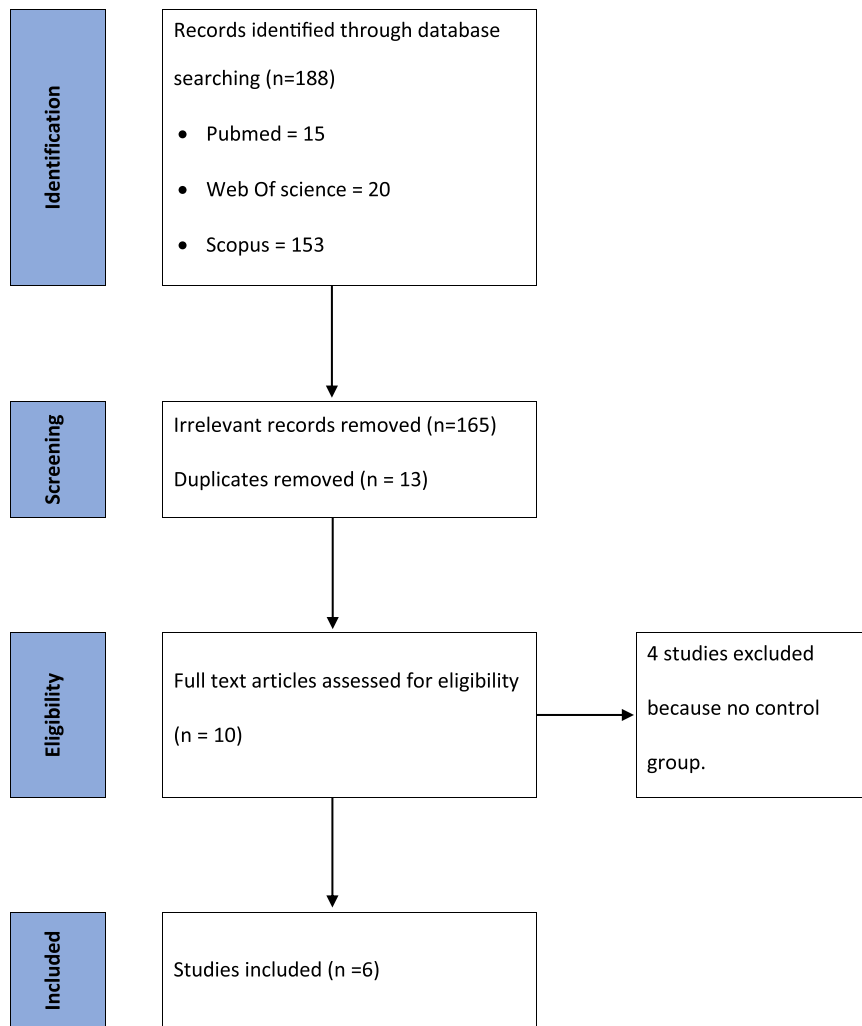


Figure 1. Flowchart for study screening and selection (n = number of articles).

Location, sample size, and age

The studies were carried out in different world regions, but mainly Asia,^{19,22,23} Europe^{25,26} and America.²⁴ The number of patients varied widely between the studies. Two studies had a sample size of 137 and 168 patients,^{22,23} two studies each recruited 60 subjects,^{25,26} whereas the remaining two had an average of 34 patients per study.^{19,24} Two studies did not specify an age group,^{22,23} whereas one study examined patients over the age of 18 years.¹⁹ The other studies included patients aged between eight to twelve.^{24–26}

Inclusion and exclusion criteria

One study did not specify its inclusion and exclusion criteria.²² A second study did not mention its

inclusion criteria,²³ whereas another did not specify its exclusion criteria.²⁴ The remaining three studies identified their inclusion and exclusion criteria.^{19,25,26}

Three studies excluded patients with a cleft lip and/or palate,^{19,23,26} whereas two studies excluded patients with previous orthodontic/prosthetic treatment.^{23,26} Additionally, two studies excluded patients with a history of maxillofacial trauma or surgery,^{19,23} whereas two studies excluded patients with temporomandibular joint dysfunction or hypodontia.^{25,26}

Instruments used

Two studies used dental casts, which were then classified according to the Thomas and Kotze classification to assess palatal rugae patterns.^{22,23}

Table 1. Summary of study characteristics

No	Study	Year	Country	Sample description	Material	Age group	Exposure	Inclusion and exclusion criteria	Outcome - Changes in palatal rugae region
1	Deepak et al. ²²	2014	India	137 pre- and post-ortho dental cast	Dental cast (Thomas and Kotze)	NA	Group 1: 50 extraction Group 2: 50 non-extraction Group 3: 37 cases of palatal expansion comprising both extraction and non-extraction*	NA	Length - Insignificant changes for all three groups. Morphological shape - Insignificant changes

* Unsure types of expansion used

2	Ali et al. ²³	2016	Pakistan	168 pre- and post-ortho dental cast	Dental cast (Thomas and Katze)	NA	Group 1: 58 subjects for extraction (all first premolars) Group 2: 58 subjects non-extraction Group 3 : 58 subjects palatal expansion (HAAS expander) with 1 turn of activation every alternate day to achieve 5mm expansion followed by non-extraction fixed appliance treatment	Exclusion: Prior history of orthodontic or prosthodontics treatment, history of any severe palatal trauma and congenital syndromes affecting the palate such as cleft palate or any surgical procedures performed on the hard palate were excluded.	Length - Second and third rugae in the extraction group were significantly reduced ($p < 0.05$). Statistically significant increase in the third rugae length was observed in the palatal expansion group ($p < 0.05$). No difference between left and right in extraction and non-extraction group No morphological change of all three groups
---	--------------------------	------	----------	--	--------------------------------------	----	--	---	--

Table 1. Summary of study characteristics

No	Study	Year	Country	Sample description	Material	Age group	Exposure	Inclusion and exclusion criteria	Outcome - Changes in palatal rugae region
3	Bavaresco et al. ¹⁹	2020	Moscow	30 patients	Photograph of dental cast (Santos classification)	> 18 years old	Group 1: 10 subjects for HAAS expander followed by fixed appliance without extraction. Group 2: 10 subjects with extraction of upper first premolars followed by anterior retraction. Group 3: 10 subjects without extraction nor expansion	Inclusion: patient that had complete dental records in the archives of the local dental centre, underwent orthodontic treatment, had initial and final orthodontic dental casts, and older than 18 years of age. Exclusion: Orthodontic dental casts in poor condition, orthodontic dental casts in which the palatal rugae were not properly visible, patients with history of trauma in the maxillofacial region, patients with visible diseases in the soft and hard tissue of the palate, and patients with history of systemic diseases	Morphological change: Significant for expansion and extraction group but not for non-extraction group

4	Damsira et al. ²⁴	2009	USA	38 patients	Photograph of dental cast (lysell classification)	Group 1: 12.4 ± 2.0 Group 2: 12.5 ± 2.1	RME group: 19 patients RME followed by fixed appliance without extraction Control group: 19 patients with fixed appliance only	Inclusion criteria: RME Group - 1. Initial treatment by a Hyrax appliance (four banded in the permanent dentition, two banded with anterior expansion in the mixed dentition) 2. A minimum of 12 months of pre-adjusted full fixed appliance treatment following RME. 3. No extraction of maxillary premolars 4. Clear and identifiable rugae points on the dental casts. 5. Standardized Hyrax activation protocol (one activation of the screw per day) 6. A minimum of 5mm palatal screw activation Control group: 1. No treatment with an expansion of any type of appliance (hyrax, quadhelix, headgear, or transpalatal arch) 2. A minimum of 12 months of pre-adjusted full fixed appliance treatment 3. No extraction of maxillary premolars 4. Clear and identifiable rugae points on the dental casts	Measurement: Significant change of transverse measurement (TM) between medial aspect of the rugae but no change in anteroposterior measurement (APM) in RME group No change in TM and APM in control group
---	------------------------------	------	-----	-------------	---	--	---	--	---

Table 1. Summary of study characteristics

No	Study	Year	Country	Sample description	Material	Age group	Exposure	Inclusion and exclusion criteria	Outcome - Changes in palatal rugae region
5	Lanteri et al. ²⁵	2020	Italy	54 subjects	3D model (best of fit superimposition using RMS)	8.5 ± 1.5 years old	Group 1: 27 subjects treated with Expander Group 2: 27 subjects without treatment	Inclusion: Early or mid-mixed dentition, with both primary second molars (Es) preserved, Cervical Vertebral Stage 1 through 3 (CVS methods 1-3), Angle Class I or Class II malocclusion, no previous orthodontic treatment and maxillary arch constriction Exclusion: The presence of craniofacial abnormalities, previous extraction or surgical treatment, Angle Class III malocclusion, Temporomandibular Joint dysfunctions (TMJD), or carries of Es	Measurement: No difference of root mean square (RMS-square root of the arithmetic mean of the squares of the point-to-point distance between the areas with an identical coordinate system) between both groups

6	Ugolini et al. ²⁶	Italy	38 Italian subjects (17 males and 21 females)	3D model (best fit algorithm)	Group 1: 8.2 ± 1.2 years Control group: 7.9 ± 1.4 years	Group 1: 38 patients received RME Group 2 (control group): 26 patient - no treatment	Inclusion criteria: Angle Class I or Class II dental malocclusion with uni- or bilateral cross-bite and/or constricted maxilla and were selected before the pubertal peak (cervical vertebral maturation stage 1 -3) Exclusion: Patients with previous orthodontic treatment, hypodontia in any quadrant excluding third molars, craniofacial syndromes, or cleft lip or palate were not considered for the study	RMS value of the RME group is statistically higher than the RMS value of control untreated groups
---	------------------------------	-------	---	-------------------------------	--	---	--	---

3D indicates 3 dimensional; APM, anteroposterior measurement; CVS, cervical vertebral stage; NA, not available; RME, rapid maxillary expansion; RMS, root mean square; TM, transverse measurement.

Two studies used photographs of dental casts.^{19,24} However, one study¹⁹ used the Santos classification system, whereas another study²⁴ used the Lysell classification system to assess palatal rugae pattern. Two studies used a 3D model in which an automatic best-fit superimposition algorithm and distance were expressed using Root Mean Square (RMS) to evaluate the rugal pattern.^{25,26}

Patient intervention

One study had groups of patients who had undergone palatal expansion involving either an extraction or non-extraction approach.²² Two studies similarly had groups of patients who had undergone extraction and non-extraction; however, an extra group comprised patients who had undergone palatal expansion following a non-extraction approach²³ and patients who had not undergo palatal expansion nor extractions.¹⁹ In addition, two studies assessed patients treated with rapid maxillary expansion (RME) versus no treatment.^{25,26} In contrast, one study only looked at patients treated with RME versus fixed appliance treatment.²⁴

Outcomes – changes in palatal rugae morphology (including length, shape, and root mean square)

Two studies concluded that there were insignificant or no changes in the morphological shape of the rugae post-treatment.^{22,23} However, one study noted significant changes in the expansion and extraction group but not in the non-extraction group.¹⁹ One study concluded that there were insignificant changes in the length of the palatal rugae.²² In contrast, another study concluded that there were significant changes post-treatment.²³ One study identified a significant change in the transverse measurement between the medial aspect of the rugae but no change in anteroposterior measurement in patients who had undergone an RME compared to a control group.²⁴ In the studies that used RME to assess palatal rugae pattern, one study concluded that there were no significant changes in patients who had undergone RME versus a control group,²⁵ whereas another study concluded that there were statistically significant changes in patients who had undergone RME.²⁶

Discussion

Plaster study models are an essential diagnostic tool in dentistry. Although they pose problems with casting and storage, they remain a gold standard for measurement due to the dimensionally stable impression material and gypsum products used for fabrication.²⁷ Digital study models were introduced in the 1990s, and their reproducibility and validity have made them popular and widely used.^{28–30} The studies included in this review used plaster models except for two,^{25,26} whereas all the included studies were the same regarding the diagnostic tools used for examination.

Patients who had a cleft lip and palate, craniofacial syndrome, trauma, or periodontal surgery that affected the hard palate region or had undergone previous orthodontic treatment were excluded from this review as these environmental influences may have altered palatal rugae morphology and therefore acted as a confounding factor.

Rapid maxillary expansion (RME), slow maxillary expansion (SME), and surgical rapid maxillary expansion (SARME) are three treatment modalities used to treat transverse discrepancy malocclusions, identified as a constricted maxillary arch or posterior crossbite. All of the studies included in this review utilised an RME to perform maxillary arch expansion, except for Lanteri et al. (2020), who used an SME.²⁵ An RME can produce forces of up to 100N over 2 to 3 weeks, whereas SME produces nearly 10N of force over four months. According to Zhou et al. (2014), an RME produced significant expansion in maxillary intermolar width compared to SME but no significant differences in maxillary interpremolar and intercanine width were identified.³¹ An RME gives rise to an increase that favours bodily tooth movement compared to tipping movements.^{32,33} Therefore, RME is almost exclusively used in paediatric patients aged 15 years or younger due to a patent palatine suture.³⁴ However, SARME is indicated when considerable maxillary expansion is needed in non-growing patients.

Unlike RME, recent studies claim that SMEs mainly produce dentoalveolar tooth movement and no skeletal expansion.^{35,36} In contrast, it is further claimed that SMEs produce light, continuous physiological forces to increase the deposition of bone in the circum-maxillary suture system and produce the same effect as an RME.^{37–39} This

allows SMEs to produce greater stability during the reorganisation process of the maxillary complex.³³ This could also be attributed to more tolerant physiological forces exerted on the palatal arch, which allows the palatal rugae to slowly adapt, and hence produce no significant changes in the rugae in this expansion group, as reported by Lanteri et al. (2016).³⁷ This result does not agree with Ugolini et al. (2021).²⁶ However, both studies used the same method to examine whether expansion causes changes to palatal rugae compared to a non-treatment group. The contrary result could be due to differences in the expansion appliance utilised, as Ugolini et al. (2021) used an RME while Lanteri et al. (2020) used a leaf expander, which is a form of SME.^{26,37} Furthermore, both studies captured the digital model at pre-treatment and appliance removal. This may have led to assessor bias as the expander's imprint on the palate was visible on post-expansion models.

Ali et al. (2016)²³ showed that the length of the third palatal rugae increased in the expansion and extraction groups compared to the non-extraction groups, which is consistent with previous studies.^{19,20,40} The change could also be due to the expansion forces mainly applied to the premolar and molar regions. Hence, the third palatal rugae are affected the most. This supports the theory that "the closer the rugae are to the teeth, the more likely they are to stretch in the direction of the associated teeth".^{21,41} Furthermore, Damstra et al. (2015) also found transverse changes between the medial aspects of the rugae in the expansion group compared to a non-extraction group.²⁴ The intermedial distance of rugae resembles an 'A' pattern because the third rugae is the largest, whereas the distance between the first rugae is the smallest. This separation pattern is not in accordance with the palatine suture, which has a 'V-shaped' pattern, suggesting that this may be due to the overlying palatal mucosa not following the separation of the palatine bone.⁴² Damstra et al. (2009)²⁴ noted no transverse nor anteroposterior changes in the non-extraction group, which supported the result of other studies.^{16,24,43}

Although there were changes in the linear measurement, the palatal rugae maintained their shape after expansion.^{22,23,44} Therefore, it can be theorised that palatal rugae morphology can potentially be used for forensic identification.

Deepak et al. (2014) and Ali et al. (2016) did not mention the age of the study participants.^{22,23} Therefore, there is uncertainty about whether the subjects had passed their growth spurt. Bavaresco et al. (2020) recruited patients 18 years and older.¹⁹ However, an RME is not indicated if the patient is above 15 years of age because the mid-palatal suture would likely be unreactive. Therefore, morphological changes in the palatal rugae reported by Bavaresco (2020) and Ali et al. (2016) may be caused by fixed orthodontic treatment instead of expansion mechanics.^{19,23}

Deepak et al. (2014) claimed that there was no significant change in the palatal rugae related to their length and shape in an expansion group, as well as extraction and non-extraction groups.²² The result is supported by Barbieri et al. (2012).⁴⁴ However, both studies carried a high risk of bias. Deepak et al. (2014) did not mention the type of expansion mechanics utilised. In addition, there was no sample size calculation or blinding of the assessor and no result of the intraclass correlation coefficient.²² In contrast, Barbieri et al. (2012) presented a limited sample size and no control group.⁴⁴ Therefore, the level of confidence that can be drawn from the conclusions of these articles is low.

The presence of growth factor and its impact on palatal rugae morphology should also be considered as some studies recruited growing patients.^{25,26} However, Lysell et al. (1955) showed that the palatal rugae remains unaltered after the 12th week of intrauterine life.⁴¹ Age may make the palatal rugae less defined, but the configuration of the rugae remains unchanged.^{45,46} Furthermore, Almeida et al. (1995) and Kim et al. (2012) argued that the changes in palatal rugae due to growth are not clinically significant.^{16,47} Therefore, age is not a confounding factor.

The periodontal apparatus consists of periodontal, supracrestal, and supraosseous fibres, which take one to one and a half years to reorganise after orthodontic tooth movement.⁴⁸ Ideally, measurement or rugoscopy should be undertaken after the soft tissue is relatively stable and more reliable.⁴⁴ All studies included in this review measured their outcome immediately after treatment intervention; therefore, this may be a confounding factor, and confirmatory longitudinal studies should be carried out. However, this may lead to attrition bias and affect the compliance of retainer wear post-orthodontic treatment, and herald relapse.

Limitations

The present scoping review descriptively summarised the data rather than provide an analytical assessment. There was heterogeneity of the data of the studies related to the expansion mechanisms, age and gender of the patients and outcome measurement.

Suggestions

In order to have a level of confidence in the conclusions drawn from studies regarding the stability of palatal rugae after expansion, a sound study design is required. The authors recommend the following:

1. Participants: Increase sample size to increase the power of the study and follow up with the patients at least until after growth has slowed to the adult level to minimise a possible growth factor effect on the palatal rugae.⁴⁹ In addition, previous studies have been carried out in different regions, therefore, the results must be viewed with caution and cannot be generalised to other populations.
2. Study design: Longitudinal study with a control group is recommended.
3. Intervention: Consider the use of different types of expansion mechanisms, especially SME, because of a lack of studies using this expander.
4. Outcome: The use of 3D superimposition to measure three-dimensional changes of palatal rugae to provide robust results.⁴⁹ Also, using digital models may avoid artifacts of plaster models such as bubbles or fractures.

Conclusion

A low level of evidence shows that orthodontic expansion makes the palatal rugae unstable; therefore, utilising the palatal rugae for forensic identification or as a stable landmark for orthodontic superimposition in patients following maxillary expansion should be used with caution.

Corresponding to

Alizae Marny Fadzlin Syed Mohamed, BDS, MOrthRCS, Discipline of Orthodontics, Department of Family Oral Health, Faculty of Dentistry, University Kebangsaan Malaysia, Jalan Raja Muda Abdul Aziz, 50300 Kuala Lumpur, Malaysia
Telephone Number: 603-92897588/6012-2276446;

Fax No: 603-2698 2944; Email: alizaemarny@ukm.edu.my

Conflict of interest

The authors declare that there is no conflict of interest.

Ethical approval

Ethical approval was not required for this study as it is a scoping review.

Acknowledgements

This work was supported by Geran Universiti Penyelidikan (GUP-2019-029), Universiti Kebangsaan Malaysia.

References

1. Patil MS, Patil SB, Acharya AB. Palatine rugae and their significance in clinical dentistry: a review of the literature. *J Am Dent Assoc* 2008;139:1471–8.
2. Sheikhi M, Zandi M, Ghazizadeh M. Assessment of palatal rugae pattern for sex and ethnicity identification in an Iranian population. *Dent Res J (Isfahan)* 2018;15:50–6.
3. Limson KS, Julian R. Computerized recording of the palatal rugae pattern and an evaluation of its application in forensic identification. *J Forensic Odontostomatol* 2004;22:1–4.
4. English WR, Robison SF, Summitt JB, Oesterle LJ, Brannon RB, Morlang WM. Individuality of human palatal rugae. *J Forensic Sci* 1988;33:718–26.
5. Shukla D, Chowdhry A, Bablani D, Jain P, Thapar R. Establishing the reliability of palatal rugae pattern in individual identification (following orthodontic treatment). *J Forensic Odontostomatol* 2011;29:20–9.
6. Caldas IM, Magalhães T, Afonso A. Establishing identity using cheiloscopia and palatoscopia. *Forensic Sci Int* 2007;165:1–9.
7. Ohtani M, Nishida N, Chiba T, Fukuda M, Miyamoto Y, Yoshioka N. Indication and limitations of using palatal rugae for personal identification in edentulous cases. *Forensic Sci Int* 2008;176:178–82.
8. Chong JA, Mohamed A, Pau A. Morphological patterns of the palatal rugae: A review. *J Oral Biosci* 2020;62:249–59.
9. Herrera LM, Strapasson RA, Mazzilli LE, Melani RF. Differentiation between palatal rugae patterns of twins by means of the Briñón method and an improved technique. *Braz Oral Res* 2017;31:e9.
10. Chong JA, Syed Mohamed AMF, Marizan Nor M, Pau A. The heritability of palatal rugae morphology among siblings. *J Forensic Sci*. 2020;65:2000–7.
11. Nalcaci R, Kocoglu-Altan AB, Bicakci AA, Ozturk F, Babacan H. A reliable method for evaluating upper molar distalization: superimposition of three-dimensional digital models. *Korean J Orthod* 2015;45:82–8.
12. Allen H. The palatal rugae in man. *Proc Acad Nat Sci Philadelphia* 1889;40:254–72.
13. Vasilakos G, Schilling R, Halazonetis D, Gkantidis N. Assessment of different techniques for 3D superimposition of serial digital maxillary dental casts on palatal structures. *Sci Rep* 2017;7:5838.

14. Sandler J, Murray A, Thiruvkatachari B, Gutierrez R, Speight P, O'Brien K. Effectiveness of 3 methods of anchorage reinforcement for maximum anchorage in adolescents: a 3-arm multicenter randomized clinical trial. *Am J Orthod Dentofacial Orthop* 2014;146:10–20.
15. van der Linden FP. Changes in the position of posterior teeth in relation to ruga points. *Am J Orthod* 1978;74:142–61.
16. Almeida MA, Phillips C, Kula K, Tulloch C. Stability of the palatal rugae as landmarks for analysis of dental casts. *Angle Orthod* 1995;65:43–8.
17. Chen G, Chen S, Zhang XY, Jiang RP, Liu Y, Shi FH, et al. Stable region for maxillary dental cast superimposition in adults, studied with the aid of stable miniscrews. *Orthod Craniofac Res* 2011;14:70–9.
18. Jang I, Tanaka M, Koga Y, Iijima S, Yozgatian JH, Cha BK, et al. A novel method for the assessment of three-dimensional tooth movement during orthodontic treatment. *Angle Orthod* 2009;79:447–53.
19. Bavaresco D, Von Meusel LDZ, Franco A, Makeeva I, Paranhos LR, Cericato GO. Morphology of the palatal rugae before and after orthodontic treatment with and without rapid maxillary expansion and dental extractions. *Indian J Dent Res* 2020;31:241–6.
20. Kapoor P, Miglani R. Transverse changes in lateral and medial aspects of palatal rugae after mid palatal expansion: A pilot study. *J Forensic Dent Sci* 2015;7:8–13.
21. Peavy DC Jr, Kendrick GS. The effects of tooth movement on the palatine rugae. *J Prosthet Dent* 1967;18:536–42.
22. Deepak V, Malgaonkar NI, Shah NK, Nasser AS, Dagrur K, Bassle T. Palatal rugae patterns in orthodontically treated cases, are they a reliable forensic marker? *J Int Oral Health* 2014;6:89–95.
23. Ali B, Shaikh A, Fida M. Stability of palatal rugae as a forensic marker in orthodontically treated cases. *J Forensic Sci*. 2016;61:1351–5.
24. Damstra J, Mistry D, Cruz C, Ren Y. Antero-posterior and transverse changes in the positions of palatal rugae after rapid maxillary expansion. *Eur J Orthod* 2009;31:327–32.
25. Lanteri V, Cossellu G, Farronato M, Ugolini A, Leonardi R, Rusconi F, et al. Assessment of the stability of the palatal rugae in a 3D-3D superimposition technique following slow maxillary expansion (SME). *Sci Rep* 2020;10:2676.
26. Ugolini A, Cossellu G, Rusconi F, De Luca S. Analysis of the palatal rugae following rapid maxillary expansion (RME) by using a 3D-3D superimposition procedure. *Aust J Forensic Sci* 2023;55:191–202.
27. Abizadeh N, Moles DR, O'Neill J, Noar JH. Digital versus plaster study models: how accurate and reproducible are they? *J Orthod* 2012;39:151–9.
28. Fleming PS, Marinho V, Johal A. Orthodontic measurements on digital study models compared with plaster models: a systematic review. *Orthod Craniofac Res* 2011;14:1–16.
29. Dalstra M, Melsen B. From alginate impressions to digital virtual models: accuracy and reproducibility. *J Orthod* 2009;36:36–41; discussion 14
30. Joffe L. OrthoCAD: digital models for a digital era. *J Orthod* 2004;31:344–7.
31. Zhou Y, Long H, Ye N, Xue J, Yang X, Liao L, et al. The effectiveness of non-surgical maxillary expansion: a meta-analysis. *Eur J Orthod* 2014;36:233–42.
32. Lagravère MO, Heo G, Major PW, Flores-Mir C. Meta-analysis of immediate changes with rapid maxillary expansion treatment. *J Am Dent Assoc* 2006;137:44–53.
33. Bell RA. A review of maxillary expansion in relation to rate of expansion and patient's age. *Am J Orthod* 1982;81:32–7.
34. Melsen B. Palatal growth studied on human autopsy material. A histologic microradiographic study. *Am J Orthod* 1975;68:42–54.
35. Pereira JDS, Jacob HB, Locks A, Brunetto M, Ribeiro GLU. Evaluation of the rapid and slow maxillary expansion using cone-beam computed tomography: a randomized clinical trial. *Dental Press J Orthod*. 2017;22:61–8.
36. Gianolio A, Cherchi C, Lanteri V. Rapid and slow maxillary expansion: a posteroanterior cephalometric study. *Eur J Paediatr Dent* 2014;15:415–8.
37. Lanteri C, Beretta M, Lanteri V, Gianolio A, Cherchi C, Franchi L. The leaf expander for non-compliance treatment in the mixed dentition. *J Clin Orthod* 2016;50:552–60.
38. Proffit WR, Fields HW Jr, Sarver DM. *Contemporary orthodontics*, 6th ed. Elsevier Health Sciences; 2006.
39. Bucci R, D'Antò V, Rongo R, Valletta R, Martina R, Michelotti A. Dental and skeletal effects of palatal expansion techniques: a systematic review of the current evidence from systematic reviews and meta-analyses. *J Oral Rehabil* 2016;43:543–64.
40. Saadeh M, Macari A, Haddad R, Ghafari J. Instability of palatal rugae following rapid maxillary expansion. *Eur J Orthod* 2017;39:474–81.
41. Lysell L. Plicae palatinae transversae and papilla incisiva in man; a morphologic and genetic study. *Acta Odontol Scand* 1955;13 (Suppl 18):5–137.
42. Shailaja AM, Romana IRU, Narayanappa G, Smitha T, Gowda NC, Vedavathi HK. Assessment of palatal rugae pattern and its significance in orthodontics and forensic odontology. *J Oral Maxillofac Pathol* 2018;22:430–5.
43. Bailey LT, Esmailnejad A, Almeida MA. Stability of the palatal rugae as landmarks for analysis of dental casts in extraction and nonextraction cases. *Angle Orthod* 1996;66:73–8.
44. Barbieri AA, Scoralick RA, Naressi SC, Moraes ME, Daruge E Jr, Daruge E. The evidence of the rugoscopy effectiveness as a human identification method in patients submitted to rapid palatal expansion. *J Forensic Sci* 2013;58 Suppl 1:S235–8.
45. Tonge CH, Luke DA. Dental anatomy: the palate. *Dent Update* 1985;12:461–2, 464, 466–67.
46. Thomas CJ, Van Wyk CW. Elastic fibre and hyaluronic acid in the core of human palatal rugae. *J Biol Buccale* 1987;15:171–4.
47. Kim HK, Moon SC, Lee SJ, Park YS. Three-dimensional biometric study of palatine rugae in children with a mixed-model analysis: a 9-year longitudinal study. *Am J Orthod Dentofacial Orthop* 2012;141:590–7.
48. Reitan K. Principles of retention and avoidance of posttreatment relapse. *Am J Orthod* 1969;55:776–90.
49. Taneva ED, Johnson A, Viana G, Evans CA. 3D evaluation of palatal rugae for human identification using digital study models. *J Forensic Dent Sci* 2015;7:244–52.