

Науковий вісник Львівського національного університету  
ветеринарної медицини та біотехнологій імені С.З. Гжицького.

Серія: Ветеринарні науки

Scientific Messenger of Lviv National University  
of Veterinary Medicine and Biotechnologies.

Series: Veterinary sciences

ISSN 2518–7554 print  
ISSN 2518–1327 online

doi: 10.32718/nvlvet11019  
<https://nvlvet.com.ua/index.php/journal>

UDC636.09:616.61:547.495.9:636.8

## Relationship between kidney ultrasound data and blood creatinine and urea levels in cats with autosomal dominant polycystic kidney disease

D. Kibkalo<sup>✉</sup>, O. Tymoshenko, O. Siehodin, O. Tsymerman, O. Matsenko

State Biotechnological University, Kharkiv, Ukraine

### Article info

Received 17.04.2023

Received in revised form

17.05.2023

Accepted 18.05.2023

State Biotechnological University,  
Alchevskikh Str., 44, Kharkiv  
61002, Ukraine.  
Tel.: +38(057) 700-38-88  
E-mail: [info@btu.kharkov.ua](mailto:info@btu.kharkov.ua)

**Kibkalo, D., Tymoshenko, O., Siehodin, O., Tsymerman, O., & Matsenko, O. (2023). Relationship between kidney ultrasound data and blood creatinine and urea levels in cats with autosomal dominant polycystic kidney disease. Scientific Messenger of Lviv National University of Veterinary Medicine and Biotechnologies. Series: Veterinary sciences, 25(110), 116–120. doi: 10.32718/nvlvet11019**

The results of studying the influence of structural changes in the kidneys on their filtration in cats with polycystic kidney disease are given. The study was conducted on 10 domestic cats, which were divided into two experimental groups based on the results of creatinine determination according to the IRIS (International Renal Interest Society) classification – 5 animals with moderate renal azotemia (group 1) and 5 animals with severe renal azotemia (group 2). Ultrasound examination of the kidneys of cats in both groups was performed using Mindray device with a microconvection transducer with a frequency of 7.5–10 MHz in B-mode. Both kidneys were examined in each animal. Scanning was performed in the sagittal plane so that the kidney gate was visible. The length, width of the kidney and thickness of the of the cortical layer, as well as the number of cysts and their diameter were counted. The renal area (RA), cyst area (CA), and the ratio of cyst area to renal area (RA/Cyst) were calculated. According to the results of the study of serum creatinine and urea content the animals were divided into two groups depending on the level of azotemia. 5 cats with stage III of chronic renal failure (CRF), serum creatinine levels were  $326.40 \pm 23.59 \mu\text{mol/l}$  and 5 animals with stage IV chronic renal failure serum creatinine –  $887.00 \pm 61.81 \mu\text{mol/l}$ , which is 2.7 times higher ( $P \leq 0.001$ ) than the creatinine level in cats with stage III CKD. The urea content in the serum was significantly increased compared to the norm and amounted to  $22.82 \pm 2.09 \text{ mol/l}$  in cats with stage III CKD and  $42.45 \pm 1.05 \text{ mol/l}$  in cats with stage IV CKD, which was 2.2 times higher ( $P \leq 0.01$ ) compared to stage III. In animals with polycystic kidney disease and stage IV of chronic renal failure according to the results of ultrasound examination an increase in the length of the kidney by 6.5 mm ( $p \leq 0.001$ ) and a thickening of the cortical layer by 0.8 mm ( $P \leq 0.01$ ) was revealed, compared to animals with polycystic kidney disease and stage III chronic renal failure. There was no correlation between the area of cysts in the kidneys and the level of creatinine in the blood serum of animals. Ultrasound signs of chronic renal failure in cats of stage III are enlargement of the kidney in length of more than 51 mm and cortical thickness of more than 5.5 mm, of stage IV is an increase in kidney length of more than 59 mm and cortical thickness of more than 6.0 mm. According to the results of ultrasonography, the number of cysts or their area cannot be used to assess the degree of renal functional failure.

**Keywords:** cats, polycystic kidney disease, creatinine, ultrasound diagnostics.

## Взаємозв'язок між даними ультразвукового дослідження нирок та рівнем креатиніну і сечовини в крові у котів, хворих на аутосомно домінуючий полікістоз нирок

Д. В. Кібкало<sup>✉</sup>, О. П. Тимошенко, О. Б. Сєгодін, О. О. Цимерман, О. В. Маценко

Державний біотехнологічний університет, м. Харків, Україна

Наведено результати вивчення впливу структурних змін нирок на їхню фільтраційну функцію у котів, хворих на полікістоз нирок. Дослідження проведені на 10 домашніх котак, яких за результатами визначення вмісту креатиніну поділили на дві дослідні групи згідно з класифікацією IRIS (International Renal Interest Society) – 5 тварин з помірною нирковою азотемією (перша група) та – 5 тварин з тяжкою ренальною азотемією (друга група). Ультразвукове дослідження нирок котів обох груп проводили за допомогою апарату Mindray з мікроконвексним датчиком із частотою 7,5–10 МГц в В-режимі. У кожній тварини досліджували обидві нирки. Сканування проводили в сагітальній площині так, щоб було видно ворота нирки. Встановлювали довжину, ширину нирки та товщину коркового шару, також підраховували кількість кіст і вимірювали їх діаметр. Вираховували площу нирок ( $S_n$ ), площу кіст ( $S_k$ ) та відношення площі кіст до площі нирок ( $S_k/S_n$ ) у тварини. За результатами дослідження вмісту креатиніну та сечовини в сироватці крові тварин поділили на дві групи залежно від рівня азотемії, а саме: 5 котів з III стадією хронічної ниркової недостатності (ХНН), показник креатиніну в сироватці крові –  $326,40 \pm 23,59$  мкмоль/л та 5 тварин з IV стадією хронічної ниркової недостатності, показник креатиніну в сироватці крові –  $887,00 \pm 61,81$  мкмоль/л, що в 2,7 рази вище ( $P \leq 0,001$ ) від показника креатиніну у котів з III стадією ХНН. Вміст сечовини в сироватці крові тварин був значно підвищеним порівняно з нормою та становив  $22,82 \pm 2,09$  моль/л у котів з III стадією ХНН та  $42,45 \pm 1,05$  моль/л у котів із IV стадією ХНН, що був у 2,2 рази вищим ( $P \leq 0,01$ ) порівняно з III стадією. У тварин з полікістозом нирок та IV стадією хронічної ниркової недостатності за результатами ультразвукового дослідження встановлено збільшення довжини нирки на 6,5 мм ( $P \leq 0,001$ ) та потовщення коркового шару на 0,8 мм ( $P \leq 0,01$ ) порівняно з тваринами із полікістозом нирок та III стадією хронічної ниркової недостатності. Не встановлено залежності між площею кіст в нирках та рівнем креатиніну в сироватці крові тварин. Ультразвуковими ознаками хронічної ниркової недостатності у кішок III стадії є збільшення нирки в довжину понад 51 мм та товщини коркового шару понад 5,5 мм, IV стадії – збільшення нирки в довжину понад 59 мм та товщини коркового шару понад 6,0 мм. За результатами ультразвукового дослідження кількості кіст чи їхньої площі не можна оцінити ступінь функціональної недостатності нирок.

**Ключові слова:** коти, полікістоз нирок, креатинін, ультразвукова діагностика.

## Introduction

Polycystic kidney disease (autosomal dominant polycystic kidney disease (ADPKD)) is a genetic and incurable disease characterised by abnormal formation of fluid-filled cysts in one or both kidneys, extracellular matrix remodeling, inflammation and fibrosis in the affected kidney. Autosomal dominant polycystic kidney disease is the most common inherited genetic disease of cats, predominantly affecting Persians and Persian cats (Scottish Fold, Exotic Shorthair and British Shorthair). The prevalence of polycystic disease in Persian cats reaches 17.5 %, and in Persian-related cat breeds – 3.9 % (Noori et al., 2019; Bilgen et al., 2020). Among other breeds, the prevalence of the disease ranges from 6 to 13.8 % (Alzahrani et al., 2022).

There are two main forms of this disease: autosomal dominant polycystic kidney disease, which is a common form of polycystic kidney disease and another form which is an autosomal recessive polycystic kidney disease that is characterised by a slower rate of progression (Noori et al., 2019).

Polycystic kidney disease is characterised by unilateral or bilateral formation of cysts in the kidneys and is a systemic, progressive hereditary disease with clinical signs that can develop at any age; cysts can also form in other organs such as the liver and pancreas (Kravhenko, 2009; Bilgen et al., 2020). The formation and growth of cysts is slow, causing a decrease in renal parenchyma and a gradual decline in renal function, leading to the development of irreversible renal failure (Schirrer et al., 2021).

As for the pathogenesis of the disease, many causes are still under investigation and its mechanisms are not well understood. The process of cyst formation is likely due to a combination of increased cell proliferation, fluid secretion, and extracellular matrix changes, so the loss of cell polarisation can alter the water reabsorption function, causing cysts to form in the parenchyma (Schirrer et al., 2021).

Ultrasonography and genetic testing are the two main methods for screening and/or detecting polycystic diseases in humans and cats (Chapman, 2007). Both methods

are highly informative, but ultrasound, as a non-invasive and simple method, is the imaging modality most commonly used for screening and diagnosis of polycystic disease in cats (Guerra et al., 2019). Ultrasound Doppler complements B-mode ultrasound and allows to assess the initial perfusion based on the calculation of hemodynamic parameters, which are increased in chronic kidney disease. Thus, ultrasound examinations are not only useful in diagnosis, but also play an important role in determining the prognosis of animals with chronic kidney disease (Bragato et al., 2017; Stock et al., 2018). Cats are classified as positive if at least one anechogenic cavity in one of the kidneys is detected (Barthez et al., 2003).

Ultrasound allows a fairly accurate measurement of renal volume (Reichle et al., 2002). In their studies, the authors did not find statistically significant differences in kidney volumes based on computed tomography and volumetric measurements based on ultrasound, which makes it possible to rely on the results of the latter in assessing structural changes in the kidneys. Functional kidney disorders are determined by creatinine and urea levels. In clinical practice it is very difficult to accurately determine the prognosis of the disease based only on clinical trial data and blood test results, so various indicators are being studied to predict the course of polycystic kidney disease. For example, it has been established that anemia diagnosed in 6 cats with polycystic kidney disease is an indicator of the degree of renal failure and a prognostic factor. Depending on the degree of parenchymal replacement by cysts and its compression (index of cystic lesions), a positive correlation between the erythropoietin level in animals was established (Roşca et al., 2022).

The determination of erythropoietin is not always available to veterinary clinics and ultrasound scanning is the first method of assessing the condition of the kidney, so in clinical practice it is necessary to establish the degree of functional impairment of the kidneys in polycystic kidney disease based on the results of ultrasound examinations.

## The aim of the research

The aim of the study is to investigate the effect of structural changes in the kidneys on their filtration function in cats with polycystic kidney disease.

## Materials and methods

The study was carried out on 10 domestic cats with polycystic kidney disease (ADPKD) on the basis of veterinary medicine clinics Vetline, Dog + Cat and Snow Leopard in Kharkiv during 2018-2021. Laboratory tests of blood serum were carried out in the accredited and certified laboratory ALVIS-CLASS in Kharkiv. Blood samples were taken from cats on an empty stomach from the saphenous vein of the forearm and the serum urea and creatinine content was determined by conventional methods (Vlizlo, 2012). Animals were divided into two experimental groups according to the IRIS classification (International Renal Interest Society, 2023), the first experimental group consisted of five animals with moderate renal azotemia (serum creatinine level up to 450  $\mu\text{mol/l}$ ) and the second experimental group consisted of five animals with severe renal azotemia (creatinine level above 450  $\mu\text{mol/l}$ ).

Ultrasound examination of kidneys in the experimental groups was performed using a Mindray device with a microconvex transducer with a frequency of 7.5 – 10 MHz in B-mode. Both kidneys were scanned in each animal. The animal was placed on its left or right side, depending on which kidney was examined. The ultrasound scan of the kidneys was performed from the lateral surface of the abdominal wall, placing the transducer directly above the kidney. The hair in this area was pre-shaved and ultrasound gel was applied, and the kidney was scanned in the sagittal plane so that the kidney gate was visible. The dimensions of the kidney were determined – the length, width and thickness of the cortical layer. The number of cysts and their diameter were also counted, which was determined in several scans of the kidney during the rotation of the transducer.

The area of the kidneys and the area of the cysts were determined by the formula for the area of an ellipse, which is equal to the product of the length of the major and minor axes of the ellipse and the number pi ( $S = a \times b \times \pi$ , where  $a$  is the length of the major axis of the ellipse,  $b$  is the length of the minor axis of the ellipse, and  $\pi$  is 3.14159). The total area of cysts in the kidney was determined as the sum of the areas of all cysts in the kidney, and the ratio of the area of cysts ( $S_c$ ) to the area of the kidneys ( $S_k$ ) in the animal ( $S_c/S_k$ ) was also determined.

*Information on compliance with bioethical standards.* The studies were conducted in accordance with the requirements of the General Ethical Principles for Animal Experiments (Kyiv, 2001), are consistent with the provisions of the European Convention for the Protection of Vertebrate Animals Used for Scientific Experiments or Other Scientific Purposes (Stasbourg, 1986), comply with the Law of Ukraine No. 3447-IV of 21.02.2006 On the

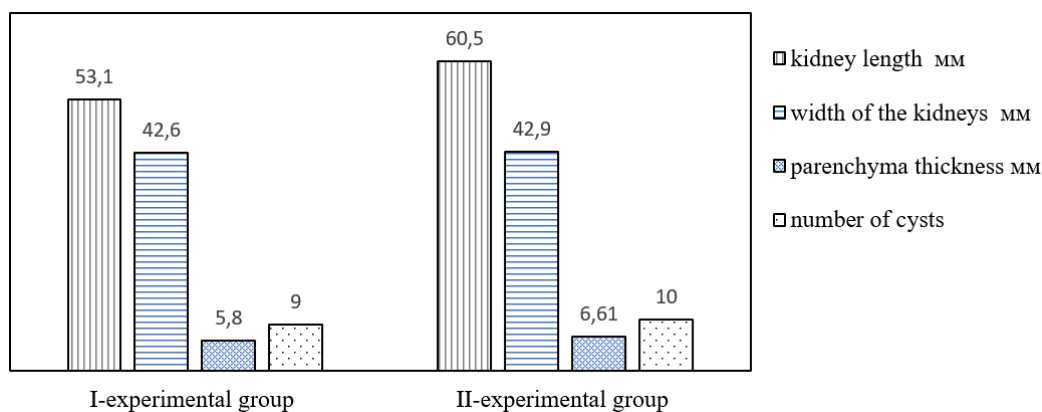
Protection of Animals from Cruelty and Directive 2010/63/EU On the Protection of Animals Used for Scientific Purposes.

## Results and discussion


According to the results of the study of serum creatinine and urea content, the animals were divided into two groups. The first experimental group consisted of five animals with moderate renal azotemia, whose serum creatinine averaged  $326.40 \pm 23.59 \mu\text{mol/l}$  and the second experimental group included five animals with severe azotemia with a serum creatinine level of  $887.00 \pm 61.81 \mu\text{mol/l}$ , which is 2.7 times higher ( $P \leq 0.001$ ) than the creatinine level in cats of the first group, the creatinine level was significantly higher than normal in animals of both groups. The urea content in the blood serum of animals of the first and second groups was significantly increased compared to the norm and amounted to  $22.82 \pm 2.09 \text{ mol/l}$  and  $42.45 \pm 1.05 \text{ mol/l}$ , respectively. At the same time, this indicator was significantly higher in cats of the first group compared to animals of the second group by 2.2 times ( $P \leq 0.01$ ). Based on the results of determining the content of creatinine and urea in the blood serum of animals, it can be concluded that there was azotemia in animals of all groups. According to the IRIS classification, the level of azotemia in the animals of the first experimental group corresponds to the third stage of chronic renal failure, and the animals of the second experimental group – to the fourth stage of chronic renal failure.

According to the results of ultrasound examination of the kidneys in animals of the II experimental group, an increase in kidney length by 6.5 mm on average was found compared to animals of the I experimental group ( $P \leq 0.001$ ) (Fig. 1). The width of the kidneys in animals of both groups did not differ. In addition, in animals of the first and second experimental groups, an increase in the thickness of the renal cortical layer was found compared to the norm (up to 5.0 mm) (Stock et al., 2018), and its thickening in animals of the second experimental group was 0.8 mm greater ( $P \leq 0.01$ ) compared to animals of the first experimental group (Fig. 1).

In animals of the first group ultrasound examination revealed from 7 to 10 cysts in both kidneys, in animals of the second group – from 9 to 11, i.e. the number of cysts did not differ significantly (Fig. 1). The area of the kidney in the animals of the first experimental group was  $1777.87 \pm 54.93 \text{ mm}^2$ , and in the animals of the second experimental group –  $2038.41 \pm 69.71 \text{ mm}^2$ . At the same time, the area of cysts in the kidney of animals of the first and second experimental groups was  $264.39 \pm 14.17 \text{ mm}^2$  and  $284.09 \pm 21.45 \text{ mm}^2$ , respectively. The ratio of cyst area to kidney area in animals of the first experimental group was  $0.15 \pm 0.01$ , and in animals of the second experimental group –  $0.14 \pm 0.01$ . That is an increase in the area of the kidney was found in animals of the second experimental group compared to the first experimental group (Fig. 2), but no significant difference between the area of cysts in the studied animals was found.



**Fig. 1.** Results of ultrasound examination of the kidneys in animals.



**Fig. 2.** Kidney area and cyst area in cats of the experimental groups

According to Reichle J. K. et al. (2002), who compared the volume of the kidneys in cats with polycystic kidney disease ( $n = 5$ ; mean age  $59 \pm 10$  months) and normal cats ( $n = 5$ ; mean age  $66 \pm 10$  months) using 2 imaging methods (ultrasound and CT), no statistically significant differences were found between the volume measurements of ultrasound and CT, which allows the use of ultrasound to determine the volume of renal cysts in sick cats. In the present study, in a group of clinically healthy middle-aged cats with polycystic kidney disease (ADPKD), renal function was within normal limits and did not differ significantly from the norm. Our studies were conducted on animals with the third and fourth stages of chronic renal failure according to the IRIS classification, which had clinical signs of chronic renal failure (depression, lack of appetite, periodic vomiting, decreased skin elasticity, uremic odour in some animals). In animals with polycystic kidney disease with the fourth stage compared to animals with the third stage of chronic renal failure, an increase in the size of the kidneys in length was found, which led to an increase in the area of the kidneys under ultrasound examination. A significant thickening of the cortical layer of the kidneys was also found. There was no significant difference between the number and area of cysts in the kidneys of the studied animals, indicating that there is no correlation between the level of

creatinine in the blood and the area of cysts in the kidneys of cats with the third and fourth stages of chronic renal failure.

The results of ultrasound examination of structural changes in the kidneys and the number of cysts or their area cannot be used to assess the degree of functional renal failure. In animals with polycystic kidney disease with the fourth stage of chronic renal failure, the results of ultrasound examination revealed an increase in kidney length by 6.5 mm ( $P \leq 0.001$ ) and cortical thickening by 0.8 mm ( $P \leq 0.01$ ) compared with animals with polycystic kidney disease with the third stage of chronic renal failure. There was no correlation between the area of cysts in the kidneys and the level of creatinine in the blood serum of animals.

### Conclusion

Ultrasound signs of chronic renal failure in cats with the third stage of CKD were an increase in the length of the kidney from 51.0 to 58.0 mm and the thickness of the cortical layer from 5.5 to 5.8 mm. Ultrasound signs of chronic renal failure in cats with the fourth stage of CKD were an increase in the length of the kidney from 58.0 to 64.0 mm and the thickness of the cortical layer from 5.9 to 7.2 mm.

*Prospects for further research.* Study of the effect of structural changes in the kidneys on their filtration function in domestic cats with polycystic kidney disease with mild or moderate azotemia (stage I or II chronic renal failure).

#### Acknowledgements

The authors express their sincere gratitude to the doctors of the veterinary clinics Vetline, Dog+Cat and Snow Leopard in Kharkiv for their assistance in conducting the study.

#### Conflict of interest disclosures

The authors declare no conflict of interest.

#### References

- Alzahrani, O. R., Alatwi, H. E., Alharbi, A. A., Alessa, A. H., Al-Amer, O. M., Alanazi, A. F. R., Shams, A. M., Alomari, E., Naser, A. Y., Alzahrani, F., Hosawi, S., Alghamdi, S. M., Abdali, W. A., Elfaki, I., Hawsawi, Y. M. (2022). Identification and Characterization of Novel Mutations in Chronic Kidney Disease (CKD) and Autosomal Dominant Polycystic Kidney Disease (ADPKD) in Saudi Subjects by Whole-Exome Sequencing. *Medicina*, 58, 1657. DOI: 10.3390/medicina58111657.
- Barthez, P. Y., Rivier, P., & Begon, D. (2003). Prevalence of polycystic kidney disease in Persian and Persian related cats in France. *Journal of Feline Medicine and Surgery*, 5, 345–347. DOI: 10.1016/S1098-612X(03)00052-4.
- Bilgen, N., Türkmen, M. B., Kul, B. C., Isparta, S., Şen, Y., Akkurt, M. Y., Çıldır, Ö. Ş., & Bars, Z. (2020). Prevalence of PKD1 gene mutation in cats in Turkey and pathogenesis of feline polycystic kidney disease. *Journal of veterinary diagnostic investigation*, 32(4), 549–555. DOI: 10.1177/1040638720935433.
- Bragato, N., Borges, N. C., & Fioravanti, M. C. S. (2017). B-mode and Doppler ultrasound of chronic kidney disease in dogs and cats. *Veterinary Research Communications*, 41, 307–315. DOI: 10.1007/s11259-017-9694-9.
- Chapman, A. B. (2007). Autosomal dominant polycystic kidney disease: time for a change? *Journal of the American Society of Nephrology*, 18(5), 1399–407. DOI: 10.1681/asn.2007020155.
- Guerra, J. M., Freitas, M. F., Daniel, A. G., Pellegrino, A., Cardoso, N. C., de Castro, I., Onuchic, L. F., Cogliati, B. (2019). Age-based ultrasonographic criteria for diagnosis of autosomal dominant polycystic kidney disease in Persian cats. *Journal of Feline Medicine and Surgery*, 21(2), 156–164. DOI: 10.1177/1098612x18764591.
- International Renal Interest Society (IRIS). Treatment recommendation for CKD in cats (2023). URL: [http://www.iris-kidney.com/education/pdf/IRIS\\_CAT\\_Treatment\\_Recommendations\\_2023.pdf](http://www.iris-kidney.com/education/pdf/IRIS_CAT_Treatment_Recommendations_2023.pdf).
- Kravchenko, S. O. (2009). Polikistoz nyrok u domashnih kishok (patogenez, diagnostyka i likuvannja): avtoref. dys. ... kand. vet. nauk : 16.00.01. Bila Cerkva (in Ukrainian).
- Noori, Z., Moosavian, H. R., Esmacilzadeh, H., Vali, Y., & Fazli, M. (2019). Prevalence of polycystic kidney disease in Persian and Persian related-cats referred to Small Animal Hospital, University of Tehran, Iran. *Iranian Journal of Veterinary Research*, 20(2), 151–154. URL: <https://www.ncbi.nlm.nih.gov/pmc/articles/PMC6716281>.
- Reichle, J. K., DiBartola, S. P., & Léveillé, R. (2002). Renal ultrasonographic and computed tomographic appearance, volume, and function of cats with autosomal dominant polycystic kidney disease. *Veterinary Radiology & Ultrasound*, 43(4), 368–373. DOI: 10.1111/j.1740-8261.2002.tb01020.x.
- Roşca, M., Cristian, A. M., Huştea, L., Preda, V., Simion, R., & Codreanu, M. (2022). Case studies regarding the hematological parameters in polycystic kidney disease in cats. *Scientific Works. Series C. Veterinary Medicine*, LXVIII (1), 125–128. URL: [https://veterinarymedicinejournal.usamv.ro/pdf/2022/issue\\_1/Art20.pdf](https://veterinarymedicinejournal.usamv.ro/pdf/2022/issue_1/Art20.pdf).
- Schirrer, L., Marin-García, P. J., & Llobat, L. (2021). Feline polycystic kidney disease: an update. *Veterinary Sciences*, 8(11), 269. DOI: 10.3390/vetsci8110269.
- Stock, E., Paepe, D., Daminet, S., Vandermeulen, E., Duchateau, L., Saunders, J. H., & Vanderperren, K. (2018). Contrast-enhanced ultrasound examination for the assessment of renal perfusion in cats with chronic kidney disease. *Journal of veterinary internal medicine*, 32(1), 260–266. DOI: 10.1111/jvim.14869.
- Vlizio, V. V. (2012). Laboratorni metody doslidzhen u biolohii, tvarynnytstvi ta veterynarii medytsyni: Dovidnyk. Lviv : SPOLOM (in Ukrainian).