

DOMINIK, Hanna, PAWĘSKA, Wojciech and DOMINIK, Barbara. Gastrointestinal tract carcinoid with carcinoid syndrome in 63-year-old diver – a case report. *Journal of Education, Health and Sport*. 2023;22(1):139-146. eISSN 2391-8306. DOI <http://dx.doi.org/10.12775/JEHS.2023.22.01.011> <https://apcz.umk.pl/JEHS/article/view/44707> <https://zenodo.org/record/8170651>

The journal has had 40 points in Ministry of Education and Science of Poland parametric evaluation. Annex to the announcement of the Minister of Education and Science of December 21, 2021. No. 32343. Has a Journal's Unique Identifier: 201159. Scientific disciplines assigned: Physical Culture Sciences (Field of Medical sciences and health sciences); Health Sciences (Field of Medical Sciences and Health Sciences). Punkty Ministerialne z 2019 - aktualny rok 40 punktów. Załącznik do komunikatu Ministra Edukacji i Nauki z dnia 21 grudnia 2021 r. Lp. 32343. Posiada Unikatowy Identyfikator Czasopisma: 201159. Przepisane dyscypliny naukowe: Nauki o kulturze fizycznej (Dziedzina nauk medycznych i nauk o zdrowiu); Nauki o zdrowiu (Dziedzina nauk medycznych i nauk o zdrowiu). © The Authors 2023: This article is published with open access at Licensee Open Journal Systems of Nicolaus Copernicus University in Torun, Poland Open Access. This article is distributed under the terms of the Creative Commons Attribution Noncommercial License which permits any noncommercial use, distribution, and reproduction in any medium, provided the original author (s) and source are credited. This is an open access article licensed under the terms of the Creative Commons Attribution Non commercial license Share alike. (<http://creativecommons.org/licenses/by-nc-sa/4.0/>) which permits unrestricted, non commercial use, distribution and reproduction in any medium, provided the work is properly cited. The authors declare that there is no conflict of interests regarding the publication of this paper. Received: 24.06.2023. Revised: 30.06.2023. Accepted: 20.07.2023. Published: 25.07.2023.

## GASTROINTESTINAL TRACT CARCINOID WITH CARCINOID SYNDROME IN 63-YEAR-OLD DIVER – A CASE REPORT

### Authors' names

1. Hanna Dominik MD, University Hospital of Zielona Gora, Zyty 26 65-046 Zielona Gora, Poland, ORCID:0000-0003-0371-2276, [hania.dominik31@gmail.com](mailto:hania.dominik31@gmail.com)
2. Wojciech Pawęska MD, District Hospital, Krakowska 31 32-700 Bochnia, Poland, ORCID: 0009-0007-0836-4983, [wojciech.paweska@gmail.com](mailto:wojciech.paweska@gmail.com)
3. Barbara Dominik MD, PhD, University Hospital in Zielona Gora, Zyty 26 65-046 Zielona Gora, Poland, ORCID:0000-0002-3926-3583, [barbaradominik48@gmail.com](mailto:barbaradominik48@gmail.com)

### Corresponding author

Hanna Dominik MD, University Hospital of Zielona Gora, Zyty 26 65-046 Zielona Gora, Poland, ORCID: 0000-0003-0371-2276, [hania.dominik31@gmail.com](mailto:hania.dominik31@gmail.com)

### ABSTRACT

**Introduction:** Carcinoid is a tumor that originates from neuroendocrine cells.<sup>[1]</sup> It was primarily named and described in 1907 by Siegfried Oberndorfer to characterize neoplasms located in GIST with a relatively indolent course.<sup>[2]</sup> Term “carcinoid” is now used to describe neuroendocrine neoplasms, a subset of rare tumors, mostly sporadic, which are typically located in gastrointestinal tract but they may also appear beyond it (e.g. in thymus or lungs).<sup>[2,3]</sup> NET's are highly differentiated and usually hormonally active. Biochemical proof of their presence can consist of a measurement of the released substances – serotonin, bradykinin, histamine, etc.<sup>[3]</sup>

Carcinoid tumors derive from serotonin-producing enterochromaffin cells.<sup>[1]</sup> They contain high quantities of tryptophane that is transformed later into serotonin. This biogenic amine is responsible for occurrence of so called- carcinoid syndrome. It manifests with hot flushes, diarrhea, tachycardia, vertigo and excessive sweating.<sup>[3]</sup> The attacks usually last from 0,5 minutes up to half an hour and they can be triggered by food or alcohol consumption, liver palpation or general anesthesia. Due to excessive serotonin production, long lasting carcinoid might lead to right endocardial fibrosis with tricuspid valve and pulmonary valve dysfunction.<sup>[4]</sup>

**Aim:** The aim of this case report is to present a clinical course, diagnostic process and outcome in 63-year-old professional diver with carcinoid syndrome.

**Description of the case:** The following case describes the clinical history, diagnostic process, imaging studies and treatment applied to 63-year-old male professional diver who was admitted to University Hospital of Zielona Góra with a clinical picture that resembled carcinoid syndrome. The final diagnosis- carcinoid originating from the ileum- was settled after performing multiple studies. The patient was referred to the department of Endocrinology and Neuroendocrine Tumors in Silesian University Center in Katowice. He initiated therapy with SomatulineAutogel. The Tumor Board was conducted in order to determine the optimal treatment for the patient.

**Keywords:** Carcinoid, Carcinoid syndrome, Serotonin, Neuroendocrine Tumors, Carcinoid Heart Disease

## CASE REPORT

A middle-aged professional diver presented himself to the admission room of the department of Internal Diseases in Clinical Hospital of Zielona Góra. The admission took place on 27.12.22 and was scheduled for diagnostics purposes. The patient was suffering from dyspnea and shortness of breath while diving. He claimed that these symptoms have been persisting for 3 months and were strongly affecting his work as he was forced to emerge much earlier than before. He noticed as well, intermittent flush on the whole body that was usually the most expressed after warm showers. He was reporting diarrheas that has been appearing for years and were without connection to the food that he consumed. For the past 2 years he has been feeling tenderness in the upper abdomen. Due to it, the abdominal USG and CT were performed 2 years ago. These studies revealed multiple solid hepatic masses, some of which were with features of decay. CT showed polycyclic

masses in the epigastrium. At that time, the patient did not undertake any further diagnostic steps nor was he treated.

Upon admission, he presented as a normally built, well-nourished man. He had a flush marked on the face, chest, abdomen, thighs and a cyanosis of the nose tip and around lips. Right nuchal, left cervical and left axillary lymph nodes were palpable. The liver was palpable 3 cm below the costal margin. Systolic-diastolic murmur was audible at Erb's point. Further physical examination did not reveal abnormalities. He did not present signs of infection, his body temperature and vital signs were within the normal range.

He was admitted to the department of Internal Diseases in a good clinical state with a high suspicion of neuroendocrine tumor with carcinoid syndrome of unknown origin.

The hospitalization lasted until 30.12.2022 and the patient was discharged home in a good clinical state on a fourth day. The diagnostic process was based on performing laboratory test, imaging and histopathological examination. The results were as follows.

**Laboratory tests:** Venous blood tests revealed high serum serotonin level – above 1000 ug/l (normal range 80-400ug/l), chromogranin A level at 438, 87 ng/ml (normal range up to 100 ng/ml). Urine analysis revealed elevated amount of 5-OH indoloacetic acid in daily urine collection- 70 mg/24 hrs (normal range 2-9 mg/24hrs).

**ECG:** This patient's ECG revealed left axis deviation, sinus rhythm of 64bpm, biphasic T wave with dominant negative phase in leads II, aVF and V6. Residual R waves in II, III, aVF and lack of R wave progression in precordial leads were noted. All of these changes are not specific or suggestive of carcinoid heart disease.

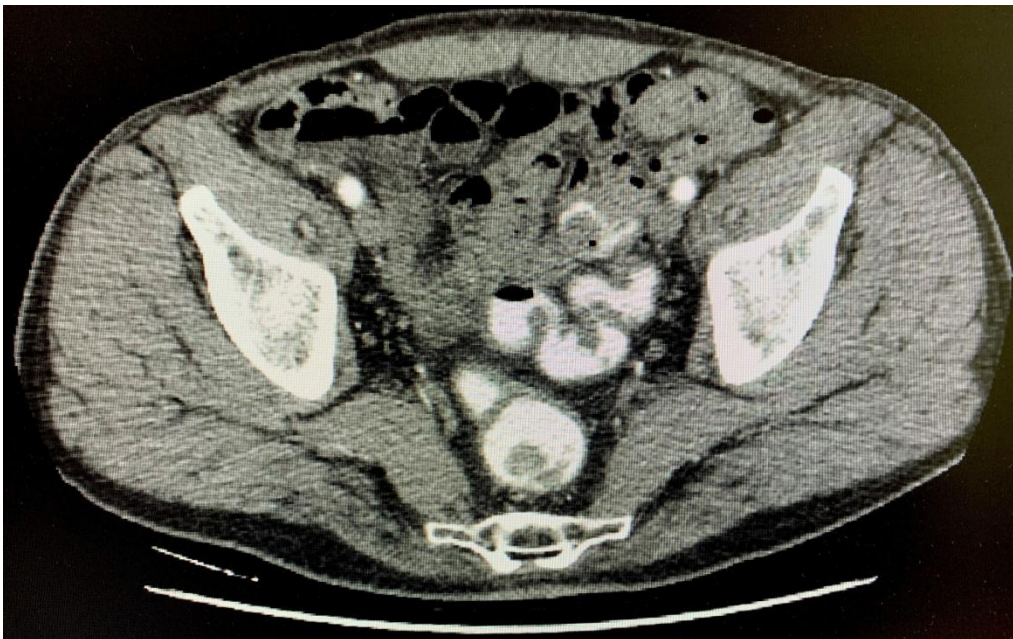**Chest RTG:** Performed AP and lateral chest RTG showed slight adhesions at apex and base of the lungs, normal cardiac silhouette and calcification in the aortic arch.

**ECHO:** Echocardiography is a contributive method of imaging when diagnosing patients with carcinoid heart disease. The measurements taken in this patient were as follows: LA 39mm, Ao 37mm, RV 32mm, LVEDD 46mm, LVESD 34mm, EF 50%, IVS 14mm. Examination showed morphologically and functionally intact mitral valve. Small calcifications were observed on aortic valve, but were not causing significant stenosis. Mild aortic insufficiency was detectable. Tricuspid valve leaflets were thickened and lacked coaptation. This resulted in severe tricuspid regurgitation. There was a 2nd degree insufficiency of pulmonary valve. Highly suggestive of pulmonary hypertension were RVSP of 60mmHg and decreased AcT of 85ms. TAPSE amounted to 19mm which lies in a normal

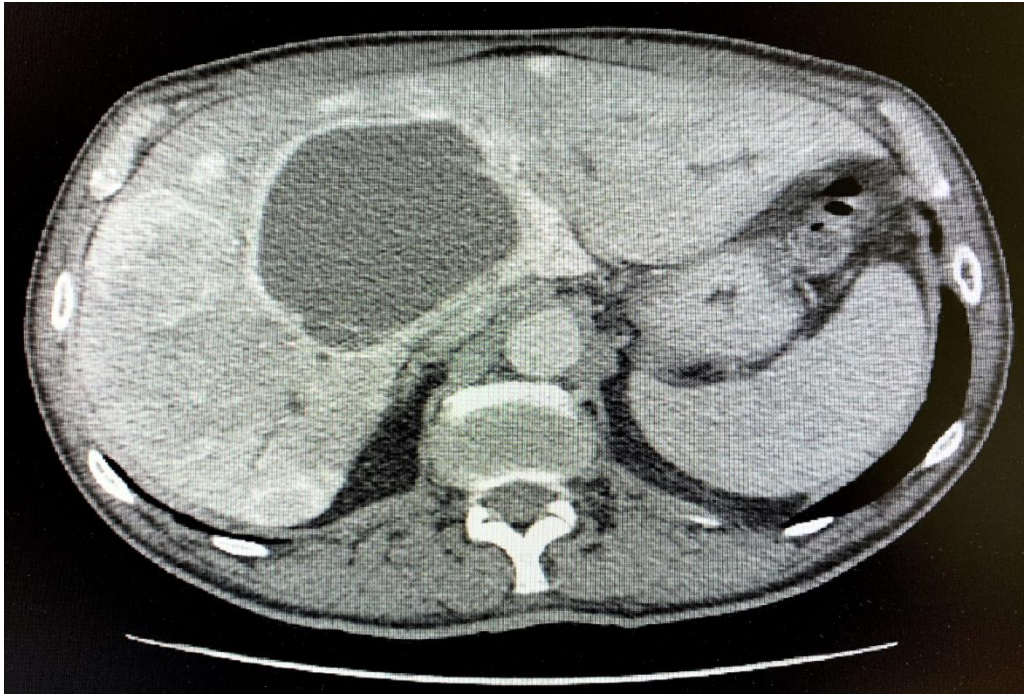
range. Diastolic function of left ventricle was impaired and hypokinesis of interventricular septum was detected. There was a trace of fluid in pericardial sac.

Some of these findings are suggestive of carcinoid heart disease.

**CT:** CT of thorax, abdomen and pelvis revealed a cystic lesion with a tissue component located at the border of segment VIII, segment IV and segment I of the liver. It measured 89x85 mm and showed enhancing after intravenous administration of contrast. Additionally, many uncountable contrast-enhancing metastatic lesions were visible in both lobes of the liver. Hepatic veins were slightly dilated with retrograde contrast enhancing (probably due to tricuspid insufficiency). Lymph nodes of up to 15mm were detected along the root of mesentery. Small intestine loops were piecewise thickened at the length of 20mm and showed contrast enhancement. This part was thought to be a primary lesion. At the level of this lesion, an enlarged lymph node measuring 20x24mm was detected. A trace of fluid between intestinal loops and at the lower border of right liver lobe was noticed. In the body of L3 vertebra a meta-suspicious lesion which penetrated to spinal canal and compressed the roots of spinal nerves was described.



*Figure S1. Primary lesion- thickening of small intestine loops with contrast enhancement and enlarged lymph node*



*Figure S2. Cystic lesion with tissue component and contrast-enhancing metastatic lesions in the liver*

On 28.12.22 the percutaneous needle biopsy of the liver was performed.

**Biopsy of the liver:** On the histopathological sample under evaluation, a neoplastic tissue was visible. It derived from a monomorphic population of cells forming beaded structures. The microscopic image was typical for NEN's G2 metastases originating from gastrointestinal tract.

The patient was discharged home in a stable clinical state. The handover of the patient for further complementary diagnostics and treatment was established with Clinic of Endocrinology and Neuroendocrine Tumors in Silesian University Center in Katowice. There, the patient had a (09.03.23) PET/CT with  $^{68}\text{Ga}$  performed.

**PET:** Study was conducted using  $^{68}\text{Ga}$ -DOTATATE with activity of 102 MBq. There were no meta-suspicious lesions in the area of head, neck and thorax. In abdominal cavity few areas of increased SUV were detected:

- In a lymph node below the area of ascending duodenum (SUVmax 25,80).
- In soft-tissue densities adjacent to small bowel between umbilical region and hypogastrium just below aortic bifurcation (SUVmax 43,63).
- In left and right lobes of the liver. There were more than 10 foci of increased SUV (SUVmax 43,17) at the border of segments II, IV and I. A big lesion measuring 98x86mm with no radioactive uptake in the centre suggestive of necrotic area was detected.

Additionally, metastatic lesions were found in a right 5th rib and bodies of vertebrae Th10 and L3.

Study revealed metastasized NEN tumor of small bowel with high expressivity of somatostatin receptors. There were many metastases to liver, bones and lymph nodes graded 3 and 4 on Krenning's score.

The patient was put on a therapy with somatostatin analogue (Somatuline Autogel 120 mg) consisting of subcutaneous injections every 28 days.

After additional test and specialistic consultations the Tumor Board was conducted. The assembly proposed the following procedures:

- Further treatment with somatostatin analogue
- Additional 18F- FDG PET scan
- Prompt radiotherapy of L3 vertebral body and channel
- Qualification for surgical treatment- excision of primary tumor in ileum followed by systemic chemotherapy – CAPTEM scheme.

## **DISCUSSION**

Carcinoid tumors are rare neuroendocrine tumors primarily occurring mostly in a small intestine or lungs.<sup>[2]</sup>They are often underdiagnosed and remain clinically silent until metastasized. After metastasizing to the liver, the hormones (e.g. serotonin) they produce get access to systemic circulation and cause carcinoid syndrome.<sup>[11]</sup>

Usually, carcinoid syndrome develops in 8% of the patients with carcinoid tumors.<sup>[4]</sup>Overall survival median in patients with carcinoid syndrome is lower than in those without CS - 4,7 years compared to 7,1 years.<sup>[4]</sup> Moreover, carcinoid heart disease is present in 20 to 50% of patients with carcinoid syndrome.<sup>[4,5]</sup>

Involvement of right-sided heart valves with severe tricuspid regurgitation is a common finding in patients with disseminated carcinoid tumors. Involvement of tricuspid and pulmonary valve affects around 85% and 60% of patients with carcinoid heart disease respectively.<sup>[6]</sup>ECG in patients with carcinoid heart disease is normal in 30 to 50% of patients.<sup>[7]</sup> In some patients ECG can show ST elevation due to serotonin-induced coronary vasospasm, PR prolongation, sinus tachycardia and low voltage QRS complexes.<sup>[8][9]</sup> Approximately 12-74% of the patients with NET's present liver metastases, which are a negative predictor in final outcome.<sup>[10]</sup>

The main goals of treatment in patients with carcinoid are reduction of hormone levels produced by tumor and management of carcinoid heart disease if present.<sup>[5]</sup>

To sum up, the patient in the presented case have developed carcinoid syndrome with typical features. NET originated from gastrointestinal tract. He is now treated with somatostatin analogue. He is under supervision of highly specialized center.

## **DECLARATIONS**

### **Funding**

This research did not receive any specific grant.

### **Author contributions**

Conceptualization, H.D., W.P.; Methodology B.D.; Validation, H.D. and B.D; Formal Analysis, H.D, W.P.; Investigation B.D; Resources, H.D., B.D.; Data curation, H.D., W.P.; Writing – Original Draft Preparation, H.D., W.P.; Writing – Review & Editing, H.D., W.P.; Visualization, B.D.; Supervision, B.D. ; Project Administration, B.D.

### **Conflicts of interest**

The authors have no known competing financial interests or personal relationships that could have appeared to influence the work reported in this manuscript.

### **Institutional Review Board Statement**

Not applicable.

### **Informed Consent Statement**

Informed and signed consent was obtained from all subjects involved in the study.

### **Data availability**

The data have not been made public, but are kept with the authors, if necessary.

### **Ethics approval**

Written informed consent for publication was obtained from the patient. We complied with the policy of the journal on ethical consent.

## References:

1. Dias AR, Azevedo BC, Alban LBV, Yagi OK et al. Gastric Neuroendocrine Tumor: Review and Update. *Arq Bras Cir Dig.* 2017 Apr-Jun;30(2):150-154. doi: 10.1590/0102-6720201700020016
2. Burkitt MD, Pritchard DM. Review article: Pathogenesis and management of gastric carcinoid tumours. *Aliment Pharmacol Ther.* 2006 Nov 1;24(9):1305-20. doi: 10.1111/j.1365-2036.2006.03130.x. PMID: 17059512
3. Grozinsky-Glasberg S, Davar J, Hofland J, Dobson R, et al. European Neuroendocrine Tumor Society (ENETS) 2022 Guidance Paper for Carcinoid Syndrome and Carcinoid Heart Disease. *J Neuroendocrinol.* 2022 Jul;34(7):e13146. doi: 10.1111/jne.13146. Epub 2022 May 25.
4. Ito T, Lee L, Jensen RT. Carcinoid-syndrome: recent advances, current status and controversies. *Curr Opin Endocrinol Diabetes Obes.* 2018 Feb;25(1):22-35. doi: 10.1097/MED.0000000000000376.
5. Davar J, Connolly HM, Caplin ME, et al. Diagnosing and Managing Carcinoid Heart Disease in Patients With Neuroendocrine Tumors: An Expert Statement. *J Am Coll Cardiol.* 2017;69(10):1288-1304.
6. Moerman VM, Dewilde D, Hermans K. Carcinoid heart disease: typical findings on echocardiography and cardiac magnetic resonance. *Acta Cardiol.* 2012 Apr;67(2):245-8. doi: 10.1080/ac.67.2.2154218. PMID: 22641985.
7. Pellikka PA, Tajik AJ, Khandheria BK, et al. Carcinoid heart disease. Clinical and echocardiographic spectrum in 74 patients. *Circulation.* 1993;87:1188–1196.
8. Eapen DJ, Clements S Jr, Block P, Sperling L. Metastatic carcinoid disease inducing coronary vasospasm. *Tex Heart Inst J.* 2012;39(1):76–8 1526-6702
9. Davar J, Connolly HM, Caplin ME, et al Diagnosing and Managing Carcinoid Heart Disease in Patients With Neuroendocrine Tumors: An Expert Statement. *J. Am. Coll. Cardiol.* . 2017. Elsevier USA, 69: 1288–1304
10. Gangi A, Howe JR. The Landmark Series: Neuroendocrine Tumor Liver Metastases. *Ann Surg Oncol.* 2020 Sep;27(9):3270-3280. doi: 10.1245/s10434-020-08787-x. Epub 2020 Jul 6.
11. Rubin de Celis Ferrari AC, Glasberg J, Riechelmann RP. Carcinoid syndrome: update on the pathophysiology and treatment. *Clinics (Sao Paulo).* 2018 Aug 20;73(suppl 1):e490s. doi: 10.6061/clinics/2018/e490s.