

University of Nebraska - Lincoln

DigitalCommons@University of Nebraska - Lincoln

H. W. Manter Laboratory Library Materials

Parasitology, Harold W. Manter Laboratory of

1902

On a Coccidium (*Klossiella muris*, gen. et spec. nov.) Parasitic in the Renal Epithelium of the Mouse

Theobald Smith
Harvard University

Herbert P. Johnson
Harvard University

Follow this and additional works at: <https://digitalcommons.unl.edu/manterlibrary>



Part of the [Parasitology Commons](#)

Smith, Theobald and Johnson, Herbert P., "On a Coccidium (*Klossiella muris*, gen. et spec. nov.) Parasitic in the Renal Epithelium of the Mouse" (1902). *H. W. Manter Laboratory Library Materials*. 107.
<https://digitalcommons.unl.edu/manterlibrary/107>

This Article is brought to you for free and open access by the Parasitology, Harold W. Manter Laboratory of at DigitalCommons@University of Nebraska - Lincoln. It has been accepted for inclusion in H. W. Manter Laboratory Library Materials by an authorized administrator of DigitalCommons@University of Nebraska - Lincoln.

ON A COCCIDIUM (*KLOSSIELLA MURIS*, GEN. ET
SPEC. NOV.) PARASITIC IN THE RENAL
EPITHELIUM OF THE MOUSE.

BY THEOBALD SMITH, M. D., AND HERBERT P. JOHNSON, PH. D.

(From the Laboratory of Comparative Pathology, Medical Department of Harvard
University).

PLATES XXI-XXIII.

In 1889 one of us¹ published a preliminary description of a polysporous coccidium found in the epithelium of the convoluted tubules of the mouse's kidney. Several stages of the parasite were seen but the scantiness of the material left many gaps in the life-cycle. During investigations recently made to determine the mode of transmission of the Sarcosporidium of the mouse one of us² found a considerable number of gray mice, caught in the animal room connected with this laboratory, whose kidneys were abundantly invaded by this coccidium. This favorable opportunity of examining more thoroughly into the life-history of this sporozoon was utilized, and, as a result, we are able to add materially to the knowledge of this cell parasite. In the following pages some details given in the first paper will be repeated to avoid obscurity in the descriptions as well as to aid those to whom the first paper is inaccessible.

Thus far we have found only adult mice infected. The invaded kidneys are a trifle enlarged and the surface is faintly uneven. The most characteristic feature is a very delicate mottling of the whole surface with minute, barely visible, grayish specks. This appearance of the kidneys may be considered almost diagnostic of the presence of the parasite.

¹ Smith. *Journal of Comparative Medicine and Surgery*, 1889, x, p. 211.

² Smith. *Journal of Experimental Medicine*, 1901, vi, p. 1.

METHODS.

To study the parasite in the fresh state a bit of the cortex is teased in physiological salt solution on a slide and gently spread by pressure on the cover-glass. This simple procedure enables us to gain an insight into that portion of the life-cycle of *Klossiella* through which it passes in the renal tubules, for, as a rule, all stages are present in the same heavily-infected kidney. Even the nuclei can be made visible by treatment with aceto-methyl green.³ Schneider's aceto-carmin has been found less satisfactory as a nuclear stain for fresh material. Kidneys intended for sectioning were halved lengthwise, fixed and hardened in Zenker's fluid for 24 hours, washed in running water for the same period, and then passed through 50 and 70 to 95 per cent alcohol. Other fixing agents were tried (Flemming's fluid, aceto-sublimate, and picro-acetic), but they possessed no advantages over Zenker's fluid. The tissue was embedded in paraffine, melting at 51°-53° C., and cut in ribbons. Sections as thick as 10-15 μ were occasionally useful, as each section included more of the parasite, which, owing to its minuteness, is not easily studied in serial sections.

The most useful stains have been ferric-alum hæmatoxylin and Mayer's hæmatate of ammonia (hæmalum), the latter used alone or followed by Van Gieson's picro-acid fuchsin. The latter, however, can only be used after prolonged staining with the hæmalum, otherwise it will completely mask the nuclear stain. Fine results are obtained by staining with eosin followed by Unna's polychrome methylene blue. Ferric-alum hæmatoxylin gives by far the clearest and sharpest picture of any stain, but certain delicate differentiations of the cytoplasm are best brought out by prolonged staining (24 hours or longer) with hæmalum followed by picro-acid fuchsin.

THE DEVELOPMENTAL STAGES OF *KLOSSIELLA MURIS*.

An adequate description of the various stages found in the kidney will necessitate a certain order beginning with the earliest stage we have seen. Before proceeding to such a detailed account it may be well to summarize very briefly the life-cycle as we now know it.

³ Glacial acetic, 5 pts., distilled water 95 pts., methyl green to saturation.

The youngest parasite is a minute nucleated cell (sporont) found within the cytoplasm of the epithelial cells of the convoluted tubules. This cell enlarges, the nucleus divides into 12 or more daughter-nuclei which are next found near the now slightly-lobed or mammillated periphery of the parasite (mother-sporoblast). The cytoplasm now separates into 12 or more spheres with each nucleus as a centre (sporoblast stage). These spheres secrete a membrane (spore stage), and the contents of each spore break up into about 30 nucleated, falciform bodies (sporozoites). Each parasite thus produces in the kidney at least 360 individuals. In severe infections the convoluted tubules are frequently found blocked with these spores. The sporozoites are not set free in the kidneys, as intact spores are found in the bladder. The further life-history of this parasite remains conjectural, although it is highly probable that the spores enter the body with the food and that the sporozoites are set free in the digestive tract.

To this cycle must be added another body of different morphology, which is parasitic in the epithelium of Bowman's capsule and whose significance will be discussed later on.

A. THE PARASITE OF THE CONVOLUTED TUBULES (SPOROGONIC CYCLE).

1. *The earliest stage (sporont).*—In fresh teased tissue the invaded cells frequently become detached and in these the sporonts are best studied. The host cell is enlarged, pear-shaped, and the parasite lies within it, not in contact with the cytoplasm, but in a vacuole (Plate XXII, Fig. 3). Not infrequently 2 sporonts are contained in the same cell; each then lies within its own vacuole (Plate XXII, Fig. 5). The sporont measures $8\ \mu$ to $11.5\ \mu$ in diameter.

A very striking feature of the sporont is the storage of reserve food material in the form of spherical, highly refractive granules, to the number of 10 to 20 (Plate XXII, Figs. 3 and 4). These are usually accompanied by smaller granules of the same optical appearance and chemical properties (Plate XXII, Fig. 4). The large granules measure $1.5\ \mu$ in diameter, the smaller, $1\ \mu$ or less. The former disappear at or towards the close of the sporont stage; the latter per-

sist and even increase in number long after the daughter-sporoblasts are formed (Plate XXIII, Fig. 14), but there is no indication that the larger granules break up to form the small ones. The granules of both sorts are doubtless of a proteid nature and come under the head of "plastin granules" described by various students of the Sporozoa. They are highly resistant toward all the chemical agents with which we have tested them. It is in fact possible with strong mineral acids and alkalis to dissolve all the rest of the cell and still leave the granules intact. The large granules stain a vivid yellowish-green with aceto-methyl green; the smaller granules remain unstained. Schneider's aceto-carminé fails to stain either kind of granule. Iodine in a solution of potassium iodide gives them a yellowish tint, which remains unchanged on the addition of dilute sulphuric acid. They are not blackened by osmic acid, and are not dissolved by absolute alcohol. We conclude that they are neither of a starchy nor of a fatty nature but a highly resistant proteid, such as is known to occur widely among Sporozoa.*

In fixed and stained preparations the shrinkage has usually obliterated the vacuole in which the sporont lies. The latter appears as if embedded in the cytoplasm of the host (Plate XXII, Figs. 5 and 7). Concerning the mode of invasion of the host cell by the sporozoite we are unable to give any facts. The parasite, when first seen, was already spherical in form and $7\ \mu$ in diameter. At this stage the invaded cells are considerably increased in size and have assumed the characteristic flask shape (Plate XXII, Fig. 7), with the parasite near the broad distal end of the flask. As the parasite grows the host cell must continue to grow. It protrudes far into the lumen of the tubule, almost occluding it, and it may even cause a local enlargement of the lumen (Plate XXII, Fig. 7). The peduncle by which the cell maintains its attachment to the basement membrane and through which it derives nourishment becomes more and more slender and assumes a very characteristic granular appearance (Plate XXII, Fig. 7, and Plate XXIII, Fig. 13). This portion stains darkly with hæmatoxylin

* Bütschli, Protozoa. Bronn's Thierreich, I, Abth. 1, p. 517, Leipzig and Heidelberg, 1882. Wasielewski, Sporozoenkunde, 1896, p. 51.

and micro-acid fuchsin. The cell nucleus becomes more and more flattened, owing to the pressure of the parasite, and is displaced to one side (Plate XXII, Figs. 7, 10, 11, and Plate XXIII, Figs. 13, 14). Sometimes it is moulded cup-like upon the surface of the sporont (Plate XXII, Fig. 7, infected cell on the right); sometimes it appears shrunken or entirely flattened by the pressure of the sporont (Plate XXII, Fig. 7, infected cell on the left).

The nucleus of the young sporont is generally eccentric in position (Plate XXII, Figs. 3, 7) and contains one or two highly-refractive, deeply-staining karyosomes. Usually at this stage and later a clear, non-staining area (karyolymph) surrounds the karyosome and the chromatic mass within or on the edge of which the karyosome lies. The nucleus may undergo a precocious division and the daughter-nuclei distribute themselves near the periphery of the sporont (Plate XXII, Fig. 5). This arrangement is seen much more clearly in the mother-sporoblast stage (Plate XXII, Figs. 6 and 7), and is obviously the precursor of the formation of daughter-sporoblasts.

2. *The formation of spores (stage of mother-sporoblast and sporoblast).*—In the mother-sporoblast stage the parasite has increased much in size, measuring $40\ \mu$ in diameter in the fresh condition. At this stage there are sometimes 2 to 4 karyosomes in each nucleus, indicating a precocious segmentation of chromatic material preparatory to the formation of sporozoites (Plate XXII, Figs. 6 and 7).

The nucleus is now in the most favorable condition for study, but on account of its minuteness we have learned very little about it. Figs. 8 and 9 (Plate XXII) represent the usual conditions met with. The nucleus may be defined as a vesicle filled with clear fluid within which are the chromatin mass and one or sometimes two karyosomes. Sometimes karyosomes only are seen (Plate XXII, Fig. 9). When there are two, one is usually much smaller than the other, and stains darker. Not the slightest indication of mitotic phenomena has been seen. The vesicular structure of the nucleus is not retained apparently beyond the mother-sporoblast stage. In all later stages we have found merely one or more round, intensely-staining bodies to all appearances identical with the karyosomes of earlier stages.

The mother-sporoblast stage is marked by a migration of the nuclei to the periphery. They are usually spaced more evenly than Fig. 6 (Plate XXII) would seem to indicate. At this stage there are often 2 to 4 karyosomes in each nucleus (Plate XXII, Figs. 6 and 7). The cytoplasm surrounding each nucleus begins to be segmented off from the rest and forms a boss on the surface of the mother-sporoblast (Plate XXII, Fig. 10). For a brief period the daughter-sporoblasts are arranged in the form of a rosette (Fig. 1, lower left-hand corner). This is due to the centrifugal mode of development of the daughter-sporoblasts, as clearly shown in the figures just mentioned. They appear to bud out from the central mass, now entirely devoid of nuclei, and then rapidly to resorb the greater portion of the mass in question while their peduncles of attachment become reduced. One or two residual masses of angular form are often seen at a later stage, wedged in among the brood of daughter-sporoblasts. In other cases there appears to be no restiform body and our conclusion is that it has been entirely resorbed by the daughter-sporoblasts. The latter, to the number of 6 to 14, rarely more, are soon entirely separate and free within the vacuole (Plate XXIII, Figs. 13 and 14). They are nearly spherical in shape and average 12μ in diameter, although smaller and possibly abortive ones are often found in the vacuole or cyst.

At this stage the host cell still maintains its attachment to the basement membrane by means of the much-attenuated peduncle. It nearly occludes the lumen of the tubule (Plate XXIII, Fig. 13). Its cytoplasm has been reduced to a mere shell enclosing the vacuole. The nucleus still persists.

3. *The formation of sporozoites.*—The nucleus of each daughter-sporoblast undergoes repeated divisions and these nuclear divisions are foreshadowed by divisions of the karyosomes at a stage considerably in advance of the formation of the sporoblasts themselves. These precocious divisions as well as those which come after the formation of the daughter-sporoblasts (Plate XXIII, Fig. 15) are preparatory to the elaboration of the sporozoites. These, to the number of 30 to 35, are so packed in the spore that most of them lie with their

long axes in one direction. The short axis of the spore is parallel to the long axis of the sporozoites (Plate XXIII, Figs. 16 and 17). In the fresh condition a ripe spore averages 16μ by 13μ . A transverse optical section (Plate XXIII, Fig. 18) shows that the sporozoites occupy very nearly all the space within the cyst. At an earlier stage than that represented in Fig. 18 a restiform body is seen within the spore. Before the spores are fully formed they may be seen attached to this body by one extremity (Plate XXIII, Fig. 17). It is probably entirely resorbed by the sporozoites.

The sporozoites are rather strongly curved and are blunt at both ends (Plate XXIII, Fig. 19). They measure 7μ in a straight line from tip to tip and 3μ in thickness. The nucleus is located midway of the length and is frequently elongated (Plate XXIII, Fig. 16). In the fresh state the sporozoite exhibits a number of granules, one of larger size than the rest often being seen at one extremity (Plate XXIII, Fig. 19). The living spores are always translucent enough to enable one to see the sporozoites within. This is not invariably true of spores in sectional material stained with ferric-alum hæmatoxylin. This stain is readily extracted from the cyst-walls of a certain number of the spores, but is retained by others to such a degree that they appear perfectly black (Plate XXI, Fig. 2 and Plate XXIII, Fig. 16). This difference we believe due to a slight increase in thickness or imperviousness of the cyst wall.

The spore membrane appears to be entirely structureless. In optical section, even with very high powers, it appears merely as a sharp line. Strong artificial digesting fluids (peptic and pancreatic) do not entirely dissolve it. It is not difficult to rupture it by cover-glass pressure and set free the sporozoites.

B. THE GLOMERULAR PARASITE.

In many of the glomeruli of certain heavily-infected kidneys we have seen a parasite of considerably larger dimensions and irregular lobate form (Plate XXI, Fig. 1, lower right corner, and Plate XXIII, Fig. 20). Its habitat is the thin epithelium—usually the visceral layer—of Bowman's capsule. It encroaches inward strongly on the glomerulus.

Only a few stages in the development have been seen. That represented in Fig. 20 (Plate XXIII) is perhaps the commonest. Every gradation between this and the later stage shown in Fig. 21 has been found, but earlier stages are extremely rare. After prolonged search we have found only one example of what corresponds to the very young or sporont stage of the tubule parasite. This had a large, oval, strongly-stained nucleus with a single karyosome. The parasite was embedded by a little more than half its diameter in a much-thickened region of Bowman's capsule close to the neck. As we have seen no intermediate stages between this and that shown in Fig. 20, we cannot positively assert that these two are genetically connected. Between the stages represented in Figs. 20 and 21 every intermediate condition has been seen. Masses of protoplasm are segmented off around each one of the numerous nuclei and each mass becomes eventually transformed into a falciform body. These are somewhat variable in size and shape, as shown in Fig. 21. On account of this variability it is difficult to state their dimensions. Perhaps $7\ \mu$ by $2\ \mu$ is a fair average.

How shall the glomerular body be interpreted? While we have failed to prove even that it belongs to the same species as the parasite in the convoluted tubules, there is very strong presumptive evidence that it does, inasmuch as we have not found it in any kidney not infected with *Klossiella muris*. On the other hand, we have failed to find it in certain lightly-infected kidneys.

The glomerular parasite may be brought within the cycle of *Klossiella muris* in one of two distinct rôles. In the first place, it may represent the schizogonic or Eimerian cycle of the species, and as such may antedate the whole sporogonic cycle of the tubules. If this be true the falciform bodies shown in Fig. 21 represent the merozoites, and the infection of the tubular epithelium is due entirely to the passage of these with the secretion along the tubule until a suitable host cell is found, into which the merozoite penetrates.

Another interpretation would regard this as the male element (mother-microgametocyte), in which the falciform bodies represent the microgametocytes and from the latter the microgametes may

arise somewhat as described by Siedlecki⁵ for *Adelea ovata*, i. e. after the microgametocyte has reached the macrogamete. In one instance we have seen a falciform, nucleated body adherent to a young sporont, and in two or three instances, in fresh material, a granular-looking body in the same position. As we have not seen any flagellated bodies or the penetration of a nucleus into the female element, we lack the necessary evidence that the adherent body in question is actually the male element.

C. THE PROBABLE LIFE-CYCLE OF *Klossiella muris* ACCORDING TO THE PRECEDING INVESTIGATIONS.

We have suggested two quite divergent interpretations of the glomerular parasite neither of which is in conflict with our present knowledge of Coccidia. If we interpret this body as the male element its position in the capsular epithelium is almost a necessary one for it to occupy in order that the microgametocytes may reach the tubular epithelium. If we accept the interpretation that the glomerular parasite represents the asexual or so-called Eimerian cycle which furnishes the means for an internal multiplication, or, pathologically speaking, an auto-infection of limited extent, the position of the body in the glomerulus is still a prerequisite for the success of the next stage, the invasion of the tubular epithelium by the resulting merozoites. The final interpretation probably will not be made until analogous forms in other species of coccidia shall have been discovered in which the significance of the two stages may be subjected to demonstration. This species seems to be the first one in which two forms, genetically related, occupy epithelial cells of somewhat different morphological and physiological characters.

The spores, as already stated, pass out in the urine and are most likely taken in by mice in the food and water. Direct infection is inferred from the large percentage of infected mice which are found in cages where numbers have been living together for several months at least. This observation frequently made by one of us in the study

⁵*Annales de l'Institut Pasteur*, 1899, xiii, p. 169.

of sarcosporidiosis led to a number of feeding experiments with infected kidneys. The method of feeding and of keeping the mice under observation was the same as that used in the study of *Sarcocystis muris*, to which the reader is referred for details.⁶ Only kidneys containing spores with fully-developed sporozoites were used. These were finely divided and mixed with crumbs of bread softened in physiological salt solution. The dish containing this food was placed in the jar with the mouse or mice to be infected. The limited number of experiments furnished no conclusive evidence. Only one deserves mention.

A mouse fed December 18, 1900, was killed February 16, 1901. The kidneys, carefully examined fresh and in sections, contained young stages only. In the spontaneous cases early and advanced stages occur together, suggesting repeated infection. In this the occurrence of only one stage is what we should expect from a single infection.

The falciform bodies (sporozoites) set free in the digestive tract probably bore their way into the circulation which carries them into all parts of the body. Their minute size permits them to enter the smallest capillaries. In the kidneys they leave the capillaries in the glomerulus to invade the capsular epithelium and the epithelium of the convoluted tubules. In all other organs they are probably suppressed.

PATHOGENESIS.

The presence of cell-parasites like the one under consideration is evidently not indifferent to the organ in which they multiply and mature; and it remains for us to consider very briefly what injuries may be inflicted and what processes induced.

The youngest stage of the parasite (sporont) leads to the formation of a vacuole in the epithelial cell which increases with the growth of the parasite. Its very attenuated walls may still be seen after the formation of the sporoblasts. As the sporont enlarges into the mother-sporoblast and from this about 12 spores are segmented off, each larger than the original sporont as first seen within the cell, the

⁶ *Journal of Experimental Medicine*, 1901, vi, p. 1.

tubule within which the parasite is lodged becomes compressed, especially when a number of the parasites have matured close together. The compression causes the adjacent epithelium to disappear, and the tubule looks like an elongated contorted bag filled with spores but largely devoid of epithelium.

No so-called inflammatory reaction can be associated with these stages. The process is a mechanical one, leading to cell destruction. There is, however, another phenomenon associated with extensive invasion of the kidneys. These organs show over the entire surface a large number of minute grayish spots, already referred to. These minute spots represent foci of necrobiotic changes in the cortex, followed by marked cell proliferation in the same areas. The less advanced foci are largely made up of the tubular epithelium of the area which has become, as it were, fused into a mass on account of the obliteration of the lumina of the tubules. In later stages the original tissue becomes gradually obscured by the active proliferation of the intertubular tissue, giving rise to a dense collection of cell nuclei with scant cytoplasm. These foci resemble early foci in tuberculosis when giant cells are absent. The cells themselves correspond to what are usually called round cells. They often appear sheathing the larger blood-vessels of the cortex. The genesis of these foci is obscure, but they are probably due to *Klossiella muris*, as we have not seen them excepting in the presence of this parasite. It is probable that they represent older foci of invasion which had been abandoned by the ripe spores, and the devastated tubules have become the seat of an interstitial process which in its progress may envelope and obliterate neighboring normal tubules as well. Processes associated with acute inflammatory reactions were not encountered. Polynuclear leucocytes as well as exudations were absent.

SYSTEMATIC POSITION OF THE RENAL PARASITE.

The classification of the Coccidia has undergone more or less change in recent years. The last attempt by Schaudinn⁷ following Léger is perhaps the best. Of the 3 families there recognized, *Disporo-*

⁷ Untersuchungen üb. d. Generationswechsel bei Coccidien. *Zool. Jahrbuch., Abth. f. Morphol.*, 1900, xiii, p. 197.

cystidea, *Tetrasporocystidea*, and *Polysporocystidea*, the mouse parasite clearly belongs to the third. When we come to the genera our difficulty begins, for these are based on the contents of the individual spore. Sporocysts with 1, 2, 3 and 4 sporozoites are accounted for, but our parasite contains about 30 sporozoites. We have therefore preferred to create a new genus rather than enlarge the scope of any of the existing genera for its reception. We have named the new genus *Klossiella*,⁸ of which the type and only known species is *Klossiella muris*. The following is offered as a diagnostic description of the same:

Klossiella muris, gen. et spec. nov. Sporogonic cycle characterized by the development of 12 to 14 spheroidal spores, measuring $16\ \mu$ by $13\ \mu$, each of which contains 30 to 34 banana-shaped sporozoites.

Schizogonic cycle unknown, but a phase of unknown significance in the glomerulus.

Sporont with 10 to 20 spherical plastin granules, $1.5\ \mu$ in diameter, and smaller granules of the same physical and chemical properties. The latter persist until sporozoite-formation.

Habitat: Renal epithelium (convoluted tubules and glomerulus) of *Mus musculus*.

DESCRIPTION OF PLATES XXI-XXIII.

(The figures on Plate XXI are reproduced from photomicrographs made with the kind permission of Dr. J. H. Wright by Mr. L. S. Brown in the Clinico-pathological Laboratory of the Massachusetts General Hospital. The figures on Plates XXII and XXIII are from camera lucida drawings made with a Leitz 1/12 homogeneous immersion objective. The fixing agent in all cases was Zenker's fluid.)

PLATE XXI.

Fig. 1. Photomicrograph of an area in a section of the cortex of a heavily-infected kidney, showing *Klossiella muris* in the mother- and daughter-sporoblast stages. In the lower right-hand corner is a portion of a glomerulus, showing two parasites in different stages in the epithelium of Bowman's capsule. $\times 750$.

Fig. 2. Photomicrograph of an area of the cortex of the same kidney, showing sporocysts (spores). Some have resisted decolorization and appear

⁸ We are indebted to Dr. C. W. Stiles for suggesting to us the generic name *Klossiella* in place of the less accurate *Microklossia* which we had selected.

as black balls. In others the nuclei of the sporozoites can be made out distinctly. $\times 800$. (Both stained in ferric-alum hæmatoxylin.)

PLATE XXII.

Fig. 3. An infected cell from a fresh kidney, teased in salt solution and stained with aceto-methyl green. It contains a sporont within a large vacuole. The spherical refractive bodies in the sporont are plastin granules. $\times 850$.

Fig. 4. A sporont containing both large and small granules. In salt solution; unstained. $\times 850$.

Fig. 5. A double infection. The nucleus has already divided and become distributed towards the periphery. Hæmalum. $\times 737$.

Fig. 6. Mother-sporoblast, showing nuclei near periphery, containing one to four karyosomes and a mass of granular, less intensely-staining chromatin. Hæmalum. $\times 1435$.

Fig. 7. Longitudinal section of a portion of a convoluted tubule, with three infected cells almost occluding its lumen. The two cells to the right show the attachment of the infected cell by a narrow densely-granular peduncle to the basement membrane. The increase in size of the infected cells is clearly seen. Hæmalum and picro-acid fuchsin. $\times 870$.

Figs. 8 and 9. Nuclei of mother-sporoblast stage. $\times 1700$.

Fig. 10. Mother-sporoblast, with daughter-sporoblasts beginning to form. Shrinkage during fixation is probably responsible for the protrusion of one sporoblast beyond the normal contour. Hæmalum. $\times 1475$.

Fig. 11. A stage a little later than the preceding. The daughter-sporoblasts, each with its nucleus at its distal end, appear to bud out from a large central mass. Ferric-alum hæmatoxylin. $\times 1590$.

Fig. 12. The daughter-sporoblasts nearly complete, still attached by a narrow peduncle to central restiform body. Ferric-alum hæmatoxylin. $\times 1590$.

PLATE XXIII.

Fig. 13. Transverse section of convoluted tubule, with very large flask-shaped cell, containing *Klossiella* in the daughter-sporoblast stage. The infected cell nearly fills the lumen. It still retains its attachment to basement membrane by a narrow peduncle. Hæmalum; picro-acid fuchsin. $\times 870$.

Fig. 14. Infected cell from fresh kidney, in salt solution. It contains 14 sporoblasts in which the small plastin granules are conspicuous. The cell is more or less flattened by pressure of the cover-glass. $\times 850$.

Fig. 15. Small brood of sporoblasts, showing division and distribution of nuclei preparatory to formation of sporozoites. Hæmalum; picro-acid fuchsin. $\times 870$.

Fig. 16. Brood of spores still within cell-membrane of the completely atrophied cell. Six spores show the sporozoites within the cyst-wall; four are solidly stained and opaque. Ferric-alum hæmatoxylin. $\times 870$.

Fig. 17. Spore from fresh kidney, in salt solution, showing sporozoites still attached to restiform body. $\times 850$.

Fig. 18. More advanced spore, fresh. Aceto-methyl green. Transverse optical section. The nucleus appears in four sporozoites. $\times 850$.

Fig. 19. *a, b*, two sporozoites in fresh condition, liberated from spore cyst by crushing; *c*, sporozoite from a spore softened by peptic digestion. $\times 850$.

Fig. 20. Section of glomerulus, showing glomerular parasite *in situ* in visceral layer of Bowman's capsule. $\times 485$.

Fig. 21. Falciform bodies, oldest stage of glomerular parasite observed. Hæmalum, picro-acid fuchsin. $\times 1590$.

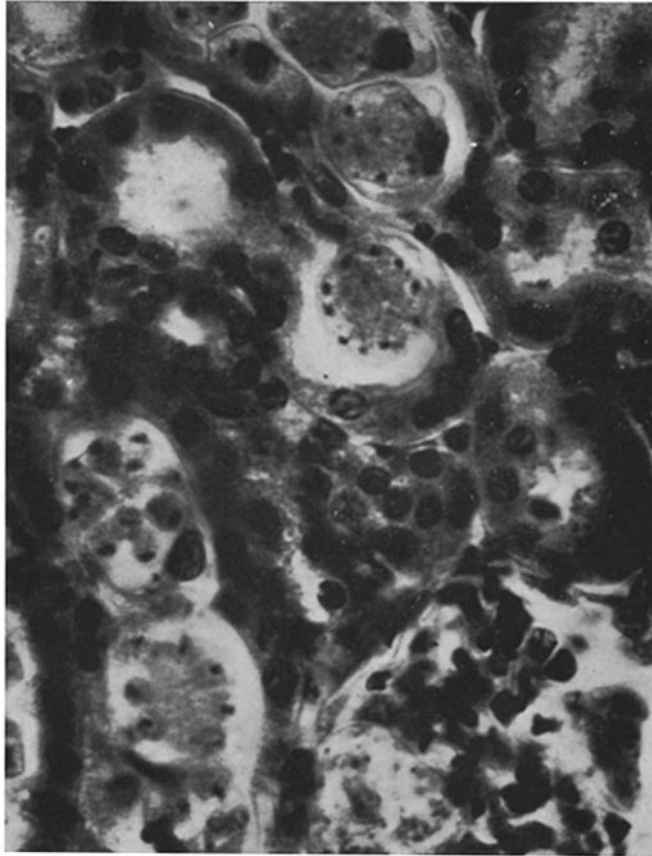


FIG. 1.

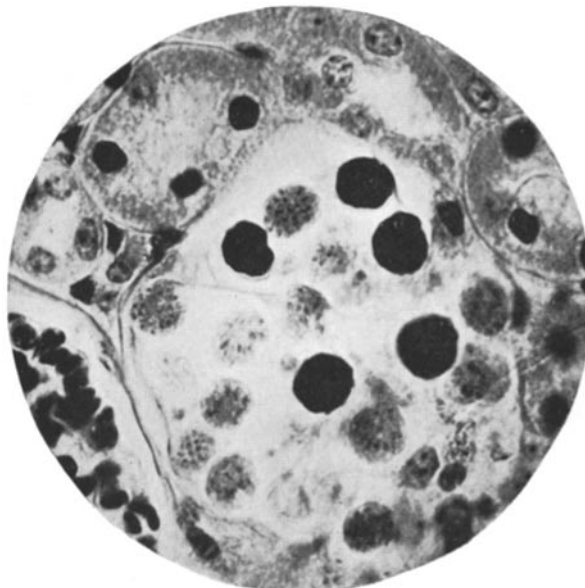
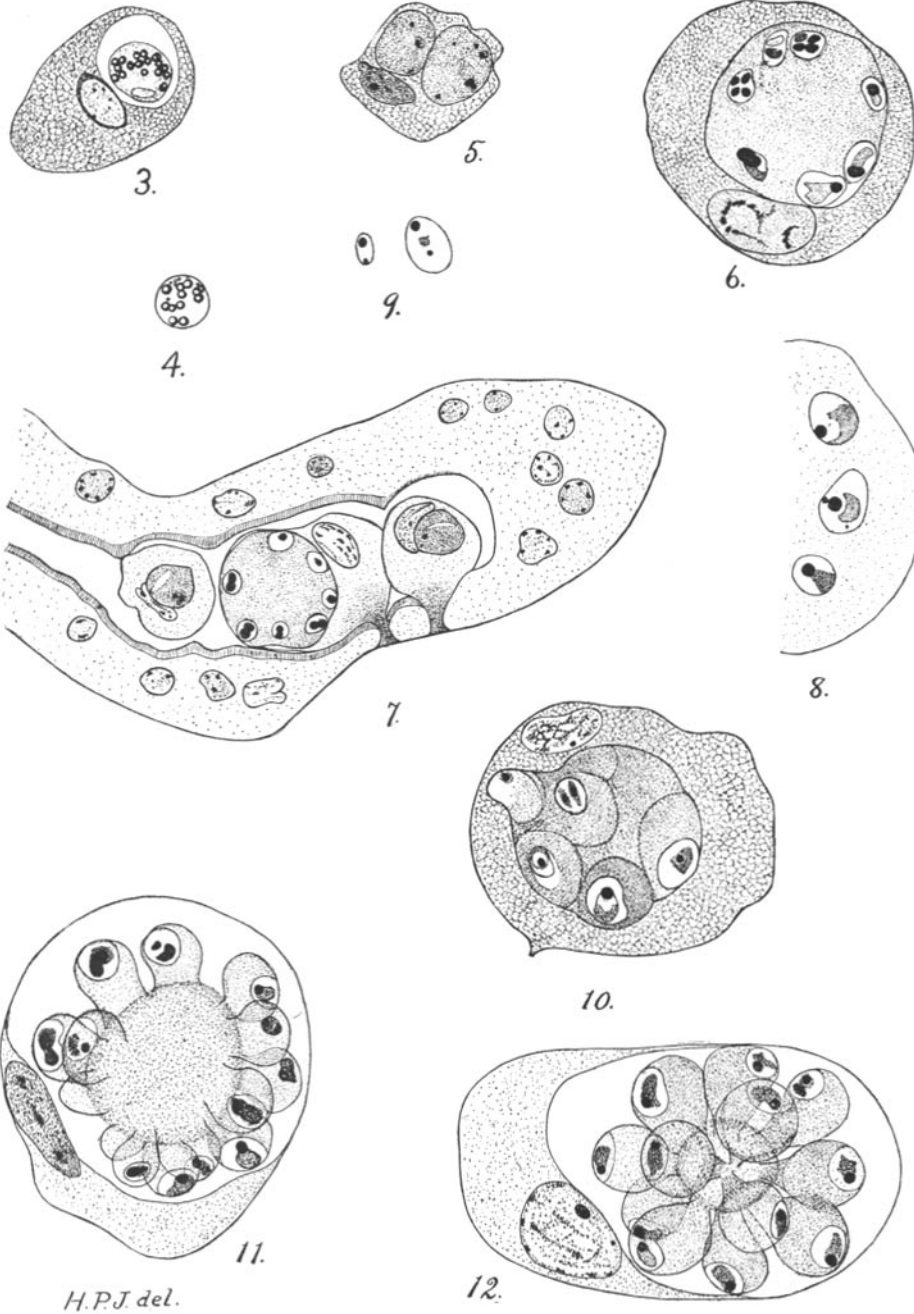
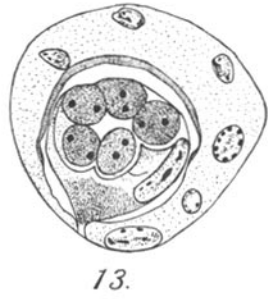
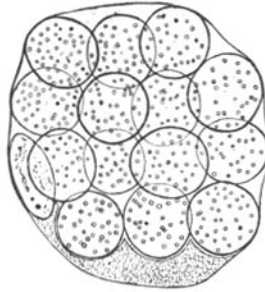


FIG. 2.

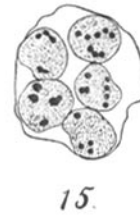



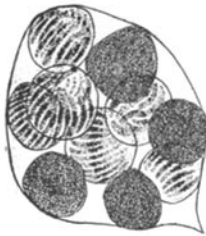13.



14.



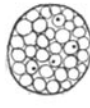
15.




16.



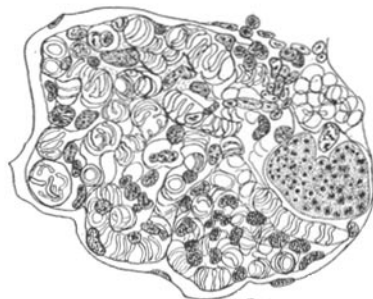17.



18.

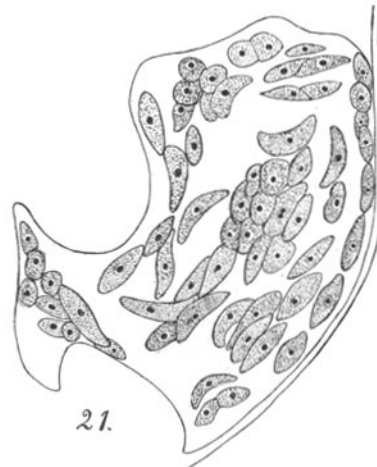

19.



H.P.J. del.

20.



21.