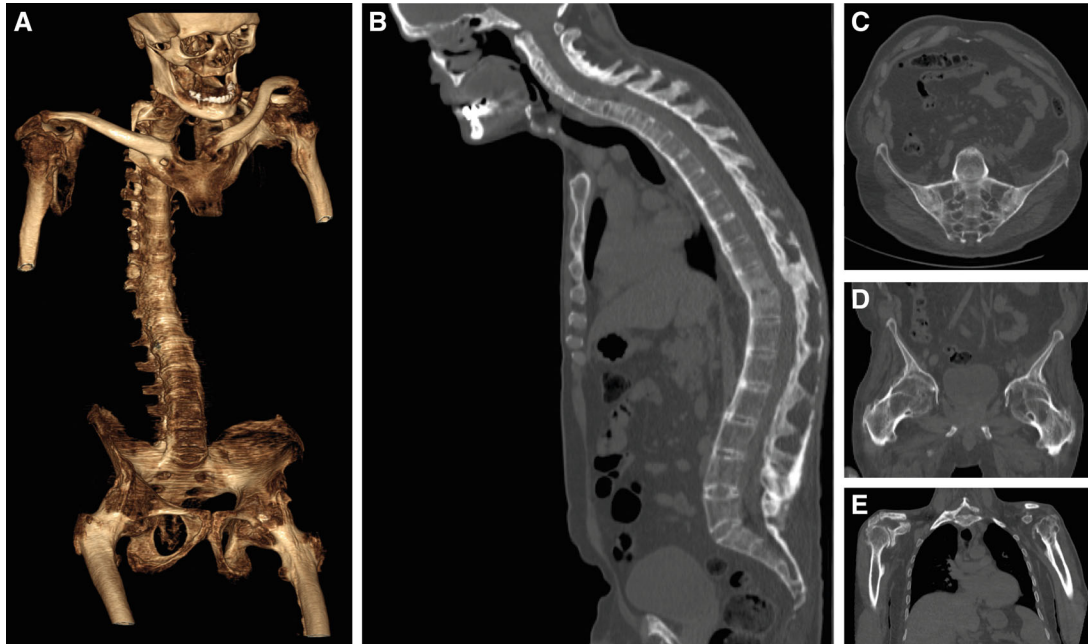


DOI 10.1002/acr2.11492

Clinical Images: A snapshot from the past: untreated ankylosing spondylitis in the biologic era

The patient, a 48-year-old man, was referred to our rheumatology clinic for severe spinal limitation and impaired gait. The patient was born in an underprivileged country and reported a 25-year history of inflammatory axial and peripheral pain with progressive disability. A specific diagnosis had never been made, and he was treated with painkillers on demand. Radiographs showed the presence of diffuse, severe musculoskeletal abnormalities. Computed tomography demonstrated total ankylosis of the spine (video and panel A, generated with three-dimensional volume rendering and bone segmentation; chest wall was removed to facilitate visualization of the spine) due to massive syndesmophytosis, ankylosis of the facet joints, and ossification of the flavum, supraspinous, and interspinous ligaments (panel B). A possible previous vertebral compression wedge fracture was also noted at the T10-T11 level (panel B), but the patient reported no history of acute back pain or trauma. Fusion of sacroiliac joints (panel C), severe destruction with complete ankylosis and fixed flexion deformity of both hips at 35 degrees (panel D), and subtotal ankylosis of both shoulders (panel E) were also evident, along with widespread periarticular and enthesal ossification. The patient was diagnosed with HLA-B27 positive radiographic axial spondyloarthritis (SpA), classified as ankylosing spondylitis, and scheduled for bilateral hip and shoulder replacement.

Encountering young patients with such a severe disease phenotype of axial SpA is becoming increasingly rare in the biologic era. Indeed, real-life long-term data support the role of biologic therapies in slowing radiographic progression (1,2), potentially preventing the extent of axial and peripheral structural damage and the clinical burden observed in our patient. Furthermore, our case emphasizes the significant risk of vertebral fractures in patients with ankylosing spondylitis, due to altered biomechanical properties and spinal remodeling. This risk is fourfold higher than in the general population, but fractures occurring after minor trauma or in asymptomatic patients can be overlooked (3).

Author disclosures are available at <https://onlinelibrary.wiley.com/action/downloadSupplement?doi=10.1002%2Facr2.11492&file=acr211492-sup-0001-Disclosureform.pdf>.

1. Baraliakos X, Gensler LS, D'Angelo S, Iannone F, Favalli EG, de Peyrecave N, et al. Biologic therapy and spinal radiographic progression in patients with axial spondyloarthritis: a structured literature review. *Ther Adv Musculoskelet Dis* 2020;12:1759720x20906040.
2. Koo BS, Oh JS, Park SY, Shin JH, Ahn GY, Lee S, et al. Tumour necrosis factor inhibitors slow radiographic progression in patients with ankylosing spondylitis: 18-year real-world evidence. *Ann Rheum Dis* 2020;79:1327-32.
3. Westerveld LA, Verlaan JJ, Oner FC. Spinal fractures in patients with ankylosing spinal disorders: a systematic review of the literature on treatment, neurological status and complications. *Eur Spine J* 2009;18:145-56.

Jacopo Ciaffi, MD 
Giancarlo Facchini, MD
Stefano Bandiera, MD
Carlotta Cavallari, MD
Marco Miceli, MD
Alessandro Gasbarrini, MD
Francesco Ursini, MD, PhD
*IRCCS Istituto Ortopedico Rizzoli
Bologna, Italy*