



Safety and efficacy of brain biopsy: Results from a single institution retrospective cohort study



Felix Jozsa^a, Celia Gaier^b, Yangxinrui Ma^b, Neil Kitchen^a, Andrew McEvoy^a, Anna Misericocchi^a, George Samandouras^a, Huma Sethi^a, Lewis Thorne^a, Ciaran Hill^{a,c}, Lucia Darie^{a,*}

^a Department of Neurosurgery, The National Hospital for Neurology and Neurosurgery, University College London Hospitals NHS Trust, London, UK

^b University College London Medical School, London, UK

^c UCL Cancer Institute, University College London, 72 Huntley Street, London, UK

ARTICLE INFO

Handling Editor: Dr W Peul

Keywords:

Brain biopsy
primary CNS tumour
Stereotactic frameless
Open biopsy
Post-operative complication rate
Day-case pathway

ABSTRACT

Introduction: Brain biopsy provides important histopathological diagnostic information for patients with new intracranial lesions. Although a minimally invasive technique, previous studies report an associated morbidity and mortality between 0.6% and 6.8%. We sought to characterise the risk linked to this procedure, and to establish the feasibility of instigating a day-case brain biopsy pathway at our institution.

Materials and methods: This single-centre retrospective case series study included neuronavigation guided mini craniotomy and frameless stereotactic brain biopsies carried out between April 2019 and December 2021. Exclusion criteria were interventions performed for non-neoplastic lesions. Demographic data, clinical and radiological presentation, type of biopsy, histology and complications in the post-operative period were recorded. **Results:** Data from 196 patients with a mean age of 58.7 years (SD+/-14.4 years) was analysed. 79% (n=155) were frameless stereotactic biopsies and 21% (n=41) neuronavigation guided mini craniotomy biopsies. Complications resulting in acute intracerebral haemorrhage and death, or new persistent neurological deficits were observed in 2% of patients (n=4; 2 frameless stereotactic; 2 open). Less severe complications or transient symptoms were noted in 2.5% of cases (n=5). 8 patients had minor haemorrhages in the biopsy tract with no clinical ramifications. Biopsy was non-diagnostic in 2.5% (n=5) of cases. Two cases were subsequently identified as lymphoma. Other reasons included insufficient sampling, necrotic tissue, and target error.

Discussion and conclusion: This study demonstrates that brain biopsy is a procedure with an acceptably low rate of severe complications and mortality, in line with previously published literature. This supports the development of day-case pathway allowing improved patient flow, reducing the risk of iatrogenic complications associated with hospital stay, such as infection and thrombosis.

1. Introduction

Brain biopsies are surgical procedures performed to secure tissue diagnosis and allow further targeted treatment in selected patients. In term of modality, the specimen can be acquired: via open craniotomy, utilizing frame-based or frameless stereotactic image guided techniques (Kitchen et al., 1993) or newly MRI-guided robot assisted approaches (Guo et al., 2018). Both frame-based and frameless biopsy forms are depicted in a recent meta-analysis to have similar morbidity and mortality, accuracy and diagnostic yield (Dhawan et al., 2019a; Kesserwan et al., 2021a), with the latter being the method employed more

commonly at our institution. Significant discrepancy exists amongst centres in reporting complication rates (Riche et al., 2021a; Dhawan et al., 2019b; Kulkarni et al., 1998a). In particular the incidence of asymptomatic haemorrhage along the biopsy tract or in the tumour cavity varies widely among publications (Lara-Almunia and Hernández-Vicente, 2021a; Mizobuchi et al., 2019; Riche et al., 2021b), hence the introduction of complication severity classification scales has proven beneficial (Riche et al., 2021c; Bertrand et al., 2020a; Wellmer et al., 2012). Significant evidence supports low level of serious complications occurring after 6 h post intervention, opening therefore the possibility for this procedure to be performed in a day case setting. Whilst North

* Corresponding author. Victor Horsley Department of Neurosurgery, The National Hospital of Neurology and Neurosurgery, University College London Hospitals NHS Trust, Queen Square, London, WC1N 3BG, UK.

E-mail address: lucia.darie@nhs.net (L. Darie).

<https://doi.org/10.1016/j.bas.2023.101763>

Received 20 April 2023; Received in revised form 30 May 2023; Accepted 10 June 2023

Available online 12 June 2023

2772-5294/© 2023 The Authors. Published by Elsevier B.V. on behalf of EUROSPINE, the Spine Society of Europe, EANS, the European Association of Neurosurgical Societies. This is an open access article under the CC BY-NC-ND license (<http://creativecommons.org/licenses/by-nc-nd/4.0/>).

American countries have been exploring this pathway (Carrabba et al., 2008a, 2008b), less attention was received by countries world-wide (Grundy et al., 2008a; Bertrand et al., 2020b).

The primary aims of this study were to analyse 1) the mobility and mortality following frameless vs “open” (neuronavigation guided mini craniotomy) brain biopsy, and 2) the timeframe of complications occurrence post intervention at our institution. Based upon the obtained data, the secondary objective was to determine the safety of implementing a day-case pathway for these types of procedures.

2. Methods

2.1. Ethics

The study was performed in conformity with the internal institutional guidelines and approved by the audit and quality improvement committee (66-202122-CA), which has waived the need for informed patient consent. This project complies with the ethical principles for medical research stipulated in the World Medical Association Declaration of Helsinki.

2.2. Study design and data collection

This is a single-institution retrospective case series study that includes all patients that underwent a brain biopsy procedure for suspected primary central nervous system malignancy between April 2019 and December 2021. Exclusion criteria were cryptogenic neurological diseases, known to have a lower diagnostic yield (Mathon et al., 2022) and complication rates influenced by other comorbidities such as immunocompromise (Layard Horsfall et al., 2020). The collected data was obtained from the electronic medical records. The following variables were registered: demographics, clinical presentation and symptom duration, comorbidities, radiological characteristics, details of the surgical procedure, post-operative complications within the first 30 days and timing of onset, type of post-operative imaging. Primary outcomes were 1) evaluation of the complication rate and diagnostic yield 2) identification of factors associated with post-operative complications and 3) timing of adverse events. Secondary outcomes were.

2.3. Surgical procedure

2.3.1. Preoperative evaluation

All patients were reviewed by anaesthetists and underwent routine pre-operative blood tests. Particular attention was given to the coagulation parameters and platelet count, both normalized before the surgical procedure. Oral anticoagulant therapy was stopped at least 72 h, in case novel oral anticoagulants (NOAC) or 7–10 days ahead of the intervention in case of antiplatelet therapy. Prophylactic low molecular heparin was held 12h in advance.

2.3.2. Stereotactic frame-less and “open” (neuronavigation guided mini craniotomy) biopsy procedures

The intervention was performed under general anaesthesia. The patients were positioned according to the chosen trajectory on the operating table, with the head fixed in a Mayfield head clamp. Volumetric, three-dimensional contrast enhanced MRI 1.5 and 3 T images were acquired prior to the surgery. Fiducials were utilized according to the surgeon's preference. Four out of 198 patients (2%) were unable to have MRI scans, hence contrast enhanced CT head scans were utilized instead. For lesions located directly on the cortical surface, a neuronavigation guided minicraniotomy was performed. In patients with an existing cortical mantle covering the lesion the surgical method of choice was stereotactic frame-less biopsy.

In this patient cohort, this step was performed with the assistance of the StealthStation™ Medtronic optical navigation system which was the only neuronavigation system used by the department for brain biopsies at

the time of data collection. Other neuronavigation systems such as the BrainLab VarioGuide® Alignment system have been used in the past, however were not included in this study. In terms of trajectory, the decision was usually taken for the shortest pathway avoiding eloquent brain areas. For deep seated lesions such as basal ganglia or thalamus, a frontal approach was adopted. A passive Medtronic biopsy needle was introduced in target and several samples were taken 360° around the target area and also at different depths if the lesion was an appropriate size. For smaller, active spots within a presumed low-grade lesion, advanced imaging such as perfusion scans were used to target that specific suspected area. Brain tissue specimens were collected for smear and definitive histopathology investigations at different depths and positions along the same previously planned trajectory. The smear results were awaited before closure or procedure sign-out.

2.3.3. Post-operative management

The patients were post-operatively observed in the recovery unit for a minimum of 4 h following the procedure, depending on how prompt they have returned to their baselines. CT or MRI scans were obtained according to the surgeon's preference and post interventional cross-sectional imaging was not routinely obtained before discharge from the recovery unit to the wards, where the patients continued to be monitored until their discharge home. Scans were obtained in case of neurological deterioration or clinical concerns. Our institutional practice is to aim for discharge within one to two days following surgery. Prophylactic low molecular heparin, in case required, was commenced after 48h post procedure.

2.3.4. Complication classification

Post-operative related complications were defined as complications that occurred within 30 days following the procedure and that were directly associated or as a consequence of the surgical intervention. Complications within the first 6 h were considered “early” and equal or more than 6 h “late”. The electronic patient records of all patients were reviewed and complications following biopsy were categorised according to a previously published classification system (Landriel Ibañez et al., 2011a; Riche et al., 2021d). This classification assigns grade 0 to patients with no complications, and 1A to those with asymptomatic complications (i.e. asymptomatic bleeding on post-operative CT scan). Patients with symptomatic complications are categorised as grade 1B denoting a symptomatic complication resolving without treatment; grade 2 a symptomatic complication requiring treatment and resolving; grade 3 and 4 representing symptomatic complications persistent at 6 months post-biopsy and biopsy-related death, respectively.

2.3.5. Statistics

Categorical variables were expressed as numbers or percentages and compared with the Chi-square tests; for continuous variables, described as means \pm standard deviation, student t-test was applied. Statistical significance was set as p value < 0.05. The statistical analyses were performed with the IBM SPSS software (Version 28, IBM Comp.).

3. Results

3.1. Patient characteristics

Following data collection 196 patients were identified and included in the study. Mean age at presentation was 58.7 years (range 18–84 years, SD \pm 4.4 years). There was a high incidence of cardiovascular disease (n=58; 29.5%) and anticoagulant use (n=24; 12.2%) among the patient population. Further thirteen percent of the patients were diagnosed with diabetes mellitus. 23.5% of the patients had a previous unrelated cancer diagnosis. Twenty-six patients (13%) had no significant past medical history whereas sixty-eight (34%) had two or more comorbidities (Table 1).

Table 1

Breakdown of presenting symptoms and their duration, and patient co-morbidities.

	n (%)
Presenting symptoms	
Motor deficit	68 (34.7%)
Headaches	46 (23.5%)
Seizures	44 (22.4%)
Cognition and memory problems	45 (23%)
Aphasia	36 (18.4%)
Sensory deficit	16 (8.2%)
Dizziness	20 (10.2%)
Confusion	6 (3.1%)
Visual impairment	7 (3.6%)
Incidental	12 (6.1%)
Duration of symptoms	
Hyperacute (1–2 days)	21 (10.7%)
Acute (3–10 days)	31 (15.8%)
Subacute (11–30 days)	56 (28.6%)
Chronic (>30 days)	81 (41.3%)
Co-morbidities	
None	26 (13%)
Cardiovascular disease	58 (29.5%)
Anticoagulant use	24 (12.2%)
Diabetes mellitus	26 (13.2%)
Epilepsy	5 (2.6%)
Previous cancer	46 (23.4%)
Autoimmune disease	6 (3.1%)
Substance abuse	
Tobacco use	16 (8.2%)
Alcohol misuse	3 (1.5%)
Recreational drug use	1 (0.5%)
Number of co-morbidities	
None	26 (13%)
One	51 (26%)
Two	46 (23%)
More than two	22 (11%)

4. Presenting symptoms

The most common presenting symptom were motor deficits (68 patients; 34.7%), followed by headaches (23.5%), memory and cognitive impairment (23%) as well as seizures (22.4%). Aphasia (18.4%), sensory deficits (8.2%), and visual deterioration (3.6%) were less common. Predominantly, the patients (n=108; 55%) displayed a single symptom at presentation. 54 (28%) of patients reported two concurrent symptoms, whereas only 23 (12%) had more than two complaints. In eleven patients (6%) the diagnosis was made incidentally. In terms of symptom onset, patients exhibited chronic symptoms (defined as >30 days) in 41% of cases (n=56). Subacute (11–30 days) and acute (3–10 days) onset was found in 15.8% and 28.5% of patients, respectively. Only 21 patients (10.7%) presented within a hyperacute period (24–48 h from onset).

4.1. Characteristics of lesions on imaging

In terms of imaging, MRI led to the diagnosis of brain tumours in the vast majority of cases and only 2% (n=4) of brain biopsies were performed based on CT scans alone. We were unable to retrieve pre-operative scans in a single patient. Characterisation of lesions on pre-operative imaging showed 2.6% (n=5) measuring less than 1 cm³, with 69.9% being unifocal and 30% multifocal. 88.3% of lesions demonstrated contrast enhancement, and 44.4% had perilesional oedema. Two-thirds of lesions were superficial (located less than 2 cm from the cortical surface; n=129; 66%), and 34% of lesions were in deep structures. Table 3 details the tumour locations for the patients in this cohort.

4.2. Biopsies performed and rates of clinical complications

A total of 198 biopsies were performed (n=2 patients undergoing biopsy twice) of which 157 interventions were stereotactic (79%) and 41 neuronavigation guided mini craniotomy biopsies (21%). 178 procedures (89.8%) were performed with no complications (grade 0). 67 patients underwent CT imaging post operatively, of which 9 (13.4%) had asymptomatic haemorrhage (grade 1A). Among these 9 patients, the CT

Table 2

Patient characteristics including comparison of patients with and without complications.

Characteristics	All biopsies (%)	Without complications (%)	With complication grades 1A-4 (%)	P value
Total	198	180 (90.9%)	18 (9.1%)	
Number male:female	122:76	109:71	13:5	0.45
Mean age at biopsy (years)	58.7 (±14.4)	58.5 (±14.6)	60.5 (±13.2)	0.58
Type of surgery				
Stereotactic biopsy	156 (78.8%)	144 (80.0%)	12 (66.7% of total complications)	0.22
Neuronavigation guided mini craniotomy biopsy	42 (21.2%)	36 (20.0%)	6 (33.3% of total complications)	0.22
Radiological appearances				
Supratentorial	192 (98%)	174 (97.8%)	18 (100%)	1.00
Superficial (<2 cm from cortical surface)	129 (65.8%)	118 (66.3%)	11 (61.1%)	0.79
Size <1 cm ³	5 (2.6%)	5 (2.8%)	0 (0%)	1.00
Size >1 cm ³	191 (97.4%)	173 (97.2%)	18 (100%)	1.00
Contrast enhancing	173 (88.3%)	155 (87.1%)	18 (100%)	0.14
Unifocal	137 (69.9%)	126 (70.8%)	11 (61.1%)	0.43
Perifocal oedema	87 (44.4%)	80 (44.9%)	7 (38.9%)	0.80

Table 3

Tumour locations of patients undergoing brain biopsy.

	Total	Left-sided, n (%)
Multi-focal	20	
Butterfly	18	
Involving two lobes	23	
Single lobe		
Frontal	30	16 (53%)
Parietal	22	8 (36%)
Temporal	32	22 (69%)
Occipital	3	1 (33%)
Deep seated		
Insula	13	
Thalamus	9	
Basal ganglia	7	
Deep white matter (cingulum, centrum semiovale)	5	
Periventricular	4	
Ventricular	2	
Eloquent areas		
Motor strip	4	
Somatosensory cortex	1	
Other		
Brainstem	3	
Falx	1	
Cerebellum	1	
Total	198	

head scan had been requested by the senior surgeon as routine in 6 cases. In 4 cases this was between 3 and 4 h post-operatively, and in 3 cases this was at 24 h post-procedure. In the remaining 3 patients, the CT scan was requested for headache 5 h post-procedure, confusion 48 h post-procedure, and superficial bruising around the eye at 24 h post-procedure.

The number of patients with symptomatic complications was 4.5% (Fig. 1). Grade 1B complications occurred in 2 patients (1%), consisting of transient dysarthria, both with onset within 4 h postoperatively and resolving within 12 h, and 5 days, respectively. Grade 2 complications were reported in 3 patients (1.5%). One patient had a self-terminated isolated episode of focal seizure on postoperative day 3 and was

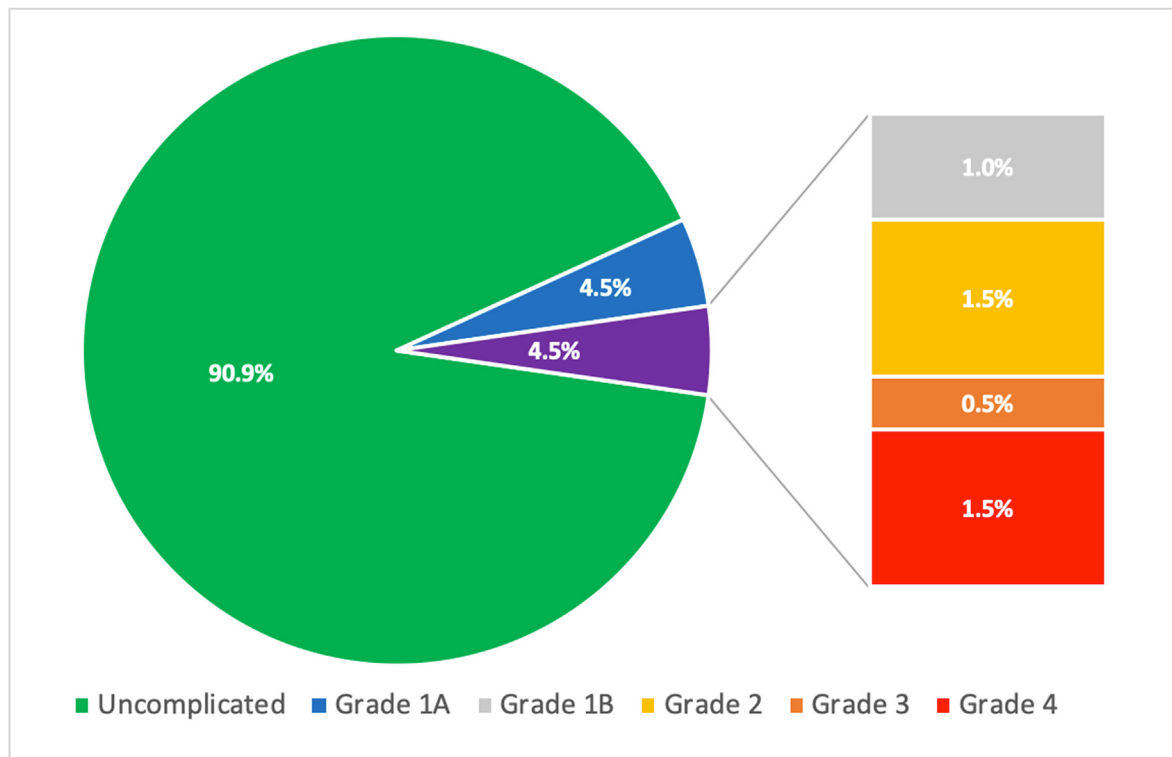


Fig. 1. Breakdown of rate of complications following brain biopsy.

Symptomatic complications (4.5%; purple) are subdivided into grade 1B, 2, 3, and 4 in the column. (For interpretation of the references to colour in this figure legend, the reader is referred to the Web version of this article.)

treated with levetiracetam, after which no further seizure activity occurred. A second patient reported postoperative right-sided paraesthesia 10 h postoperatively and was treated with intravenous levetiracetam. CT imaging showed a small volume subarachnoid haemorrhage, and the patients symptoms resolved 48 h later. A third patient developed worsening hemiparesis compared to their preoperative status, and this resolved with intensive physiotherapy.

One patient (0.5%) had a grade 3 complication, having developed recurrent seizures and new hemiparesis approximately 9 h following biopsy, with no corresponding evidence of haematoma, lesion progression, or oedema on imaging. The patient was diagnosed with Todd's paralysis and eventually supplementary motor area (SMA) syndrome and discharged with residual left-sided weakness. Three patients died as a result of complications following biopsy (grade 4 complication, 1.5%), all with intracerebral haemorrhage presenting as acute drop in GCS within the first 2 h following surgery (Table 5).

Univariate analysis of the patient cohort with Fisher's exact test and unpaired t-tests revealed that no patient characteristics, clinical features or imaging findings were associated with an increased risk of developing complications. The corresponding p-values for each characteristic are detailed in Table 2.

4.3. Histopathology results

Biopsy yielded a histopathological diagnosis in 97% of cases (n=194). Among the diagnostic biopsies, 176 (89%) found a primary malignancy, of which 67% were WHO grade 4 (n=118). Within this group the large majority were glioblastoma (n=111, 94.1%) while 7 patients had diffuse midline glioma (5.4%). Thirty-one tumours were primary CNS lymphoma and 11 were metastasis from a distal primary malignancy (see Table 4). Immunohistochemistry and molecular profiling were successfully performed on 98.9% (n=196) of cases, with insufficient tissue hindering these investigations in only two patients. The number of non-diagnostic biopsies was 5 (2.5%), two of them being primary CNS

Table 4

Histopathology results of brain biopsy cohort.

Histopathology results		n (%)
Primary CNS tumour	Total	176 (89%)
	Grade 4 glioma	118 (59%)
	Grade 3 glioma	6 (3%)
	Grade 2 glioma	17 (8.6%)
	Grade 1 glioma	1 (0.5%)
	Primary CNS Lymphoma	31 (16%)
	Low grade glioma (NOS)	3 (1.5%)
Metastasis	Total	11 (5.6%)
	Lymphoma	6 (3%)
	Breast	3 (1.5%)
	Melanoma	2 (1%)
Miscellaneous	Total	5 (2.5%)
	Primary melanoma	1 (0.5%)
	Radiation necrosis	1 (0.5%)
	Inflammatory demyelination	1 (0.5%)
	Progressive multifocal leukoencephalopathy	1 (0.5%)
	T-cell infiltration	1 (0.5%)

lymphoma patients who subsequently underwent a second intervention for confirmation of the diagnosis. Neither of these patients were on steroids at the time of the initial biopsy. The remaining three non-diagnostic biopsies occurred in the following scenario: insufficient sampling (n=2) and finding of normal cortical tissue (n=1). Among patients with a diagnosis of primary CNS lymphoma, 4 had biopsies whilst taking dexamethasone, or had been taking within the previous 24 h. None of these biopsies were non-diagnostic.

5. Discussion

This study indicates that symptomatic complications following brain biopsies are an infrequent occurrence, making this type of surgery a safe

Table 5
Timeline of significant morbidity and mortality following biopsy (grade 3 and 4 complications).

	Patient 1	Patient 2	Patient 3	Patient 4
Age, sex	61, M	36, F	74, M	60, M
Co-morbidities	nil	Alcohol misuse, on anticoagulation	Hypertension, on anticoagulation	nil
Biopsy type	Stereotactic	Neuronavigation guided mini craniotomy	Stereotactic	Neuronavigation guided mini craniotomy
Lesion location	Right temporal lobe	Falx	Bilateral periventricular	Right frontal lobe
Lesion characteristics	Unifocal, superficial	Multifocal, superficial	Deep, multifocal	Unifocal, superficial
Final histology	Glioblastoma	Metastasis from primary melanoma	PCNSL	Glioblastoma
Complication	Death	Death	Death	Persistent hemiparesis and focal seizures
Complication grade	4	4	4	3
Post-biopsy scan findings	Large volume parenchymal and intraventricular haemorrhage	Haemorrhage in biopsy bed with oedema	Intracerebral and intraventricular haemorrhage	No haemorrhage or ischaemia
Time from biopsy to deterioration	2 h	1.5 h	2 h	9.5 h

procedure. Fatal complications were found only in a minority of patients ($n=3$; representing 1.5%) as well as post-interventional new neurological deficits ($n=1$; 0.5%). This raises the number of severe incidents to an overall of 2%. Further transient neurological symptoms, that spontaneously regressed or required medication and consequently corresponding to severity grades 1b and 2 respectively, were present in 5 patients (2%). These rates are in line with those reported in a recent meta-analysis of patients undergoing frame based stereotactic procedures. Rieche et al. (Riche et al., 2021e) estimated the mortality rate of stereotactic, frame-based, performed brain biopsies to 1% (with a range in between 0% and 4%), whereas 3.5% (range 0–8.6%) of the patients were reported to have developed symptomatic complications. In a further recent meta-analysis, comparing the safety and diagnostic yield of frame-based versus frame-less brain biopsies. Kesserwan et al. (2021b), found no significant difference between these two modalities, with an estimated mortality of 2% for frame-base and 2.2% for the frame-less performed procedures. As depicted in Tables 2 and in our cohort of patients there were no significant differences in terms of symptomatic complications or fatality rate between open and frame-less stereotactic interventions.

The use of a complication severity score (Landriel Ibáñez et al., 2011b; Riche et al., 2021f) has facilitated reporting the rate of asymptomatic haemorrhage detected in post interventional performed CT head scans in a systematic fashion. We emphasize with this occasion the advantages brought by such a grading score in the view of a widely variable rate described in the literature, ranging between 7% and 60% (Riche et al., 2021g; Kulkarni et al., 1998b; Kesserwan et al., 2021c; Pasternak et al., 2021a). Just above one third of our patients underwent a routine CT head scan with 13.4% ($n=9$) having a confirmed asymptomatic bleeding. The decision to obtain a post-operative scan was made according to the preference of the senior operating surgeon and not based on clinical deterioration or complaints. When compared with the patients who had no haemorrhage on postoperative imaging, there were no statistically significant differences in age ($p=0.182$), comorbidities such as hypertension (0.46), or anticoagulant use ($p=0.291$). Furthermore, there was no significant difference in the rate of asymptomatic haemorrhage following stereotactic ($n=6$) versus open ($n=3$) biopsy ($p=0.35$).

Lara-Almunia et al. (Lara-Almunia and Hernández-Vicente, 2021b), have looked into factors that could drive asymptomatic haemorrhage in stereotactic brain biopsies, concluding that the literature shows variable and discrepant data with regards to the risk of bleeding according to location (deep versus superficial brain lesions) or histological grade (benign versus malignant). On the other hand, Riche et al. (2021h), has found that patients diagnosed with glioblastoma, and lymphoma are overall more prone to post interventional complications. Histopathological diagnosis confirmed high-grade tumours in 83.6% of our patients, which accounts for the vast majority in this cohort. Low-grade tumours represent as expected a minority, as brain biopsies are not routinely

indicated this subgroup of patients. High grade tumours are well vascularized lesions, known to dispose over a significant capacity of angiogenesis (Ahir et al., 2020), increasing at least theoretically the susceptibility towards bleeding. Kesserwan et al. (2021d), describe in their meta-analysis a higher and statistically significant rate of asymptomatic haemorrhage in frame-less performed procedures compared to frame-based brain biopsies (20% versus 15.7%). This difference however became insignificant when the authors excluded the study conducted by Michaud et al. (2013), which assumes that the above-described higher rate could be attributed to the post-operative CT head scan being performed earlier in the included patients that underwent frame-based procedures. Further risk factors correlated with a higher complication rate as identified by Rieche et al. (Riche et al., 2021i,j) were age above 65 years, gadolinium enhanced and infratentorial lesions as well as performing a second intervention; with gadolinium-enhanced lesions being a sign of malignancy and subsequently of increased lesion vascularisation.

The histopathological diagnosis of the three patients deceased in our study revealed three different types of malignant tumours: glioblastoma, lymphoma and metastasis. Consequently, it is impossible to draw an adequate conclusion in this respect from our data.

5.1. Precision and diagnostic yield

In terms of accuracy and precision, we were able to secure histopathological diagnosis in 97% ($n=194$) of the performed brain biopsy interventions. These figures are comparable to those published in 2019 in a metanalysis written by Dhawan et al. (2019c), that attributed a diagnostic yield between 84 and 100% to the frame-based and between 86.6% and 100% to the frame-less procedures. Our cohort consisted of 67 cases (34.2%) deep seated lesions, defined as located below 2 cm from the cortical surface and 5 (2.6%) cases of tumours below 1 cm in size. Five brain biopsies (2.5%) were non-diagnostic. Broken down according to the surgical technique and depth of the tumours: one lesion was located superficially and biopsied via a neuronavigation guided mini craniotomy; the rest four patients underwent a frame-less stereotactic procedure. The latter group comprised of two superficial and two deep-seated tumours. Overall, this results in a 2.5% (4 out of 156 cases) inaccuracy or incapacity to obtain diagnosis for the frame-less technique and 2.4% (one out of 42 cases) for neuronavigation guided mini craniotomy surgery; two out of 67 patients with deep seated lesions received initial negative results, corresponding to a 5.85% rate of unsuccessful biopsies for this location. In terms of histology, it is worthy to mention that 2 out of 5 non-diagnostic cases were primary CNS lymphomas, subsequently confirmed following a second surgical intervention. None of these patients had been on steroids before surgery. The remaining three non-diagnostic biopsies occurred in the following scenario:

insufficient sampling (n=2) and finding of normal cortical tissue (n=1). We have deliberately excluded from our study patients with cryptogenic neurological conditions, considering the higher reported rate of complications and non-diagnostic samples (Pasternak et al., 2021b).

5.2. Brain biopsy for primary CNS lymphomas and steroids treatment

In our cohort, 31 patients had a final diagnosis of primary CNS lymphoma, four of which had taken dexamethasone within 24 h prior to biopsy. Despite widely accepted beliefs in neurosurgical practice about the detrimental effects of dexamethasone administration of the diagnostic yield of brain biopsy, several studies indicate that this assumption is not always supported (Bullis et al., 2020; Porter et al., 2008; Binnahil et al., 2016). In line with these results, all 4 patients taking steroids at time of biopsy yielded a pathological diagnosis. Two patients with a final diagnosis of primary central nervous system lymphoma (PCNSL) underwent repeat biopsies following non-diagnostic histopathology results, however, neither of these patients were taking steroids at the time of biopsy. Additional cases where the MRI lesion regressed and became unsuitable for biopsy after steroid administration are not captured in this series.

5.3. Complications timeline

Significant amounts of evidence, emerging both from prospective and retrospective studies supports the fact that severe or lethal post procedure complications arise in the first 6–12 h, with the majority occurring within the first 2 h following intervention (Riche et al., 2021i,j; Lar-a-Almunia and Hernández-Vicente, 2021c). Our study enforces these findings, with grade 4 complications in our cohort occurring with pre-dilection in the first 2 h (Table 5). Table 6 details the timeline and evolution of less severe and non-fatal complications following biopsy (grade 1B and 2). Of the 5 patients in this group, 2 presented within 6 h post-biopsy, whereas a third presented at 9 h. The remaining 2 patients presented with dysphasia on day 3 post-biopsy. We emphasize that infection was not an encountered complication in this study, with no post-operative infections reported within 30 days, and furthermore, no procedure-related readmissions following biopsy in this period. These findings, consequently, advocate that major adverse events are unlikely to arise later than a few hours, making brain biopsies a potentially appropriate procedure for a day-case pathway given the correct initial clinical observation period and correct patient safety netting.

5.4. Developing brain biopsy as an elective day-case procedure

The use of day-case pathways in elective brain biopsy patients has been previously reported (Grundy et al., 2008b; Vallejo et al., 2022; Boulton and Bernstein, 2008), however it has been rarely integrated in the UK neurosurgical practice (<https://www.gettingit-rightfirsttime.co.uk/surgical-specialty/cranial-neurosurgery/a>). The recent *Getting It Right First Time Cranial Neurosurgery* report (<https://www.gettingit-rightfirsttime.co.uk/surgical-specialty/cranial-neurosurgery/b>) highlighted the need to perform procedures as a day-case where possible, reducing patient risks of iatrogenic infection, thromboembolism, and delirium, as well as improving system costs and logistical management issues. Our study outlines that severe or fatal post interventional complications have a low rate of occurrence following brain biopsy. Furthermore, severe complications were found to occur predominantly within the first 2 h post-procedure, and, in our cohort, not later than 10 h (Table 5).

This is in line with previously published results showing prompt presentation of post-procedure complications within 4–8 h (Kaakaji et al., 2001; Warnick et al., 2003; Bhardwaj and Bernstein, 2002). In order to safely identify and treat and such complications that arise, pathways recommend a) post-operative CT scanning at 2–4 h, and b)

Table 6
Timeline of grade 1B and 2 complications following biopsy.

	Patient 1	Patient 2	Patient 3	Patient 4	Patient 5
Age, sex	62, F	57, F	68, F	27, F	50, M
Co-morbidities	Cardiovascular disease, anticoagulant use	Previous cancer, immunosuppression	Cardiovascular disease	Nil	Nil
Biopsy type	Stereotactic	Neuronavigation guided mini craniotomy	Stereotactic	Stereotactic	Stereotactic
Lesion location	Right temporal lobe	Left frontotemporal	Left parieto-occipital	Left insula	Left insula/frontal
Lesion characteristics	Superficial, unifocal	Superficial, unifocal, with perilesional oedema	Superficial, unifocal, with perilesional oedema	Superficial, unifocal	Superficial, unifocal
Final histology	PCNSL	Glioblastoma	Glioblastoma	Glioblastoma	Glioblastoma
Complication grade	2	2	2	1B	1B
Initial presentation	1-min self-terminating focal seizure on day 3 post-biopsy	Worsening right leg weakness noted 4 h post-biopsy	Right arm and leg paraesthesia 9 h post-biopsy. One absence seizure episode 24 h post-biopsy	Dysarthria 1 h post-biopsy	Dysphasia day 3 post-biopsy
Intervention	Commenced IV then oral levetiracetam	CT head: no haemorrhage, increased lesion oedema. Steroids commenced. Improved to baseline. Transferred to another hospital day 10	CT head: small volume subarachnoid blood at biopsy site. Commenced IV levetiracetam	CT head: small volume pneumocephalus, no bleed	CT head: intralésional haemorrhage with mild lesional oedema
Outcome	No further seizures. Home on day 7.	No further seizures. Discharged day 6 with no deficits	No further seizures. Discharged day 6 with no deficits	Resolved at 6 h; home day 2	Resolved on day 6; discharged day 11

observation and clinical review for a further 2 h to ensure vital signs are stable and the patient is eating and drinking. Successful and safe instigation of a day case biopsy pathway must also include adequate pre-operative planning with up-to-date pre-operative neuroimaging, screening by the anaesthetic team and routine blood tests, as well as ensuring patients stop anticoagulation medication within an appropriate time frame before admission. Fig. 2 outlines a proposed pathway for integration of a day case brain biopsy pathway within the hospital neurosurgical multi-disciplinary team.

6. Limitations

This study has several limitations. In the first instance there are the inherent disadvantages of a retrospective case-series study, for example the occasional loss of imaging data (n=1 in our study), or the inability to entirely control for confounding factors among the observed group. Secondly our institution is a tertiary centre, which brings with itself a predisposition towards selection bias. It is worthy to mention however that the advantage of such a centre is the experience and the high-volume

case load. Further, there are differences in practice amongst neurosurgeons both in the surgical technique preferred and in the post-operative care. In example, we have highlighted the fact that only a proportion of the patient undergoing brain biopsied had post-operative imaging. Hence, we were not able to completely report how many patients from our cohort had asymptomatic haemorrhage along the biopsy tract, which may or may not be regarded as a significant complication. Finally, we have reported the complication rate in a simple, standardized manner utilizing a previously published grading scale. Nevertheless, it cannot be conclusively and unanimously stated what exactly it is defined to be a post brain biopsy complication.

7. Conclusion

We report our data on 198 brain biopsies and demonstrate that in our series frameless stereotactic biopsy or neuronavigation guided mini-craniotomy brain biopsy is a procedure with a low rate of severe complications and mortality. We demonstrate that all complications occurred within a 10-h period and therefore this supports the development of

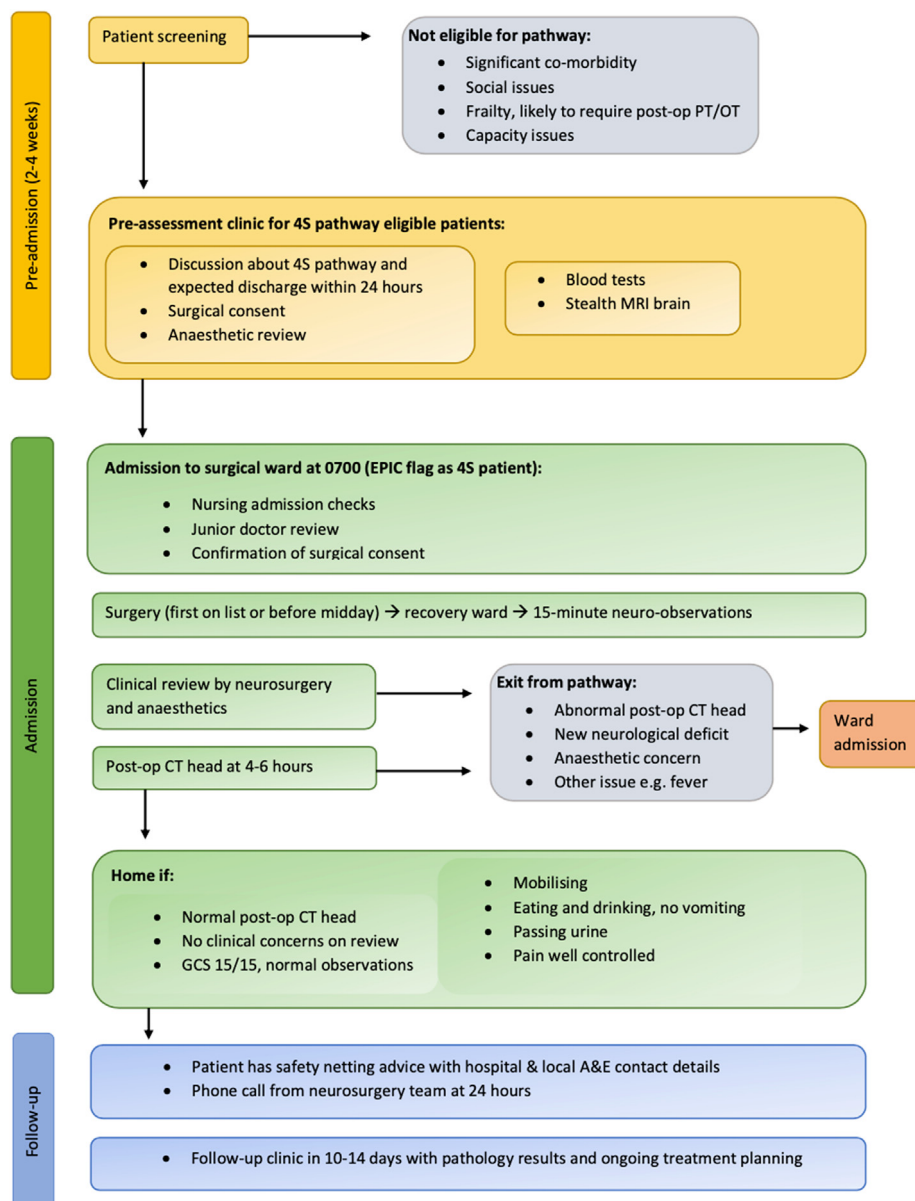


Fig. 2. Proposed day case brain biopsy pathway.

short-stay pathway allowing improved patient flow, and with the potential to reduce the risk of iatrogenic complications associated with hospital stay, such as infection and thrombosis.

Authors' contributions

Conceptualization, L.D and C.H.; methodology, L.D.; formal analysis, L.D, F.J and C.H.; data collection: F.J, C.C, X.M and L.D; imaging review, L.D.; writing—original-draft preparation, L.D, F.J and C.H.; writing—review and editing, L.D and C.H, final review, all authors; supervision, C.H and L.D. All authors have read and agreed to the published version of the manuscript.

Funding

CSH is supported by a CRUK Pioneer Award (C70568/A29787), an AMS Starter Grant (SGL021/1034), a National Brain Appeal Innovation Award (NBA/NSG/BTB), and UCLH BRC NIHR funding.

Disclosure

The authors have nothing to disclose and no conflicts of interest. No funds were received for the completion of this study.

Declaration of competing interest

The authors declare that they have no known competing financial interests or personal relationships that could have appeared to influence the work reported in this paper.

References

- Ahir, B.K., Engelhard, H.H., Lakka, S.S., 2020. Tumor development and angiogenesis in adult brain tumor: glioblastoma. *Mol. Neurobiol.* 57 (5), 2461–2478. <https://doi.org/10.1007/s12035-020-01892-8>. Epub 2020 Mar 9. PMID: 32152825; PMCID: PMC7170819.
- Bertrand, Mathon, Le Joncour, Alexandre, Bielle, Franck, Mokhtari, Karima, et al., 2020a. Neurological diseases of unknown etiology: brain-biopsy diagnostic yields and safety. *Eur. J. Intern. Med.* 80, 78–85. <https://doi.org/10.1016/j.ejim.2020.05.029>. ISSN 0953-6205.
- Bertrand, Mathon, Le Joncour, Alexandre, Bielle, Franck, Mokhtari, Karima, et al., 2020b. Neurological diseases of unknown etiology: brain-biopsy diagnostic yields and safety. *Eur. J. Intern. Med.* 80, 78–85. <https://doi.org/10.1016/j.ejim.2020.05.029>. ISSN 0953-6205.
- Bhardwaj, R.D., Bernstein, M., 2002. Prospective feasibility study of outpatient stereotactic brain lesion biopsy. *Neurosurgery* 51 (2), 358–361 discussion 361-4. PMID: 12182773.
- Binnahil, M., Au, K., Lu, J.Q., Wheatley, B.M., Sankar, T., 2016. The influence of corticosteroids on diagnostic accuracy of biopsy for primary central nervous system lymphoma. *Can. J. Neurol. Sci.* 43 (5), 721–725. <https://doi.org/10.1017/cjn.2016.255>. Epub 2016. PMID: 27468790.
- Boulton, M., Bernstein, M., 2008. Outpatient brain tumor surgery: innovation in surgical neurooncology. *J. Neurosurg.* 108 (4), 649–654. <https://doi.org/10.3171/JNS/2008/108/4/649>. PMID: 18377241.
- Bullis, C.L., Maldonado-Perez, A., Bowden, S.G., Yaghi, N., Munger, D., Wood, M.D., Barajas, R.F., Ambady, P., Neuwelt, E.A., Han, S.J., 2020. Diagnostic impact of preoperative corticosteroids in primary central nervous system lymphoma. *J. Clin. Neurosci.* 72, 287–291. <https://doi.org/10.1016/j.jocn.2019.10.010>. Epub 2019 Oct 21. PMID: 31648968.
- Carrabba, G., Venkatraghavan, L., Bernstein, M., 2008a. Day surgery awake craniotomy for removing brain tumours: technical note describing a simple protocol. *Minim. Invasive Neurosurg.* 51 (4), 208–210. <https://doi.org/10.1055/s-2008-1073132>. PMID: 18683111.
- Carrabba, G., Venkatraghavan, L., Bernstein, M., 2008b. Day surgery awake craniotomy for removing brain tumours: technical note describing a simple protocol. *Minim. Invasive Neurosurg.* 51 (4), 208–210. <https://doi.org/10.1055/s-2008-1073132>. PMID: 18683111.
- Dhawan, S., He, Y., Bartek Jr., J., Alattar, A.A., Chen, C.C., 2019a. Comparison of frame-based versus frameless intracranial stereotactic biopsy: systematic review and meta-analysis. *e4 World Neurosurg* 127, 607–616. <https://doi.org/10.1016/j.wneu.2019.04.016>. Epub 2019 Apr 8. PMID: 30974279.
- Dhawan, S., He, Y., Bartek Jr., J., Alattar, A.A., Chen, C.C., 2019b. Comparison of frame-based versus frameless intracranial stereotactic biopsy: systematic review and meta-analysis. *e4 World Neurosurg* 127, 607–616. <https://doi.org/10.1016/j.wneu.2019.04.016>. Epub 2019 Apr 8. PMID: 30974279.
- Dhawan, S., He, Y., Bartek Jr., J., Alattar, A.A., Chen, C.C., 2019c. Comparison of frame-based versus frameless intracranial stereotactic biopsy: systematic review and meta-analysis. *e4 World Neurosurg* 127, 607–616. <https://doi.org/10.1016/j.wneu.2019.04.016>. Epub 2019 Apr 8. PMID: 30974279.
- Grundy, P.L., Weidmann, C., Bernstein, M., 2008a. Day-case neurosurgery for brain tumours: the early United Kingdom experience. *Br. J. Neurosurg.* 22 (3), 360–367. <https://doi.org/10.1080/02688690801961858>. PMID: 18568724.
- Grundy, P.L., Weidmann, C., Bernstein, M., 2008b. Day-case neurosurgery for brain tumours: the early United Kingdom experience. *Br. J. Neurosurg.* 22 (3), 360–367. <https://doi.org/10.1080/02688690801961858>. PMID: 18568724.
- Guo, Ziyang, Leong, Martin Chun-Wing, Su, Hao, Kwok, Ka-Wai, Chan, Danny Tat-Ming, Poon, Wai-Sang, 2018. Techniques for stereotactic neurosurgery: beyond the frame, toward the intraoperative magnetic resonance imaging-guided and robot-assisted approaches. *World Neurosurgery* 116, 77–87. <https://doi.org/10.1016/j.wneu.2018.04.155>. ISSN 1878-8750. <https://www.gettingitrightfirsttime.co.uk/surgical-specialty/cranial-neurosurgery/>. <https://www.gettingitrightfirsttime.co.uk/surgical-specialty/cranial-neurosurgery/>.
- Kaakaji, W., Barnett, G.H., Bernhard, D., Warbel, A., Valaitis, K., Stamp, S., 2001. Clinical and economic consequences of early discharge of patients following supratentorial stereotactic brain biopsy. *J. Neurosurg.* 94 (6), 892–898. <https://doi.org/10.3171/jns.2001.94.6.0892>. PMID: 11409516.
- Kesserwan, M.A., Shakil, H., Lannon, M., McGinn, R., Banfield, L., Nath, S., Alotaibi, M., Kasper, E., Sharma, S., 2021a. Frame-based versus frameless stereotactic brain biopsies: a systematic review and meta-analysis. *Surg. Neurol. Int.* 12, 52. <https://doi.org/10.25259/SNI.824.2020>. PMID: 33654555; PMCID: PMC7911151.
- Kesserwan, M.A., Shakil, H., Lannon, M., McGinn, R., Banfield, L., Nath, S., Alotaibi, M., Kasper, E., Sharma, S., 2021b. Frame-based versus frameless stereotactic brain biopsies: a systematic review and meta-analysis. *Surg. Neurol. Int.* 12, 52. <https://doi.org/10.25259/SNI.824.2020>. PMID: 33654555; PMCID: PMC7911151.
- Kesserwan, M.A., Shakil, H., Lannon, M., McGinn, R., Banfield, L., Nath, S., Alotaibi, M., Kasper, E., Sharma, S., 2021c. Frame-based versus frameless stereotactic brain biopsies: a systematic review and meta-analysis. *Surg. Neurol. Int.* 12, 52. <https://doi.org/10.25259/SNI.824.2020>. PMID: 33654555; PMCID: PMC7911151.
- Kesserwan, M.A., Shakil, H., Lannon, M., McGinn, R., Banfield, L., Nath, S., Alotaibi, M., Kasper, E., Sharma, S., 2021d. Frame-based versus frameless stereotactic brain biopsies: a systematic review and meta-analysis. *Surg. Neurol. Int.* 12, 52. <https://doi.org/10.25259/SNI.824.2020>. PMID: 33654555; PMCID: PMC7911151.
- Kitchen, N.D., Lemieux, L., Thomas, D.G., 1993. Accuracy in frame-based and frameless stereotaxy. *Stereotact. Funct. Neurosurg.* 61 (4), 195–206. <https://doi.org/10.1159/000100637>. PMID: 7846382.
- Kulkarni, A.V., Guha, A., Lozano, A., Bernstein, M., 1998a. Incidence of silent hemorrhage and delayed deterioration after stereotactic brain biopsy. *J. Neurosurg.* 89 (1), 31–35. <https://doi.org/10.3171/jns.1998.89.1.0031>. PMID: 9647169.
- Kulkarni, A.V., Guha, A., Lozano, A., Bernstein, M., 1998b. Incidence of silent hemorrhage and delayed deterioration after stereotactic brain biopsy. *J. Neurosurg.* 89 (1), 31–35. <https://doi.org/10.3171/jns.1998.89.1.0031>. PMID: 9647169.
- Landriel Ibañez, F.A., Hem, S., Ajler, P., Vecchi, E., Ciruolo, C., Baccanelli, M., Tramontano, R., Knezevich, F., Carrizo, A., 2011a. A new classification of complications in neurosurgery. *discussion 604-11 World Neurosurg* 75 (5–6), 709–715. <https://doi.org/10.1016/j.wneu.2010.11.010>. PMID: 21704941.
- Landriel Ibañez, F.A., Hem, S., Ajler, P., Vecchi, E., Ciruolo, C., Baccanelli, M., Tramontano, R., Knezevich, F., Carrizo, A., 2011b. A new classification of complications in neurosurgery. *discussion 604-11 World Neurosurg* 75 (5–6), 709–715. <https://doi.org/10.1016/j.wneu.2010.11.010>. PMID: 21704941.
- Lara-Almunia, Mónica, Hernández-Vicente, Javier, 2021a. Related factors with diagnostic yield and intracranial hemorrhagic complications in frame-based stereotactic biopsy. *Rev. Neurocir.* 32 (6), 285–294. <https://doi.org/10.1016/j.neucie.2021.04.004>. ISSN 2529-8496.
- Lara-Almunia, Mónica, Hernández-Vicente, Javier, 2021b. Related factors with diagnostic yield and intracranial hemorrhagic complications in frame-based stereotactic biopsy. *Rev. Neurocir.* 32 (6), 285–294. <https://doi.org/10.1016/j.neucie.2021.04.004>. ISSN 2529-8496.
- Lara-Almunia, Mónica, Hernández-Vicente, Javier, 2021c. Related factors with diagnostic yield and intracranial hemorrhagic complications in frame-based stereotactic biopsy. *Rev. Neurocir.* 32 (6), 285–294. <https://doi.org/10.1016/j.neucie.2021.04.004>. ISSN 2529-8496.
- Layard Horsfall, H., Toescu, S.M., Grover, P.J., Hassell, J., Sayer, C., Hemingway, C., Harding, B., Jacques, T.S., Aquilina, K., 2020. The utility of brain biopsy in pediatric cryptogenic neurological disease. *J. Neurosurg. Pediatr.* 26 (4), 431–438. <https://doi.org/10.3171/2020.4.PEDS19783>. PMID: 32619987.
- Mathon, B., Marijon, P., Riche, M., Degos, V., Carpentier, A., PSL BRAIN-BIOPSY STUDY GROUP, 2022. Outpatient stereotactic brain biopsies. *Neurosurg. Rev.* 45 (1), 661–671. <https://doi.org/10.1007/s10143-021-01593-3>. Epub 2021 Jun 23. PMID: 34164746; PMCID: PMC8221740.
- Michaud, Karine, et al., 2013. FRAME-BASED or frameless stereotactic BIOPSY: the debate continues. *Neuro Oncol.* 15. JOURNALS DEPT, 2001 EVANS RD, CARY, NC 27513 USA: OXFORD UNIV PRESS INC.
- Mizobuchi, Y., Nakajima, K., Fujihara, T., Matsuzaki, K., Mure, H., Nagahiro, S., Takagi, Y., 2019. The risk of hemorrhage in stereotactic biopsy for brain tumors. *J. Med. Invest.* 66 (3.4), 314–318. <https://doi.org/10.2152/jmi.66.314>. PMID: 31656296.
- Pasternak, K.A., Schwake, M., Warneke, N., Masthoff, M., Zawy Alsofy, S., Suero Molina, E., Stummer, W., Schipmann, S., 2021a. Evaluation of 311 contemporary cases of stereotactic biopsies in patients with neoplastic and non-neoplastic lesions—diagnostic yield and management of non-diagnostic cases. *Neurosurg. Rev.* 44 (5),

- 2597–2609. <https://doi.org/10.1007/s10143-020-01394-0>. Epub 2020 Sep 20. Erratum in: *Neurosurg Rev.* 2021 Aug 28; PMID: 32951126; PMCID: PMC8490258.
- Pasternak, K.A., Schwake, M., Warneke, N., Masthoff, M., Zawy Alsofy, S., Suero Molina, E., Stummer, W., Schipmann, S., 2021b. Evaluation of 311 contemporary cases of stereotactic biopsies in patients with neoplastic and non-neoplastic lesions—diagnostic yield and management of non-diagnostic cases. *Neurosurg. Rev.* 44 (5), 2597–2609. <https://doi.org/10.1007/s10143-020-01394-0>. Epub 2020 Sep 20. Erratum in: *Neurosurg Rev.* 2021 Aug 28; PMID: 32951126; PMCID: PMC8490258.
- Porter, A.B., Giannini, C., Kaufmann, T., Lucchinetti, C.F., Wu, W., Decker, P.A., Atkinson, J.L., O'Neill, B.P., 2008. Primary central nervous system lymphoma can be histologically diagnosed after previous corticosteroid use: a pilot study to determine whether corticosteroids prevent the diagnosis of primary central nervous system lymphoma. *Ann. Neurol.* 63 (5), 662–667. <https://doi.org/10.1002/ana.21366>. PMID: 18481293.
- Riche, M., Amelot, A., Peyre, M., Capelle, L., Carpentier, A., Mathon, B., 2021a. Complications after frame-based stereotactic brain biopsy: a systematic review. *Neurosurg. Rev.* 44 (1), 301–307. <https://doi.org/10.1007/s10143-019-01234-w>. Epub 2020 Jan 4. PMID: 31900737.
- Riche, M., Amelot, A., Peyre, M., Capelle, L., Carpentier, A., Mathon, B., 2021b. Complications after frame-based stereotactic brain biopsy: a systematic review. *Neurosurg. Rev.* 44 (1), 301–307. <https://doi.org/10.1007/s10143-019-01234-w>. Epub 2020 Jan 4. PMID: 31900737.
- Riche, M., Amelot, A., Peyre, M., Capelle, L., Carpentier, A., Mathon, B., 2021c. Complications after frame-based stereotactic brain biopsy: a systematic review. *Neurosurg. Rev.* 44 (1), 301–307. <https://doi.org/10.1007/s10143-019-01234-w>. Epub 2020 Jan 4. PMID: 31900737.
- Riche, M., Marijon, P., Amelot, A., Bielle, F., Mokhtari, K., Chambrun, M.P., Joncour, A.L., Idbaih, A., Touat, M., Do, C.H., Deme, M., Pasqualotto, R., Jacquens, A., Degos, V., Shotar, E., Chougar, L., Carpentier, A., Mathon, B., 2021d. Severity, timeline, and management of complications after stereotactic brain biopsy. *J. Neurosurg.* 136 (3), 867–876. <https://doi.org/10.3171/2021.3.JNS21134>. PMID: 34507289.
- Riche, M., Amelot, A., Peyre, M., Capelle, L., Carpentier, A., Mathon, B., 2021e. Complications after frame-based stereotactic brain biopsy: a systematic review. *Neurosurg. Rev.* 44 (1), 301–307. <https://doi.org/10.1007/s10143-019-01234-w>. Epub 2020 Jan 4. PMID: 31900737.
- Riche, M., Amelot, A., Peyre, M., Capelle, L., Carpentier, A., Mathon, B., 2021f. Severity, timeline, and management of complications after stereotactic brain biopsy. *J. Neurosurg.* 136 (3), 867–876. <https://doi.org/10.3171/2021.3.JNS21134>. PMID: 34507289.
- Riche, M., Amelot, A., Peyre, M., Capelle, L., Carpentier, A., Mathon, B., 2021g. Complications after frame-based stereotactic brain biopsy: a systematic review. *Neurosurg. Rev.* 44 (1), 301–307. <https://doi.org/10.1007/s10143-019-01234-w>. Epub 2020 Jan 4. PMID: 31900737.
- Riche, M., Amelot, A., Peyre, M., Capelle, L., Carpentier, A., Mathon, B., 2021h. Complications after frame-based stereotactic brain biopsy: a systematic review. *Neurosurg. Rev.* 44 (1), 301–307. <https://doi.org/10.1007/s10143-019-01234-w>. Epub 2020 Jan 4. PMID: 31900737.
- Riche, M., Amelot, A., Peyre, M., Capelle, L., Carpentier, A., Mathon, B., 2021i. Complications after frame-based stereotactic brain biopsy: a systematic review. *Neurosurg. Rev.* 44 (1), 301–307. <https://doi.org/10.1007/s10143-019-01234-w>. Epub 2020 Jan 4. PMID: 31900737.
- Riche, M., Amelot, A., Peyre, M., Capelle, L., Carpentier, A., Mathon, B., 2021j. Complications after frame-based stereotactic brain biopsy: a systematic review. *Neurosurg. Rev.* 44 (1), 301–307. <https://doi.org/10.1007/s10143-019-01234-w>. Epub 2020 Jan 4. PMID: 31900737.
- Vallejo, F.A., Eichberg, D.G., Morell, A.A., Shah, A.H., Di, L., Berry, K., Luther, E., Lu, V.M., Patel, N.V., Ivan, M.E., Komotar, R.J., 2022. Same-day discharge after brain tumor resection: a prospective pilot study. *J. Neuro Oncol.* 157 (2), 345–353. <https://doi.org/10.1007/s11060-022-03969-x>. Epub 2022 Feb 22. PMID: 35192136; PMCID: PMC8861287.
- Warnick, R.E., Longmore, L.M., Paul, C.A., Bode, L.A., 2003. Postoperative management of patients after stereotactic biopsy: results of a survey of the AANS/CNS section on tumors and a single institution study. *J. Neuro Oncol.* 62 (3), 289–296. <https://doi.org/10.1023/a:1023315206736>. PMID: 12777081.
- Wellmer, J., von der Groeben, F., Klarmann, U., Weber, C., Elger, C.E., Urbach, H., Clusmann, H., von Lehe, M., 2012. Risks and benefits of invasive epilepsy surgery workup with implanted subdural and depth electrodes. *Epilepsia* 53 (8), 1322–1332. <https://doi.org/10.1111/j.1528-1167.2012.03545.x>. Epub 2012 Jun 18. PMID: 22708979.