



## Hepatic failure and malnutrition as predisposing factors of cutaneous mucormycosis in a pediatric patient

Silvia Colman<sup>a</sup>, Gustavo Giusiano<sup>b,\*</sup>, Carmen Colman<sup>a</sup>, María de los Ángeles Sosa<sup>c</sup>,  
Florencia Rojas<sup>b</sup>

<sup>a</sup> Hospital Pediátrico Dr. Avelino Castelán, Resistencia, 3500, Argentina

<sup>b</sup> Instituto de Medicina Regional, Universidad Nacional del Nordeste, CONICET, Resistencia, 3500, Argentina

<sup>c</sup> Instituto de Medicina Regional, Universidad Nacional del Nordeste, Resistencia, 3500, Argentina

### ARTICLE INFO

#### Keywords:

*Lichtheimia ramosa*  
Pediatric  
Cutaneous mucormycosis  
Malnutrition

### ABSTRACT

The genus *Lichtheimia* is the third-most frequent genus isolated in mucormycosis. We report a cutaneous case caused by *Lichtheimia ramosa*, localized on the face of a pediatric patient, in the context of acute liver failure and caloric malnutrition. Several surgeries and treatment with liposomal amphotericin B enabled the patient's favorable evolution.

### 1. Introduction

Mucormycosis is an opportunistic infection caused by ubiquitous molds belonging to the order Mucorales. Mucormycosis cases have significantly increased over the last decade, probably due to the increasing population at risk [1–3]. The main factors that favor the development of mucormycosis include uncontrolled diabetes mellitus with metabolic acidosis and other forms of metabolic acidosis, treatment with corticosteroids, solid organ or bone marrow transplantation, prolonged neutropenia, severe burns, malignant hematologic disorders, malnutrition, deferoxamine therapy in patients receiving hemodialysis, iron overload as well as prematurity in pediatrics patients. This infection can also occur in immunocompetent patients after traumatic exposure to environmental contaminants. The course of these infections are aggressive, progresses rapidly with high mortality and morbidity rates [2–6].

*Lichtheimia* (ex *Absidia*, *Mycocladius*) is the third-most frequent genus isolated in mucormycosis, after *Rhizopus* and *Mucor* [1,7]. Data from Europe have documented 19%–29% prevalence of *Lichtheimia* species, which is significantly higher than USA and Asia [4,8,9]. In contrast, an international review of the English literature for all cases of zygomycosis from the original case published in 1885 until to 2005, reported 5% of cases caused by *Lichtheimia* species [1]. Case reports in Argentina are limited, mostly caused by *Rhizopus* species [10]. The epidemiological differences observed are probably related to ecological environments

and emphasizes the importance to know local epidemiology [3].

We report a cutaneous mucormycosis case caused by *Lichtheimia ramosa*, in a pediatric patient with acute liver failure and caloric malnutrition.

### 2. Case report

A 5 years old male patient from Presidencia Roque Sáenz Peña city (26° 47' 27" S, 60° 26' 29"), located in Chaco (Argentina), with a low familiarly socioeconomic status and background of epilepsy, on treatment, and fully vaccinated.

The patient was hospitalized with signs of poor nutrition status, generalized tonic-clonic seizures, vomiting, fever (41 °C) and symptoms of drowsiness. Parents denied any intake of toxic substance or home-made infusions. They only emphasized the change of an antiepileptic treatment from phenobarbital to valproic acid one week before presentation.

Due to the persistence of the symptoms despite the medication administered (lorazepam 0.1 g/kg + phenytoin 20mg/kg), abnormal alanine aminotransferase (ALT) 6000 U/l and aspartate aminotransferase (AST) 12000 U/l, the case was assumed as an acute hepatic failure with encephalopathy and transferred to a tertiary center.

Day 0. Clinical examination revealed a patient with caloric malnutrition (body weight 14.5 kg, weight-for-age 3rd percentile, dry skin and hair, muscle weakness, emaciated), comatose, fever, Glasgow Coma

\* Corresponding author.

E-mail address: [gusianogustavo@gmail.com](mailto:gusianogustavo@gmail.com) (G. Giusiano).

<https://doi.org/10.1016/j.mmcr.2021.12.005>

Received 25 August 2021; Received in revised form 15 December 2021; Accepted 27 December 2021

Available online 31 December 2021

2211-7539/© 2022 The Authors. Published by Elsevier B.V. on behalf of International Society for Human and Animal Mycology. This is an open access article

under the CC BY-NC-ND license (<http://creativecommons.org/licenses/by-nc-nd/4.0/>).

Scale less than 8, strabismus and anisocoric pupils. Hepatomegaly and a globose abdomen, soft and depressible, were also observed. Laboratory studies showed elevated levels of bilirubin (direct bilirubin 0.89 mg/dl, total bilirubin 4.38 mg/dl) and hepatic enzymes: alanine aminotransferase (ALT) 6700 U/l, aspartate aminotransferase (AST) 12800 U/l and alkaline phosphatase (AF) 352 U/l. Due to the shock symptoms, the patient required intubation and mechanical ventilation, vasoactive drugs and inotropic support. Blood and urine culture were performed before to start of empirical therapy with clindamycin and ceftazidime.

Serologic tests for hepatitis B and C, syphilis, Chagas, toxoplasmosis and HIV were negative.

On day +2, a rounded necrotic lesion with blackish edges on the chin area was observed. On day +3, the lesion progressed rapidly involving soft tissue, and communication with oral mucosa and mandible exposure was verified (Fig. 1A). Samples by resection of the necrotic tissue were obtained and transferred to the reference laboratory for mycological study. Rarely septate thick hyaline hyphae were observed in direct examinations. Giemsa stain of the necrotic tissue sample revealed broad pauciseptate hyaline hyphae, irregularly branched, with a large diameter, suggestive of mucormycosis. The sample was inoculated onto potato dextrose agar containing chloramphenicol (250 mg/L) at 28 °C and 37 °C. Diagnosis was assumed as cutaneous mucormycosis and treatment with liposomal amphotericin B (3 mg/Kg/day) was started.

On day +4, central nervous system compromise was excluded by Nuclear Magnetic Resonance of the brain with normal cytochemical analysis of the cerebrospinal fluid. As an additional therapeutic measure, the patient underwent a first surgical debridement. Grafting and suturing was performed on day +17 (Fig. 1 B).

After 48 h (Day +7) of the sample culture, cream and cottony with uncoloured reverse colonies were observed. Using lactophenol cotton blue, micromorphology of the colony showed abundant cinate side branches on the sporangiophores and pleomorphic giant cells with finger-like projections (Fig. 2). Based on morphological and physiological characteristics, the isolated was identified as *Lichtheimia ramosa*. The isolated was sent to the Mycology Department, INEI-ANLIS Dr. Carlos Malbrán, Buenos Aires, Argentina, for molecular identification by sequencing the complete ITS1-5.8S-ITS2 region of the ribosomal DNA (rDNA). Sequences obtained was compared with those published in GenBank using the Basic Local Alignment Search Tool (<http://blast.ncbi.nlm.nih.gov/Blast.cgi>). The isolate shared 99% homology with *L. ramosa* (JQ912662.1). Antifungal susceptibility testing was determined using the broth microdilution method according to document M38-A2 CLSI [11]. Minimal inhibitory concentrations (MIC) obtained were: fluconazole >64 µg/ml; voriconazole ≥16 µg/ml; itraconazole 0.06 µg/ml; amphotericin B ≤ 0.03 µg/ml; terbinafine 0.06 µg/ml.

After 25 days of treatment with liposomal amphotericin B, no

adverse effects were observed. The patient was transferred to the local hospital with good evolution, afebrile, lucid, to complete 30 days with antifungal treatment. The patient did not return to control.

### 3. Discussion

The incidence of mucormycosis has increased with rising numbers among the immunodeficient population. However, mucormycosis can also lead to serious infections in relatively immunocompetent hosts with no apparent immune deficiency other than a traumatic injury [12].

Underlying risk factors are correlated with the clinical presentation and the site of infection. While diabetes is well recognized as the most common risk factor, iron overload, drug use, and renal failure are seen less frequently but well-recognized, particularly in children. Cutaneous mucormycosis infections makes up 27% of all pediatric cases and are generally associated with burns and traumatic wounds, especially patients with no apparent trace of immunodeficiency [13]. We report a case of cutaneous mucormycosis in which neither the child or his family, referred any history of trauma on the infection site.

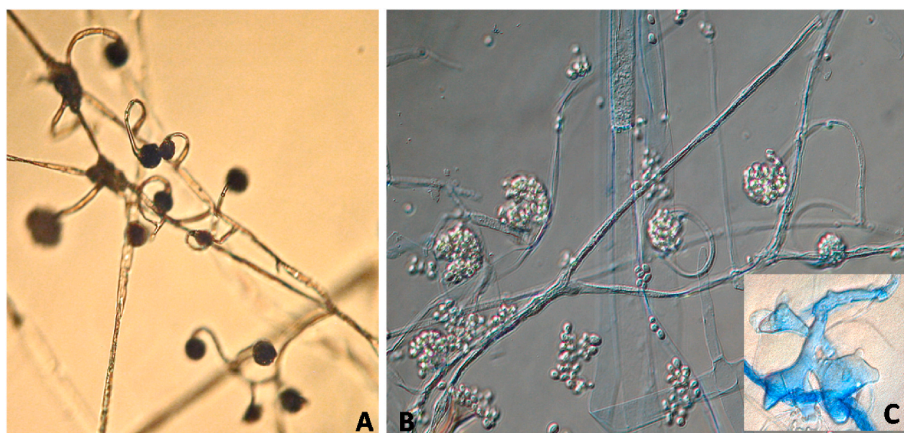
Valproate is a widely used anticonvulsant that can cause acute liver failure in children and adults [14,15]. Since his parents denied any history of intake of toxic and/or homemade infusions, the acute liver failure with encephalopathy detected was probably due to the valproic acid. The elevation of ALT above twice its normal value, as well as the increase in ALT/AF ratio greater than or equal to 5, classifies toxic hepatitis as hepatocellular and was associated with the use of drugs including valproic acid [14,15].

Metabolic acidosis, caloric malnutrition and treatment with broad spectrum antibiotics were defined as several risk factors for developing this opportunistic infection [16]. Since iron is utilized by zygomycetes for its growth, defective phagocytic function and decreased affinity of transferrin to iron may account for the predisposition of mucormycosis in metabolic acidosis [17]. Our patient presented all these predisposing factors, including a metabolic acidosis as consequence of his mal nutrition and hepatic dysfunction confirmed. Poor nutrition may compromise cellular immunity and has been considered an important underlying condition in developing fungal infections.

The genus *Lichtheimia* belongs to the family *Lichtheimiaceae*, in the fungal order Mucorales but taxonomy of the members of this genus has been changed in the last decades. Today, based on morphological, physiological and molecular data, six species have been described in this genus: *L. corymbifera*, *L. ornata*, *L. ramosa*, *L. hyalospora*, *L. sphaerocystis* and *L. brasiliensis*, of which only *L. corymbifera* and *L. ramosa* are considered clinically relevant [5,18]. A study performed by Woo et al. [19] showed that a significant proportion of infections caused by *L. corymbifera* (ex *Absidia corymbifera*) was, in fact, *L. ramosa* infections

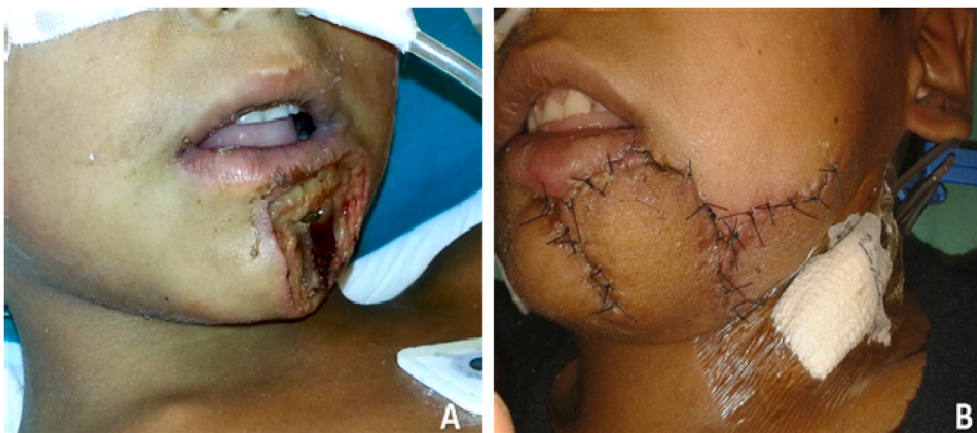

Fig. 1. A) Necrotic ulcer on the chin showing communication to oral mucosa and mandible exposure. B) Grafting and suturing performed 17 days after admission, under treatment with liposomal amphotericin B.



**Fig. 2.** Circinate side branches on the sporangiophores. A) Stereoscopic magnifying glass, 40X. B) Micromorphology using lactophenol cotton blue, 400X. C) Typical pleomorphic giant cells with finger-like projections, 400X. (For interpretation of the references to colour in this figure legend, the reader is referred to the Web version of this article.)

using both phenotypic and genotypic methods. In clinical microbiology laboratories, *L. ramosa* should be suspected if an *Absidia*-like mold that possesses abundant circinate side branches on the sporangiophores and pleomorphic giant cells with finger-like projections are observed. Although these structures are not exclusively found in *L. ramosa*, they are abundant in this species [5,19].

As all mucoralean fungi, *Lichtheimia* is a ubiquitous saprophyte and globally distributed. *L. ramosa*, is frequently isolated from soil, it can be found in putrefying vegetation, rotting fruits and in a variety of substrates including farming products as well as processed and unprocessed food products [18]. Socioeconomic conditions and the lifestyle of our patient probably are other important aspects to discuss, which could have influenced the development of mucormycosis. The housing environment, from the lack of potable water and garbage collection to the poor environmental conditions of his house, characterize the low familiarly socioeconomic status. In addition, the patient's parents referred that he usually takes baths in a lagoon near his house. In that environment, maybe the patient made contact with the fungus.

The prognosis in cutaneous mucormycosis is better than other clinical forms of the disease, but mortality still nearly remains 31% [1]. Due to the scarce therapeutic options, the early and accurate diagnosis are the most critical aspects in order to prevent disfiguring and debilitating surgeries [12]. Successful management of cutaneous mucormycosis usually requires a combination of measures including surgical debridement, control of the underlying risk factors and early antifungal therapy administration [12,20]. Those premises were applied for the management of our patient including, the improvement of the underlying health conditions observed on the admission day, accompanied with repeated surgical interventions and the indicated antifungal treatment. As a result, the infection could be contained.

Isolation and identification of the fungus to genus and species level is considered to be of epidemiological importance, predictive of the prognosis, and also its usefulness in guiding the management of infections [12]. Mucorales have differential responses to antifungal agents. A gold-standard therapy has not yet been established because of their intrinsic resistance to many of the commonly used antifungal drugs [2,4,5]. Amphotericin B still remains the agent of choice as empiric treatment for *L. ramosa* and other mucormycosis [3]. However, problems related to the optimal dosage and timing for treatment initiation for each site of infection are still under discussion [2,12,21]. In this case, amphotericin B MIC was  $\leq 0.03$   $\mu\text{g/ml}$  and the favorable evolution of the patient portrayed it as antifungal active against *L. ramosa*.

Researches on animal models demonstrate that development of *Lichtheimia* infections depend on the route of infection and the patient's state, especially its immunological state [18]. Most studies or reviews do

not analyze the relationship between types of infection with the causative species, therefore, it is difficult to evaluate the incidence of different types of infections and the predisposing risk factors for the development of *L. ramosa* infections.

The challenge to cure this infection, which can be devastating, is related to host-fungus interactions and pathogenic mechanisms and also to difficulties in the early diagnosis and the scarce therapeutic options available [12].

This report is a contribution to the epidemiology of mucormycosis caused by *Lichtheimia* species.

#### Funding source

All sources of funding should be acknowledged and you should declare any extra funding you have received for academic research of this work. If there are none state 'there are none'.

#### Sources of funding

Nothing to declare.

#### Consent

Written informed consent was obtained from the patient or legal guardian(s) for publication of this case report and accompanying images. A copy of the written consent is available for review by the Editor-in-Chief of this journal on request.

#### Declaration of competing interest

Please declare any financial or personal interests that might be potentially viewed to influence the work presented. Interests could include consultancies, honoraria, patent ownership or other. If there are none state 'there are none'.

#### Acknowledgements

We express our acknowledgment to Rubén Abrantes, (INEI-ANLIS Dr. Carlos Malbrán, Buenos Aires, Argentina), for his support in molecular identification by sequencing.

#### References

- [1] M.M. Roden, T.E. Zaoutis, W.L. Buchanan, T.A. Knudsen, T.A. Sarkisova, R. L. Schaefele, et al., Epidemiology and outcome of zygomycosis: a review of 929 reported cases, *Clin. Infect. Dis.* 41 (2005) 634–653.

- [2] U. Binder, E. Maurer, C. Lass-Flörl, Mucormycosis - from the pathogens to the disease, *Clin. Microbiol. Infect.* 20 (2014) 60–66.
- [3] O.A. Cornely, A. Alastruey-Izquierdo, D. Arenz, S.C.A. Chen, E. Dannaoui, B. Hochhegger, et al., Global guideline for the diagnosis and management of mucormycosis: an initiative of the European Confederation of Medical Mycology in cooperation with the mycoses study group education and research consortium, *Lancet Infect. Dis.* 19 (2019) e405–e421.
- [4] A. Skiada, L. Pagano, A. Groll, S. Zimmerli, B. Dupont, K. Lagrou, et al., Zygomycosis in Europe: analysis of 230 cases accrued by the registry of the European Confederation of Medical Mycology (ECMM) working group on zygomycosis between 2005 and 2007, *Clin. Microbiol. Infect.* 17 (2011) 1859–1867.
- [5] A. Alastruey-Izquierdo, K. Hoffmann, G.S. de Hoog, J.L. Rodriguez-Tudela, K. Voigt, E. Bibashi, et al., Species recognition and clinical relevance of the zygomycetous genus *Lichtheimia* (syn. *Absidia pro parte, Mycocladus*), *J. Clin. Microbiol.* 48 (2010) 2154–2170.
- [6] J. Pan, C. Tsui, M. Li, K. Xiao, G.S. de Hoog, P.E. Verweij, et al., First case of rhinocerebral mucormycosis caused by *Lichtheimia ornata*, with a review of *Lichtheimia* infections, *Mycopathologia* 185 (2020) 555–567.
- [7] V.U. Schwartze, I.D. Jacobsen, Mucormycoses Caused by *Lichtheimia* Species 57, 2014, pp. 1–6.
- [8] M. Rüping, W. Heinz, A. Kindo, V. Rickerts, C. Lass-Flörl, C. Beisel, et al., Forty-one recent cases of invasive zygomycosis from a global clinical registry, *J. Antimicrob. Chemother.* 65 (2010) 296–302.
- [9] F. Lanternier, E. Dannaoui, G. Morizot, C. Elie, D. Garcia-Hermoso, M. Huerre, et al., A global analysis of mucormycosis in France: the RetroZygo study (2005–2007), *Clin. Infect. Dis.* 54 (2012) 35–43.
- [10] I. Tiraboschi, M. Bravo, N. Fernández, D. Stecher, M. Melero, M. Lasala, [Mucormycosis. An emergent mycosis], *Medicina* 72 (2012) 23–27.
- [11] C.L.S.I. Reference, Method for broth dilution antifungal susceptibility testing of filamentous fungi ; approved standard, in: CLSI Document M38-A2, second ed., Clinical and Laboratory Standards Institute, Wayne, PA, 2008.
- [12] A. Katragkou, T.J. Walsh, E. Roilides, Why is mucormycosis more difficult to cure than more common mycoses? *Clin. Microbiol. Infect.* 20 (2014) 74–81.
- [13] J.R. Francis, P. Villanueva, P. Bryant, C.C. Blyth, Mucormycosis in children: review and recommendations for management, *J. Pediatr. Infect. Dis. Soc.* 7 (2018) 159–164.
- [14] P. Mc Kiernan, Acute liver failure after valproate exposure: liver transplantation may be indicated beyond childhood, *Liver Transplant.* 20 (2014) 1287–1289.
- [15] A.L. Mindikoglu, D. King, L.S. Magder, J.A. Ozolek, G.V. Mazariegos, B.L. Shneider, Valproic acid-associated acute liver failure in children: case report and analysis of liver transplantation outcomes in the United States, *J. Pediatr.* 158 (2011) 802–807.
- [16] A. Skiada, G. Petrikos, Cutaneous zygomycosis, *Clin. Dermatol.* 30 (2012) 413–419.
- [17] T.R. Rogers, Treatment of zygomycosis: current and new options, *J. Antimicrob. Chemother.* 61 (2008) 35–40.
- [18] V.U. Schwartze, I.D. Jacobsen, Mucormycoses caused by *Lichtheimia* species, *Mycoses* 57 (2014) 73–78.
- [19] P.C. Woo, S.Y. Leung, A.H. Ngan, S.K. Lau, K.Y. Yuen, A significant number of reported *Absidia corymbifera* (*Lichtheimia corymbifera*) infections are caused by *Lichtheimia ramosa* (syn. *Lichtheimia hongkongensis*): an emerging cause of mucormycosis, *Emerg. Microb. Infect.* 1 (2012) e15.
- [20] B. Spellberg, T.J. Walsh, D.P. Kontoyiannis Jr., J.E. A.S. Ibrahim, Recent advances in the management of mucormycosis: from bench to bedside, *Clin. Infect. Dis.* 48 (2009) 1743–1751.
- [21] A. Alastruey-Izquierdo, I. Cuesta, G. Walther, M. Cuenca-Estrella, J.L. Rodriguez-Tudela, Antifungal susceptibility profile of human-pathogenic species of *Lichtheimia*, *Antimicrob. Agents Chemother.* 54 (2010) 3058–3060.