

NEUROLOGY

Tumor suppressor in lung cancer-1 (TSLC1) functions as a glioma tumor suppressor

S. S. Houshmandi, E. I. Surace, H. B. Zhang, G. N. Fuller and D. H. Gutmann
Neurology 2006;67;1863-1866
DOI: 10.1212/01.wnl.0000244472.56198.84

This information is current as of November 27, 2006

The online version of this article, along with updated information and services, is located on the World Wide Web at:

<http://www.neurology.org/cgi/content/full/67/10/1863>

Neurology is the official journal of AAN Enterprises, Inc. A bi-monthly publication, it has been published continuously since 1951. Copyright © 2006 by AAN Enterprises, Inc. All rights reserved. Print ISSN: 0028-3878. Online ISSN: 1526-632X.



Tumor suppressor in lung cancer-1 (TSLC1) functions as a glioma tumor suppressor

Abstract—Tumor suppressor in lung cancer-1 (TSLC1) loss is common in many human cancers, including meningioma. In this study, we demonstrate that TSLC1 protein and RNA expression is lost in 60% to 65% of high-grade gliomas, and that *TSLC1* reintroduction into glioma cells results in growth suppression. Moreover, *Tslc1* loss in mice results in increased astrocyte proliferation in vivo and in vitro. These data indicate that TSLC1 functions as a glioma tumor suppressor.

NEUROLOGY 2006;67:1863–1866

S.S. Houshmandi, PhD; E.I. Surace, PhD; H.B. Zhang, MD, PhD; G.N. Fuller, MD, PhD; and D.H. Gutmann, MD, PhD

Recent advances in molecular genetics have led to the identification of novel genes involved in brain tumor pathogenesis. In this regard, tumor suppressor in lung cancer-1 (TSLC1), originally identified as a non-small-cell lung cancer tumor suppressor,¹ is involved in the pathogenesis of diverse types of human cancers,^{2,3} including meningioma.⁴ TSLC1 is expressed in human leptomeninges but is lost or markedly reduced in 30% of World Health Organization (WHO) Grade I meningiomas.⁴ In normal rodent tissues, *Tslc1* messenger RNA (mRNA) is likewise expressed in astrocytes,⁵ raising the possibility that TSLC1 might also be important in the molecular pathogenesis of astrocytoma. In this study, we demonstrate loss or marked reduction of TSLC1 expression in high-grade astrocytoma (glioma) at both the protein and RNA levels. Consistent with its role as a tumor suppressor, reintroduction of TSLC1 in *TSLC1*-deficient glioma cells results in growth suppression. Moreover, *Tslc1* loss in genetically engineered mice results in increased astrocyte proliferation in vivo and in vitro.

Methods. *Patient samples.* The glioma tissue microarray (TMA) was assembled at the MD Anderson Cancer Center (G.N.F.) as previously described.⁶ Additional tumor samples were obtained from the Washington University/Siteman Cancer Center Tumor Tissue Repository. Human tissues were used in accordance with approved human studies protocols.

Immunohistochemistry. TSLC1 antibody (ES1; 1:20,000 dilution) and Vectastain ABC development (Vector Laboratories, Burlingame, CA) were used for immunohistochemical analysis.

From the Department of Neurology, Washington University School of Medicine, St. Louis, MO (S.S.H., E.I.S., H.B.Z., D.H.G.); and the Department of Pathology, MD Anderson Cancer Center, Houston, TX (G.N.F.).

Supported in part from grants from the James F. McDonnell Foundation and the Department of Defense (DAMD-17-04-0266 to D.H.G.). S.S.H. is supported by a nested postdoctoral fellowship from the Department of Defense. The Siteman Cancer Center is supported in part by NCI Cancer Center Support Grant #P30 CA91842.

Disclosure: The authors report no conflicts of interest.

Received May 12, 2006. Accepted in final form July 28, 2006.

Address correspondence and reprint requests to Dr. David H. Gutmann, Department of Neurology, Washington University School of Medicine, Box 8111; 660 S. Euclid Avenue, St. Louis, MO 63110; e-mail: gutmann@wustl.edu

Western blots. Samples were lysed in NP-40 lysis buffer with protease inhibitors, and proteins were separated by sodium dodecyl sulfate polyacrylamide gel electrophoresis before Western blot analysis with TSLC1 (ES1; 1:2,000 dilution), S6 (Cell Signaling Technology, Beverly, MD; 1:2,000 dilution), and α -tubulin (Sigma, St. Louis MO; 1:10,000 dilution) antibodies. Densitometric analysis was performed using the Gel-Pro Analyzer 4.0 (MediaCybernetics, Silver Spring, MD) with α -tubulin or S6 as a loading control.

Real-time reverse-transcription PCR. Complementary DNAs (cDNAs) were prepared from 1 μ g of total RNA. Real-time reverse-transcription (RT) PCR was performed and analyzed as previously described.⁷

Clonogenic assays. 10⁵-U87 glioblastoma cells per well were transfected with 2 μ g of pcDNA3.hygro or pcDNA3.hygro.TSLC1 plasmid DNA using Lipofectamine reagent (Invitrogen, Carlsbad, CA) before selection with Hygromycin B (200 μ g/mL; Roche Diagnostics, Indianapolis, IN) for 14 to 21 days. Surviving colonies were stained with crystal violet and counted.

Tslc1^{+/-} mice. *Tslc1^{+/-}* mice were generated at the J. David Gladstone Institute (University of California, San Francisco) from BayGenomics XI486 embryonic stem cells.⁸

Immunofluorescence. One-week-old *Tslc1^{+/+}* (WT) and *Tslc1^{+/-}* mice (n = 3) were injected with 5-bromo-2-deoxyuridine (50 μ g/g BrdU; Sigma). After 2 hours, mice were killed, and their brains were fixed in 4% paraformaldehyde. Brain sections were immunolabeled with BrdU (1:100 dilution; Abcam, Cambridge, MA) and glial fibrillary acidic protein (GFAP; 1:200 dilution; Sigma) antibodies followed by Alexa 488 (BrdU; 1:200 dilution; Abcam Cambridge, MA) and Cy3 (GFAP; 1:500 dilution; Sigma) secondary antibodies. The number of BrdU-positive cells in the hippocampus from each set of three littermates was determined.

Thymidine incorporation assay. Primary astrocyte cultures were generated from 3-day-old WT and *Tslc1^{+/-}* mouse brains as previously described,⁹ and seeded at 5 \times 10⁴ cells per well for 24 hours of serum starvation. [³H]-thymidine (1 μ Ci per well) was added in serum-free media, and the counts per minute were determined after 24 hours.

Results. Immunohistochemical analysis denoted no loss of TSLC1 expression in 26 WHO Grade I and 6 Grade II gliomas. In contrast, 60% of the WHO Grade III gliomas and 65% of the WHO Grade IV (glioblastoma or GBM) glioma samples showed loss of TSLC1 expression (figure 1, A and B). TSLC1 loss was more common in astrocytic neoplasms; most oligodendrogliomas retained TSLC1 expression (42/46; 91%). Because frozen specimens from these TMA tumors were not available, GBM samples from an independent set of 25 patients were examined for TSLC1 expression at both protein and the mRNA levels. Western blotting and densitometric analysis demonstrated more than a twofold reduction in TSLC1 expression in 15 tumors (60%), with 8 tumors showing more than a fourfold reduction (32%; representative data shown in figure 1B). The remaining tumors demon-

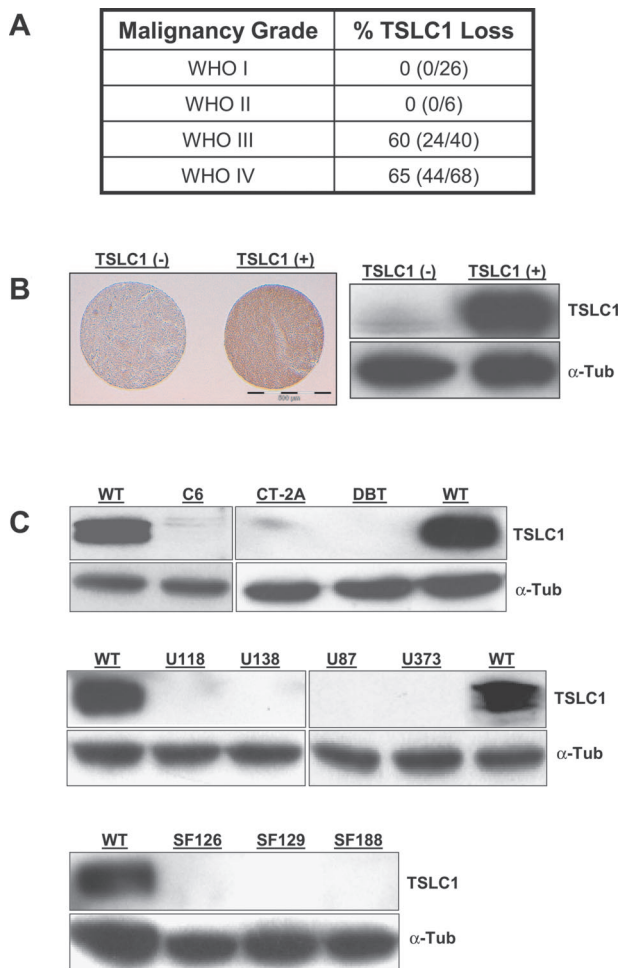


Figure 1. TSLC1 expression in glioma. (A) TSLC1 immunohistochemistry was performed on gliomas representing each World Health Organization (WHO) malignancy grade. Whereas no loss of TSLC1 expression was observed in WHO Grade I and II gliomas, anaplastic astrocytoma (WHO III) and glioblastoma (WHO IV) exhibited 60% to 65% loss of TSLC1 expression. (B) Representative immunohistochemical results from one TSLC1-immunopositive (TSLC1+) and one TSLC1-immunonegative (TSLC1-) WHO IV glioma (left panel) are shown. Magnification = 20 \times . Also included is a representative Western blot of TSLC1 expression in two human glioblastoma (GBM) tumor samples (right panel), demonstrating both retention and loss of TSLC1 protein expression. (C) Western blot analysis of TSLC1 expression in several glioma cell lines, including rat C6, mouse CT-2A and DBT (top panel), human U118, U138, U87, and U373 (middle panel), and human SF126, SF129, and SF188 (bottom panel) cells, demonstrates loss of TSLC1 protein expression in all cell lines. Normal mouse astrocytes (WT) were included as a positive control for TSLC1 expression. α -Tubulin was used as an internal control for equal protein loading.

strated less than twofold decreases in TSLC1 expression. To determine whether TSLC1 loss was observed at the RNA level, we examined TSLC1 mRNA expression by real-time RT-PCR using TSLC1-specific primers in the same samples examined by Western blot. We observed a similar pattern of TSLC1 mRNA loss in these GBM specimens (data not shown). There was an 84%

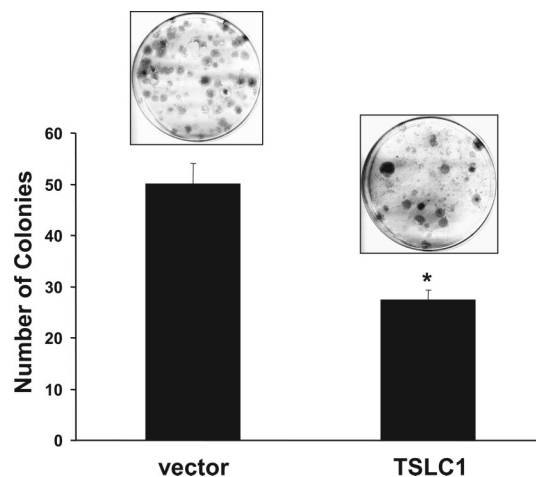


Figure 2. TSLC1 re-expression results in reduced glioma growth. U87 cells transfected in triplicate with either an empty vector or a vector containing human TSLC1 were selected in hygromycin, and the number of colonies was determined after 2 to 3 weeks. A representative plate from each transfection is shown. The number of colonies in the TSLC1-transfected U87 cells was significantly reduced relative to empty vector. * $p < 0.003$, unpaired t test.

concordance between TSLC1 protein and TSLC1 RNA loss in these tumors. Last, no TSLC1 expression was observed in a panel of both human and rodent high-grade glioma cell lines (figure 1C).

Previous studies from our laboratory and others have shown that TSLC1 functions as a negative growth regulator (tumor suppressor) when reintroduced into TSLC1-deficient tumor cells.^{4,10} We used clonogenic assays on the TSLC1-deficient human U87 glioblastoma cell line to assess TSLC1 growth suppression. TSLC1 re-expression resulted in a twofold reduction in the number of hygromycin-resistant U87 colonies compared with vector-transfected cells (figure 2).

Because TSLC1 loss is not the only genetic change in high-grade glioma, we sought to determine whether *Tslc1* loss in mice was sufficient to confer an astrocyte growth advantage in vivo and in vitro. Recent studies from our laboratory have shown that mice heterozygous for an inactivating *Tslc1* gene mutation exhibit >90% reduction in *Tslc1* expression in the brain⁸ and in derivative astrocytes (figure 3B). To determine the effect of *Tslc1* expression on astrocyte proliferation in vivo, WT and *Tslc1*^{+/-} mice were injected with BrdU and analyzed by immunofluorescence with BrdU and GFAP antibodies. We observed a twofold increase in both BrdU-positive and GFAP-positive cells in the hippocampus of *Tslc1*^{+/-} mice compared with WT littermates (figure 3A). Similar increases in BrdU-positive and GFAP-positive cells were observed in other brain regions (e.g., neocortex) of *Tslc1*^{+/-} mice (data not shown).

Because not all of the proliferating BrdU-positive cells colabeled with GFAP, we next sought to directly measure the effect of reduced *Tslc1* expression on astrocyte proliferation in vitro. Using [³H]-thymidine incorporation, we observed a twofold increase in proliferation in *Tslc1*^{+/-} astrocytes relative to WT astrocytes (figure 3B). Collectively, these results provide direct evidence that TSLC1 functions as an astrocyte growth regulator.

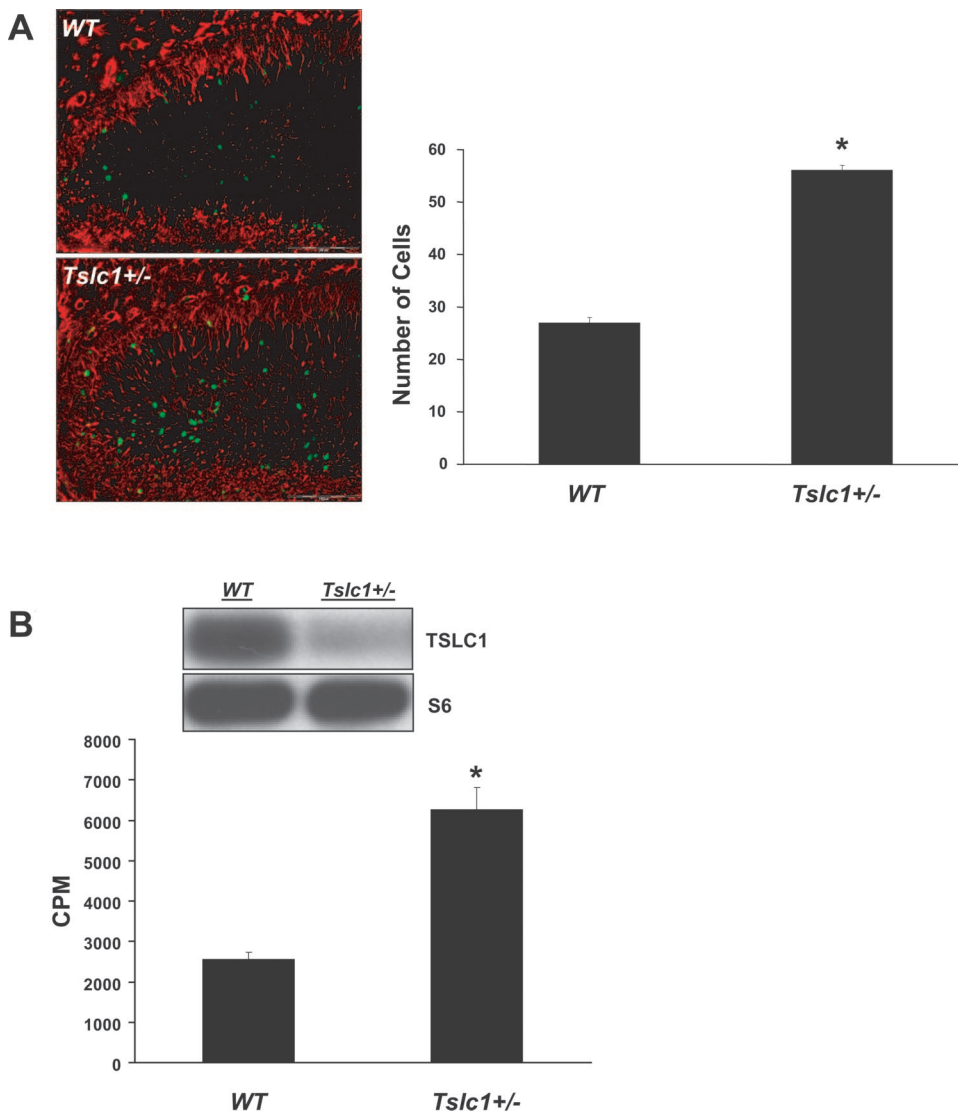


Figure 3. Reduced Tslc1 expression results in increased astrocyte proliferation in vivo and in vitro. (A) Representative immunofluorescence photomicrograph images of the hippocampus from BrdU-injected Tslc1^{+/+} (WT) and Tslc1^{+/-} mice are shown, labeled with both BrdU (green) and GFAP (red) antibodies. Tslc1^{+/-} mice exhibit an increase in the number of BrdU+ and GFAP+ labeled cells compared with WT littermates. BrdU+ cells from three different sections of both WT and Tslc1^{+/-} mice brains were counted and averaged ($n = 3$ mice per genotype). Twofold more BrdU+ cells were observed in the Tslc1^{+/-} compared with the WT brain sections. * $p < 0.001$, unpaired t test (right panel). (B) Western blot analysis demonstrates >90% reduction in Tslc1 protein expression in Tslc1^{+/-} astrocytes compared with WT astrocytes. S6 protein expression was used as an internal control for equal protein loading. Using [³H]-thymidine incorporation to measure astrocyte proliferation, Tslc1^{+/-} astrocytes exhibited an average twofold increased proliferation relative to WT astrocytes in vitro ($n = 3$). * $p < 0.001$, unpaired t test (bottom panel).

Discussion. In this report, we demonstrate TSLC1 loss at the protein and RNA levels in high-grade (WHO III/IV) glioma but not in low-grade WHO I or II glial neoplasms. These findings suggest that TSLC1 is most likely associated with malignant progression, rather than glioma formation. Similar to our previous findings in meningioma, TSLC1 loss predominated in high-grade tumors with high proliferative indices.⁴ Interestingly, TSLC1 loss was not observed in another glial cell tumor (oligodendroglioma), which may reflect a unique role for TSLC1 in astrocyte growth control.

Because genomic alterations involving chromosome 11q23 are rare in glioma, as is true for meningioma, the mechanism of TSLC1 gene inactivation likely involves epigenetic silencing (e.g., promoter methylation). Future studies will be required to determine whether methylation accounts for the reduced TSLC1 expression observed in glioma.

Consistent with the function of TSLC1 as a negative growth regulator, we show that the TSLC1 suppresses human glioma growth in vitro and mouse astrocyte proliferation in vivo and in vitro. These

latter data demonstrate a direct effect of Tslc1 on astrocyte proliferation and suggest that TSLC1 modulates pathways important for glial cell growth. Studies are ongoing to define the mechanism of TSLC1 growth regulation in the brain.

Acknowledgment

The authors thank the Alvin J. Siteman Cancer Center at Washington University School of Medicine and Barnes-Jewish Hospital in St. Louis, MO, for use of the Tissue Procurement Core, which provided the GBM tumor specimens.

References

1. Kuramochi M, Fukuhara H, Nobukuni T, et al. TSLC1 is a tumor-suppressor gene in human non-small-cell lung cancer. *Nat Genet* 2001; 4:427–430.
2. Ito T, Shimada Y, Hashimoto Y, et al. Involvement of TSLC1 in progression of esophageal squamous cell carcinoma. *Cancer Res* 2003;63:6320–6326.
3. Uchino K, Ito A, Wakayama T, et al. Clinical implication and prognostic significance of the tumor suppressor TSLC1 gene detected in adenocarcinoma of the lung. *Cancer* 2003;98:1002–1007.
4. Surace EI, Lusic E, Murakami Y, Scheithauer BW, Perry A, Gutmann DH. Loss of tumor suppressor in lung cancer-1 (TSLC1) expression in meningioma correlates with increased malignancy grade and reduced patient survival. *J Neuropathol Exp Neurol* 2004;63:1015–1027.

- Ohta Y, Itoh K, Yaoi T, Tando S, Fukui K, Fushiki S. Spatiotemporal patterns of expression of IGSF4 in developing mouse nervous system. *Brain Res Dev Brain Res* 2005;156:23–31.
- Wang H, Wang H, Zhang W, Fuller GN. Tissue microarrays: applications in neuropathology research, diagnosis and education. *Brain Pathol* 2002;12:95–107.
- Sharma MK, Watson MA, Lyman M, et al. Matrilin-2 expression distinguishes clinically relevant subsets of pilocytic astrocytoma. *Neurology* 2006;66:127–130.

- Surace EI, Strickland A, Hess RA, Gutmann DH, Naughton CK. Tslc1 (Nectin-like molecule-2) is essential for spermatozoa motility and male fertility. *J Androl* 2006 (in press).
- Dasgupta B, Li W, Perry A, Gutmann DH. Glioma formation in neurofibromatosis 1 reflects preferential activation of K-RAS in astrocytes. *Cancer Res* 2005;65:236–245.
- Mao X, Seidlitz E, Truant R, Hitt M, Ghosh HP. Re-expression of TSLC1 in a non-small-cell lung cancer cell line induces apoptosis and inhibits tumor growth. *Oncogene* 2004;23:5632–5642.

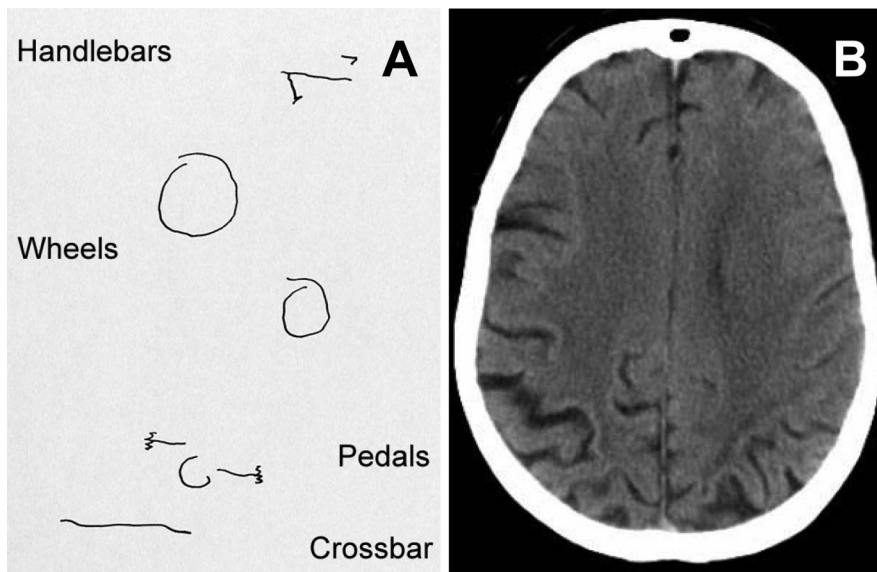


Figure. (A) The patient's disjointed attempt at drawing a bicycle with items scattered over the page (exploded drawing). Once she lifted her pen from the page she could not see the drawing and could only guess where to place the pen next. (B) The patient's CT scan at the time of assessment showing mild posterior cortical atrophy.

Exploded drawing in posterior cortical atrophy

Paul McMonagle, MRCPI, MD; and
Andrew Kertesz, MD, FRCPC, London, Ontario, Canada

A 69-year-old woman was referred with a progressive 2-year history of problems reading, locating items in front of her, and knocking over things she reached for. Examination revealed normal acuity and visual fields, slowness directing voluntary sac-

ades (oculomotor apraxia), and mis-reaching toward visual targets (optic ataxia). Her drawing (figure, A) was grossly distorted but cognition was otherwise normal.

Drawing tasks may be underutilized in dementia assessment¹ but this patient's exploded drawing² illustrates the inability to perceive and bind elements of a scene together, characteristic of simultanagnosia. The progressive Balint's syndrome, preservation of memory, and scan findings (figure, B) suggest the diagnosis of posterior cortical atrophy, which often has underlying Alzheimer pathology.

Copyright © 2006 by AAN Enterprises, Inc.

Disclosure: The authors report no conflicts of interest.

Address correspondence and reprint requests to Dr. McMonagle, Wessex Neurological Centre, Southampton General Hospital, Tremona Road, Southampton SO16 YD, UK; e-mail: paul.mcmonagle@suht.swest.nhs.uk

- Kirk A, Kertesz A. On drawing impairment in Alzheimer's disease. *Arch Neurol* 1991;48:73–77.
- Godwin-Austen RB. A case of visual disorientation. *J Neurol Neurosurg Psychiatry* 1965;28:453–458.

Tumor suppressor in lung cancer-1 (TSLC1) functions as a glioma tumor suppressor

S. S. Houshmandi, E. I. Surace, H. B. Zhang, G. N. Fuller and D. H. Gutmann
Neurology 2006;67;1863-1866

DOI: 10.1212/01.wnl.0000244472.56198.84

This information is current as of November 27, 2006

Updated Information & Services

including high-resolution figures, can be found at:
<http://www.neurology.org/cgi/content/full/67/10/1863>

Subspecialty Collections

This article, along with others on similar topics, appears in the following collection(s):
All Oncology
http://www.neurology.org/cgi/collection/all_oncology **Primary brain tumor**
http://www.neurology.org/cgi/collection/primary_brain_tumor

Permissions & Licensing

Information about reproducing this article in parts (figures, tables) or in its entirety can be found online at:
<http://www.neurology.org/misc/Permissions.shtml>

Reprints

Information about ordering reprints can be found online:
<http://www.neurology.org/misc/reprints.shtml>

