

·Original Article·

Testicular fine needle aspiration as a diagnostic tool in non-obstructive azoospermia

A. Bettella¹, A. Ferlin¹, M. Menegazzo¹, M. Ferigo¹, I. M. Tavolini², P. F. Bassi², C. Foresta¹

¹Department of Histology, Microbiology and Medical Biotechnologies, Centre for Male Gamete Cryopreservation,

²Department of Surgical and Oncological Sciences, Clinical Urology, University of Padova, Padova 35121, Italy

Abstract

Aim: To report the fine needle aspiration cytology (FNAC) of the testes used as a diagnostic tool in non-obstructive azoospermic patients. **Methods:** One hundred and twenty-five non-obstructive azoospermic male candidates to intracytoplasmic sperm injection (ICSI) were analysed for follicle stimulating hormone (FSH), luteinizing hormone (LH), testosterone and inhibin B plasma levels. They were classified into three groups on the basis of FNAC: 1) Sertoli cell-only syndrome (SCOS) (70); 2) severe hypospermatogenesis (42); and 3) maturation arrest (13). Then, all men underwent testicular sperm extraction (TESE) for sperm recovery for ICSI. **Results:** Mature spermatozoa were detected by FNAC in 24 of 42 men with severe hypospermatogenesis and nine of 13 men with maturation arrest; while they were retrieved by TESE in 29 of 70 men with SCOS, 35 of 42 men with severe hypospermatogenesis (including the 24 by FNAC) and 10 of 13 men with maturation arrest (including the nine by FNAC). The sensitivity and specificity of FNAC were 44.6 % and 100 %, respectively. There was no difference on testicular volume and hormonal parameters in men with and without sperm retrieved. **Conclusion:** These findings suggest that FNAC may be a simple and valid diagnostic parameter in non-obstructive azoospermic men and it may represent a valid positive prognostic parameter for sperm recovery at TESE. (*Asian J Androl* 2005 Sep; 7: 289–294)

Keywords: oligospermia; fine needle aspiration; diagnosis; ICSI

1 Introduction

Azoospermia is present in about 10 %–15 % of men evaluated for infertility [1]. This condition represents the final result of different testicular alterations, ranging from normal spermatogenesis with seminal tract obstruc-

tion or absence of vas deferens (obstructive azoospermia) to different impairment of the spermatogenic process, including hypospermatogenesis, maturation arrest and complete absence of germ cells-Sertoli cell-only syndrome (SCOS) (non-obstructive azoospermia) [2–4].

Before the introduction of intracytoplasmic sperm injection (ICSI) [5], the only available treatment for men with azoospermia was adoption or sperm donor. ICSI and the modern techniques for sperm recovery from different regions of the male reproductive tract have led to the successful treatment of these patients. Therefore, testicular biopsy has become an important therapeutic procedure for testicular sperm recovery in non-obstruc-

Correspondence to: Prof. Carlo Foresta, Department of Histology, Microbiology, and Medical Biotechnologies, Centre for Male Gamete Cryopreservation, University of Padova, Via Gabelli 63, 35121 Padova, Italy.

Tel: +39-049-821-2639, Fax: +39-049-821-3222

E-mail: carlo.foresta@unipd.it

Received 2004-12-20 Accepted 2005-02-04

tive azoospermic patients, and testicular sperm extraction (TESE) is successful in 40 % – 60 % of these patients [6–10]. Furthermore, sperm retrieved from the testes have been shown to be able to move and fertilize the oocyte [11–13]. Nevertheless, testicular biopsy for TESE is an invasive procedure and may be associated with complications [14, 15]. Ideally, therefore, it should be performed only when there is a high probability of finding mature spermatozoa within the testis, in order to avoid an unnecessary induction of multiple follicular growth in the partner. Reliable prognostic methods for successful sperm recovery are therefore needed.

To this aim several possible clinical and biochemical predictive factors, such as serum levels of follicle stimulating hormone (FSH), luteinizing hormone (LH), inhibin B, testosterone and testicular volume, have been proposed, but to date none of these has been shown to be adequate [7, 8, 16].

Fine needle aspiration cytology (FNAC) of the testes was proposed in 1992 and has been demonstrated to represent a minimally invasive and reliable parameter in the study of the seminiferous epithelium and spermatogenic process in severely infertile men [2, 3, 17]. Testicular cytological analysis is relatively simple and allows the identification of different clinical groups of infertile subjects and different kinds of testicular tubular alteration in azoospermic subjects. In the present retrospective study we evaluated the prognostic value of FNAC for testicular sperm recovery by TESE in non-obstructive azoospermia.

2 Materials and methods

2.1 Patient selection

A total of 125 infertile patients with non-obstructive azoospermia and candidates to ICSI evaluated in the Centre for Male Gamete Cryopreservation of the University of Padova between March 1999 and April 2004, were reviewed in this study. Patients with obstructive azoospermia diagnosed by bilateral FNAC were excluded. All men presented a normal 46,XY karyotype and did not carry Y chromosome microdeletions.

Azoospermia was documented on at least three semen analyses after centrifugation and subsequent examination of the re-suspended pellet. Each subject was evaluated with a clinical history and a full physical examination. Hormonal determination included serum FSH, LH, inhibin B and testosterone. All patients underwent ultrasound scanning of the testes to evaluate tes-

ticular size and morphology before undergoing testicular aspiration.

2.2 Bilateral fine needle aspiration cytology

The spermatogenic activity of the participants was studied by means of bilateral testicular FNAC, performed as previously described [2, 3, 17]. Briefly, aspiration was performed with a 23-gauge (0.6 mm) butterfly needle attached to a 20 mL syringe. The retrieved material from each testis was placed on two or more microscope slides, allowed to air-dry for 24 h, stained with May-Grünwald and Giemsa and examined under light microscope at $\times 125$, $\times 400$ and $\times 1250$ magnifications. This method allows the identification of all germ cells in their different maturation steps as well as Sertoli cells and permits to clarify the different kinds of tubular damage. We counted ≥ 200 consecutive spermatogenic cells per smear and recorded all Sertoli cells observed. Cytologic analysis allowed us to identify the following spermatogenetic cell types: spermatogonia, primary and secondary spermatocytes, early and late spermatids (corresponding to Sa-Sb and Sc-Sd steps of spermatogenesis, respectively) and spermatozoa. The relative numbers of each cell type were expressed as percentages. Sertoli Index (SEI, the ratio of the number of Sertoli cells to spermatogenic cells) constitutes an attempt to quantify the spermatogenic activity: because the number of Sertoli cells in adults is constant per unit of tubular length, an increase in SEI may reveal the existence of tubular germ cell depopulation and thus hypospermatogenesis [2, 3, 17].

On the basis of FNAC analysis, the 125 subjects were divided into three cytological groups: 1) SCOS (when no germ cells were observed in both testes) in 70 cases (56.0 %); 2) severe hypospermatogenesis (when SEI was ≥ 300 , with normal value of < 50) in 42 cases (33.6 %); and 3) maturation arrest (spermatogonial-spermatocyte and spermatidic stage arrest with strong reduction or absence of mature sperm) in 13 cases (10.4 %). Patients with SEI ≤ 300 were excluded because they were considered having obstructive azoospermia.

2.3 Testicular sperm extraction

All patients underwent bilateral testicular open biopsy to retrieve sperm by using assisted reproductive techniques. TESE was performed under sedation with spermatic cord block with 0.5 % bupivacaine solution. After transverse incision of the tunica albuginea on the anterior surface of the testis, two small specimens of a diameter of approxi-

mately 5 mm were excised from each testis utilizing sharp scissors. Testis specimens were placed in a Petri dish with 2 mL of Biggers, Whitten and Whittingham (BWW) medium (Irvine Scientific, Santa Ana, CA, USA), mechanically sectioned by means of sterile slides and then further gently minced by sterile needles. After testicular shredding the testicular suspension was vortexed for 5 min and then transferred into a 15-mL conical tube containing 2 mL fresh medium and centrifuged at $1200 \times g$ for 10 min. The supernatant was then discarded, the pellet resuspended with 1 mL of BWW medium and vortexed for 2 min. Under an inverted microscope at $\times 400$ magnification, the testicular suspension was checked for the presence of mature sperm. If sperm were found, the sample was frozen with the method described previously [18] for future ICSI use.

2.4 Statistical analysis

Comparisons between the groups were performed with Student's *t*-test. When the distribution of values was not normal (assessed by the Kolmogorov–Smirnov test), the Wilcoxon sum of ranks test was used. $P < 0.05$ were regarded as statistically significant. Data are expressed as mean \pm SD.

Table 1. Clinical conditions associated with non-obstructive azoospermia.

Diagnosis	<i>n</i>	(%)
Varicocele	18	(14.4)
Cryptorchidism	28	(22.4)
Post-mumps orchitis	13	(10.4)
Testicular torsion	3	(2.4)
Testicular trauma	6	(4.8)
Chemo/radiotherapy	8	(6.4)
Idiopathic	49	(39.2)
Total	125	(100.0)

3 Results

The average age of patients undergoing testicular sperm retrieval was 37.6 ± 3.3 (range 28–43) years. The clinical condition associated with non-obstructive azoospermia is shown in Table 1.

Table 2 summarizes the hormonal levels and testicular volume of patients studied, grouped according to testicular cytological analysis. FSH plasma levels in the SCOS group were higher than those in the severe hypospermatogenesis and maturation arrest groups; Serum inhibin B in the SCOS group was significantly lower than that in the hypospermatogenesis and maturation arrest groups; and testicular volume in the SCOS group was lower than that in the maturation arrest group. LH and testosterone were not statistically different among the three groups.

Table 3 summarizes the results of FNAC and TESE. Mature spermatozoa by FNAC were identified in 33 of 125 men (26.4 %): in 24 of 42 patients with severe hypospermatogenesis (57.1 %), nine of 14 subjects with maturation arrest (64.3 %) and none of the men with SCOS (by definition). The sperm recovery rate of TESE was 35 of 42 (83.3 %) patients with severe hypospermatogenesis (including all 24 patients showing testicular spermatozoa at FNAC), 10 of 13 (76.9 %) patients with maturation arrest (including all nine patients showing testicular spermatozoa at FNAC) and 29 of 70 (41.4 %) patients with SCOS. Overall, in 74 of 125 patients with non-obstructive azoospermia (59.2 %), testicular spermatozoa were successfully recovered by TESE. Comparison of sperm recovery with FNAC and TESE shows that: 1) in all cases when sperm were found at FNAC, TESE successfully retrieved sperm; and 2) in 41 of 92 cases (44.6 %) in which FNAC did not detect sperm, TESE retrieved sperm (Figure 1). The sensitivity and specificity of FNAC were 44.6 % and 100 %, respectively,

Table 2. Hormonal levels and testicular volume of the 125 patients, grouped on the basis of the testicular fine needle aspiration cytology diagnosis. Testicular volume is the mean of the two testes for each subject. ^b $P < 0.05$, ^c $P < 0.01$, compared with the corresponding SCOS group.

Cytological picture	<i>n</i>	FSH (IU/L)	LH (IU/L)	Testosterone (ng/mL)	Inhibin B (pg/mL)	Testicular volume (mL)
Sertoli cell-only syndrome	70	22.1 ± 6.3	5.0 ± 1.5	3.9 ± 1.1	46.0 ± 19.6	10.8 ± 1.7
Severe hypospermatogenesis	42	17.7 ± 3.9^c	4.7 ± 1.0	4.2 ± 0.8	69.5 ± 20.2^c	11.4 ± 1.6
Maturation arrest	13	17.9 ± 1.7^c	4.2 ± 0.9	4.3 ± 0.8	66.5 ± 14.1^c	11.9 ± 0.9^b

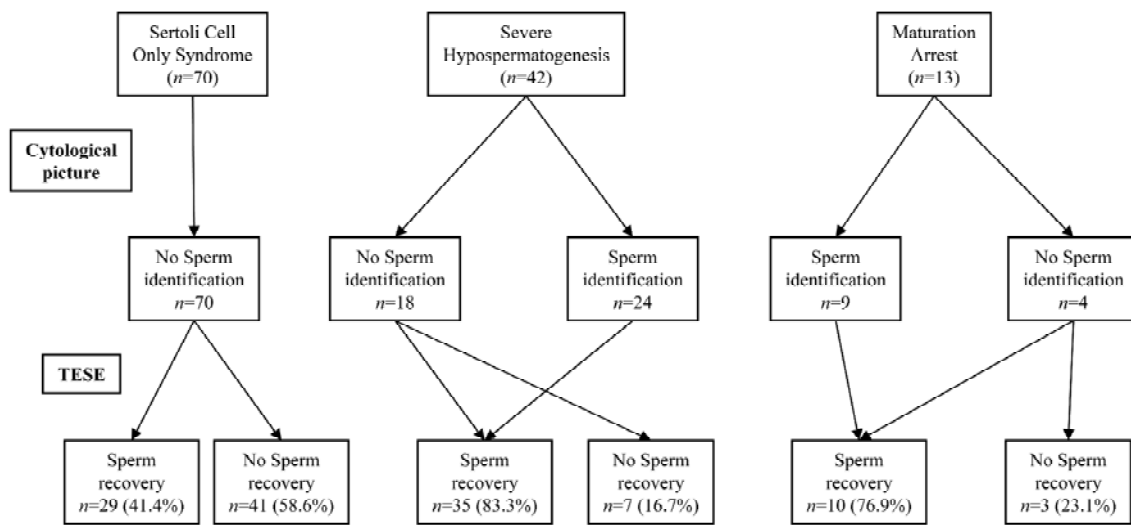


Figure 1. Schematic representation of fine needle aspiration cytology and testicular sperm extraction results.

Table 3. Comparison of fine needle aspiration cytology and testicular sperm extraction results with regard to sperm identification and recovery. FNAC, fine needle aspiration cytology; TSE, testicular sperm extraction.

Cytological picture	FNAC	TESE	FSH (IU/L)	LH (IU/L)	Testosterone (ng/mL)	Inhibin B (pg/mL)	Testicular volume (mL)
Sertoli cell-only syndrome (70)							
Sperm recovery	0	29	21.9 ± 6.8	4.8 ± 1.6	4.1 ± 1.1	44.2 ± 18.0	11.0 ± 2.0
No sperm recovery	70	41	22.3 ± 6.0	5.2 ± 1.4	3.7 ± 1.0	47.3 ± 21.9	10.6 ± 1.5
Severe hypospermatogenesis (42)							
Sperm recovery	24	35	17.8 ± 4.2	4.6 ± 1.0	4.3 ± 0.8	70.2 ± 21.4	11.4 ± 1.6
No sperm recovery	18	7	17.5 ± 2.4	4.9 ± 1.3	3.8 ± 0.4	66.0 ± 14.8	11.6 ± 1.8
Maturation arrest (13)							
Sperm recovery	9	10	18.4 ± 1.6	3.9 ± 0.8	4.2 ± 0.9	63.4 ± 14.5	12.0 ± 0.9
No sperm recovery	4	3	16.5 ± 1.3	4.5 ± 0.4	4.4 ± 0.2	76.7 ± 11.5	11.5 ± 0.9

with a positive predictive value of 100 %.

Table 3 documents the clinical and hormonal data of all subjects according to the testicular cytological picture as evidenced by FNAC of the testes and sperm retrieval at TESE. There were no statistically significant differences among the groups with successful and failed sperm retrieval at TESE.

4 Discussion

ICSI has revolutionized the clinical approach of azoospermic subjects who did not have the opportunity

to access any assisted reproduction techniques (ARTs) before 1992. In subjects suffering from obstructive azoospermia, the different microsurgical techniques are able to retrieve mature sperm from the different regions of the male reproductive tract [9]. In contrast, the retrieval of sperm may not always be successful in cases of non-obstructive azoospermia, as demonstrated by a number of retrospective studies reporting sperm recovery in a wide range of percentages [6–10].

During recent years many studies have tried to identify clinical and biochemical markers predictive for the presence of active spermatogenesis and mature sperm

within the testis in subjects suffering from non-obstructive azoospermia, but none of them was shown to be adequate [7–9, 16, 19]. For example, foci of active spermatogenesis can be present also in azoospermic men with a high FSH plasma level and with testicular atrophy; one study found mature sperm in 30 % of azoospermic patients with FSH concentrations of up to 30 mIU/mL [20]. Also, inhibin B cannot exactly predict the presence of testicular sperm [21]. Only testicular histology by open biopsy seems to be predictive for the successful retrieval of sperm during TESE [7, 19, 22], but it cannot be proposed as a diagnostic tool for all azoospermic men.

In the present study we evaluated the clinical and hormonal characteristics of a group of infertile subjects with non-obstructive azoospermia undergoing TESE, comparing results with testicular FNAC performed previously during the diagnostic work-up of these patients. Consistent with previous studies, we did not find any correlation between clinical and hormonal parameters and the success of TESE, confirming that these parameters had no prognostic value. The only positive prognostic parameter for successful sperm retrieval was the presence of mature sperm in the cytological analysis performed before TESE. In fact sperm were retrieved in all cases in which mature sperm were identified at FNAC. When mature sperm were not present at FNAC, TESE led to sperm retrieval in 41.4 % of cases previously diagnosed as SCOS, 61.1 % of severe hypospermatogenesis (11/18) and 25.0 % of maturation arrest (1/4). Therefore, absence of identification of sperm at FNAC had no prognostic value. FNAC has a sensitivity of 44.6 % and a specificity of 100.0 %, with a positive predictive value of 100.0 %. In other words, if sperm are present on FNAC, they will be present on TESE, but if sperm are not seen by FNAC, they will be present by TESE with possibility of approximate 50.0 %.

This study confirms what has been reported previously by other authors: the importance of understanding testicular structures with respect to other clinical parameters for successful TESE. Testicular histology by open biopsy has been reported to be the most reliable prognostic method. Here we show that testicular FNAC may also be useful. Testicular cytological analysis is relatively simple and can be performed routinely in severely infertile men. It allows the identification of all germinal cells in their different maturation steps as well as Sertoli cells. As with histological preparations, FNAC permits the characterization of specific cytological pictures that

are related to the nature of testicular damage, such as SCOS, hypospermatogenesis and maturation arrest. Therefore, cytological evaluation is able to identify different groups of azoospermic subjects and represents a reliable and prognostic parameter of the status of the seminiferous epithelium.

Testicular biopsy is an invasive procedure and transient adverse effects including devascularization of the testes which may occur after multiple biopsies [23]. Therefore, although in non-obstructive azoospermia, spermatogenesis may be focal and multiple biopsies are recommended, we have preferred two single biopsies to limit testicular damage. Failure to retrieve sperm from the testis in azoospermic subjects may cause the patient and his partner financial and psychological distress, especially when sperm recovery techniques are performed simultaneously with ovarian stimulation of the female partner. An accurate preoperative assessment is beneficial both to the couple and reproductive operators. Testicular FNAC may therefore represent an important diagnostic procedure in non-obstructive azoospermic men, and a reliable prognostic parameter for successful sperm retrieval at TESE. The high positive prognostic value of finding sperm at FNAC implies that TESE in such cases may be performed at the same time as ICSI, without the need of sperm cryopreservation.

References

- 1 Jarow JP, Espeland MA, Lipshultz LI. Evaluation of the azoospermic patient. *J Urol* 1989; 142: 62–5.
- 2 Foresta C, Varotto A, Scandellari C. Assessment of testicular cytology by fine needle aspiration as a diagnostic parameter in the evaluation of the azoospermic subject. *Fertil Steril* 1992; 57: 858–65.
- 3 Foresta C, Ferlin A, Bettella A, Rossato M, Varotto A. Diagnostic and clinical features in azoospermia. *Clin Endocrinol (Oxf)* 1995; 43: 537–43.
- 4 Foresta C, Bettella A, Petraglia F, Pistorello M, Luisi S, Rossato M. Inhibin B levels in azoospermic subjects with cytologically characterized testicular pathology. *Clin Endocrinol(Oxf)* 1999; 50: 695–701.
- 5 Palermo G, Joris H, Devroey P, Van Steirteghem AC. Pregnancies after intracytoplasmic injection of single spermatozoon into an oocyte. *Lancet* 1992; 340: 17–8.
- 6 Su LM, Palermo GD, Goldstein M, Veeck LL, Rosenwaks Z, Schlegel PN. Testicular sperm extraction with intracytoplasmic sperm injection for nonobstructive azoospermia: testicular histology can predict success of sperm retrieval. *J Urol* 1999; 161: 112–6.
- 7 Seo JT, Ko WJ. Predictive factors of successful testicular

- sperm recovery in non-obstructive azoospermia patients. *Int J Androl* 2001; 24: 306–10.
- 8 Amer M, Ateyah A, Zohdy W, Abd El Nasser T, Abdel-Malak G, Fakhry E. Preoperative and intraoperative factors that predict difficult testicular sperm retrieval in patients with nonobstructive azoospermia. *Fertil Steril* 2002; 78: 646–7.
 - 9 Fasouliotis SJ, Safran A, Porat-Katz A, Simon A, Laufer N, Lewin A. A high predictive value of the first testicular fine needle aspiration in patients with non-obstructive azoospermia for sperm recovery at the subsequent attempt. *Hum Reprod* 2002; 17: 139–42.
 - 10 Glander HJ, Horner LC, Dorschner W, Paasch U, Kratzsch J. Probability to retrieve testicular spermatozoa in azoospermic patients. *Asian J Androl* 2000; 2: 199–205.
 - 11 Schoysman R, Vanderzwalmen P, Nijs M, Segal-Bertin G, van de Casseye M. Successful fertilization by testicular spermatozoa in an *in-vitro* fertilization programme. *Hum Reprod* 1993; 8: 1339–40.
 - 12 Devroey P, Liu J, Nagy Z, Goossens A, Tournaye H, Camus M, *et al.* Pregnancies after testicular sperm extraction and intracytoplasmic sperm injection in non-obstructive azoospermia. *Hum Reprod* 1995; 10: 1457–60.
 - 13 Osmanagaoglu K, Vernaeve V, Kolibianakis E, Tournaye H, Camus M, Van Steirteghem A, *et al.* Cumulative delivery rates after ICSI treatment cycles with freshly retrieved testicular sperm: a 7-year follow-up study. *Hum Reprod* 2003; 18: 1836–40.
 - 14 Beierdorffer H, Schirren C. Peculiarities and side effects of testicular biopsy. *Andrologia* 1979; 11: 311–9.
 - 15 Harrington TG, Schauer D, Gilbert BR. Percutaneous testis biopsy: an alternative to open testicular biopsy in the evaluation of the subfertile man. *J Urol* 1996; 156: 1647–51.
 - 16 Ezeh UI, Moore HD, Cooke ID. Correlation of testicular sperm extraction with morphological, biophysical and endocrine profiles in men with azoospermia due to primary gonadal failure. *Hum Reprod* 1998; 13: 3066–74.
 - 17 Foresta C, Varotto A. Assessment of testicular cytology by fine needle aspiration as a diagnostic parameter in the evaluation of the oligospermic subject. *Fertil Steril* 1992; 58: 1028–33.
 - 18 Rossato M, Zorzi M, Ferlin A, Garolla A, Foresta C. Effects of cryopreservation on progesterone-induced ion fluxes and acrosome reaction in human spermatozoa. *Hum Reprod* 2000; 15: 1739–43.
 - 19 Tournaye H, Verheyen G, Nagy P, Ubaldi F, Goossens A, Silber S, *et al.* Are there any predictive factors for successful testicular sperm recovery in azoospermic patients? *Hum Reprod* 1997; 12: 80–6.
 - 20 Kim ED, Gilbaugh JH 3rd, Patel VR, Turek PJ, Lipshultz LI. Testis biopsies frequently demonstrate sperm in men with azoospermia and significantly elevated follicle-stimulating hormone levels. *J Urol* 1997; 157: 144–6.
 - 21 von Eckardstein S, Simoni M, Bergmann M, Weinbauer GF, Gassner P, Schepers AG. Serum inhibin B in combination with serum follicle-stimulating hormone FSH is a more sensitive marker than serum FSH alone for impaired spermatogenesis in men, but cannot predict the presence of sperm in testicular tissue samples. *J Clin Endocrinol Metab* 1999; 84: 2496–501.
 - 22 Schultze W, Thoms F, Knuth UA. Testicular sperm extraction: comprehensive analysis with simultaneously performed histology in 1418 biopsies from 766 subfertile men. *Hum Reprod* 1999; 14 Suppl 1: 82–96.
 - 23 Schlegel PN, Su LM. Physiological consequences of testicular sperm extraction. *Hum Reprod* 1997; 12: 1688–92.