

Original Paper

Acute Tubular Necrosis Following Interferon-Based Therapy for Hepatitis C: Case Study with Literature Review

Fabrizio Fabrizi^a Alessio Aghemo^b G. Battista Fogazzi^a Gabriella Moroni^a
Patrizia Passerini^a Roberta D'Ambrosio^b Piergiorgio Messa^a

^aDivision of Nephrology and ^bDivision of Digestive Diseases, Maggiore Policlinico Hospital, IRCCS Foundation, Milan, Italy

Key Words

Hepatitis C • Acute Tubular Necrosis • Interferon • Ribavirin • Nephrotoxicity

Abstract

Background/Aims: Interferon treatment of malignant or viral diseases can be accompanied by various side-effects including nephro-toxicity. **Methods:** We report on a 68-year-old Caucasian male who received dual therapy with pegylated interferon 2a plus ribavirin for chronic hepatitis C. **Results:** After three months of antiviral therapy, the patient developed acute kidney failure (serum creatinine up to 6 mg/dL) with mild proteinuria (500 mg daily) and haematuria. Immediate immunosuppressive therapy with high-dose intravenous steroids did not improve kidney function. Kidney biopsy was consistent with acute tubular necrosis without glomerular abnormalities. He started long-term peritoneal dialysis (four regular exchanges) to provide both dialysis adequacy and ascites removal. Kidney function gradually improved over the following months (serum creatinine around 2 mg/dL) and peritoneal dialysis was continued with two exchanges daily. The temporal relationship between the administration of the drug and the occurrence of nephro-toxicity, and the absence of other obvious reasons for acute tubular necrosis support a causative role for pegylated interferon; benefit on kidney disease was noted after withdrawal of antiviral agents. An extensive review of the literature on acute tubular necrosis associated with interferon-based therapy, based on in vitro data and earlier case-reports, has been made. The proposed pathogenic mechanisms are reviewed. **Conclusions:** Our case emphasizes the importance of monitoring renal function during treatment of chronic hepatitis C with antiviral combination therapy as treatment may precipitate kidney damage at tubular level.

Copyright © 2014 S. Karger AG, Basel

Introduction

Hepatitis C virus (HCV) is a blood-borne pathogen that appears to be endemic in many countries and is the main cause of chronic liver disease worldwide. The major long-term complications of chronic HCV infection are liver fibrosis, cirrhosis, and a high risk for hepatocellular carcinoma; the development of cirrhosis in published studies in the general population has ranged from 2% to 42% [1]. Antiviral treatment with pegylated interferon (peg-IFN) and ribavirin eradicates HCV infection in many patients (around 50%), depending on host and viral characteristics, especially the viral genotype [2]. However, interferon (IFN)-based therapy is complicated by frequent and, at times, serious adverse effects which represent an important barrier to treatment delivery. Information accumulated in the last decade suggests a rate of premature discontinuation of peg-IFN α and ribavirin treatment by patients with chronic HCV infection of around 9%-12% [3]. One of the reasons for the low SVR rates is the high frequency of adverse events related to peg-IFN α and ribavirin; therefore, the adherence to antiviral treatment would have a favorable effect on the sustained virological response (SVR) rate. In fact, patients who discontinued peg-IFN α and ribavirin treatment prematurely for whatever reason had an SVR rate of 12% compared with 65% of those who continued antiviral treatment despite dose reduction [4]. Combined antiviral therapy (conventional or peg-IFN plus ribavirin) impacts most, if not all, organ systems [4]. This darker side of IFN activity has been recognized by various investigators and was summarized in an editorial by Tang, who had asked the important question 'Interferon: friend or foe?' [5].

In addition to the widely recognized side-effects, nephro-toxicity is an uncommon but potentially severe side-effect of antiviral therapy [6]. Nephro-toxicity of combined antiviral treatment appears more related to IFN than ribavirin in view of the lack of reports on side-effects with ribavirin mono-therapy [7]. We report here the case of a patient who developed acute renal insufficiency due to acute tubular necrosis (ATN) during treatment with combined antiviral treatment (pegIFN α -2b plus RBV) for chronic hepatitis C. After discontinuation of antiviral agents, he showed partial recovery of renal function and remission of urinary abnormalities. A systematic review on the renal side effects of IFN-based therapy, based on laboratory investigations data and earlier case reports, was also performed.

Case Study

A 68-year-old Caucasian male was diagnosed with hepatitis C (genotype 1b) in 2009. His past medical history included tonsillectomy, coronary artery bypass graft surgery (1984), and percutaneous transluminal coronary angioplasty (PTCA) due to myocardial infarction (1999). He underwent liver biopsy (2009) which showed steatosis, chronic active hepatitis with nodular changes and mild activity; a quantitative PCR assay for hepatitis C virus RNA (HCV RNA) gave a viral load of 589,919 IU/mL. At that time kidney function was normal with serum creatinine of 0.95 mg/dL. In November 2009, he started combination antiviral therapy with peg-IFN α 2a (180 mcg/week) and ribavirin (1,200 mg daily).

Renal function was normal throughout the initial months of antiviral therapy, but acute kidney failure (serum creatinine of 1.97 mg/dL) occurred in February 2010 [Figure 1]. Antiviral therapy was immediately discontinued and the patient referred to our renal Division. On admission he was pale and apyrexial, peripheral edema and macroscopic haematuria were present. Blood pressure was normal. Serum biochemical tests were as follows: serum creatinine 5.19 mg/dL, urea 180 mg/dL, haemoglobin 8.8 g/dL; urine analysis showing proteinuria (500 mg daily) with granular and red cell casts [Table 1]. Serum cryocrit of 3% was found whereas other immunological tests (ANA, ANCA, ENA, and complement) tested negative. HCV RNA was 44 IU/mL. Liver biochemistries were as follows: GOT 32 IU/L, GPT 6 IU/L, γ -GT 40 I/L, cholinesterasis 3034 IU/L, total protein 5.8 gr/dL, and albumin 2.6 g/dL. Initially his urine output was low, and anuria occurred on the third hospital

Fig. 1. Temporal relationship between serum creatinine, HCV viraemia, and antiviral therapy.

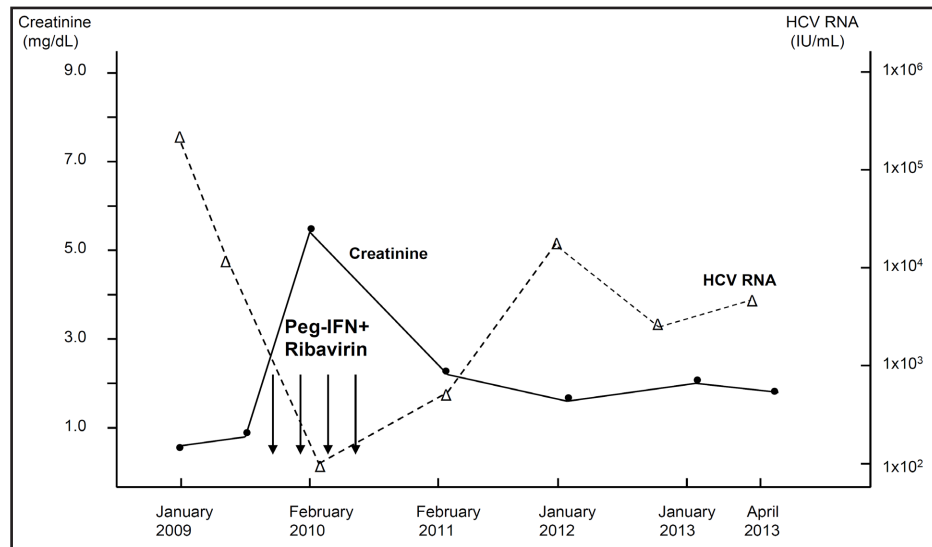


Table 1. Blood chemistries at presentation and over follow-up

	January, 2009	February, 2010	October, 2011	March, 2013
Creatinine (0.5-1.2, mg/dL)	1.07	5.19	1.89	2.04
Blood urea nitrogen (8-20, mg/dL)	35	180	98	112
AST (5-38, IU/L)	62	32	84	43
ALT (5-41, IU/L)	98	6	106	65
γGT (8-61, IU/L)	71	40	225	86
Cholinesterasis (5,300-12,900, IU/L)	9.392	8.503	13.113	8.204
Total bilirubin (0.1-1.1, mg/dL)	0.85	1.2	0.8	0.58
Uric acid, mg/dL	6.2	5.3	4.6	6.1
Total protein (6.6-8.7, g/dL)	7.6	7.3	5.9	6.3
Albumin (3.4-4.8, g/dL)	4.0	3.8	3.3	3.3
Total cholesterol (<200, mg/dL)	159	151	173	173
Triglycerides (<170, mg/dL)	117	75	111	111
IgA (70-400, mg/dL)	360	343	320	405
IgG (700-1600, mg/dL)	1.758	1.087	1.122	915
IgM (40-230, mg/dL)	185	119	119	192
C3 (90-180, mg/dL)	106	99	102	111
C4 (10-40, mg/dL)	22	21	32	24
Rheumatoid factor (<18, IU/mL)	7	9	12	12
PTH (15-65, pg/mL)	56.7	77.8	94	162
HCV RNA (IU/mL)	392.091	44	42.230	8.723

Abbreviations: AST, aspartate aminotransferase; ALT, alanine aminotransferase; γGT, glutamyl transpeptidase; HCV RNA, hepatitis C virus viraemia; PTH, parathormone

day. Acute nephritic syndrome was suspected and we immediately started intravenous corticosteroid therapy (methyl-prednisolone 500 mg and 300 mg on two consecutive days). Immunosuppressive therapy was complicated by diabetes mellitus and further deterioration of renal function was noted (serum creatinine up to 6.2 mg/dL, urea 264 mg/dL). We started intermittent haemodialysis; on the 6th hospital day, he underwent percutaneous renal biopsy showing acute tubular necrosis (five glomeruli included). The tubular damage was diffused and involved all nephron segments; damage to the proximal tubules was shown by the occurrence of coarse vacuolar degeneration, whereas the distal tubules and collecting ducts were dilated, attenuated, and partially obstructed by either hyaline or granular or red cell casts. The intracapsular space of two glomeruli was partially filled haemorrhagic substance. The interstitium surrounding the damaged tubules was edematous but without inflammatory infiltrate. Necrosis in many tubules occurred. Mild and aspecific glomerular abnormalities were present including thin glomerular walls, focal expansion of mesangial matrix, and mild segmental proliferation of mesangial cells. Immunofluorescence analysis was fully negative. The renal biopsy excluded uric acid crystals or myeloma casts causing

tubular obstruction; the chronology of exposure to nephro-toxins such as non-steroidal anti-inflammatory agents or radio-contrast was not appropriate to implicate these etiologies to renal failure. No drug rashes or eosinophilia was detected. Abdominal computed tomography (CT) scan demonstrated abundant peri-hepatic and peri-splenic ascites, kidneys with regular size and increased echogenicity and no evidence of a stone or an obstruction; blood flow was regular without vascular lesions in the kidney and liver. Tenckhoff peritoneal catheter was implanted in March (2010) and the patient started peritoneal dialysis with the aim to provide both dialysis adequacy and ascites removal (four regular exchanges throughout the day). He was discharged with serum creatinine of 4.03 mg/dL, and urea 107 mg/dL.

He continued peritoneal dialysis at home (continuous ambulatory peritoneal dialysis-CAPD) with normal blood pressure, and stable body weight. Urine output resumed on the following weeks and renal function gradually improved. At routine follow-up 96 days after the onset of acute renal failure, the patient's creatinine level was 2.1 mg per deciliter. CAPD was continued with two exchanges daily.

Two months later, he was again in charge at the Hospital for mental confusion with altered level of consciousness- diagnosis of hepatic encephalopathy was made, and medical therapy with oral lactulose was initiated. He did well until February 2013 when he was again hospitalized at our Hospital due to symptomatic pneumonia; intravenous antibiotics were given with benefit. Important anemia was also observed (ten units of red blood cells administered). Gastrointestinal (GI) endoscopy showed esophageal varices without signs of active blood loss, and hemorrhoids were found by colonoscopy. Chest x ray showed a right pleural effusion; thus, a connection between pleural and peritoneal cavities was suspected and dialysis was stopped. Fourteen days later peritoneal dialysis was started again with serum creatinine and urea of 1.9 mg/dL and 132 mg/dL, respectively; body weight increased of around 5 Kg with edema refractory to oral diuretics. He received intravenous iron and folic acid supplementation, and the dose of subcutaneous erythropoietin was increased. Biochemical liver tests were stable (Child-Pugh B7), HCV RNA 8,723 IU/mL. Normal blood pressure was again recorded. Therapy with insulin was interrupted and oral medications were started with good control of blood sugar levels. His medications currently include: omeprazole 20 mg daily, folic acid 5 mg daily, lactulose 10 g daily, calcitriol 0.5 mcg three times weekly, cardioaspirin 100 mg daily, furosemide 250 mg twice daily, potassium canreonate 100 mg daily, darbepoetin alpha 60 mcg sc weekly, bisoprolol 2.5 mg twice daily, iron sulphate 329 mg daily, and repaglinide 0.5 mg three times daily.

Review of the literature

In 1981, purified human leukocyte interferon (interferon- α) became available for clinical use [6]. IFNs are a family of natural cytokines provided with ability to interfere with viral replication, cell proliferation, and immuno-regulation. Three types of IFNs (α , β , and γ) exist, according to the major IFN peaks observed under high performance liquid chromatography (HPLC). The major cells of origin for α , β , and γ IFNs are leukocytes (other than lymphocytes), fibroblasts, and T cells and natural killer cells, respectively. Many other cell types are also capable of producing lower levels of IFN- α , and - β when virally infected. Type I IFNs include IFN α , β , and ω species. IFN γ activates different intracellular signaling events by the use of a distinct set of receptors, namely type II IFN receptors. Recombinant DNA technology has allowed cloning and mass production of IFNs for therapeutic use: IFN α which include IFN α -2a and IFN α -2b is currently approved for the treatment of multiple medical conditions such as hepatitis B and C, and some types of malignant diseases (malignant melanoma, chronic myeloid leukaemia, hairy cell leukaemia, mycosis fungoides, and non-Hodgkin follicular lymphoma) [8]. IFN- β is recommended for relapsing multiple sclerosis (MS) [9]. IFN- γ is indicated for the treatment of severe malignant osteopetrosis [10].

Although IFNs have been shown to be of benefit in many clinical situations, many retrograde aspects to IFNs therapy have been emphasized- acute toxicity (influenza-like

symptoms and fever), subacute and chronic toxicity (fatigue, anorexia, and general wasting) have been attributed to IFN-based therapy. Complications associated with the administration of IFNs can affect nervous (depression, lethargy, somnolence, mental slowing), hematopoietic (leukopenia, anemia, and thrombocytopenia), cardiovascular (myocardial infarction, arrhythmias, hypotension), musculoskeletal (myalgias, arthralgias), and endocrine system (thyroid dysfunction). Gastrointestinal toxicity consists mostly of anorexia, vomiting, diarrhea, and nausea.

Renal function is usually well preserved during IFN use and IFN-induced renal toxicity is considered quite unusual, although some evidence in the scientific literature exists. An important adverse effect of IFN on kidney is graft rejection after kidney transplantation—at least 12 published studies, although uncontrolled retrospective or observational studies, have shown kidney graft dysfunction during IFN-based therapy for chronic hepatitis B or C [11]. Reported rates of kidney graft dysfunction range from 9% to 100%, with most episodes occurring between 1 and 8 months after initiation of the therapy. In most cases, IFN-induced acute kidney injury appears to be predominantly related to its immuno-modulatory properties, leading to increased rates of both cell- and antibody-mediated rejection; acute rejection induced by IFN being frequently insensitive to corticosteroids and irreversible. On the other hand, the development of HCV-related fibrosing cholestatic hepatitis (FCH) may be an indication for IFN use after kidney transplantation as FCH has an ominous course. In these subjects, IFN-based therapy may be potentially lifesaving and should be given despite the risk of kidney graft rejection and graft loss. For HCV-infected kidney transplant recipients in whom the benefits of antiviral treatment clearly outweigh the risks, mono-therapy with standard IFN has been recommended, according to the Kidney Disease Improving Global Outcomes (KDIGO) guidelines. In any circumstance, this course of therapy should be undertaken only after the patient has been properly informed of the risks of both treatment and electing not to treat [11].

The most common adverse effect on the kidney during treatment of immuno-competent individuals with IFN is proteinuria. Early reports from phase II and III clinical trials on the use of IFN- α have documented the occurrence of proteinuria (15% to 25%) and abnormal urinalysis (14%) [6]. In many instances, these abnormalities were mild and reversible after stopping IFN. A variety of glomerular, interstitial, and tubular abnormalities sometimes seen in the same biopsy specimen, have been ascribed to IFN-associated nephro-toxicity. Some of these lesions have occurred after short-term (<16 weeks) administration of IFNs, and others with more chronic use (8 months to 6 years). In many reports, discontinuation of IFNs led to improvement of kidney disease.

Discussion

This report describes a case of acute renal failure by acute tubular necrosis during antiviral therapy (peg-IFN α plus ribavirin) for chronic hepatitis C. The chronology of progressive rise in serum creatinine a few weeks after the initiation of antiviral therapy supports a possible relationship between cytokine therapy and deterioration of renal function. The improvement of renal function after discontinuation of peg-IFN α and the absence of other evident causes of ATN strongly suggest a link between ATN and antiviral therapy with peg-IFN α . In fact, there was no increase in plasma uric acid concentration suggestive of a tumour lysis syndrome, no underlying infection or hypotension, no use of radio-contrast or other medications, e.g. antibiotics or non-steroidal anti-inflammatory drugs, to account for the tubular necrosis.

IFN- α therapy has been implicated in various renal diseases such as renal thrombotic microangiopathy (in patients with chronic leukemia) [12], interstitial nephritis [13], and glomerular diseases including podocytopathies (focal segmental glomerulosclerosis and minimal change disease) or immune complex glomerulonephritis (membranous nephropathy, membrano-proliferative glomerulonephritis, IgA nephropathy), as shown in

Table 2. Acute renal failure (due to ATN) associated with IFN therapy

	Ault B., <i>et al.</i>	Fahal H., <i>et al.</i>	Miranda- Guardiola F., <i>et al.</i>	Dimitrov Y., <i>et al.</i>	Al Harbi A., <i>et al.</i>	Gordon A., <i>et al.</i>
Publication year	1988	1993	1995	1997	1998	2004
Reference number	34	35	36	37	38	39
Country	US	UK	Spain	France	Saudi Arabia	Australia
IFN type	Recombinant IFN- γ	Recombinant IFN- α 2b	IFN- α	IFN- α	IFN- α	Peg-IFN- α 2a
IFN dose	1x10 ⁷ U/ square meter	3 MUIx3/ week	5 MUIx3/ week	3 MUI/ day	3 MUIx3/ week	180 mcg/ week
IFN duration	19 days	10 mo	5 days	42 days	10 days	10 days
IFN route	sc	sc	Sc	sc	sc	sc
Gender	Male	Female	NA	Male	Male	Male
Age, yrs	9	49	26	42	38	54
Race	NA	NA	Caucasian	Black	Black	NA
Renal presentation	ARF	ARF	ARF	ARF, NS	ARF, NS	ARF
Creatinine (mg/dL)	14.3	11.5	21.7	5.5	13.4	2.7
Original disease	Lymphoblastic leukemia	Multiple myeloma	Hepatitis B	Lymphoma	HBV-related GN	Hepatitis C
Outcome after IFN withdrawal	Complete recovery	Complete recovery	Complete recovery	Complete recovery	Complete recovery	Complete recovery
Duration of follow- up	33 days	NA	25 days	80 days	92 days	80 days
Kidney biopsy	ATN, FSGS	ATN	ATN	ATN	NA	ATN,IgA nephropathy

Abbreviations: ATN, acute tubular necrosis; ARF, acute renal failure; FSGS, focal segmental glomerulosclerosis; IFN, interferon; GN, glomerulonephritis; NA, not available; NS, nephrotic syndrome; sc, subcutaneously

several case reports published over the last 20 years [14-30]. In addition, case series have been published [31]. Additional papers provided evidence of exacerbation of pre-existing glomerular disease during IFN [32-33]. The usual presentation of glomerular disease associated with IFN is isolated proteinuria, and nephrotic syndrome [14-31]. In a minority of patients, nephritic syndrome with renal failure has been recorded. Conversely, renal toxicity with acute renal failure due to ATN appears less frequent and it had been previously reported in a few patients [34-39]. As listed in Table 2, these reports concerned mostly the treatment of haematological or solid neoplastic disorders, with dosages of interferon frequently higher than in the current case. Three other case reports on IFN-associated renal failure described focal ATN in kidney biopsy in association with glomerular abnormalities [14, 30, 40].

How IFN therapy causes renal injury at tubular level is unknown, even if this is an area of intense research. An *in vitro* cell culture model system has been established to investigate the effects of IFN α on renal epithelial cells. It has been found a reversible, dose- and time-dependent decrease of trans-epithelial resistance (TER) of renal proximal tubular monolayer cells (LLC-PKi porcine proximal tubular cells). IFN can directly affect the epithelial barrier function of renal proximal tubular cells, increasing the leakiness of the epithelial layer after IFN α treatment. 'Backleak' of glomerular filtrate into the renal interstitium might thus be induced, generating edema with inflammatory changes; these *in vitro* observations could explain the severe and in part life threatening adverse effects of IFN α , such as renal dysfunction or the capillary leak syndrome [41-42]. A novel and independent action of IFN α on renal tubular epithelium is the induction of apoptosis in renal tubular epithelial cells; IFN α supports the activation of caspase-3, -8 and -9, DNA fragmentation, and nuclear condensation. IFN α also caused mitochondrial depolarization. In other words, IFN α induced apoptosis is directed by an extrinsic death receptor signaling pathway, amplified by an intrinsic mitochondrial pathway. The apoptotic signaling pathways activated in proximal tubular cells resemble the pathways induced by IFN α in melanoma and bladder carcinoma cells [43].

Recently, Satou *et al* [44] have observed in animal models (rodents) that interferon γ (IFN γ) induces activation of the intrarenal renin-angiotensin system (RAS) by modulating

the STAT1-SOCS1 axis. In the kidney, intra-renal angiotensin II (Ang II) is derived from intra-renal angiotensinogen (AGT) which is produced mainly in renal proximal tubular cells (RPCTs). IFN γ augments AGT expression in RPCTs which may lead to increases in intra-renal RAS activity. The local RAS functions are expressed in individual organs in a tissue-specific manner; intra-renal AGT is increased in several forms of clinical and experimental hypertension and exacerbation of renal inflammation. These *in vitro* data can contribute to explain the tubular injury associated with IFN administration in humans.

An alternative explanation implicates an apoptotic activity of ribavirin, that has been recently established in *in vitro* settings [45]. Ribavirin proved to be a strong inducer of apoptosis using various human cancer cell lines, and these findings are in keeping with the rationale of the initiation of the ribavirin treatment trial that is in progress on acute myeloid leukemia (AML) patients. It remains to assess whether the apoptotic activity of ribavirin (or its metabolites) is evident in the renal tubular cells and plays a role in the exacerbation of tubular necrosis instigated by IFN.

Conclusion

This case report gives emphasis to the renal toxicity of IFN-based therapy at tubular level. Because our patient had no other obvious reason for ATN, we postulate that it may be secondary to peg-IFN plus ribavirin therapy. Further studies are in progress to understand better pathogenesis, outcome and management of IFN-associated NTA. Physicians treating chronic hepatitis C patients with IFNs should be advised to be vigilant and be aware of these potential renal complications.

Conflict of Interests

None of the authors have any conflict of interest to report.

Acknowledgements

This work was supported in part by the grant 'Project Glomerulonephritis'; in memory of Pippo Neglia.

References

- 1 Alter H, Seeff L: Recovery, persistence, and sequelae in hepatitis C virus infection: a perspective on long-term outcome. *Semin Liver Dis* 2000;20:17-35.
- 2 Pol S, Vallet-Pichard A, Corouge M, Mallet V: Hepatitis C: Epidemiology, diagnosis, natural history, and therapy. *Contrib Nephrol* 2012;176:1-9.
- 3 Ogawa E, Furusyo N, Kajiwara E, Takahashi K, Nomura H, Tanabe Y, Satoh T, Maruyama T, Nakamura M, Kotoh K, Azuma K, Dohmen K, Shimoda S, Hayashi J; Kyushu University Liver Disease Study [KULDS] Group: Evaluation of the adverse effect of premature discontinuation of pegylated interferon α -2b and ribavirin treatment for chronic hepatitis C virus infection: results from the Kyushu University Liver Disease Study [KULDS] Group. *J Gastroenterol Hepatol* 2012;27:1233-1240.
- 4 Russo M, Fried M: Side effects of therapy for chronic hepatitis C. *Gastroenterology* 2003;36:S237-S244.
- 5 Tang R: Interferon: friend or foe? *Arch Ophthalmol* 1995;113:987.
- 6 Quesada J, Talpaz M, Rios A, Kurzrock R, Gutterman J: Clinical toxicity of interferons in cancer patients: A review. *J Clin Oncol* 1986;4:234-243.

- 7 Schalm S, Hanson B, Chemello E, Bellobuono A, Brouwer J, Weiland O, Cavalletto L, Schwarcz R, Ideo G, Alberti A: Ribavirin enhances the efficacy but not the adverse effects of interferon in chronic hepatitis C: meta-analysis of individual patient data from European centers. *J Hepatol* 1997;26:961-966.
- 8 Bekisz J, Sato Y, Johnson C, Husain S, Puri R, Zoon K: Immunomodulatory effects of interferons in malignancies. *J Interferon Cytokine Res* 2013;33:154-161.
- 9 Wallbach M, Grone H, Kitz B, Muller G, Koziol M: Nephrotic syndrome in a multiple sclerosis patient receiving long-term interferon beta therapy. *Am J Kidney Dis* 2013;61:786-789.
- 10 Kocher M, Kasser J: Osteopetrosis. *Am J Orthop* 2003;32:222-228.
- 11 Kidney Disease: Improving Global Outcomes. KDIGO clinical practice guidelines for the prevention, diagnosis, evaluation, and treatment of Hepatitis C in chronic kidney disease. *Kidney Int* 2008;73:S1-S99.
- 12 Jadoul M, Piessevaux H, Ferrant A, Cosyns J, van Ypersele de Strihou C: Renal thrombotic microangiopathy in patients with chronic myelogenous leukaemia treated with interferon-alpha 2b. *Nephrol Dial Transplant* 1995;10:111-113.
- 13 Averbuch S, Austin H, Sherwin S, Antonovych T, Bunn P, Longo D: Acute interstitial nephritis with the nephrotic syndrome following recombinant leukocyte A interferon therapy for mycosis fungoides. *N Engl J Med* 1984;311:32-35.
- 14 Traynor A, Kuzel T, Samuelson E, Kanwar Y: Minimal change glomerulopathy and glomerular visceral epithelial hyperplasia associated with alpha-interferon therapy for cutaneous T-cell lymphoma. *Nephron* 1994;67:94-100.
- 15 Rettmar K, Kienast J, van de Loo J: Minimal change glomerulonephritis with reversible proteinuria during interferon α 2a therapy for chronic myeloid leukemia. *Am J Hematol* 1995;49:335-366.
- 16 Shah M, Jenis E, Mookerjee B, Schriber J, Baer M, Herzog G, Wetzler M: Interferon- α associated focal segmental glomerulosclerosis with massive proteinuria in patients with chronic myeloid leukemia following high dose chemotherapy. *Cancer* 1998;83:1938-1946.
- 17 Nakao K, Sugiyama H, Makino E, Matsuura H, Ohmoto A, Sugimoto T, Ichikawa H, Wada J, Yamasaki Y, Makino H: Minimal change nephrotic syndrome developing during postoperative interferon -beta therapy for malignant melanoma. *Nephron* 2002;90:498-500.
- 18 Bremer C, Lastrapes A, Alper A, Mudar R: Interferon-alpha induced focal segmental glomerulosclerosis in chronic myelogenous leukemia. *Am J Clin Oncol* 2003;26:262-264.
- 19 Kumasaka R, Nakamura N, Shirato K, Fujita T, Murakami R, Shimada M, Nakamura M, Osawa H, Yamabe H, Okumura K: Nephrotic syndrome associated with interferon-beta 1b therapy for multiple sclerosis. *Clin Exp Nephrol* 2006;10:222-225.
- 20 Coroneos E, Petrussevska G, Varghese F, Truong L: Focal segmental glomerulosclerosis with acute renal failure associated with α -interferon therapy. *Am J Kidney Dis* 1996;28:888-892.
- 21 Horino T, Kuriyama S, Tomonari H, Numata M, Hayashi F, Nagata H, Hikita M, Utsunomiya Y, Kawamura T, Hosoya T: Renal damage in a chronic active hepatitis C patient receiving interferon-alpha therapy. *Nihon Jinzo Gakkai Shi* 1998;40:48-53.
- 22 Endo M, Ohi H, Fujita T, Ohsawa I, Kanmatsuse K, Yamaguchi Y: Appearance of nephrotic syndrome following interferon- α therapy in a patient with hepatitis B virus and hepatitis C virus coinfection. *Am J Nephrol* 1998;18:439-443.
- 23 Stein D, Ahmed A, Sunkhara V, Khalbuss W: Collapsing focal segmental glomerulosclerosis with recovery of renal function: An uncommon complication of interferon therapy for hepatitis C. *Dig Dis Sci* 2001;46:530-535.
- 24 Nishimura S, Miura H, Yamada H, Shinoda T, Kitamura S, Miura Y: Acute onset of nephrotic syndrome during interferon- α treatment for chronic active hepatitis C. *J Gastroenterol* 2002;37:854-858.
- 25 Willson R: Nephrotoxicity of interferon alpha-ribavirin therapy for chronic hepatitis C. *J Clin Gastroenterol* 2002;35:89-92.
- 26 Dizer U, Beker C, Yavuz I, Ortatatl M, Ozguven V, Pahsa A: Minimal change disease in a patient receiving IFN- α therapy for chronic hepatitis C virus infection. *J Interferon Cytokine Res* 2003;23:51-54.
- 27 Suresh R, Suryati Y, Merican I: Interferon induced glomerular disease in a patient with chronic hepatitis C. *Med J Malaysia* 2003;58:594-596.
- 28 Couto A, Faria L, Ribeiro D, de Paula F, de Melo Couto O, de Abreu Ferrari T: Life-threatening thrombocytopenia and nephrotic syndrome due to focal segmental glomerulosclerosis associated with pegylated interferon alpha-2b and ribavirin treatment for hepatitis C. *Liver Int* 2006;26:1294-1297.

- 29 Tovar J, Buti M, Segarra A, Majò J, Esteban R: De novo nephrotic syndrome following pegylated interferon alfa 2b/ribavirin therapy for chronic hepatitis C infection. *Int Urol Nephrol* 2008;40:539-541.
- 30 Kanungo S, Tamirisa S, Gopalakrishnan R, Salinas-Madriral L, Bastani B: Collapsing glomerulopathy as a complication of interferon therapy for hepatitis C infection. *Int Urol Nephrol* 2010;42:219-222.
- 31 Markowitz G, Nasr S, Stokes M, D'Agati V: Treatment with IFN- α , - β or - γ is associated with collapsing focal segmental glomerulosclerosis. *Clin J Am Soc Nephrol* 2010;5:607-615.
- 32 Ohta S, Yokoyama H, Wada T, Sakai N, Shimizu M, Kato T, Furuichi K, Segawa C, Hisada Y: Exacerbation of glomerulonephritis in subjects with chronic hepatitis C virus infection after interferon therapy. *Am J Kidney Dis* 1999;33:1040-1048.
- 33 Roithinger F, Allinger S, Kirchgatterer A, Prischl F, Balon R, Haidenthaler A, Knoflach P: A lethal course of chronic hepatitis C, glomerulonephritis, and pulmonary vasculitis unresponsive to interferon treatment. *Am J Gastroenterol* 1995;90:1006-1008.
- 34 Ault B, Stapleton F, Gaber L, Martin A, Roy S, Murphy S: Acute renal failure during therapy with recombinant human gamma interferon. *N Engl J Med* 1988;319:1397-1400.
- 35 Fahal I, Murry N, Chu P, Bell G: Acute renal failure during interferon treatment. *Br Med J* 1993;306:973.
- 36 Miranda-Guardiola F, Fdez-Llama P, Badia J, Botey A, Estruch R, Darnell A, Rozman C, Revert L: Acute renal failure associated with alpha-interferon therapy for chronic hepatitis B. *Nephrol Dial Transplant* 1995;10:1441-1443.
- 37 Dimitrov Y, Heibel F, Marcellin L, Chantrel F, Moulin B, Hannedouche T: Acute renal failure and nephrotic syndrome with alpha interferon therapy. *Nephrol Dial Transplant* 1997;12:200-203.
- 38 Al Harbi A, Al Ghamdi S, Subaity Y, Khalili A: Interferon-induced acute renal failure in nephrotic syndrome. *Nephrol Dial Transplant* 1998;13:1316-1318.
- 39 Gordon A, Menahem S, Mitchell J, Jenkins P, Dowling J, Roberts S: Combination pegylated interferon and ribavirin therapy precipitating acute renal failure and exacerbating IgA nephropathy. *Nephrol Dial Transplant* 2004;19:2155.
- 40 Nassar G, Pedro P, Remmers R, Mohanty L, Smith W: Reversible renal failure in a patient with hypereosinophilia syndrome during therapy with alpha-interferon. *Am J Kidney Dis* 1998;31:121-126.
- 41 Lechner J, Krall M, Netzer A, Radmayr C, Ryan M, Pfaller W: Effects of interferon α -2b on barrier function and junctional complexes of renal proximal tubular LLC-PK₁ cells. *Kidney Int* 1999;55:2178-2191.
- 42 Lechner J, Pfaller W: Interferon α 2b increases paracellular permeability of renal proximal tubular LLC-PK₁ cells via a mitogen activated protein kinase signaling pathway. *Renal Fail* 2001;23:573-588.
- 43 Lechner J, Malloth N, Seppi T, Beer B, Jennings P, Pfaller W: IFN- α induces barrier destabilization and apoptosis in renal proximal tubular epithelium. *Am J Physiol Cell Physiol* 2008;294:C153-C160.
- 44 Satou R, Miyata K, Gonzalez-Villalobos R, Ingelfinger J, Navar L, Kobori H: Interferon- γ biphasically regulates angiotensinogen expression via a JAK-STAT pathway and suppressor of cytokine signaling 1 (SOCS1) in renal proximal tubular cells. *FASEB J* 2012;26:1821-1830.
- 45 Kokeny S, Papp J, Weber G, Vaszko T, Carmona-Saez P, Olah E: Ribavirin acts via multiple pathways in inhibition of leukemic cells proliferation. *Anticancer Res* 2009;29:1971-1980.