

The Endolog system for moderate-to-severe hallux valgus

Luigi Di Giorgio, Georgios Touloupakis, Simonetta Simone, Luca Imparato, Luca Sodano, Ciro Villani
Dipartimento di Scienze dell' Apparato Locomotore, Policlinico Umberto I, Università "Sapienza", Roma, Italy

ABSTRACT

Purpose. To report the midterm outcome of the Endolog system for correction of moderate-to-severe hallux valgus.

Methods. 23 women and 2 men (33 feet) aged 35 to 80 (mean, 52) years underwent minimally invasive surgery for moderate (n=25) and severe (n=8) hallux valgus using the Endolog system. The hallux valgus angle (HVA), the intermetatarsal angle (IMA), and the proximal articular set angle (PASA) were measured on radiographs. The feet were also assessed based on the American Orthopaedic Foot and Ankle Society (AOFAS) scale.

Results. The mean follow-up duration was 18.2 (range, 12–36) months. The mean HVA, IMA, PASA, and the mean AOFAS score improved significantly after surgery (all $p < 0.0001$). Periosteal reaction was noted by week 4, and callus formation after 3 months. There were no delayed or non-union or other complications.

Conclusion. The Endolog system achieved good outcome for moderate-to-severe hallux valgus.

Key words: hallux valgus; osteotomy; surgical procedures, minimally invasive

INTRODUCTION

Hallux valgus is more prevalent in women and the elderly,¹ and is often associated with functional deterioration and foot pain. The pressure and pain at the head of the other metatarsals increases when patients shift their weight laterally.² Orthoses and night splints do not appear to improve outcome, but surgery is reported to be beneficial.³ Whether minimally invasive or percutaneous surgery is the preferred technique for correction of moderate-to-severe hallux valgus remains controversial.⁴ We reports the midterm outcome of the Endolog system for correction of moderate-to-severe hallux valgus.

MATERIALS AND METHODS

From June 2008 to September 2010, 23 women and 2 men (33 feet) aged 35 to 80 (mean, 52) years underwent minimally invasive surgery for moderate (n=25) and

severe ($n=8$) hallux valgus using the Endolog system. Indications for surgery included foot pain, problems wearing shoes, and cosmetic concerns. Dorsoplantar radiographs of the foot in a weight-bearing position were taken. The hallux valgus angle (HVA), which is the angle between the axes of the first metatarsal and proximal phalanx, the intermetatarsal angle (IMA), which is the angle between the axes of the first and second metatarsals, and the proximal articular set angle (PASA) were measured on radiographs using the Graphisoft ArchiCAD 14 software. Hallux valgus was classified as: mild (HVA, $\leq 19^\circ$; IMA, $\leq 13^\circ$), moderate (HVA, 20° – 40° ; IMA, 14° – 20°), and severe (HVA, $>40^\circ$; IMA, $>20^\circ$).⁵ The feet were also assessed based on the American Orthopaedic Foot and Ankle Society (AOFAS) hallux-metatarsophalangeal-interphalangeal scale.

The Endolog system is composed of a curved nail with a proximal plate-like component with one hole for an angular stability screw. An

approximately 3-cm dorsal medial incision over the first metatarsophalangeal joint, and a linear capsular incision were made. The bunion was then shaved (exostectomy). A linear or oblique osteotomy was then made behind the head of the first metatarsus (Fig. 1). An oblique osteotomy enabled decompression of the articulation, especially in arthrosis. The mild shortening of the first metatarsal was compensated by the plantarisation of the metatarsal head and release of articular space and of soft tissues (Fig. 2). After insertion of a trial device under fluoroscopic imaging guidance, an appropriate-size Endolog system was press-fitted into the intramedullary bone of the first metatarsal (Fig. 1). The angular stability screw was inserted in the metatarsal head through the hole in the plate. If the abductor muscle persisted to contract, its attachment to the base of the proximal phalanx was percutaneously divided; a lateral capsulotomy could also be used in combination. A good translation could be obtained with a mildly oblique osteotomy of about 10° with respect to the perpendicular line to the metatarsal axis.

The incision was closed using 3-0 non-absorbable suture after a medial capsulorrhaphy. The sutures were removed after 14 days. A functional bandage and Barouk heel bearing shoes were used for 3 weeks. Thereafter, full weight bearing with slightly larger shoes was allowed. Patients were followed up at weeks 1, 2, 3, 4, and months 3, 6, and 12, and every year thereafter.

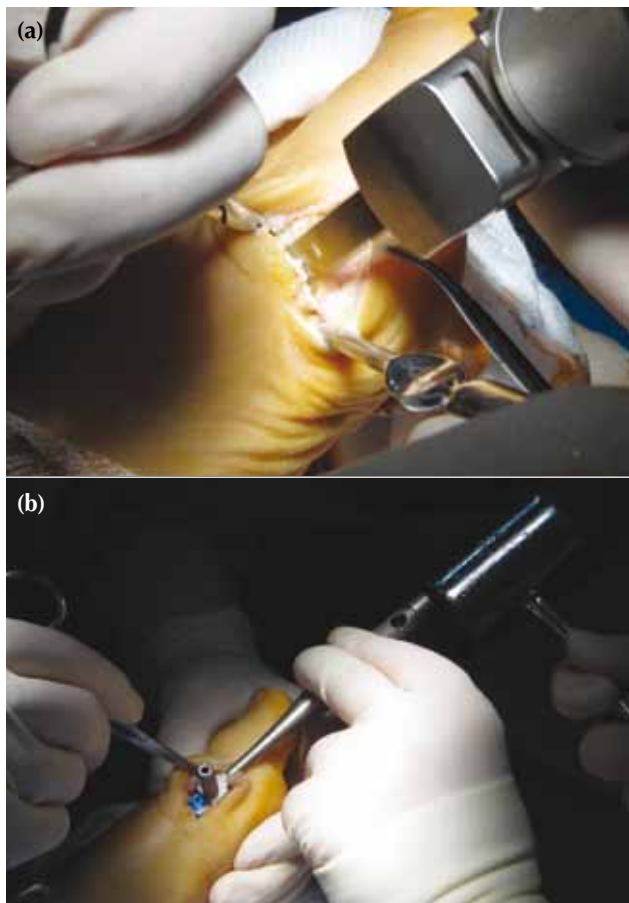


Figure 1 (a) A linear or oblique osteotomy of the first metatarsal head to shorten or lengthen the first ray, and (b) intramedullary insertion of the Endolog system into the proximal first metatarsal.

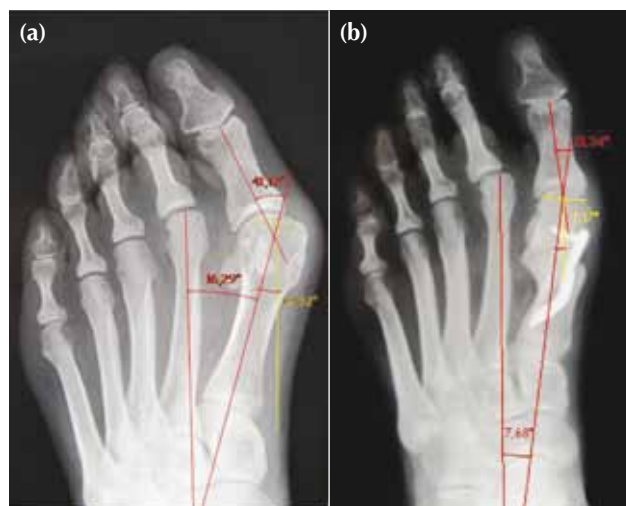

Figure 2 In a patient with moderate hallux valgus: (a) the first metatarsal is shorter than the second metatarsal before surgery. (b) After distal oblique metatarsal osteotomy and fixation by the Endolog system, the first metatarsal is shortened. A linear osteotomy and a percutaneous lateral soft tissue release should be more appropriate.

The two-sample *t*-test with equal variances was used to compare preoperative and follow-up AOFAS scores, IMA, HVA, and PASA. A *p* value of <0.05 was considered statistically significant.

RESULTS

The mean follow-up duration was 18.2 (range, 12–36) months. 24 of the patients were evaluated at year 2. The mean HVA, IMA, PASA, and the mean AOFAS score improved significantly after surgery (all *p*<0.0001, Table).

Periosteal reaction was noted by week 4, and callus formation after 3 months. There were no delayed or non-union and other complications such as dislocation, avascular necrosis of the first metatarsal, deep vein thrombosis, intra-operative fractures, and vascular and nerves lesions.

DISCUSSION

Surgical procedures for moderate-to-severe hallux valgus include distal soft-tissue release, osteotomies through the base or head of the first metatarsal, arthrodesis of the metatarsocuneiform joint or metatarsophalangeal joint, excisional arthroplasty, and combined osteotomy and distal soft-tissue release.^{6–9} These procedures enable deformity correction, pain relief, and return to daily living.¹⁰

The Austin metatarsal osteotomy combined with transection of adductor muscle through a single medial incision enables correction of mild-to-moderate hallux valgus but not severe deformity.¹¹ Other distal metatarsal osteotomies (Austin's chevron, Reverdin's variant, or Mitchell) also confer limited benefits in severe cases. The Austin metatarsal osteotomy is contraindicated in the presence of a large IMA,^{12–14} although it achieves excellent results in correction

of mild HVA (12°–13°) and IMA (4°–5°).¹⁵ In patients with severe deformity, it seems to produce more complications. In 50 patients (72 feet), 74% achieved good results when the IMA was >12°, whereas up to 94% did so when the IMA was <12°.¹⁶ Recurrences and undercorrection of the deformity were common.

The chevron technique was also effective in mild-to-moderate deformity, but was insufficient in severe deformity. Percutaneous distal osteotomies (Boesch and SERI) enable correction of IMA of up to 20°, but are associated with low stability and the risk of correction loss owing to traction from the extensor and long flexor of the hallux during bone consolidation.^{17,18} Proximal osteotomies enable correction of a large IMA but an accessory distal osteotomy is often needed to correct the PASA.^{19–21} In addition, fixation with Kirschner wires or staples is less stable than fixation with screws or plates.²² Recurrence of hallux valgus is common,²³ although stable implant can reduce such a risk.

In the current study, a distal oblique osteotomy of the first metatarsal was performed to decompress the articular space (first metatarsal head and the base of proximal phalanx) and to release the periarticular soft tissue (rather than correcting the PASA). Correction of the PASA is due to triplanar movement of the metatarsal head after osteotomy and fixation in the desired position with the Endolog system.

In severe hallux valgus, orientation of the first metatarsophalangeal joint axis (different from the first metatarsal axis) is altered.²⁴ Hallux valgus is associated with the first metatarsal arch segment. The collapse of the arch under weight bearing orients the first metatarsal axis toward vertical and predisposes to adduction of the first metatarsal, which initiates the deformity.²⁵ The Endolog system enables a multiplanar correction in a prone, supine, or a neutral position of the metatarsal head after osteotomy. Dynamic stabilisation of the first metatarsal head (owing to the angular stability screw) and the implant

Table
Improvement of the hallux valgus angle (HVA) intermetatarsal angle (IMA), proximal articular set angle (PASA), and the American Orthopaedic Foot and Ankle Society (AOFAS) score

Parameter	Mean±SD (range)			
	Preoperative	Month 6	Month 12	Month 24
HVA	36.6±8.1° (20°–53°)	17.5±6.2° (6°–26°)	21.6±5.7° (8°–30°)	22.7±6.7° (8°–32°)
IMA	16.0±1.9° (14°–19.9°)	6.1±2.8° (3°–9°)	6.1±2.8° (3°–10°)	6.1±2.9° (3°–11°)
PASA	13.4±3.7° (4°–22°)	6.3±4.3° (0°–7°)	6.7±4.5° (0°–8°)	6.9±4.9° (1°–10°)
AOFAS				
Total	22.1±11.1 (0–34)	91.8±8.3 (87–100)	91.1±4.0 (85–100)	88.2±6.1 (85–100)
Pain	3.0±7.2 (0–20)	37.3±4.0 (30–40)	38.3±3.6 (30–40)	36.8±4.6 (30–40)
Function	19.1±8.3 (0–27)	40.2±3.3 (37–45)	40.6±3.5 (37–45)	40.9±3.6 (37–45)
Alignment	0	14.4±2.0 (8–15)	12.1±3.4 (8–15)	10.2±3.4 (8–15)

shape contribute to periosteal callus formation and early movement of the hallux. The distal osteotomy of the first metatarsus can be linear or oblique to shorten or lengthen the hallux, depending on the surgical indication and surgeon's preference. In the current study, to gain a good articularity, an oblique osteotomy to decompress the metatarsophalangeal articulation was preferred, especially in the presence of arthrosis and rigidity. Although the first metatarsal was shortened, overload of the second ray was prevented by plantarisation of the first metatarsus head. The stability of the Endolog system avoided migration of the head at the osteotomy site. The Endolog system enabled correction of moderate-

to-severe hallux valgus, using a minimally invasive procedure with a distal metatarsal osteotomy. A distal osteotomy, translation, rotation, angulation, and fixation of the metatarsal head, correction of the IMA, PASA, and pronation were achieved through a 3-cm incision. The Endolog system is not supposed to be removed. Thus, this technique should be reserved for patients aged >50 years or those with severe hallux valgus. The long-term effects of this technique warrant further investigation.

DISCLOSURE

No conflicts of interest were declared by the authors.

REFERENCES

- Nix S, Smith M, Vicenzino B. Prevalence of hallux valgus in the general population: a systematic review and meta-analysis. *J Foot Ankle Res* 2010;3:21.
- Ayub A, Yale SH, Bibbo C. Common foot disorders. *Clin Med Res* 2005;3:116–9.
- Ferrari J, Higgins JP, Prior TD. Withdrawn: Interventions for treating hallux valgus (abductovalgus) and bunions. *Cochrane Database Syst Rev* 2009;2:CD000964.
- Huang PJ, Lin YC, Fu YC, Yang YH, Cheng YM. Radiographic evaluation of minimally invasive distal metatarsal osteotomy for hallux valgus. *Foot Ankle Int* 2011;32:S503–7.
- Robinson AH, Limbers JP. Modern concepts in the treatment of hallux valgus. *J Bone Joint Surg Br* 2005;87:1038–45.
- De Lavigne C, Rasmont Q, Hoang B. Percutaneous double metatarsal osteotomy for correction of severe hallux valgus deformity. *Acta Orthop Belg* 2011;77:516–21.
- Wulker N, Suckel A. Metatarsal osteotomies for hallux valgus [in German]. *Orthopade* 2005;34:726, 728–34.
- Panchbhavi VK, Rapley J, Trevino SG. First web space soft tissue release in bunion surgery: functional outcomes of a new technique. *Foot Ankle Int* 2011;32:257–61.
- Yamamoto K, Imakiire A, Katori Y, Masaoka T, Koizumi R. Clinical results of modified Mitchell's osteotomy for hallux valgus augmented with oblique lesser metatarsal osteotomy. *J Orthop Surg (Hong Kong)* 2005;13:245–52.
- Tai CC, Ridgeway S, Ramachandran M, Ng VA, Devic N, Singh D. Patient expectations for hallux valgus surgery. *J Orthop Surg (Hong Kong)* 2008;16:91–5.
- Joseph TN, Mroczek KJ. Decision making in the treatment of hallux valgus. *Bull NYU Hosp Jt Dis* 2007;65:19–23.
- Nery C, Barroco R, Ressio C. Biplanar chevron osteotomy. *Foot Ankle Int* 2002;23:792–8.
- Trnka HJ, Zembsch A, Wiesauer H, Hungerford M, Salzer M, Ritschl P. Modified Austin procedure for correction of hallux valgus. *Foot Ankle Int* 1997;18:119–27.
- Donnelly RE, Saltzman CL, Kile TA, Johnson KA. Modified chevron osteotomy for hallux valgus. *Foot Ankle Int* 1994;15:642–5.
- Johnson JE, Clanton TO, Baxter DE, Gottlieb MS. Comparison of Chevron osteotomy and modified McBride bunionectomy for correction of mild to moderate hallux valgus deformity. *Foot Ankle* 1991;12:61–8.
- Meier PJ, Kenzora JE. The risks and benefits of distal first metatarsal osteotomies. *Foot Ankle* 1985;6:7–17.
- Bosch P, Wanke S, Legenstein R. Hallux valgus correction by the method of Bosch: a new technique with a seven-to-ten-year follow-up. *Foot Ankle Clin* 2000;5:485–98.
- Giannini S, Faldini C, Vannini F, Digennaro V, Bevoni R, Luciani D. The minimally invasive osteotomy "S.E.R.I." (simple, effective, rapid, inexpensive) for correction of bunionette deformity. *Foot Ankle Int* 2008;29:282–6.
- Coughlin MJ, Carlson RE. Treatment of hallux valgus with an increased distal metatarsal articular angle: evaluation of double and triple first ray osteotomies. *Foot Ankle Int* 1999;20:762–70.
- De Lavigne C, Rasmont Q, Hoang B. Percutaneous double metatarsal osteotomy for correction of severe hallux valgus deformity. *Acta Orthop Belg* 2011;77:516–21.
- Markbreiter LA, Thompson FM. Proximal metatarsal osteotomy in hallux valgus correction: a comparison of crescentic and chevron procedures. *Foot Ankle Int* 1997;18:71–6.
- Acevedo JI. Fixation of metatarsal osteotomies in the treatment of hallux valgus. *Foot Ankle Clin* 2000;5:451–68.
- Bock P, Lanz U, Kroner A, Grabmeier G, Engel A. The Scarf osteotomy: a salvage procedure for recurrent hallux valgus in selected cases. *Clin Orthop Relat Res* 2010;468:2177–87.
- Talbot KD, Saltzman CL. Hallucal rotation: a method of measurement and relationship to bunion deformity. *Foot Ankle Int* 1997;18:550–6.
- Glasoe WM, Nuckley DJ, Ludewig PM. Hallux valgus and the first metatarsal arch segment: a theoretical biomechanical perspective. *Phys Ther* 2010;90:110–20.