

“Endonyx” Onychomycosis: A New Modality of Nail Invasion by Dermatophytes

ANTONELLA TOSTI¹, ROBERT BARAN², BIANCA MARIA PIRACCINI¹ and PIER ALESSANDRO FANTI¹

¹Department of Dermatology, University of Bologna, Italy and ²Nail Disease Center, Cannes, France

Three patients with onychomycosis due to *Trichophyton soudanense* with an “endonyx” type of nail invasion are presented. Endonyx onychomycosis is clinically characterized by a diffuse milky-white discolouration of the affected nail, in the absence of nail bed hyperkeratosis or onycholysis. Nail plate surface and nail thickness are normal. The pathology shows a contrast between the great number of fungal hyphae visible in the nail plate and the absence of fungal elements in the nail bed. The nail bed does not show inflammatory changes or hyperkeratosis and adheres strictly to the lowermost layers of the nail plate. The hyponychium is normal and does not contain hyphae. The endonyx pattern of nail infection appears to be specific to *T. soudanense* nail invasion and may possibly reflect the high affinity of *T. soudanense* to hard keratins. **Key words:** dermatophytes; endonyx; onychomycosis; *Trichophyton soudanense*.

(Accepted May 19, 1998.)

Acta Derm Venereol (Stockh) 1999; 79: 52–53.

Antonella Tosti, Department of Dermatology, University of Bologna, Via Massarenti, I-40138 Bologna, Italy.

Three different modalities of nail invasion by dermatophytic fungi were originally described by Zaias in 1972, i.e. distal subungual onychomycosis, proximal subungual onychomycosis, and white superficial onychomycosis (1). Here we present pathological evidence of a different kind of onychomycosis, one that is characterized by an “endonyx” pattern of fungal invasion. This modality of nail invasion was observed in three patients with onychomycosis due to *Trichophyton soudanense*.

MATERIAL AND METHODS

Clinical findings

The patients (1 male and 2 females, aged 65–69 years) were immunocompetent Caucasians affected by a toenail onychomycosis associated with tinea pedis due to *T. soudanense*. The affected nails showed a

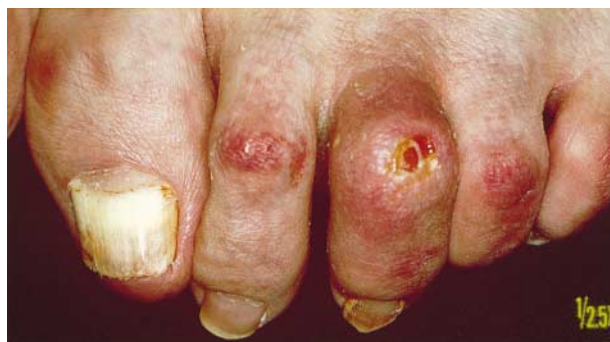

Fig. 1. *Trichophyton soudanense* onychomycosis of the great toenail. The nail plate is opaque and milky-white in colour.

diffuse milky-white discolouration (Fig. 1). The nail plate was firmly attached to the nail bed and there was no evidence of nail bed hyperkeratosis or onycholysis. Nail plate surface and nail thickness were normal.

Pathological study

A 4 mm punch nail bed biopsy was taken, after informed consent, from the distal portion of the great toenail. Specimens were routinely processed and stained with Hematoxylin & Eosin (HE) and PAS stain. The specimens showed identical pathological features. At low power view, the most striking aspect was the contrast between the abundance of fungal elements in the nail plate and the absence of fungal elements in the nail bed.

The nail plate stained weakly at HE and thickness was normal. Fungal hyphae were present throughout the length of the nail plate specimens. Fungi were almost exclusively confined to the ventral nail plate in one patient but penetrated its entire thickness in the other two patients (Fig. 2). The fungal elements appeared as elongated branching filaments arranged in both longitudinal and transverse manner.

The nail bed showed no inflammatory changes or hyperkeratosis and adhered strictly to the lowermost layers of the nail plate. The

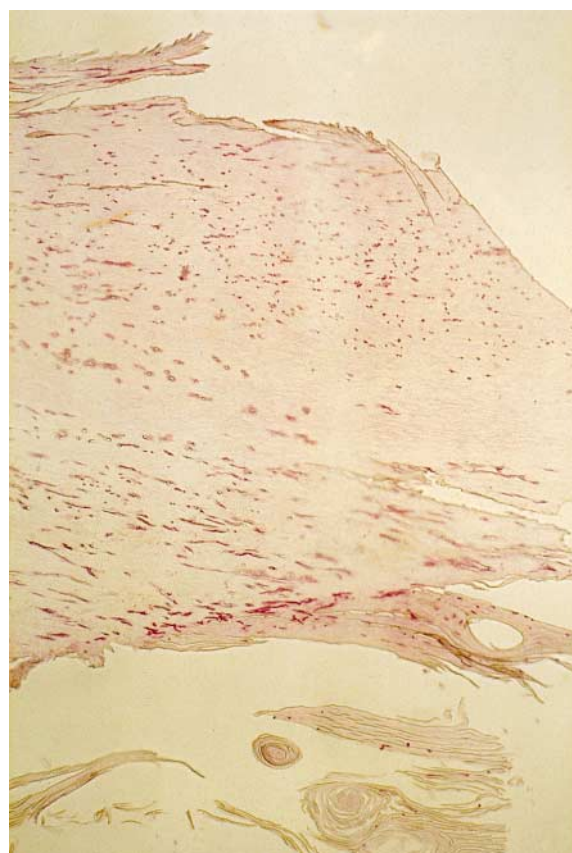


Fig. 2. *Trichophyton soudanense* onychomycosis. The entire thickness of the nail plate contains branching fungal filaments arranged in both longitudinal and transverse manner (PAS 200 ×).

hyponychium was normal and did not contain hyphae. A few fungal elements were visible within the nail bed scant horny layer.

DISCUSSION

Endonyx onychomycosis differs from distal subungual onychomycosis because of the absence of nail bed hyperkeratosis and onycholysis. In all our cases the nail plate was so firmly attached to the nail bed that clipping to obtain subungual debris produced pain and diffuse bleeding. Pathologically, endonyx onychomycosis is characterized by massive nail plate invasion in the absence of nail bed inflammatory changes. Similar pathological features have previously been reported in onychomycosis due to *Trichophyton violaceum* (2, 3).

The presence of tunnels filled with fungal elements in the whole thickness of the nail plate explains the milky-white discolouration, which was the prominent clinical manifestation of onychomycosis due to *T. soudanense* in all our patients. The white colour is caused by alteration in light diffraction, as in leukonychia. The clinical peculiarities of nail infection due to some endothrix dermatophytes have already been noticed by Kalter & Hay (4), who stressed the clinical differences between onychomycosis due to *T. soudanense* or

T. violaceum and distal subungual onychomycosis due to *Trichophyton rubrum*.

According to Zaias, the modality of nail invasion by dermatophytes is mainly related to the biological characteristics of the responsible fungi, and particularly to their biochemical ability to invade the nail plate (5).

The endonyx pattern of nail infection appears to be specific for *T. soudanense* nail invasion and may possibly reflect the high affinity of *T. soudanense* as well as *T. violaceum* for hard keratins.

REFERENCES

1. Zaias N. Onychomycosis. Arch Dermatol 1972; 105: 263–274.
2. Shagher F. Histologic examination of fungus infections of the nails. J Invest Dermatol 1948; 11: 337–357.
3. Graham JH. Superficial fungus infections. In: Graham JH, Johnson WC, Helwig EB, eds. Dermal pathology. Hagerstown, MD: Harper & Row, 1972: 137–253.
4. Kalter DC, Hay RJ. Onychomycosis due to *Trichophyton soudanense*. Clin Exp Dermatol 1988; 13: 221–227.
5. Zaias N. Onychomycosis. In: Zaias N, ed. The nail in health and disease. 2nd ed. East Norwalk, CT: Appleton & Lange, 1990: 87–105.

Copyright of Acta Dermato-Venereologica is the property of Society for Publication of Acta Dermato-Venereologica and its content may not be copied or emailed to multiple sites or posted to a listserv without the copyright holder's express written permission. However, users may print, download, or email articles for individual use.