

Intraretinal Correlates of Reticular Pseudodrusen Revealed by Autofluorescence and En Face OCT

We read with great interest the article by Paavo et al.¹ entitled “Intraretinal correlates of reticular pseudodrusen revealed by autofluorescence and en face OCT.” We congratulate the authors for the excellent multimodal imaging description of reticular pseudodrusen (RPD) and the correlation between each imaging technique. We agree that RPD could be the result of a degenerative process of the RPE and photoreceptor layer. The authors supported this theory with the reduced melanin signal observed on near-infrared fundus autofluorescence (NIR-AF), the reduced reflectivity detected on en face optical coherence tomography (OCT) images, and reduced autofluorescence on short wavelength autofluorescence (SW-AF) corresponding to the sites of RPD.¹ On the other hand, the authors reported that bright spots were detectable within some darkened foci of NIR-AF, SW-AF, and near-infrared reflectance (IR-R) images, resulting in the “target lesion” aspect. Querques et al.^{2,3} first described the “target aspect” of RPD at IR-R and SW-AF matching on spectral domain OCT a well-defined round or triangular hyperreflective lesion localized between RPE and the external limiting membrane or outer plexiform layer. Querques G, et al. *IOVS* 2010;51:ARVO E-Abstract 2265.^{2,3} According to the description of Querques et al.,^{2,3} looking at the original images by Paavo et al.,¹ indeed these bright spots seem to be present in most RPD cases as isoautofluorescent or hyperautofluorescent spots inside hypoautofluorescent foci, resulting in the “target lesion” aspect (Fig.).

Querques et al.^{2,3} suggested that RPE deposits may be constituted at least in part by extracellular lipofuscin-like material, which accumulates either primarily or secondarily to a dysfunctional RPE. However, besides the prevalence of these

bright spots in RPD, the authors failed to discuss this important imaging characteristic and did not explain how their theory about RPE and photoreceptor layer degeneration could support this finding.

Riccardo Sacconi^{1,2}
Giuseppe Querques¹

¹Department of Ophthalmology, University Vita-Salute, IRCCS Ospedale San Raffaele, Milan, Italy; and ²Eye Clinic, Department of Neurological, Biomedical and Movement Sciences, University of Verona, Verona, Italy.
E-mail: giuseppe.querques@hotmail.it

Acknowledgments

Disclosure: **R. Sacconi**, None; **G. Querques**, Alimera Sciences (C), Allergan, Inc. (C), Bayer Shering-Pharma (C), Heidelberg (C), Novartis (C), Sandoz (C), Zeiss (C)

References

1. Paavo M, Lee W, Merriam J, et al. Intraretinal correlates of reticular pseudodrusen revealed by autofluorescence and en face OCT. *Invest Ophthalmol Vis Sci*. 2017;58:4769–4777.
2. Querques G, Querques L, Martinelli D, et al. Pathologic insights from integrated imaging of reticular pseudodrusen in age-related macular degeneration. *Retina*. 2011;31:518–526.
3. Querques G, Souied EH. Correspondence. *Retina*. 2015;35:e4–e6.

Citation: *Invest Ophthalmol Vis Sci*. 2017;58:6193.
doi:10.1167/iovs.17-23166

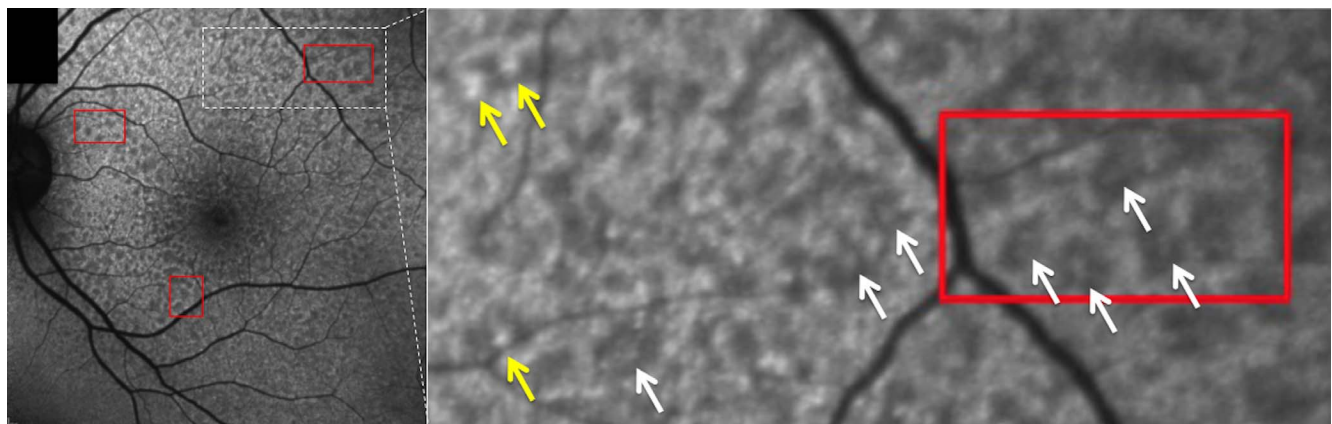


FIGURE. SW-AF of reticular RPD (adapted from Fig. 1 of Paavo M, Lee W, Merriam J, et al.¹). SW-AF image showing several “bright spots” as isoautofluorescent (white arrows) or hyperautofluorescent (yellow arrows) spots inside hypoautofluorescent foci, resulting in the “target lesion” aspect of RPD.

