

Unilateral inferior turbinate hypoplasia caused by a longstanding (approximately 35 yr) nasal foreign body

Fiorenza Derosas, MD; Gino Marioni, MD; Giuseppe Brescia, MD; Alessandra Florio, MD; Claudia Staffieri, MD; Alberto Staffieri, MD

Abstract

We report the unusual case of a 44-year-old man who presented with a plastic foreign body that had been lodged in his right nasal cavity for approximately 35 years. Initial attempts to remove the object were unsuccessful; only after it was broken into several parts was removal achieved. Rigid nasal endoscopy and computed tomography revealed hypoplasia of the ipsilateral inferior turbinate.

Introduction

Reports of foreign bodies being lodged in the nasal cavity for more than 20 years are rare in the English-language literature. We describe the case of a nasal foreign body that had been impacted for approximately 35 years. We also discuss the resultant hypoplasia of the inferior turbinate on the ipsilateral side.

Case report

We evaluated a 44-year-old man who complained of recurrent right-sided epistaxis of approximately 2 years' duration. These episodes were self-limited and did not require any medical or surgical treatments. During the previous year, he had also experienced cacosmia, ipsilateral rhinorrhea, and mild facial pain in the area of the right maxillary sinus.

Four months earlier, the patient had been evaluated at another otolaryngology department and diagnosed with acute rhinosinusitis. He was treated with an oral antibiotic (amoxicillin) and a topical nasal steroid (budesonide), but he experienced only limited improvement. The patient's general

practitioner then ordered computed tomography (CT), which revealed a low-density area in the right nasal cavity that was surrounded by a 2-cm area of higher density (figure 1). CT did not identify any paranasal sinus abnormalities. Based on the patient's clinical history and CT findings, we hypothesized that he had rhinolithiasis.

Videorhinoscopy (4 mm, 30°) of the right nasal cavity detected a calcified mass leaning on the nasal floor between the septum and the middle and anterior portion of the inferior turbinate. Part of the turbinate was hypoplastic. The mass was hard to the instrument's touch. The left nasal cavity was normal.

The patient was administered topical anesthesia, and an attempt to remove the mass was undertaken. However, removal was difficult because of the significant size of the foreign body. We therefore broke the object into several parts, which we removed separately. The foreign body appeared to be a toy rubber bullet (figure 2). The patient remembered having played with such toys when he was approximately 8 to 10 years old. Ever since, the impacted object had been acting as a nucleus for salt concretion.

Further examination revealed that the body and the tail of the right inferior turbinate were normal, but the head was significantly hypoplastic. Following the endoscopic procedures, the endonasal mucosa was deepithelialized. A silicon sheet was placed between the septum and lateral nasal wall to reduce the risk of synechia formation; the sheet was removed endoscopically after 10 days without complication.

Discussion

Nasal foreign bodies are commonly encountered in children and mentally handicapped patients, whose curiosity leads them to explore body orifices. The list of objects that have been removed from the nose is quite lengthy. The most common are rubber erasers, paper wads, pebbles, beads, marbles, beans, safety pins, washers, nuts, sponges, and

From Centro Medico-Chirurgico di Foniatria, Padova, Italy (Dr. Derosas), and the Otorhinolaryngology Clinic, Department of Medical-Surgical Specialties, University of Padova (Dr. Derosas, Dr. Marioni, Dr. Brescia, Dr. Florio, Dr. C. Staffieri, and Dr. A. Staffieri).

Corresponding author: Gino Marioni, MD, Via Giustiniani 2, 35100 Padova, Italy. Phone: 39-49-821-8626; fax: 39-49-875-2266; e-mail: gino.marioni@unipd.it

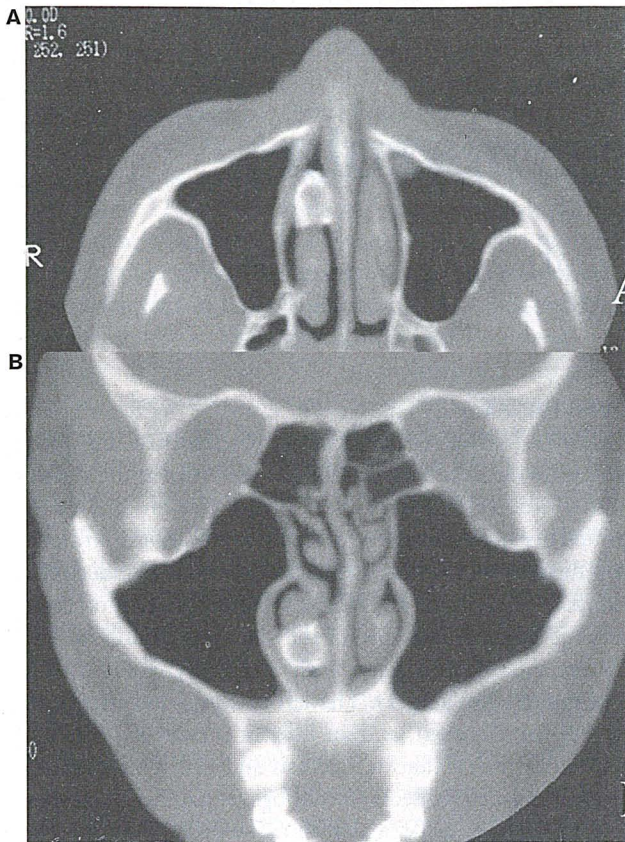


Figure 1. Axial (A) and coronal (B) CTs show the 2-cm foreign body in the right nasal cavity.

chalk.¹ These objects can become lodged in any portion of the nasal cavity, but most are discovered around the floor of the nose just below the inferior turbinate, as occurred in our patient. Another common location is immediately anterior to the middle turbinate.

The presence of a foreign body for more than a brief period is likely to interrupt normal mucociliary clearance and result in inflammation and infection, although plastic and other inert materials may be tolerated for long intervals. During the period of impaction, a foreign body may become enveloped by the gradual formation of exuberant granulation tissue. The foreign body may act as a nucleus for concretion, or it may become buried in granulation tissue; in the latter case, the globule may become enveloped in a coating of calcium, magnesium phosphate, and carbonate and become a rhinolith.

The longstanding presence of a firmly impacted nasal foreign body may exert pressure on surrounding bone and erode it; erosion into the maxillary sinus and perforation of the palate by pressure necrosis have been described.² The rubber foreign body in our patient was covered with a deposit of mineralized concretions. We also observed hypoplasia of the right inferior turbinate that corresponded with the

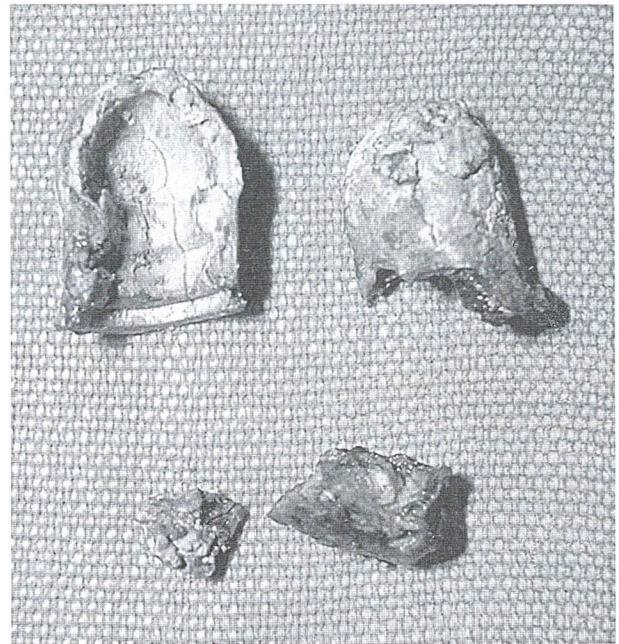


Figure 2. Removal of the bullet-shaped foreign body was achieved only after it was broken into several pieces.

location of the foreign body. The hypoplasia was probably caused by both the longstanding presence of the foreign body and the object's size, which caused compression of the endonasal structures.

Our patient's nasal foreign body might have affected the growth and development of his inferior turbinate, and it might have modified his respiration. The age of our patient at the time we suspect the foreign body was aspirated (8 to 10 years) is important. Prior to puberty, the inferior turbinate and inferior meatus enlarge and become significant anatomic structures.³

Although foreign bodies typically cause unilateral purulent and bloodstained rhinorrhea, bilateral symptoms are sometimes present. Nasal occlusion has been frequently reported. Pain and headache are usually not experienced on the involved side. Halitosis has been described occasionally as an isolated presenting symptom. Ipsilateral or bilateral otitis media is a potential infectious sequela of a nasal foreign body; infection can be caused by posterior nasal inflammation with functional obstruction of the eustachian tube.⁴

Cases of nasal foreign bodies that have remained asymptomatic for more than 30 years are unusual. It is difficult to understand why the foreign body in our patient began to cause recurrent epistaxis, pain, and acute rhinosinusitis after so long. It is possible that the increasing accumulation of concretions around the foreign body over the years led to the slow compression and inflammation of the surrounding tissues.

Continued on page 33

ation. Instead the patient received combination therapy and repeated local debridements, and he recovered completely. However, this case differs from ours in that this patient had several predisposing factors for invasive fungal sinusitis; he was diabetic, and he had received a liver transplant for hepatitis C-related cirrhosis. Also, this patient had developed fungal sinusitis while receiving systemic liposomal amphotericin B, whereas our patient had received only inhaled amphotericin.

While our case and the case reported by Tsiodras et al¹³ are rare and were characterized by somewhat extenuating circumstances, each represents a clear case of successful treatment of this invasive disease with relatively nontoxic medications that spared both patients radical, disfiguring surgery.

Our experience suggests that combination therapy with caspofungin and voriconazole may prove to be safe and effective in the management of invasive *Aspergillus* sinusitis, and we believe it should be considered a therapeutic option in the future.

References

1. Ferguson BJ. Definitions of fungal rhinosinusitis. *Otolaryngol Clin North Am* 2000;33(2):227-35.
2. Petraitis V, Petraitiene R, Sarafandi AA, et al. Combination therapy in treatment of experimental pulmonary aspergillosis: Synergistic interaction between an antifungal triazole and an echinocandin. *J Infect Dis* 2003;187(12):1834-43.
3. Stringer SP, Ryan MW. Chronic invasive fungal rhinosinusitis. *Otolaryngol Clin North Am* 2000;33(2):375-87.
4. Washburn RG, Kennedy DW, Begley MG, et al. Chronic fungal sinusitis in apparently normal hosts. *Medicine (Baltimore)* 1988;67(4):231-47.
5. Denning DW. Invasive aspergillosis. *Clin Infect Dis* 1998;26(4):781-803.
6. Arikian S, Lozano-Chiu M, Paetznick V, Rex JH. In vitro synergy of caspofungin and amphotericin B against *Aspergillus* and *Fusarium* spp. *Antimicrob Agents Chemother* 2002;46(1):245-7.
7. Marr KA, Boeckh M, Carter RA, et al. Combination antifungal therapy for invasive aspergillosis. *Clin Infect Dis* 2004;39(6):797-802.
8. Maertens J, Glasmacher A, Herbrecht R, et al. Multicenter, noncomparative study of caspofungin in combination with other antifungals as salvage therapy in adults with invasive aspergillosis. *Cancer* 2006;107(12):2888-97.
9. Herbrecht R, Denning DW, Patterson TF, et al; Invasive Fungal Infections Group of the European Organisation for Research and Treatment of Cancer and the Global *Aspergillus* Study Group. Voriconazole versus amphotericin B for primary therapy of invasive aspergillosis. *N Engl J Med* 2002;347(6):408-15.
10. Perea S, Gonzalez G, Fothergill AW, et al. In vitro interaction of caspofungin acetate with voriconazole against clinical isolates of *Aspergillus* spp. *Antimicrob Agents Chemother* 2002;46(9):3039-41.
11. Manavathu EK, Alangaden GJ, Chandrasekar PH. Differential activity of triazoles in two-drug combinations with the echinocandin caspofungin against *Aspergillus fumigatus*. *J Antimicrob Chemother* 2003;51(6):1423-5.
12. Kirkpatrick WR, Perea S, Coco BJ, Patterson TF. Efficacy of caspofungin alone and in combination with voriconazole in a Guinea pig model of invasive aspergillosis. *Antimicrob Agents Chemother* 2002;46(8):2564-8.
13. Tsiodras S, Zafiropoulou R, Giotakis J, et al. Deep sinus aspergillosis in a liver transplant recipient successfully treated with a combination of caspofungin and voriconazole. *Transpl Infect Dis* 2004;6(1):37-40.

UNILATERAL INFERIOR TURBINATE HYPOPLASIA CAUSED BY A LONGSTANDING (APPROXIMATELY 35 YR) NASAL FOREIGN BODY

Continued from page 29

The differential diagnosis of a longstanding nasal foreign body should include unilateral sinusitis, unilateral nasal calcified polyp, osteoma, osteomyelitis, fungal infection,⁴ syphilis,¹ and benign and malignant tumors of the nasal cavities. Axial and coronal CTs without contrast enhancement are useful for performing an accurate study of the mass and its relation to adjacent structures,⁵ but rigid nasal endoscopy is an ideal method for establishing an instant diagnosis.²

In accordance with recommendations published in the literature, we removed the foreign body from our patient via an endonasal endoscopic approach with local anesthesia. After the object was removed, the endoscopic view of the right nasal cavity confirmed the hypoplasia of the ipsilateral inferior turbinate.

References

1. Kalan A, Tariq M. Foreign bodies in the nasal cavities: A comprehensive review of the aetiology, diagnostic pointers, and therapeutic measures. *Postgrad Med J* 2000;76(898):484-7.
2. Stoney P, Bingham B, Okuda I, Hawke M. Diagnosis of rhinoliths with rigid endoscopy. *J Otolaryngol* 1991;20(6):408-11.
3. Rontal M, Anon JB, Zinreich SJ. Embryology and anatomy of the paranasal sinuses. In: Bluestone CD, Stool SE, Alper CM, et al, eds. *Pediatric Otolaryngology*. 4th ed. Philadelphia: W.B. Saunders; 2003:861-75.
4. Sculerati N. Foreign bodies of the nose. In: Bluestone CD, Stool SE, Alper CM, et al, eds. *Pediatric Otolaryngology*. 4th ed. Philadelphia: W.B. Saunders; 2003:1032-7.
5. Celikkanat S, Turgut S, Ozcan I, et al. Rhinolithiasis. *Rhinology* 1997;35(1):39-40.