

## INVESTIGATIVE REPORT

# Recombinant Human Erythropoietin Influences Revascularization and Healing in a Rat Model of Random Ischaemic Flaps

MICHELE BUEMI<sup>1</sup>, MARIO VACCARO<sup>2</sup>, ALESSIO STURIALE<sup>1</sup>, MARIA ROSARIA GALEANO<sup>3</sup>, CARLO SANSOTTA<sup>4</sup>, VITTORIO CAVALLARI<sup>5</sup>, FULVIO FLOCCARI<sup>1</sup>, DOMENICO D'AMICO<sup>2</sup>, VALERIO TORRE<sup>5</sup>, GIOACCHINO CALAPAI<sup>6</sup>, NICOLA FRISINA<sup>1</sup>, FABRIZIO GUARNERI<sup>2</sup> and GIUSEPPE VERMIGLIO<sup>4</sup>

<sup>1</sup>Department of Internal Medicine, <sup>2</sup>Institute of Dermatology, <sup>3</sup>Department of Plastic Surgery, <sup>4</sup>Department of Physics, <sup>5</sup>Department of Human Pathology and <sup>6</sup>Clinical Experimental Department of Medicine and Pharmacology, University of Messina, Italy

In order to ascertain whether erythropoietin plays a role in early and late repair processes following ischaemic skin flap injury, a dorsal, caudally based skin flap was created in rats. The rats were successively divided into four groups. Group 1 was not treated. The other groups were treated with a subcutaneous administration of 0.9% NaCl saline solution (group 2), a subcutaneous administration of vehicle (group 3) or a subcutaneous administration of 300 IU/kg/day of recombinant human erythropoietin (group 4). We evaluated the possible relationships between neutrophil accumulation, myeloperoxidase activity and content in flap tissue, flap survival, flap temperature (using telethermography) and flap revascularization (using videocapillaroscopy). Necrosis in the flap was significantly less extensive in group 4 than in groups 1, 2 and 3. A significant increase in neutrophil infiltration occurred between the 1st and 24th hour in these groups, but this was not observed in group 4. These findings were confirmed by biochemical data of myeloperoxidase activity and malonyldialdehyde content. Between the 1st and 7th days, we recorded an increase of about 20% in flap temperature in groups 1, 2 and 3, whereas no significant variation was observed in group 4. On the 7th day, videocapillaroscopic findings showed an increase in the mean vascularization index in group 4. Our findings suggest that recombinant human erythropoietin administration can improve the wound healing process, in both early and late stages of injury, by reducing inflammatory response, increasing the density of capillaries in ischaemic flaps and allowing earlier repair of a damaged area. **Key words:** erythropoietin; ischaemic skin flap injury; neo-vascularization; wound healing.

(Accepted July 23, 2002.)

Acta Derm Venereol 2002; 82: 411–417.

Mario Vaccaro, Institute of Dermatology, Policlinico Universitario, Via Consolare Valeria Gazzi, IT-98125 Messina, Italy. E-mail: Mario.Vaccaro@unime.it

Erythropoietin (Epo), a glycoprotein stimulating the formation of erythrocytes from their precursors, is the drug of choice in the treatment of anaemia, especially in

patients with renal diseases (1). Experimental evidence demonstrates that this hormone can stimulate mitosis and induce differentiation and activation of numerous cell lines, such as those of endothelium, myocardium, smooth muscle and mesangium (2–4).

The finding of Epo receptors on endothelial cells prompted several *in vitro* and *in vivo* investigations aimed to determine whether the hormone may directly affect some of the functions of these cells (5–7): particular attention has been paid to the complex network of cytokines and growth factors involved in both the maturation of red cells and the proliferation of endothelial cells (8). The numerous elements common to these two processes are probably linked to their similar embryonic origin and to the genetic programme of erythrocytes and endothelial cells. In embryonic stem cells of rats in culture, it has been confirmed that a single cell type differentiates into endothelial or haematopoietic cells, depending on the culture medium (9, 10). The endothelium, cornerstone of the vascular repair process in adults (11), intervenes in the control of the post-angioplastic parietal wound-healing process and in the angiogenic response to ischaemia.

Numerous angiogenic growth factors have been characterized so far, including vascular endothelial growth factor (VEGF) (12, 13) and families of fibroblastic growth factors (14). Like them, Epo influences certain properties of endothelial cells in culture, such as cell proliferation and motility, which are *in vivo* correlated with neovascularization (15). On this basis, we ascertained whether recombinant human Epo (rHuEpo) influences revascularization and healing in a rat model of random ischaemic flaps.

## MATERIALS AND METHODS

### Animals

Fifty-one inbred Sprague-Dawley male rats (body weight 300–350 g) were acclimatized for 7 days at a constant temperature of 22 ± 2°C under a 12-h light/12-h dark cycle (lights on at 06.00 h), and had free access to Purina rat chow pellets and tap water. In 48 rats, caudally based dorsal random skin flaps were created following the procedure described by Green et al. (16). These animals were then divided into 4 groups of 12 animals as follows: control without

drug administration (group 1), control with subcutaneous administration of 0.9% NaCl saline solution (group 2), control with subcutaneous administration of the rHuEpo vehicle (group 3), animals with subcutaneous administration of 300 IU/kg/day of rHuEpo (group 4). All substances were administered once daily, between 15.00 and 16.00 h, for 7 days after surgery.

Cutaneous fragments were taken from the limb 1 h, 24 h and 7 days after surgery. The fragments, taken at 4.5 cm from the caudal margin of the flap, were fixed in formalin at room temperature. Three rats were sham-operated and used exclusively as source of normal skin for biochemical data comparison.

### *Surgical procedure*

All animals were premedicated with the subcutaneous administration of a standard dose of atropine sulphate (0.02 mg) and anaesthetized with a standard dose of ketamine (100 mg/kg of body weight) intraperitoneally and xylazine (50 mg/kg) i.m. The skin was shaved and washed with Betadine. The random skin flap was 9 cm long and 3 cm wide, a proximal peduncle being cut on the dorsal surface of the rat. The flap included skin, subcutaneous layer and panniculus carnosus, with triangular lateral extensions of 0.5 mm. It was incised and raised, and then immediately re-sutured in its bed.

The flaps were observed every day for 7 days. Viable and necrotic portions were measured on the 1st and 7th days by the same observer. On the 7th day, restitutio ad integrum and uniformity of skin growth in rHuEpo-treated and non rHuEpo-treated animals were compared. At the same time, a photograph of each flap was taken and the percentage of necrotic skin was measured in rHuEpo-treated animals and controls. Moreover, at time 0 and on days 1 and 7, the dorsal area of each rat was submitted to telethermographic and videocapillaroscopic study. All procedures were executed on the animals in conformity with the Declaration of Helsinki and Instructions for the Care of Laboratory Animals.

### *Histological examination*

Skin samples 1 cm<sup>2</sup> in size were taken 4.5 cm from the proximal portion of the flap, 60 min, 24 h and 7 days after surgery. The samples were fixed in 10% formalin, embedded in paraffin and 4 µ sections were obtained for haematoxylin and eosin staining. All slides were examined under high power ( $\times 400$ ) light microscopy by two of the authors, who were blinded to the grouping. Accumulation of inflammatory cells was evaluated at the 1st and 24th postoperative hours in the dermal and subcutaneous areas above the panniculus carnosus. Proliferation of endothelial and fibroblastic cells was also evaluated. A four-step scoring system (from + to + + + +) was used to express the results in accordance with the number of cells (i.e. endothelial cells and fibroblasts) found in the involved area.

### *Biochemical analysis*

Soon after tissue samples were obtained, they were placed in liquid nitrogen and stored at  $-80^{\circ}\text{C}$  until analysis. They were then sectioned at 20 µm and desiccated under vacuum at  $-20^{\circ}\text{C}$  for the entire night. The sections were kept in dry ice ( $-20^{\circ}\text{C}$ ) until biochemical analysis.

*Malonyldialdehyde (MDA) assay.* Lipid peroxidation was assayed in cutaneous tissue samples by measuring the levels of MDA, the final product of lipid peroxidation. The

homogenates, prepared from 20 mg of dry frozen tissue, were suspended in 1.5 ml of cold saline solution containing 0.001% of hydroxytoluene butylate (BHT) and 0.07% of sodium dodecil sulphate, using a Potter-type homogenizer in glass. The saline solution and BHT were air-injected with gaseous nitrogen 10 min before use. The homogenate was treated with a mixture of ethanol and chloroform (3:2) to remove contaminated haemoglobin. The MDA was assayed using a calorimetric reaction with thiobarbituric acid as described by Shin et al. (17). Protein concentration of the homogenate was determined using the method described by Lowry et al. (18). The concentration of MDA was expressed in nanomoles per milligram of proteins.

*Assay of the activity of tissue myeloperoxidase (MPO).* Homogenates were prepared from 20 mg of dry frozen tissue in 0.5 ml of 50 mM phosphate buffer (pH 6.0). To trigger the release of MPO contained in neutrophil granules, 0.5 ml of esadecil trimethyl amonium bromide in 50 mM of phosphate buffer (pH 6.0) was added to the homogenates, and they were then sonicated for 1 min, dissolved, re-frozen three times and then re-sonicated. The homogenates were centrifuged at 32,000 rpm for 15 min. A part of each supernatant was sampled with guaiacolate to determine MPO activity using the procedure described by Tagesson et al. (19). The increase in the absorbance at 470 nm was recorded spectrophotometrically every 15 sec for 5 min. The concentration of protein in each surnatant was determined using Lowry's method (18). Enzymatic activity was expressed as micromoles of substrate consumed per minute per milligrams of protein.

### *Telethermographic analysis*

Rats were acclimatized for not less than 15 min in a thermostatic environment at  $22^{\circ}\text{C}$ , with a constant ventilation of 1 m/s, and sedated with ketamine (50 mg/kg) 15 min before measurement. They were then positioned for photographing the camera lens being at a distance of 1 m; the sensor plane was designated inside the infra-red telecamera parallel. A modified AGA Telethermovision 720 was used to obtain images, which were then fed into a personal computer (Intel Pentium III 450 MHz) using a digitized image-card (Co.Re.Co. Oculus Tci). The images, acquired in black/white modality at 256 tones of grey, were then fed into specific software for graphic processing (Media Cibernetics Image Pro Plus). Graphic processing consisted of: (a) moderation of the image, (b) application of a scale of pseudo colours; (c) quantification of the isothermic areas and normalization of the isoareas; (d) calculation of the mean index of the image (MII). For MII processing, the values for the single isoareas were compared in a homogeneous way through an algorithm that, applied to each image, allowed the transformation of numerous graphic and numerical data contained in the same image in a single number, ranging from 0 to 9, which represented the thermal level of the area of telethermographic interest.

### *Videocapillaroscopic analysis*

The microangiotectionic examination of skin flaps was performed using a computerized optical probe videomicroscope (Videocap 200, DS MediGroup) with  $\times 200$  magnification factor lens. This system was connected to a PC (Hewlett-Packard Vectra) for image-processing and storage. Software for instrument control and image processing was that provided by the manufacturer. The examination was carried out

in an environment at controlled temperature (22°C). The fur on the flap skin was shaved with a disposable razor in order to allow an easier examination with the optic probe and to improve the visibility of the capillary loops. A drop of immersion oil was placed on the cutaneous surface to be analysed in order to enhance the transparency of the corneal layer of the rats and the optic qualities of the videomicroscope. The examination started from the peduncle of the skin flap, progressively proceeding to its distal portion. Thirty microscopic fields of 1 cm<sup>2</sup> were evaluated in each rat. The evaluation of vessel status was made by two independent observers. A score was used to express:

- absence of capillaries in the microscopic field (0 points)
- presence of isolated and ectasic vessels, with oedema and perivascular haemorrhages (1 point)
- presence of ramified vessels (2 points)
- presence of highly ramified vessels over the entire microscopic field (3 points).

An arithmetical mean of the scores attributed by both operators was then calculated for each microscopic field analysed. The sum of the scores of the 30 microscopic fields was considered as index of vascularization of the area.

A capillaroscopic evaluation was made a few minutes before the flap was created (T0), and one day (T1) and 7 days (T7) after surgery, to evaluate the variation of vascularization index.

*Statistical analysis*

Data were analysed using the statistics software package Statistical Product for Social Science release 7.5 (SPSS, IL, USA). Data analysis was performed using the ANOVA one-way test, with the Scheffe post hoc test for multiple comparisons when appropriate. Data were expressed as mean ± SD. Statistical significance was set at *p* < 0.05.

**RESULTS**

*Weight, haematocrit and area of flap necrosis*

On the first day after surgery, weight and haematocrit were not modified to a statistically significant extent in either rHuEpo-treated or non-rHuEpo-treated animals. On the 7th day, all rats had lost weight: the mean weight loss was 80 ± 18 g in group 1, 77 ± 13 g in group 2 and 75 ± 15 g in group 3, while the rats in group 4

Table I. Neutrophilic accumulation, endothelial cells and fibroblastic proliferation in skin samples, evaluated by microscopy at various time points after surger

	Neutrophils				Endothelial cells		Fibroblast proliferation	
	Extravascular		Intravascular		24 h	7 days	24 h	7 days
	1 h	24 h	1 h	24 h				
Group 1 (no treatment)	++	++++	++	++++	+	++	++	+++
Group 2 (0.9% NaCl)	++	+++	++	+++	+	++	++	++
Group 3 (rHuEpo vehicle)	++	+++	++	+++	++	+	++	++
Group 4 (rHuEpo)	+	+	+	+	++	+++	++	++++

rHuEpo: recombinant human erythropoietin.

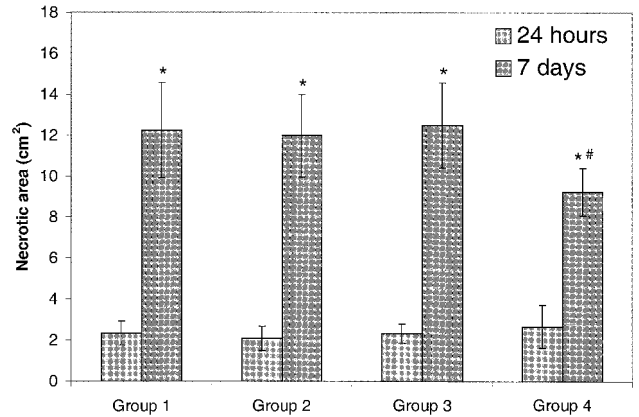


Fig. 1. Extension of necrotic areas in caudally based dorsal flaps, in control groups (1–3) and in the rHuEpo-treated group (4), 24 h and 7 days after surgery (\**p* < 0.05 versus same area at 24 h; #*p* < 0.05 versus groups 1, 2 and 3 at 7 days).

had lost only 32 ± 8 g (*p* < 0.05 vs. groups 1, 2 and 3). Haematocrit values of the four groups were comparable.

The ischaemic area of flaps, 24 h after surgery, measured 2.4 ± 0.6 cm<sup>2</sup> in group 1, 2.1 ± 0.6 cm<sup>2</sup> in group 2, 2.4 ± 0.45 cm<sup>2</sup> in group 3 and 2.7 ± 1.05 cm<sup>2</sup> in group 4 (Fig. 1). No statistically significant differences were found in the mean extension of the necrotic area between groups 1, 2, 3 and group 4.

On the 7th day, the necrotic area of flaps measured 12.3 ± 2.4 cm<sup>2</sup> in group 1, 12 ± 2 cm<sup>2</sup> in group 2 and 12.5 ± 2.1 cm<sup>2</sup> in group 3 (Fig. 1). Suture margins appeared pale and were easily scraped away in all these groups. In group 4, the necrotic area measured 9.3 ± 1.2 cm<sup>2</sup> (*p* < 0.05 vs. groups 1, 2 and 3); suture margins appeared more tenacious in comparison with controls, and were more resistant to cutting.

*Histopathological results*

Table I shows that, 1 h after surgery, ischaemia had caused neutrophil accumulation both in vessels and in extravascular areas in groups 1, 2 and 3. In group 4, a limited accumulation of neutrophils was recorded, in comparison with groups 1, 2 and 3, both in vessels and in extravascular areas.

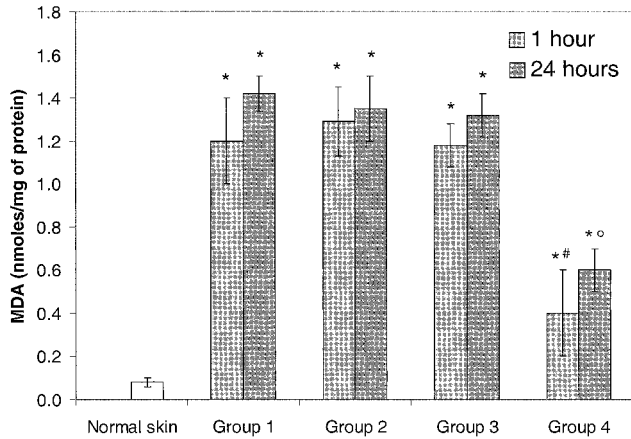


Fig. 2. Malonyldialdehyde (MDA) in flap tissue, 1 h and 24 h after surgery. In rHuEpo-treated rats, the increase in MDA levels appears smaller than in controls (\* $p < 0.05$  versus normal skin; <sup>#</sup> $p < 0.05$  versus groups 1, 2, 3 at 1 h; <sup>o</sup> $p < 0.05$  versus groups 1, 2, 3 at 24 h). For group explanations see Table I.

Twenty-four hours later, neutrophil accumulation in vessels and, particularly, in extravascular areas was considerably increased in groups 1, 2 and 3, while in group 4 the histological pattern of neutrophil localization was comparable with the first hour pattern. On the 7th day, fibroblast proliferation, which is essential for proper wound healing, was less evident in groups 1, 2 and 3 than in group 4. Moreover, a higher number of endothelial cells were found in group 4 (Table I).

Biochemical analysis

Ischaemia caused an increase in MDA levels, statistically significant versus normal skin, at both 1 h and at 24 h after flap elevation in all groups of animals. In rHuEpo-treated rats (group 4), the increase in MDA levels appeared smaller than in controls (groups 1, 2

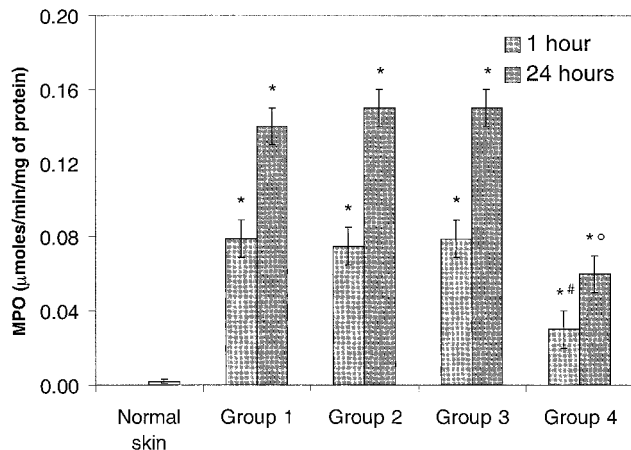


Fig. 3. Myeloperoxidase (MPO) flap tissue activity after the 1st hour and at 24 h. In rHuEpo-treated rats, MPO activity increased, in response to ischaemia, less than in controls (\* $p < 0.05$  versus normal skin; <sup>#</sup> $p < 0.05$  versus groups 1, 2, 3 at 1 h; <sup>o</sup> $p < 0.05$  versus groups 1, 2, 3 at 24 h). For group explanations see Table I.

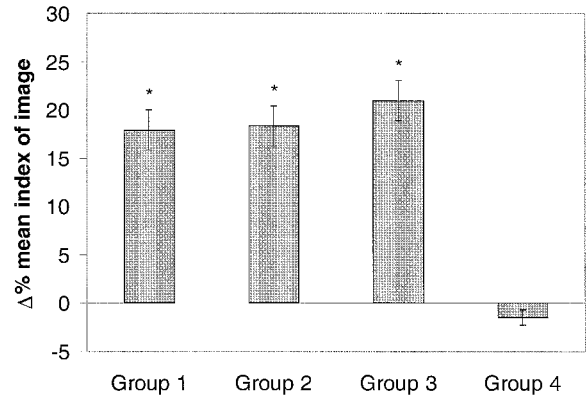


Fig. 4. Percent change of mean index of image (telethermography) between 1st and 7th day after surgery. A decrease of the mean index of image was observed in rHuEpo-treated rats, while an increase was observed in controls (\* $p < 0.05$  between values at 1st and 7th day). For group explanations see Table I.

and 3), both at the 1st hour and at 24 h, as shown in Fig. 2. Elevation of the flap induced a sharp increase in MPO activity in comparison with normal skin.

MPO data for the three control groups (groups 1, 2 and 3) both after the 1st hour and at 24 h were comparable. In group 4, MPO activity increased, in response to ischaemia, less than in the control groups, this behaviour being similar to that observed in MDA levels (Fig. 3).

Telethermography

No significant differences were observed between telethermographic findings in the four groups in basal conditions. Telethermographic pictures of rats in groups 1, 2 and 3 showed a 20% increase of MII between days 1 and 7 ( $p < 0.05$ ), while rHuEpo-treated rats (group 4), in the same period, showed a reduction in MII, but not to a statistically significant extent (-1.5%) (Fig. 4).

Videocapillaroscopic examination

At T0, the vascular pattern of all rats showed the prevalence of ramified capillaries and almost no avascular areas, ectasic vessels or haemorrhagic phenomena. Capillaries were parallel to the cutaneous plans, forming a mainly polygonal network, with a fairly regular form and size. At the examination made at T1, in all control groups we observed avascular areas, ectasic vessels with oedema and perivascular haemorrhage and a marked reduction of capillary ramification. These alterations were more marked in the microscopic fields of the distal part of the skin flap. rHuEpo-treated rats had similar capillaroscopic features, but oedema in avascular areas and perivascular haemorrhages were less evident. On day 7, control rats presented moderate angiogenesis and an increase in

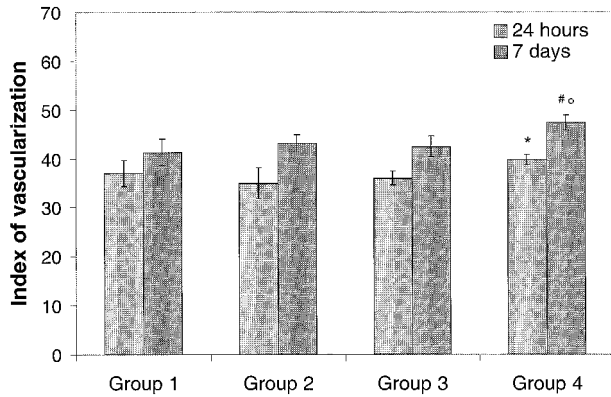


Fig. 5. Mean index of vascularization (videocapillaroscopy) of the flaps 24 h and 7 days after surgery. rHuEpo-treated rats show a significantly higher index of vascularization, in comparison with controls, 24 h and 7 days after surgery (\* $p < 0.05$  versus groups 1, 2 and 3 at 24 h; # $p < 0.05$  versus groups 1, 2 and 3 at 7 days; ° $p < 0.05$  versus group 4 at 24 h). For group explanations see Table I.

capillary ramifications also in the distal microscopic fields and in the flap peduncle; the percentages of avascular areas and ectasic vessels were higher than in group 4. rHuEpo treatment induced marked revascularization both in the area proximal to the peduncle and in the distal flap, and a great reduction of avascular areas, ectasic vessels and haemorrhages was observed.

Our findings were expressed and evaluated using the above-described scoring system. The mean score of skin vascularization was  $75 \pm 2.2$  before flap elevation. At T1, it was  $37 \pm 2.6$  in group 1,  $35 \pm 3.1$  in group 2 and  $36 \pm 1.38$  in group 3, while in group 4 it was  $39.8 \pm 1.0$ . At T7, the score was  $41.3 \pm 2.7$  for group 1,  $43.2 \pm 1.7$  for group 2 and  $42.5 \pm 2.1$  for group 3, while in group 4 rats it was  $47.4 \pm 1.5$  (Fig. 5).

The difference in the mean index of vascularization between treated and non-treated rats at T1 was within the range of statistical significance ( $p < 0.039$ ). Analysis of data also revealed a statistically significant increase of the mean index of vascularization in rHuEpo-treated rats between T1 and T7 ( $p < 0.05$ ). Moreover, a significant difference in the same index was found between untreated and rHuEpo-treated rats at T7 ( $p < 0.05$ ). The increase in non-treated rats between T1 and T7 was not statistically significant ( $p > 0.05$ ).

## DISCUSSION

The aim of the present study was to ascertain whether the administration of rHuEpo could play a role in early and late repair phenomena of ischaemic skin flap. Creation of the flap induced ischaemia, inflammation and granulation tissue formation, including angiogenesis (20). For the time evaluation of inflammatory and repair processes of the ischaemic flap we used telethermographic analysis and histological study of the ischaemic skin. In the three control groups (groups

1, 2 and 3), the increase in limb temperature was consistent with particularly active inflammatory events occurring in the skin, whereas no significant variations were found at any observation time in the temperature of the ischaemic area in rHuEpo-treated rats (group 4). Moreover, a significant number of inflammatory cells were found in control rats, in particular neutrophils mixed with fibroblasts in an oedematous tissue, whereas in group 4 a slight oedema and an early neutrophilic infiltration of the ischaemic tissue observed were constant during the different observation times.

In our experimental model, therefore, the hormone induced an earlier start of the inflammatory process, with a greater diapedesis of inflammatory cells, and a faster normalization in comparison with the controls. This was probably due to the direct activity of rHuEpo on skin vessels and to the faster modulation of the cell movements involved in the repair mechanisms through the activation of some adhesion molecules, as demonstrated elsewhere (21–23). Functional consequences can be readily understood when considering the wound healing a complex process in which there are modifications of the structures involved in the adhesion process, as a result of the action of inflammatory cytokines and growth factors released in this condition and of the changed conditions of extracellular matrix. Changes of adhesion and self-proliferation characteristics and a new pattern of the actin-cytoskeleton are events necessary to allow cellular migration and the subsequent reconstruction of the epidermal continuity. An earlier easing of inflammatory processes supports the recovery of these cells to a differentiating phenotype, allowing the normal cytomorphosis processes (4).

Furthermore, during the ischaemic phase, there is a condition in cutaneous flap that favours the formation of free radicals deriving from the oxygen through the activity of leukocytes and in particular of activated neutrophils (24). Oxygen radicals cause tissue reorganization, lipid peroxidation, destruction of intracellular matrix and alteration of important enzymes (25). These agents damage lipids both directly and by producing intermediate metabolites, leading to a cascade of lipid peroxidation (26).

To evaluate the variations of free radicals in ischaemic tissue, we assayed the levels of MPO and MDA. In our experimental model, the increase in tissue levels of MPO and MDA, in association with neutrophil accumulation, suggests a close correlation between ischaemic damage and inflammatory infiltrate.

rHuEpo modified the inflammatory response to ischaemic stress. In fact, in group 4, tissue levels of MPO and MDA were significantly reduced compared to controls, both in the initial inflammatory phase and 24 h after the beginning of ischaemic damage. This finding was confirmed by observation at optic microscopy at 1 and 24 h: neutrophilic infiltration was earlier

and faster in rHuEpo-treated rats than in control rats, but remained at low levels for the entire period of observation in the first case, showing instead a gradual increase to a much greater extent in other groups. Therefore, the administration of high doses of rHuEpo caused a reduction in the lipidic peroxidation between 1 and 24 h, when the inflammatory activity following the ischaemic damage reached its maximum. This suggests that rHuEpo has a protective role against free radicals, as demonstrated by Squadrito et al. (27).

Findings reported by Anagnostou et al. demonstrate the capacity of endothelial cells to express Epo receptors and to respond to this cytokine with an increase in cell proliferation and chemotaxis (9, 28). It has also been shown, in *in vitro* rat aorta ring assay, that rHuEpo stimulates endothelial cell sprouting (29). These findings have been interpreted as suggesting that Epo might be endowed with an angiogenic activity. However, the ability of rHuEpo to stimulate neovascularization *in vivo* was not assessed clearly.

Alterations of skin capillaries can be studied non-invasively through videocapillaroscopy, a method that allows *in vivo* observation, by an optic microscope, of the papillary derma capillaries (30).

In our experimental model, the revascularization process was evidenced on the 7th day after the onset of ischaemic stress. rHuEpo-treated rats presented an increased number of ramified capillaries and neoangiogenesis. At optic microscopy observation of the samples of granulation tissue, the capillaroscopic finding was confirmed: ischaemic skin of rats treated with rHuEpo showed an earlier formation of granulation tissue, and, in the late stage, a dense network of newly formed capillaries in a matrix of loose connective tissue. These observations, in agreement with increasing experimental evidence, suggest a role of Epo in vasoproliferative and neoangiogenic processes (direct interaction with endothelial cells) (15) and in wound healing (31).

In conclusion, our findings suggest that rHuEpo administration can improve the wound-healing process, in both early and late stages of injury, by reducing inflammatory response, increasing the capillary density in ischaemic flaps and allowing an earlier repair of the damaged area.

## REFERENCES

- Goodnough LT, Monk TG, Andriole GL. Erythropoietin therapy. *N Engl J Med* 1997; 336: 933–938.
- Amarguelat F, Gogusev J, Drueke TB. Direct effect of erythropoietin on rat vascular smooth-muscle cell via a putative erythropoietin receptor. *Nephrol Dial Transplant* 1996; 11: 687–692.
- Alvarez Arroyo MV, Castilla MA, FR Gonzales Pancheo, Tan D, Riesco A, Casado S, et al. Role of vascular endothelial growth factor on erythropoietin-related endothelial cell proliferation. *J Am Soc Nephrol* 1988; 9: 1998–2004.
- Vaccaro M, Magaudda L, Cutroneo G, Trimarchi F, Barbuza O, Guarneri F, et al. Changes in the distribution of laminin  $\alpha$  1 chain in psoriatic skin. Immunohistochemical study using confocal laser scanning microscopy. *Br J Dermatol* 2002; 146: 392–398.
- Haller H, Christel C, Dannenberg L, Thiele P, Lindschau C, Luft FC. Signal transduction of erythropoietin in endothelial cells. *Kidney Int* 1996; 50: 481–488.
- Maschio G. Erythropoietin and systemic hypertension. *Nephrol Dial Transplant* 1995; 10 Suppl 2: 74–79.
- Ren HY, Komatsu N, Shimizu R, Okada K, Miura Y. Erythropoietin induces tyrosine phosphorylation and activation of phospholipase C-gamma 1 in human erythropoietin in endothelial cell line. *J Biol Chem* 1994; 269: 19633–19638.
- Metcalf D. Peptide factors, haemopoietic growth factors. *Lancet* 1989; 1: 825–827.
- Anagnostou A, Liu Z, Steiner M, Chin K, Lee ES, Kessimian N, et al. Erythropoietin receptor mRNA expression in human endothelial cells. *Proc Natl Acad Sci USA* 1994; 91: 3974–3978.
- Choi K, Kennedy M, Kazarov A, Papadimitroum JC, Keller G. A common precursor for hematopoietic and endothelial cells. *Development* 1998; 125: 725–732.
- Cines DB, Pollak ES, Buck CA, Loscalzo J, Zimmermann GA, McEver RP, et al. Endothelial cells in physiology and pathophysiology of vascular disorders. *Blood* 1998; 91: 3527–3561.
- Dvorak HF, Brown LF, Detmar M, Dvorak AM. Vascular permeability factor/vascular endothelial growth factor microvascular hyperpermeability and angiogenesis. *Am J Pathol* 1995; 146: 1029–1039.
- Peters KJ, de Vries C, Williams LT. Vascular endothelial growth factor receptor expression during embryogenesis and tissue repair suggests a role in endothelial differentiation and blood vessel growth. *Proc Natl Acad Sci USA* 1993; 90: 8915–8919.
- Bjornsson TD, Dryjsk M, Tluczek J, Mennie R, Ronan J, Mellin TN, et al. Acidic fibroblast growth factor promotes vascular repair. *Proc Natl Acad Sci USA* 1991; 88: 8651–8655.
- Ribatti D, Presta M, Vacca A, Ria R, Giuliani R, Dell'Era P, et al. Human erythropoietin induces a pro-angiogenic phenotype in cultured endothelial cells and stimulates neovascularization *in vivo*. *Blood* 1999; 93: 2627–2636.
- Green CJ, Dhami L, Prasad, et al. The effect of desferrioxamine on lipid peroxidation and survival of ischemic island skin flaps in rats. *Br J Plast Surgery* 1989; 42: 565–569.
- Shin MS, Angel MF, Im MJ, Manson PN. Effect of 21-Aminosteroid U74389F on skin-flap survival after secondary ischemia. *Plast Reconstr Surg* 1994; 94: 661–666.
- Lowry OH, Rosebrough NJ, Farr A, Randall AR. Protein measurement with folin phenol reagent. *J Biol Chem* 1951; 193: 256–275.
- Tagesson C, Stendahl D, Magnusson KE, Edebo L. Disintegration of single cells in suspension. Isolation of rabbit polymorphonuclear leucocyte granules. *Acta Pathol Microbiol Immunol Scand* 1973; 81: 464–472.
- Bell E, Sher S, Hull B, Merrill C, Rosen S, Chamson A, et al. The reconstitution of living skin. *J Invest Dermatol* 1983; 81 Suppl: 2s–10s.
- Allegra A, Buemi M, Corica F, Aloisi C, Frisina N. Erythropoietin administration induces an increase of serum levels of soluble E-selectin and soluble intercellular adhesion molecule 1. *Nephron* 1999; 82: 361–362.
- Buemi M, Allegra A, Corica F, Cavallaro G, Aloisi C,

- Pettinato G, et al. Rapid and transient lymphocytopenia after i.v. administration of high doses of human recombinant erythropoietin. *Hematopathol Mol Hematol* 1987; 98: 13–17.
23. Buemi M, Denuzzo G, Allegra A, Aloisi C, Squadrito F, Squadrito G, et al. Recombinant human erythropoietin inhibits the cutaneous vasodilatation induced by acetylcholine. *Int J Microcirc Clin Exp* 1995; 15: 283–286.
  24. Angel MF, Ramasastry SS, Swartz WM, Narayanan K, Kuhns DB, Basford RE, et al. The critical relationship between free radicals and degrees of ischemia. Evidence for tissue intolerance of marginal perfusion. *Plast Reconstr Surg* 1988; 81: 233–239.
  25. White MJ, Heckler FR. Oxygen free radicals and wound healing. *Clin Plast Surg* 1990; 17: 473–484.
  26. Martin A. The use of antioxidants in healing. *Dermatol Surg* 1996; 22: 156–160.
  27. Squadrito F, Altavilla D, Squadrito G, Campo GM, Arlotta M, Quartarone C, et al. Recombinant human erythropoietin inhibits iNOS activity and reverts vascular dysfunction in splanchnic artery occlusion shock. *Br J Pharmacol* 1999; 127: 482–488.
  28. Anagnostou A, Lee ES, Kessimian N, Levinson R, Steiner M. Erythropoietin has a mitogenic and positive chemotactic effect on endothelial cells. *Proc Natl Acad Sci USA* 1990; 87: 5978–5982.
  29. Carlini RG, Reyes AA, Rothstein M. Recombinant human erythropoietin stimulates angiogenesis in vitro. *Kidney Int* 1995; 47: 740–745.
  30. Hashimoto H, Prewitt RL. Microvascular density changes during wound healing. *Int J Microcirc Clin Exp* 1987; 5: 303–310.
  31. Goldberg MA, Schneider TJ. Similarities between the oxygen-sensing mechanisms regulating the expression of vascular endothelial growth factor and erythropoietin. *J Biol Chem* 1994; 269: 4355–4359.

Copyright of Acta Dermato-Venereologica is the property of Taylor & Francis Ltd and its content may not be copied or emailed to multiple sites or posted to a listserv without the copyright holder's express written permission. However, users may print, download, or email articles for individual use.