

Original Article

The video endoscopy inguinal lymphadenectomy for vulvar cancer: A pilot study



Angelica Naldini ^{a,*}, Cristiano Rossitto ^a, Fabio Pacelli ^b, Giuseppe Vizzielli ^a,
Giuseppe Campagna ^a, Maria Cristina Moruzzi ^a, Giovanni Scambia ^a

^a Division of Gynecologic Oncology, Department of Women's and Children's Health, "Agostino Gemelli" Foundation University Hospital, Rome, Italy

^b Department of Oncology Unit, Catholic University of the Sacred Heart, Campobasso, Italy

ARTICLE INFO

Article history:

Accepted 24 January 2017

Keywords:

Vulvar cancer
Video endoscopy inguinal
lymphadenectomy
VEIL

ABSTRACT

Objective: This prospective pilot study aims to validate feasibility, efficacy and safeness of the innovative technique of video endoscopy inguinal lymphadenectomy (VEIL) and compare it to open inguinal lymphadenectomy (OIL) in the staging and treatment of vulvar cancer (VC).

Material and methods: All patients affected by VC suitable for bilateral inguinal-femoral lymphadenectomy were prospectively enrolled and submitted to VEIL on one side and OIL contralaterally, sparing the saphenous vein.

The surgical and post-surgical data were collected. Univariate analysis included chi square analysis or Fisher's exact test, when appropriate for categorical variables, and the Student t test and Mann–Whitney test when appropriate for continuous variables.

Results: Between October 2014 and June 2015 fifteen patients were valuable for the study. Although nodal retrieval was comparable for both procedures, operative time was higher after VEIL. No intra-operative complications were observed in both techniques. Postoperative complications were observed in 3 and 2 cases for OIL and VEIL respectively. One patient needed reoperation after OIL for wound necrosis and infection. According to Campisi's stage, lymphedema resulted significantly to be lower after VEIL ($p = 0.024$).

Conclusions: Waiting for larger series and longer follow-up data, the VEIL seems to be feasible allowing a radical removal of inguinal lymph nodes as well as OIL with lower morbidity.

© 2017 Taiwan Association of Obstetrics & Gynecology. Publishing services by Elsevier B.V. This is an open access article under the CC BY-NC-ND license (<http://creativecommons.org/licenses/by-nc-nd/4.0/>).

Introduction

Vulvar carcinoma (VC) is an uncommon cancer that has a bimodal age distribution and it is seen both in young and older women with risk factors including human papilloma virus (HPV) infection, smoking, and vulvar skin disease [1,2]. The surgical treatment for VC have greatly improved over the last three decades with more conservative surgery that carries decreased risk morbidity (e.g. leg lymphedema, disfigurement, sexual dysfunction). Surgical management of VC must be individualized and tailored to the extent of disease [3]. The efforts in optimizing care to the individual patient, have minimizing the physical, psychological

and sexual morbidity [3–7]. Groin lymphadenectomy is an integral part of the surgical management of invasive VC, and the evaluation of nodes still remain the most important prognostic factor [8,9]. However, groin lymphadenectomy can be omitted for early stage due to the negligible risk of node metastasis. More in depth for unifocal lesion <4 cm with no clinical or radiological evidence of node metastasis, the sentinel lymph node biopsy (SNB) is a valid and safe technique with negligible postoperative morbidity [10,11]. However, for all the other stages, unilateral or bilateral inguino-femoral lymphadenectomy is mandatory and, despite the care' improvements, post-operative wound dehiscence, lymphocele, lymphedema, infections and psychosexual impairment, are still early and long-term complicated [12]. To reduce the post-operative morbidity, some authors have described alternative surgical approach to inguinal lymph node dissection with unclear oncological outcomes. In this context an endoscopic procedure, with a small incision away from the dissecting area, seems to be a new and

*Corresponding author. Division of Gynecologic Oncology, Department of Women's and Children's Health, "Agostino Gemelli" Foundation University Hospital, L.go A. Gemelli, 1, 00168, Rome, Italy. Fax +39 0635506279.

E-mail address: naldini.angelica@gmail.com (A. Naldini).

attracting approach, duplicating the standard procedure with less morbidity and our group firstly described in the last year the video endoscopic inguinal lymphadenectomy for VC (VEIL) [13–18].

Here following a pilot study comparing perioperative outcome between open inguinal lymphadenectomy (OIL) and VEIL in patients with VC is described.

Materials and methods

The study was approved by the local ethics committee and patients involved in the study signed a written informed consent to participate before recruitment. This is a Single-Institutional pilot study aimed to evaluate the feasibility, complications and efficacy of video endoscopic inguinal lymphadenectomy (VEIL) comparing to standard open inguinal lymphadenectomy (OIL) in the staging and treatment of VC. All patients with VC suitable for bilateral inguinal-femoral lymphadenectomy were prospectively enrolled and submitted to VEIL on one pelvic side (*Cases*) and OIL contralaterally (*Controls*). Moreover, with the aim to render the surgical technique as homogeneous as possible, all the VEILs were performed on the left side.

Inclusion criteria were: 1) histological diagnosis of VC; 2) Age <90 years; 3) patients with VC with or without nodal involvement, suitable for bilateral inguinal-femoral lymphadenectomy; 4) performance Status ≤ 2 ; 5) written informed consent to participate before recruitment.

Exclusion criteria were: 1) Bulky nodes fixed to overlying skin; 2) patient submitted to pelvic lymphadenectomy for other gynecological cancer; 3) previous chemotherapy or radiotherapy; 4) concomitant hematologic or lymphatic disease; 5) patient suitable for bilateral sentinel lymph node biopsy; 6) cardiovascular, liver, renal, lung diseases.

We decided to perform the comparison of these two surgical approaches in the same patient to have identical clinical and body characteristics and consequently to minimize the influence of non-treatment factors.

All patients were submitted to ultrasound examination and/or TC and/or PET/TC as preoperative assessment. In case of bulky and/or suspicious inguinal-femoral lymph nodes, women were underwent to fine needle aspiration cytology (FNAC).

Moreover, if preoperative imaging did not report bilateral inguinal lymph-node metastases, a bilateral groin lymphadenectomy was performed when FNAC showed metastatic disease on inguinal nodes and/or when it did not fulfill all the criteria to perform a SNB (i.e. tumor diameter >4 cm, previous vulvar surgery, multifocal lesion, midline tumor in which the lymphoscintigraphy didn't identify the sentinel nodes).

Surgical technique

The same surgical team performed all surgical procedures. At the beginning of the operation, patients received a single shot antibiotic treatment. All patients underwent standard inguinal lymph node dissection, sparing the saphenous vein bilaterally. However, at one side it was performed endoscopic inguinal lymphadenectomy as previously published [18], whereas on the other side a standard inguinal lymphadenectomy surgery (OIL) was performed. In no cases it was performed a sentinel node biopsy.

For the *Controls* we used the standard technique for inguinal lymph node dissection [19]. On the other hand, for the *Cases* the endoscopic technique was described by Tobias-Machado et al. [15,20]. In detail the surgeon stood on the outside of operative limb and the assistant between the patient's legs. We practice the first 12 mm skin incision about 2 cm distal to the apex of femoral triangle. We proceeded with a finger dissection deep to the Scarpa's

fascia. Once enough space was created, we placed a 12 mm port with a pressure of 10 mmHg. Then two short bladeless trocars were placed 3 cm outside of boundaries of the femoral triangle, respectively.

After additional dissection, we proceeded with the development of the anterior space between the fibro fatty packet containing the lymph nodes and the subcutaneous fat. The main landmarks of dissection were medially the adductor longus muscle, laterally the sartorius muscle, superiorly the inguinal ligament and the inferior margin was the apex of the femoral triangle.

Saphenous vein along with the femoral vein and artery were visualized and spared after a care dissection. An exposure of the sapheno-femoral junction was practiced, as previously described by Ames, an infero-medial dissection around the femoral vein to obtain a complete deep inguino-femoral nodes resection [18]. All the surgical dissection was performed by using ultrasonic dissecting scalpel.

Postoperative care

All clinical, surgical and post-surgical data were recorded in an electronic database. During the postoperative course the patient was routinely examined. Criteria for discharging patients were as follows: no fever, no pelvic inflammation, no lymphedema (swelling of the lower extremities), and good clinical conditions. All patients received a daily dose of subcutaneous low-molecular weight heparin starting from the day after surgery and continuing at least for 4 weeks postoperatively.

The lower extremity lymphedema (LEL) was described according to Yamamoto and Campisi clinical classification [21,22]. The Yamamoto's index and the conventional Campisi's clinical stages [22] are both potentially useful in determining the severity of postoperative lymphedema thus assessing potentially differences between the two surgical approach [21].

Moreover, according to our protocol, a post-operative ultrasound (US) examination was performed beyond 6 weeks after the surgery by the same physician to evaluate inguinal lymph cyst or lymphedema at the follow-up.

Statistical analysis

Univariate analysis included chi square analysis or Fisher's exact test, when appropriate for categorical variables, and the Student t test and Mann–Whitney test when appropriate for continuous variables. All p values are considered significant if the p value < 0.05. The SPSS statistical software program (SPSS Inc., Chicago, IL) was used.

Results

Between October 2014 and June 2015 fifteen consecutive patients affected by VC suitable for bilateral inguino-femoral lymphadenectomy were enrolled. Patient's characteristic and histological features are summarized in Table 1, whereas the surgical-pathological details were showed in Table 2 Median age was 70.5 years (range, 63–86 years), and median body mass index (BMI) was 27.3 kg/m² (range, 22.2–35.1). Intra-operative time was significantly higher at VEIL with respect to OIL procedure (110 min vs. 45 min, respectively, p < 0.01), although a time-trend improvement was observed (Fig. 1).

The median number of lymph nodes removed was 10 (range, 3–17), with no statistically significant differences between the two "hemigroin". Eight women (54%) had positive lymph-nodes: among them four had bilateral metastases, whereas one and three patients had unilateral metastases detected by VEIL and OIL,

Table 1
Baseline patients' characteristics.

Variable	N (%)
All cases	15
Age (range)	70.5 (63–86)
BMI (kg/m ²) (range)	27.3 (22.2–35.1)
FIGO stage	
IA	5 (33.4)
IIA	2 (13.3)
IIIC	8 (53.3)
Diameter of tumor (mm) (range)	30 (7–60)
Histotype	
Squamous	14 (93.3)
Adenocarcinoma	1 (6.7)

respectively (Table 2). No intraoperative complication occurred and in no case we observed a lymph-nodal rupture during the VEIL. Moreover, no VEIL procedures have been converted and just one abdominal pneumoperitoneum due to an inguinal hernia was observed. More in depth it was resolved at the end of the procedure using a trans-umbilical Verres needle to remove the CO₂ from the abdomen. The median postoperative hospital stay was 3 days. The suction drains were removed after 12 (range, 8–18) days for OIL side, and 7 (range, 5–19) for VEIL side. Post operative complications were recorded in 3 and in 2 women in the *Control* and in the *Case* group, respectively (Table 3). In particular, in the OIL group, 1 patient needed reoperation for necrosis of the inguinal scare, which was treated by debridement and re-suture. No skin-related complications were seen in VEIL group. After 4 weeks, at the US examination, 4 lymphoceles (13.3%) were detected, two for each group. For these patients, radiologic percutaneous drainage under local anesthesia was required together with intravenous antibiotic therapy. Only one woman (OIL group) delayed the beginning of adjuvant radiotherapy because of lymphocele. The other patients were evaluated asymptomatic until to 4 months after surgery. No significant correlation was found between the size of the lymphocele and the incidence of symptoms. The 4 patients with asymptomatic lymphocele were clinically followed-up without any emerging complications for a median time of 10 months (range, 6–14 months). No cases of thrombosis or pulmonary emboli were detected. Moreover, we noted a less lymphedema in the VEIL side with respect to OIL side (Fig. 2) according to both Yamamoto and Campisi classification methods. However, the difference was statistically significant only according to Campisi's index (Fig. 2).

Table 2
Surgical-pathological details.

N	FIGO stage	Diameter of tumor (mm)	Site of tumor	LN ^a removed by VEIL (N)	Positive LN removed by VEIL (N)	Extracapsular nodal spread by site of VEIL (N)	LN removed by OIL (N)	OT (VEIL) (min)	Positive LN removed by OIL (N)	Extracapsular spread by site of OIL (N)	OT (OIL) (min)
#1	IIIC	38	Anterior	10	4	1	6	180	1	0	40
#2	IIIC	30	Lateral-left	13	5	1	12	145	1	0	30
#3	IA	15	Lateral-left	5	0	0	8	140	0	0	30
#4	IIIC	25	Lateral-left	10	0	0	5	120	1	1	40
#5	IIIC	50	Lateral-right	6	1	1	8	110	2	1	50
#6	IA	15	Lateral-right	3	0	0	2	120	0	0	20
#7	IIIC	60	Lateral-right	7	0	0	8	180	1	0	40
#8	IA	20	Lateral-right	8	0	0	10	100	0	0	45
#9	IA	7	Anterior	8	0	0	15	110	0	0	40
#10	IIIC	55	Anterior	10	0	0	10	110	3	1	45
#11	IIIC	15	Lateral-left	12	3	0	7	90	0	0	45
#12	IA	15	Lateral-left	6	0	0	10	100	0	0	60
#13	IIA	55	Anterior	11	0	0	10	90	0	0	60
#14	IIIC	60	Lateral-right	19	1	1	16	90	1	0	45
#15	IIA	60	Multifocal	13	0	0	17	130	0	0	60

^a LN = lymph nodes; VEIL = video endoscopy inguinal lymphadenectomy; OIL = open inguinal lymphadenectomy; OT = operating time.

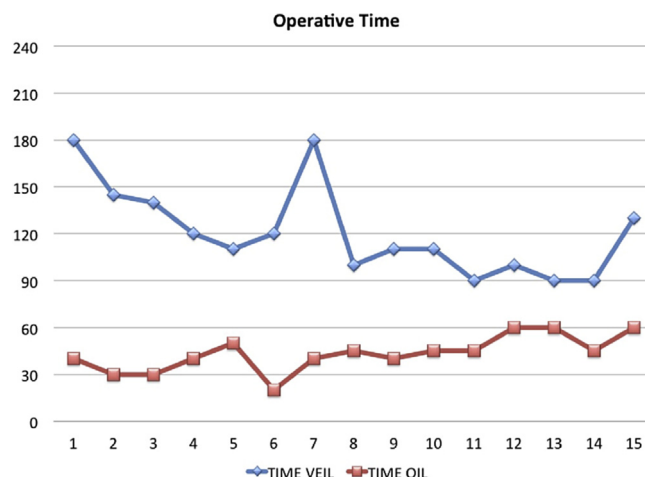


Fig. 1. Operative time learning curve.

Finally, at the present time with a median follow-up of 18 months, no recurrences were observed.

Discussion

Since the introduction in 1940 of the radical vulvectomy and bilateral inguinal lymphadenectomy through a butterfly incision, many modifications were made to the operative technique, aiming at the decrease the complications with no compromising the oncological outcome [5,19,23,24].

Modern approach of VC implies an individualized approach, with each patient requiring assessment of the most appropriate operation for the primary lesion and the regional lymph nodes [25].

To date, most results indicate that a full inguinofemoral lymphadenectomy should be considered the gold standard for clinically negative patients in whom SNB is not needed. But, despite some technical improvements, a crucial point of this surgery is that inguinofemoral lymphadenectomy leads to significant morbidity and to procedure related complications, including lymphedema and lymphocele (28–39%), wound infection (25–39%) and wound dehiscence (17–31%) [12,26,27].

As showed in other heterogeneous experiences [15–17, 20, 28–30], the VEIL technique has the aim to duplicate the standard radical procedure with less morbidity and this is the first pilot study

Table 3
Perioperative outcomes.

Variable	OIL N (%)	VEIL N (%)	p value
Operation time (min) (range)	45 (20–60)	110 (90–180)	0.001
Median number of lymph nodes (range)	10 (5–17)	10 (5–19)	0.861
Removal drainage (days) (range)	13 (8–18)	10 (5–13)	0.114
Complications	3 (20.0)	2 (13.3)	0.513
Reoperations	1 (6.7)	0	0.277
Lymphedema ^a			0.024
1	0	2 (13.3)	
2	0	4 (26.7)	
3	12 (80.0)	9 (60.0)	
4	3 (20.0)	0	
Lymphedema (median) (range) ^b	344 (248–356)	309 (239–356)	0.125

Bold characters are statistical significant ($p < 0.05$).

^a According to Campisi's Lymphedema clinical stage.

^b According to Yamamoto's classification.

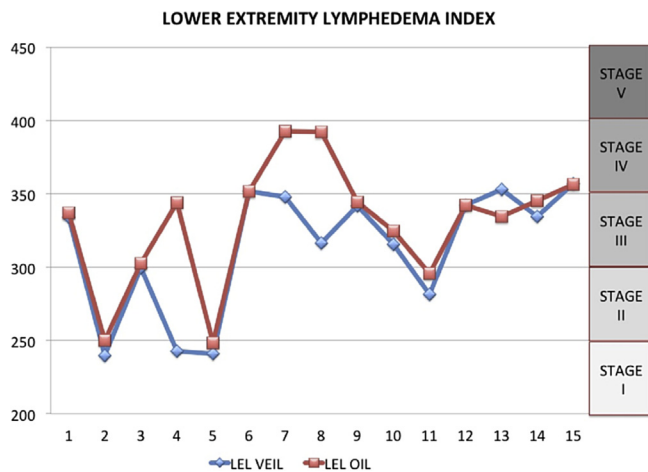


Fig. 2. Lower extremity lymphedema Index graph according to Yamamoto and Campisi classification. On the right side of the table Campisi stage is indicated.

on the safety and feasibility of this technique in a consecutive series of vulvar cancer.

Considering the number of retrieved nodes as a measure of how carefully the surgery has been performed, the recorded number of retrieved nodes after VEIL in our series is like the number of nodes after open traditional procedures. Moreover, since the VEIL is able to identify the same landmarks of the open surgery and to perform a dissection following the same template of the radical surgery, the quality of lymphadenectomy may be guaranteed [31]. Moreover, through the magnification of the image, the VEIL technique appears more easy to preserve the internal saphenous vein and its tributaries. However, if the VEIL seems feasible in patient with bulky nodes, it can be unsafe with nodes fixed to overlying skin or adjacent structures, maybe.

However, the favorable toxicity profile in terms of length of hospitalization and short-term complications should not be underestimated. In particular two major results of the VEIL technique have to be highlighted: first, the absence of skin complications in the VEIL leg, maybe due to the fact that the incisions are made out of the dissection area. Second, we noted a less early LEL. This could be explained, but not still validated, by the fact that the VEIL technique, preserves not only the internal saphenous vein, but also its tributaries. Indeed it cannot be neglected that the magnification of the anatomical structures leads to an easy identification

and preservation of the vessels and the endoscopic approach, which initially identifies the vein safena distal to the fossa ovalis, results the best way to preserve the safena's collaterals. This hypothesis is in line with the physiological concept that the integrity of the microcirculatory system and a well-perfused tissue products a best retrieval of the fluids in the extravascular system [32].

Then, the longer operative time in the VEIL side with respect to conventional technique is consistent with an initial endoscopic experience potentially improving with time (Fig. 1).

The weaknesses of our paper could lie in the small sample size and in a shorter follow-up to evaluate the oncological outcome, but well-matching with a pilot study of feasibility. However, since safety and oncologic adequacy must necessarily remain top priorities during surgical management of gynecologic cancers, further larger studies are needed to confirm and assess whether or not the preliminary technical difficulty of VEIL could justifies its routinely use vulvar oncology practice.

Conflicts of interest

The authors have no conflicts of interest relevant to this article.

References

- [1] Siegel R, Naishadham D, Jemal A. CA Cancer J Clin 2013 Jan;63(1):11–30.
- [2] Hampf M, Deckers-Figiel S, Hampf JA, Rein D, Bender HG. New aspects of vulvar cancer. Gynecol Oncol 2008 Jun;109(3):340–5.
- [3] Berek JS, Hacker NF. Berek and Hacker's Gynecology Oncology. 5th ed. Philadelphia: Lippincott Williams & Wilkins; 2009. p. 536–74.
- [4] Tantipalakorn C, Robertson G, Marsden DE, GebSKI V, Hacker NF. Outcome and patterns of recurrence for International Federation of Gynecology and Obstetrics (FIGO) stages I and II squamous cell vulvar cancer. Obstet Gynecol 2009 Apr;113(4):895–901.
- [5] De Hullu JA, Hollema H, Lolkema S, Boezen M, Boonstra H, Burger MP, et al. Vulvar carcinoma: the price of less radical surgery. Cancer 2002 Dec 1;95(11):2331–8.
- [6] Alkatout I, Schubert M, Garbrecht N, Weigel MT, Jonat W, Mundhenke C, et al. Vulvar Cancer: epidemiology, clinical presentation, and management options. Int J Womens Health 2015 Mar 20;7:305–13.
- [7] Covens A, Vella ET, Kennedy EB, Reade CJ, Jimenez W, Le T. Sentinel lymph node biopsy in vulvar cancer: Systematic review, meta-analysis and guideline recommendations. Gynecol Oncol 2015 May;137(2):351–61.
- [8] Woelber L, Kock L, Gieseck F, Petersen C, Trillsch F, Choschick M, et al. Clinical management of primary vulvar cancer. Eur J Cancer 2011 Oct;47(15):2315–21.
- [9] Hacker NF, Berek JS, Lagasse LD, Leuchter RS, Moore JG. Management of regional lymphnodes and their prognostic influence in vulvar cancer. Obstet Gynecol 1983 Apr;61(4):408–12.
- [10] Farias-Eisner R, Cirisano FD, Grouse D, Leuchter RS, Karian BY, Lagasse LD, et al. Conservative and individualized surgery for early squamous carcinoma of the vulva: the treatment of choice for stage I and II (T1–2, N0–1, M0) disease. Gynecol Oncol 1994 Apr;53(1):55–8.
- [11] Van der Zee AG, Oonk MH, De Hullu JA, Ansink AC, Vergote I, Verheijen RH, et al. Sentinel node dissection is safe in the treatment of early-stage vulvar cancer. J Clin Oncol 2008 Feb 20;26(6):884–9.
- [12] Farrell R, GebSKI V, Hacker NF. Quality of life after complete lymphadenectomy for vulvar cancer: do women prefer sentinel lymph node biopsy? Int J Gynecol Cancer 2014 May;24(4):813–9.
- [13] Tobias-Machado M, Starling ES, Oliveira ABP. 5-years experience with Video Endoscopy Inguinal Lymphadenectomy (VEIL): learning curve and technical variations of a new procedure. J Androl Sci 2009;16:25–32.
- [14] Ornellas AA, Correia Sexia AL, Marota A, Wisnesky A, Campos F, de Moraes JR. Surgical treatment of invasive squamous cell carcinoma of the penis: retrospective analysis of 350 cases. J Urol 1994 May;151(5):1244–9.
- [15] Tobias-Machado M, Tavares A, Molina Jr WR, Forseto Jr PH, Juliano RV, Wroclawski ER. Video endoscopic inguinal lymphadenectomy (VEIL): minimally invasive resection of inguinal lymphnodes. Int Braz J Urol 2006;32(3):316–21.
- [16] Tobias-Machado M, Tavares A, Silva MN, Molina Jr WR, Forseto PH, Juliano RV, et al. Can video endoscopic inguinal lymphadenectomy achieve a lower morbidity than open lymph node dissection in penile cancer patients? J Endourol 2008;22(8):1687–91.
- [17] Tobias-Machado M, Tavares A, Ornellas AA, Molina Jr WR, Juliano RV, Wroclawski ER. Video endoscopic inguinal lymphadenectomy: a new minimally invasive procedure for radical management of inguinal nodes in patients with penile squamous cell carcinoma. J Urol 2007;177:953–7.

- [18] Naldini A, Rossitto C, Morciano A, Panico G, Campagna G, Paparella P, et al. The first leg video endoscopic groin lymphadenectomy in vulvar cancer: a case report. *Int J Surg Case Rep* 2014;5(8):455–8.
- [19] Hacker NF, Leuchter RS, Berek JS, Castaldo TW, Lagasse LD. Radical vulvectomy and bilateral inguinal lymphadenectomy through separate groin incisions. *Obstet Gynecol* 1981;58(5):574–9.
- [20] Delman KA, Kooby DA, Rizzo M, Organ K, Master V. Initial experience with videoscopic inguinal lymphadenectomy. *Ann Surg Oncol* 2011;18(4):977–82.
- [21] Yamamoto T, Matsuda N, Todokoro T, Yoshimatsu H, Narushima M, Mihara M, et al. Lower extremity lymphedema index. A simple method for severity evaluation of lower extremity lymphedema. *Ann Plast Surg* 2011;67(6):637–40.
- [22] Campisi C, Boccardo F. Microsurgical technique for lymphedema treatment: derivative lymphatic-venous microsurgery. *World J Surg* 2004;28:609–13.
- [23] Ansink A, Van der Velden J. Surgical intervention for early squamous cell carcinoma of the vulva. *Cochrane Database Syst Rev* 2000;(2):CD002036.
- [24] Hacker NF, Van der Velden J. Conservative management of early vulvar cancer. *Cancer* 1993 Feb 15;71(4 Suppl):1673–7.
- [25] Hacker NF, Eifel PJ, Van der Velden J. Cancer of the vulva. *FIGO Cancer Report. Int J Gynaecol Obstet* 2015 Oct;131(Suppl 2):S76–83.
- [26] Spillane AJ, Saw RP, Tucker M, Byth K, Thompson JF. Defining lower limb lymphedema after inguinal or ilio-inguinal dissection in patients with melanoma using classification and regression tree analysis. *Ann Surg* 2008 Aug;248(2):286–93.
- [27] Wills A, Obermair A. A review of complications associated with the surgical treatment of vulvar cancer. *Gynecol Oncol* 2013 Nov;131(2):467–79.
- [28] Delman KA, Kooby DA, Ogan K, Hsiao W, Master V. Feasibility of a novel approach to inguinal lymphadenectomy: minimally invasive groin dissection for melanoma. *Ann Surg Oncol* 2010 Mar;17(3):731–7.
- [29] Master V, Ogan K, Kooby D, Hsiao W, Delman K. Leg endoscopic groin lymphadenectomy (LEG procedure): step-by-step approach to a straightforward technique. *Eur Urol* 2009 Nov;56(5):821–8.
- [30] Delman KA. Videoscopic Versus Open Inguinal Lymphadenectomy for cancer. <https://clinicaltrials.gov/ct2/show/NCT01526486>.
- [31] Guidelines NCCN, Melanoma. http://www.nccn.org/professionals/physician_gls_guidelines.asp#site.
- [32] Soliman AA, Heubner M, Kimming R, Wimberger P. Morbidity of inguinofemoral lymphadenectomy in vulvar cancer. *Sci World J* 2012;2012:341253.