

INVESTIGATIVE REPORT

Rat Bladder Epithelium: A Sensitive Substrate for Indirect Immunofluorescence of Bullous Pemphigoid

SERGIO DELMONTE, EMANUELE COZZANI, MASSIMO DROSER, AURORA PARODI and ALFREDO REBORA

DISEM, Section of Dermatology, University of Genoa, Genoa, Italy

Serological diagnosis of bullous pemphigoid is based on immunoblotting or indirect immunofluorescence on normal human salt-split skin. These methods are expensive or time-consuming and not available as a routine test in all laboratories. We used rat bladder epithelium as substrate for indirect immunofluorescence and compared it with other substrates and with immunoblotting. Twenty-nine bullous pemphigoid sera were studied on rat bladder epithelium, monkey oesophagus, salt-split skin and with immunoblotting on human keratinocyte cultures. Indirect immunofluorescence on rat bladder epithelium proved to be more sensitive (72%) than on monkey oesophagus alone (45%) and less sensitive than on salt-split skin (97%). Rat bladder epithelium, when tested on 41 sera of a control group, showed a very high specificity: 2/41 (95%). In combination with immunoblotting on keratinocyte extracts, indirect immunofluorescence on rat bladder epithelium allowed 93% of sera to be recognized, a value close to the salt-split skin alone. Rat bladder epithelium appears to be a more sensitive substrate than monkey oesophagus for the diagnosis of bullous pemphigoid and, although less specific, it is easier and faster than using salt-split skin, which remains indispensable to distinguish bullous pemphigoid from epidermolysis bullosa acquisita. **Key words:** bullous pemphigoid; indirect immunofluorescence; rat bladder epithelium; monkey oesophagus; immunoblotting.

(Accepted 17 February 2000.)

Acta Derm Venereol 2000; 80: 175–178.

Aurora Parodi, MD, Clinica Dermatologica dell'Università, Viale Benedetto XV, 7–16132, Genova, Italy. E-mail: rebdermo@unige.it

Clinical diagnosis of bullous pemphigoid is easy, but it needs to be confirmed by the observation of linear deposits of IgG and/or C3 at the basement membrane zone. Indirect immunofluorescence (IIF) on monkey oesophagus (ME) detects IgG anti-basement membrane zone antibodies in about 70% of patients (1, 2) and immunoblotting (IB) on extracts of human keratinocyte cultures is positive only in 69% of cases (3). The introduction of the normal human salt-split skin (SSS) as a substrate raised IIF sensitivity to 90% (4–6). SSS, however, is time-consuming, needing at least an additional 48 h for preparing the substrate.

Rat bladder epithelium (RBE) is an IIF substrate that has been used successfully for diagnosing paraneoplastic pemphigus, in which it reveals a characteristic staining of the intercellular substance (7). However, its capacity to reveal immune deposits at the basement membrane zone with bullous pemphigoid sera has not been directly studied. The available information comes from 3 studies of specificity of

RBE for paraneoplastic pemphigus; altogether 29 sera have been tested and only 2 were clearly reported to be positive for staining the basement membrane zone showing antibodies directed to the 230 kDa antigen (BP230) (8–10). We tested RBE substrate on 29 patients in order to verify its specificity and sensitivity in diagnosing bullous pemphigoid.

MATERIAL AND METHODS

Fourteen men and 15 women (age range 45–92 years; mean 75 years) who had their bullous pemphigoid diagnosed with direct immunofluorescence showing a linear band of IgG and/or C3 at the basement membrane zone were included in the study. They were clinically evaluated for the extent (more or less than 20% of the body surface) and the presence of mucosal involvement and urticarioid lesions.

Laboratory investigations included IIF on ME, RBE, SSS and IB on extracts of human keratinocyte cultures. All tests were done before initiating any treatment with the same samples. A single operator did the work using the same microscopic equipment.

IIF on RBE and ME was also performed on a control group of 41 subjects aged more than 65 years who were referred to our laboratory for antinuclear antibodies testing. None of them had a clinical diagnosis of bullous disease or any antinuclear antibodies.

The patients have been followed up for at least 2 years. The possible paraneoplastic nature of their disease was considered when cancer was concurrent or appeared within 1 year after the diagnosis of bullous pemphigoid. To this end, in addition to a thorough clinical examination and routine haematological tests, all patients were submitted to chest X-ray and abdominal ultrasonography. Occult blood in the stools, carcinoembryonic antigen and prostatic specific antigen were also looked for.

Direct immunofluorescence

Cryostat sections 6 µm thick from perilesional skin were incubated with fluorescein isothiocyanate (FITC)-labelled anti-human IgG, IgA, IgM, C3 goat serum. The reagents (Kallestad Diagnostics, Chaska MN, USA) had different concentrations: 1/55 for IgG; 1/16 for IgA; 1/22 for IgM; 1/35 for C3; 0.1 µg/ml for FITC. Incubation times were 30 min.

FITC alone was used as control. After washing with phosphate buffered saline (PBS), the slides were mounted in PBS-glycerin and examined under a fluorescence microscope, with epi-illumination.

SSS procedure

Normal human skin was obtained from mammoplasty. Epidermis was split from dermis according to the standard technique (4).

Indirect immunofluorescence (IIF)

Cryostat sections of RBE and SSS 6 µm thick were cut in our laboratory, while ME was obtained commercially from Bio-System. Serum dilutions ranged from 1:40 to 1:2560. The slides were washed

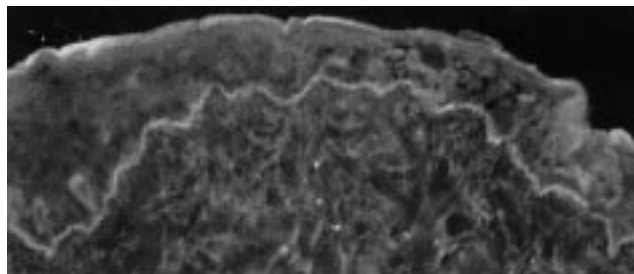


Fig. 1. Linear deposits of IgG at basal membrane zone. Substrate: rat bladder epithelium.

with PBS and incubated with diluted serum for 30 min. After a second PBS washing, the slides were covered with FITC-labelled anti-human IgG goat serum for 30 min. After a further PBS washing, they were mounted in PBS glycerin and examined.

The same FITC-IgG and the same reagents were used both for direct and indirect immunofluorescence.

Immunoblotting

Epidermal proteins were obtained from normal human keratinocyte cultures. The proteins were extracted directly from the culture flasks by incubation for 30 min at 4°C. The extraction buffer containing 10 mmol/l Tris-HCl, pH 7.8, 2% sodium dodecyl sulphate (SDS), 5% β-mercaptoethanol, 100 μmol/l ethylenediamine tetra-acetic acid (EDTA), 200 μmol/l phenylmethylsulphonyl fluoride (PMSF), 1 μmol/l leupeptin and 1 μmol/l pepstatin. After centrifugation at 13,000 g for 30 min, the supernatants were collected and the protein content of the homogenates was adjusted to 2 mg/ml using Bradford's method (11). Epidermal proteins were separated by 6% SDS-polyacrylamide slab gel electrophoresis under reducing conditions. The proteins were electrophoretically transferred to nitrocellulose filters. The efficiency of transblotting was checked by Ponceau antigen red staining of the transferred epidermal and standard proteins. Nitrocellulose strips were then sequentially incubated with: (i) Tris-buffered saline (TBS)/milk for 1 h at 37°C; (ii) 1:100 dilution of each sample serum in TBS/milk overnight at 4°C; (iii) 1:500 dilution of a biotinylated goat antihuman IgG (Amersham, Buckinghamshire, UK) in TBS/milk for 30 min at room temperature; and (iv) 1:3000 dilution of streptavidin-alkaline phosphatase complexes (Amersham) in TBS/milk for 30 min at room temperature. The strips were finally developed with alkaline phosphatase substrate solution diethanolamine buffer, NBT (nitrobluetetrazolium) BCIP (5-bromo-4-chloro-3-indolyl phosphate) (Sigma, St Louis, USA). Intervening washes were performed with TBS containing 0.1% Tween 20.

RESULTS

Most of the 29 patients had a widespread disease (24 cases) and urticarioid lesions (17 cases), while only in a small group were mucosae involved (6 cases). An internal malignancy was found in 6 patients (19%): 2 prostatic cancers, 2 colonic cancers, 1 pulmonary cancer and 1 Kaposi sarcoma.

Thirteen sera showed IIF positive results with ME as substrate, 21 with RBE (Fig. 1) and 28 with SSS. Eight sera were negative with both ME and RBE and all negative sera on RBE-IIF were also negative on ME-IIF. In addition, no RBE negative sera were positive on ME, while 7 negative sera on RBE were positive on SSS. Only one SSS-negative RBE-positive case was observed. RBE-IIF sensitivity was 72%, higher than ME-IIF (45%), but lower than SSS-IIF (97%) (Table I).

Two controls were RBE-IIF positive at a low titre (1/40). RBE-IIF specificity was 95.1% (2/41). None of the control sera were positive on ME-IIF. ME-IIF specificity was 100% (0/41). In addition, in sera that proved positive on both substrates, RBE titres were higher than ME ones, confirming the higher sensitivity of RBE.

IB was positive in 21 cases: 8 patients showed antibodies directed to BP230, 6 patients to BP180 and 7 to both antigens.

RBE-IIF positive patients exhibited urticarioid lesions more frequently than did RBE-IIF negative patients, while the latter were more frequent in patients with cancer. Patients with cancer had neither a more widespread skin disease nor a more frequent mucosal involvement than those without.

Four of the 8 RBE-IIF negative patients had an internal malignancy (Table II) and 5 of the 16 ME-IIF negative patients were in the same condition. By contrast, all of the 6 patients with cancer were SSS-IIF and IB positive (BP230 in 2 sera, BP180 in 3 sera and both antigens in 1 serum).

DISCUSSION

Since the introduction of the SSS substrate, IIF sensitivity in diagnosing bullous pemphigoid was raised to about 90%, which is much higher than the value (50–70%) obtained with ME and guinea pig oesophagus. Still, a significant number of negative sera remains.

As showed previously, RBE proved to express the antigens of bullous pemphigoid. In fact, in our study RBE proved to be much more sensitive a substrate than ME, with almost the same specificity. The combination of RBE-IIF and IB matches the diagnostic accuracy of SSS.

Although SSS-IIF is more sensitive and allows bullous pemphigoid to be distinguished from epidermolysis bullosa acquisita, RBE-IIF is much easier, faster and is available to all laboratories. On the other hand, ME-IIF is useful for the diagnosis of pemphigus, but in bullous pemphigoid, its sensitivity is lower than RBE-IIF. We believe that RBE-IIF should support ME and SSS in the presence of negative sera.

Whether or not bullous pemphigoid is associated with cancer is still a matter of discussion. Some clinical and laboratory criteria have been suggested to detect patients with bullous pemphigoid and cancer (12, 13), namely mucosal lesions, negative IIF and presence of antibodies to BP180 (14). We were unable to fully confirm such suggestions. Our patients with cancer did not differ from those without either for the extent of the disease or the frequency of the mucosal involvement. We found, instead, that a negative RBE-IIF associated with a positive SSS-IIF or IB may suggest the presence of cancer.

In addition, we failed to find any difference in the antigens of bullous pemphigoid disclosed in the patients with cancer. Our findings, therefore, disagree with other studies, which emphasize the relationship of BP180 with cancer (14) and poor prognosis (15).

Finally, RBE-IIF negative sera proved to contain antibodies directed to BP180 alone more frequently than to BP230 alone or in combination with BP180. There was no statistical difference between BP230 and BP180 ($p=0.2774$, Fisher's exact test), although there was a difference between BP 180 only and the combined group (BP230 and BP230+BP180) ($p=0.0307$, Fisher's exact test). However,

Table I. Results of indirect immunofluorescence on monkey oesophagus (ME), rat bladder epithelium (RBE), salt-split skin (SSS) and of immunoblotting on human keratinocyte cultures.

χ^2 test for ME vs. RBE vs. SSS: $p=0.00076$; Fisher's exact test for ME vs. RBE+SSS: $p=0.0032$; Fisher's exact test for RBE vs. SSS: $p=0.013$; Wilcoxon test for ME vs. RBE: $p<0.0001$). RBE- positive sera with BP180 are in **bold** type.

Patients sex/age	Indirect immunofluorescence dilution			Immunoblot antigens (kDa)
	ME	RBE	SSS	
M/84	–	–	160	230
F/70	–	–	320	180
M/60	40	80	40	230
F/83	–	–	40	230
F/79	–	40	40	180–230
F/66	–	80	40	–
M/67	160	320	160	180–230
M/65	–	40	80	230
M/74	–	80	–	–
M/81	–	40	320	180–230
M/59	40	160	80	–
M/76	40	640	160	230
F/69	–	80	40	180–230
F/79	40	80	160	180–230
M/74	160	640	320	230
F/62	640	1280	160	–
F/65	–	–	40	–
F/83	320	640	1280	180–230
M/86	–	–	2560	180
F/71	80	1280	320	230
M/83	1280	2560	320	180–230
F/90	160	640	40	180
F/92	40	1280	40	230
M/68	–	–	80	–
M/82	–	40	40	–
F/78	320	1280	40	–
F/45	–	40	40	180
M/89	–	–	40	180
F/84	–	–	160	180
<i>N</i> = 29	13 (45%)	21 (72%)	28 (97%)	21 (72%)

Table II. Correlation of cancer and immunopathological findings in bullous pemphigoid. (ME: monkey oesophagus, RBE: rat bladder epithelium)

Serology	Patients <i>n</i> (%)	
	with cancer	without cancer
RBE-IIF negative	4 (50)	4 (50)
ME-IIF negative	5 (31)	11 (69)
IB positive	6 (29)	15 (71)
RBE-IIF negative + IB positive	4 (67)	2 (33)
Total	6 (21)	23 (79)

IIF = indirect immunofluorescence; IB = immunoblotting.

we found 2 RBE-IIF positive sera which proved to contain BP180; this result is in contrast with Hashimoto's work in which transitional epithelia seem to express only BP230 (8).

ACKNOWLEDGEMENTS

We thank Mr A. Pastorino for his invaluable technical help.

REFERENCES

- Jordan RE, Beutner EH, Witebsky E, Blumental G, Hale WL, Lever WK. Basement membrane zone antibodies in bullous pemphigoid. *JAMA* 1967; 200: 751–756.
- Ahmed AR, Maize JC, Provost TT. Bullous pemphigoid: clinical and immunological follow-up after successful therapy. *Arch Dermatol* 1997; 113: 1043–1046.
- Ghohestani R, Kanitakis J, Nicolas JF, Cozzani E, Claudy A. Comparative sensitivity of indirect immunofluorescence to immunoblot assay for the detection of circulating antibodies to bullous pemphigoid antigens 1 and 2. *Br J Dermatol* 1996; 135: 74–79.
- Gammon WR, Briggaman RA, Inman AO, Queen LL, Wheeler CE. Differentiating anti lamina-lucida and anti-sublamina densa anti-BMZ antibodies by indirect immunofluorescence on 1.0 M sodium chloride-separated skin. *J Invest Dermatol* 1984; 82: 139–144.
- Kelly SE, Wojnarowska F. The use of chemically split tissue in the detection of circulating anti-basement membrane zone antibodies in bullous pemphigoid and cicatricial pemphigoid. *Br J Dermatol* 1988; 118: 31–40.
- Gammon WR, Fine JD, Forbes M, Briggaman RA. Immunofluorescence on split skin for the detection and differentiation of basement membrane zone autoantibodies. *J Am Acad Dermatol* 1992; 27: 79–87.

7. Anhalt GY, Kim SC, Stanley JR, Korman NJ, Jabs DA, Kory M, et al. Paraneoplastic pemphigus. *N Engl J Med* 1990; 323: 1729–1735.
8. Hashimoto T, Amagai M, Watanabe K, Chorzelski TP, Bhogal BS, Black MM, et al. Characterization of paraneoplastic pemphigus autoantigens by immunoblot analysis. *J Invest Dermatol* 1995; 104: 829–834.
9. Anhalt GJ, Aris-Abdo A, Bonitz P, Labib RS. Antigen specificity of paraneoplastic pemphigus: predictive value of diagnostic techniques based on the study of 17 patients and 135 control subjects. *J Invest Dermatol* 1992; 98: 580.
10. Liu AY, Valenzuela R, Helm TN, Camisa C, Melton AL, Bergfeld WF. Indirect immunofluorescence on rat bladder transitional epithelium: A test with high specificity for paraneoplastic pemphigus. *J Am Acad Dermatol* 1993; 28: 696–699.
11. Bradford M. Rapid and sensitive method for the quantification of microgram quantities of proteins utilizing the principle of protein dye binding. *Ann Biochem* 1976; 72: 248–254.
12. Venencie PY, Rogers RS, Shroeter AL. Bullous pemphigoid and malignancy: relationship to indirect immunofluorescent findings. *Acta Derm Venereol* 1984; 64: 316–319.
13. Hodge L, Marsden RA, Black MM, Bhogal B, Corbett MF. Bullous pemphigoid: the frequency of mucosal involvement and concurrent malignancy related to indirect immunofluorescence findings. *Br J Dermatol* 1981; 105: 65–69.
14. Muramatsu T, Iida T, Tada H, Hatoko M, Koyabashi N, Ko T, Shirai T. Bullous pemphigoid associated with internal malignancies: identification of 180-kDa antigen by Western immunoblotting. *Br J Dermatol* 1996; 135: 782–784.
15. Bernard P, Bedane C, Bonnetblanc JM. Anti-BP180 autoantibodies as a marker of poor prognosis in bullous pemphigoid: a cohort analysis of 94 elderly patients. *Br J Dermatol* 1997; 136: 694–698.

Copyright of Acta Dermato-Venereologica is the property of Society for Publication of Acta Dermato-Venereologica and its content may not be copied or emailed to multiple sites or posted to a listserv without the copyright holder's express written permission. However, users may print, download, or email articles for individual use.