

Erythema-directed digital photography for the enhanced evaluation of topical treatments for acne vulgaris

G. Micali  | F. Dall'Oglio | A. Tedeschi | F. Lacarrubba

Dermatology Clinic, University of Catania, Catania, Italy

Correspondence

Giuseppe Micali, Dermatology Clinic, University of Catania, Catania, Italy.
Email: cldermct@gmail.com

Funding information

Writing/editorial support was funded by Meda, a Mylan company

Abstract

Background: Erythema-directed digital photography is a novel method for evaluating the efficacy and tolerability of topical acne treatments. Here, we describe three case reports in which erythema-directed digital photography was used to evaluate acne before and after up to 12 weeks of treatment with clindamycin 1%/tretinoin 0.025% (Clin-RA).

Materials and methods: Erythema-directed digital photography was used to evaluate acne in three patients with mild-to-moderate facial acne, two of whom had refused to continue previous topical acne treatment (benzoyl peroxide 5% and clindamycin 1%/benzoyl peroxide 5%) due to persistent irritation. Acne lesions and erythema were evaluated using standard clinical photography and erythema-directed digital photography (VISIA-CR™ system) before and after 8-12 weeks of treatment with Clin-RA.

Results: Erythema-directed digital photography revealed background erythema from previous topical acne treatments that was not evident from standard clinical photographs and allowed a better visualization of both inflammatory and non-inflammatory lesions. In all patients, there was a clear improvement in background erythema and a reduction in acne lesions following treatment with Clin-RA.

Conclusion: This study has demonstrated for the first time that erythema-directed digital photography can enhance the evaluation of the efficacy and tolerability of topical acne treatments. These cases show that Clin-RA was associated with improved efficacy and tolerability vs previous treatments with topical monotherapy (benzoyl peroxide 5%) or a topical fixed-dose combination (clindamycin 1%/benzoyl peroxide 5%).

KEYWORDS

acne, clindamycin, erythema, fixed combination, tretinoin

1 | INTRODUCTION

Acne is a chronic inflammatory disease of the pilosebaceous unit which is most common during adolescence.^{1,2} A range of methods for clinically evaluating acne and the impact of topical treatments have been proposed, in particular lesion counting and global disease assessments.³ Clinical lesion counting can be subjective to individual assessors, only assesses what is visible to the naked eye and can

be challenging if the visible presentation is subtle.⁴ It can also be difficult to reliably identify minimal inflammatory lesions and to differentiate between papules and early pustules. Clinical assessments of acne treatments should also include the evaluation of local side effects such as erythema, which may occur in up to 70% of patients treated with topical retinoids.⁵ The occurrence of these side effects can have a detrimental impact on patients' adherence to their topical regimen, which is poor in about 50% of acne patients,⁶ and

may also affect future treatment choices. However, it can be difficult to accurately and objectively evaluate the presence and severity of erythema that may occur during treatment. Advanced digital photography techniques may be able to supplement simple clinical assessments of some dermatologic disorders including acne by allowing a more detailed and objective evaluation of the condition, as well as monitoring the effectiveness of therapy and its associated side effects over time.⁷⁻¹²

Clindamycin 1%/tretinoin 0.025% (Clin-RA) is a well tolerated and effective treatment for acne vulgaris, as shown in three 12-week pivotal clinical studies involving 4550 patients.¹³⁻¹⁵ This fixed-dose combination of a retinoid and an antibiotic was shown to be significantly more effective at reducing inflammatory, non-inflammatory and total acne lesions compared with its monotherapy and vehicle components. Local side effects such as erythema, burning, scaling, stinging and itching with Clin-RA were no greater than mild in intensity and comparable with the monotherapy and vehicle treatment groups. The favorable tolerability profile of Clin-RA is considered to be due to its patented, aqueous gel formulation, and the presence of both solubilized and crystalline tretinoin. The latter form of retinoid is slowly released on the skin surface allowing sustained cutaneous penetration.¹⁶ The tolerability profile of Clin-RA observed in clinical trials has also been confirmed in daily clinical practice. However, to date, a detailed examination of the tolerability of Clin-RA using novel imaging technology has not been performed.

The aim of the case reports presented here is to investigate for the first time how erythema-directed digital photography can be used to enhance the evaluation of topical acne treatments, using Clin-RA as an example of a well tolerated treatment for acne.

2 | MATERIALS AND METHODS

The three patients reported here were affected by mild-to-moderate facial acne vulgaris and were treated once-daily for 8-12 weeks with a topical gel containing Clin-RA. The patients' acne was evaluated before and after treatment using standard clinical photography and the VISIA-CR™ system (Canfield Scientific Inc., Fairfield, NJ, USA). The latter digital photography tool is equipped with technology to enable separation of the unique color signatures of red skin components (RBX™ technology). The erythema-directed imaging is able to highlight areas of redness corresponding to increased vascular flare or inflammation and has previously been used in the evaluation of other inflammatory dermatological conditions such as seborrheic dermatitis and rosacea.^{12,17} To our knowledge, this is the first use of erythema-directed digital photography to assess acne. The study was approved by the local Ethics Committee and was conducted in accordance with the principles of the Declaration of Helsinki.

3 | RESULTS

3.1 | Patient 1

Patient 1 was an 18-year-old female who had mild facial acne for 1 year. This patient had previously been treated with benzoyl peroxide 5% gel for 4 months, but refused to continue with this treatment due to a poor response and persistent irritation. Comparison of the standard clinical photograph (Figure 1A) with the erythema-directed digital image (Figure 1B) shows that the latter allows a better

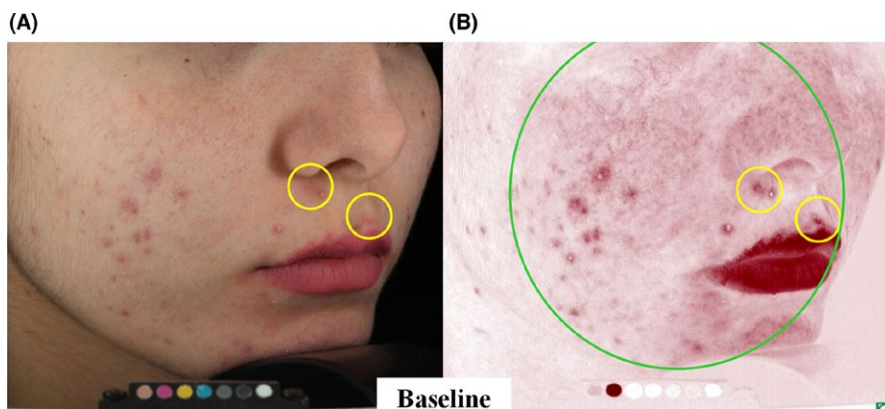


FIGURE 1 Patient 1: Standard clinical photography (A) and VISIA-CR™ digital photography imaging (B) at baseline. Erythema-directed photography by RBX™ using the VISIA-CR™ system enables a better assessment of minimal inflammatory lesions (yellow circles) and of the background erythema (green circle) following previous treatment with benzoyl peroxide 5% compared with standard photography

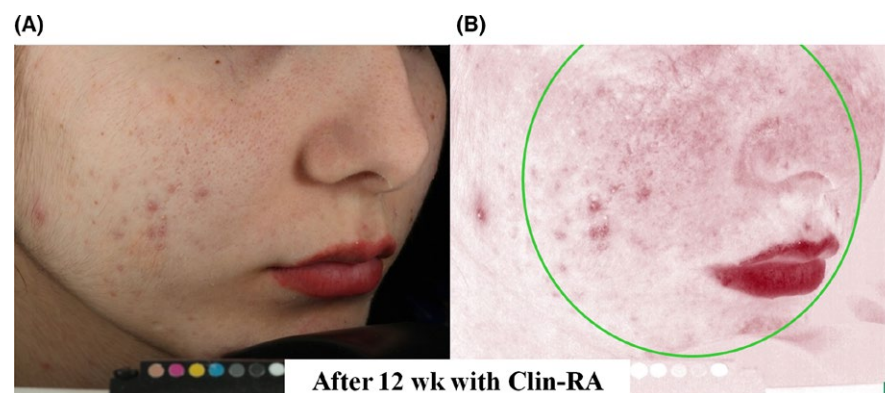
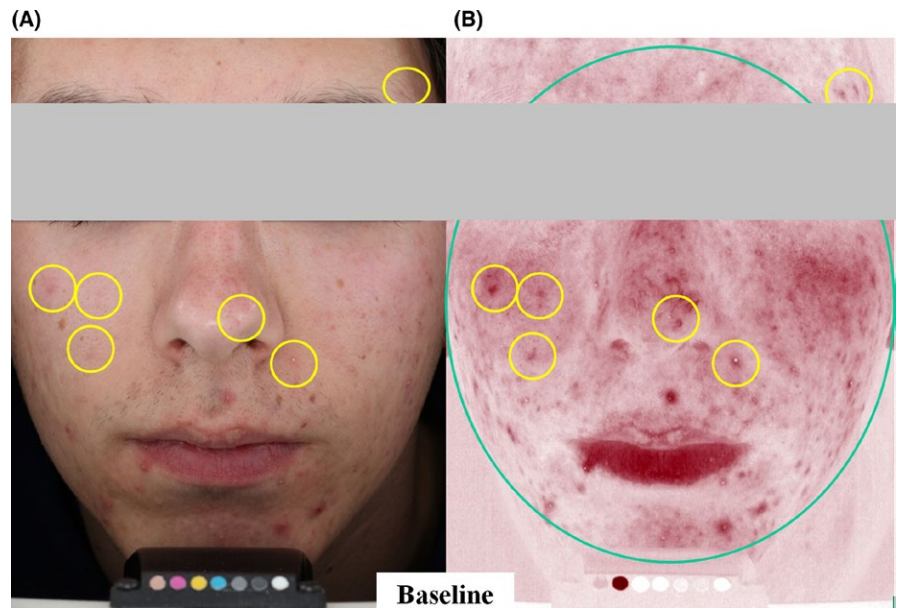


FIGURE 2 Patient 1: Clinical (A) and erythema-directed digital images (B) after 12 weeks of treatment with Clin-RA showing visible improvement of the inflammatory lesions as well as of the background erythema. Clin-RA, clindamycin 1%/tretinoin 0.025%

FIGURE 3 Patient 2: Standard clinical photography (A) and VISIA-CR™ digital photography imaging (B) at baseline. Erythema-directed photography by RBX™ using the VISIA-CR™ system enables a better assessment of minimal inflammatory lesions (yellow circles) and of the background erythema (green circle) following previous treatment with clindamycin 1%/benzoyl peroxide 5% compared with standard photography



visualization of the patient's inflammatory lesions, including minimal lesions. Background erythema from previous treatment with benzoyl peroxide 5% is also evident in the erythema-directed digital image. Clinical and erythema-directed photographs of the patient after 12 weeks of treatment with Clin-RA show that the majority of the baseline lesions were cleared with this topical fixed-dose combination (Figure 2A and B). Erythema-directed photography also shows that there was a clear improvement in the patient's background erythema following Clin-RA treatment (Figure 2B).

3.2 | Patient 2

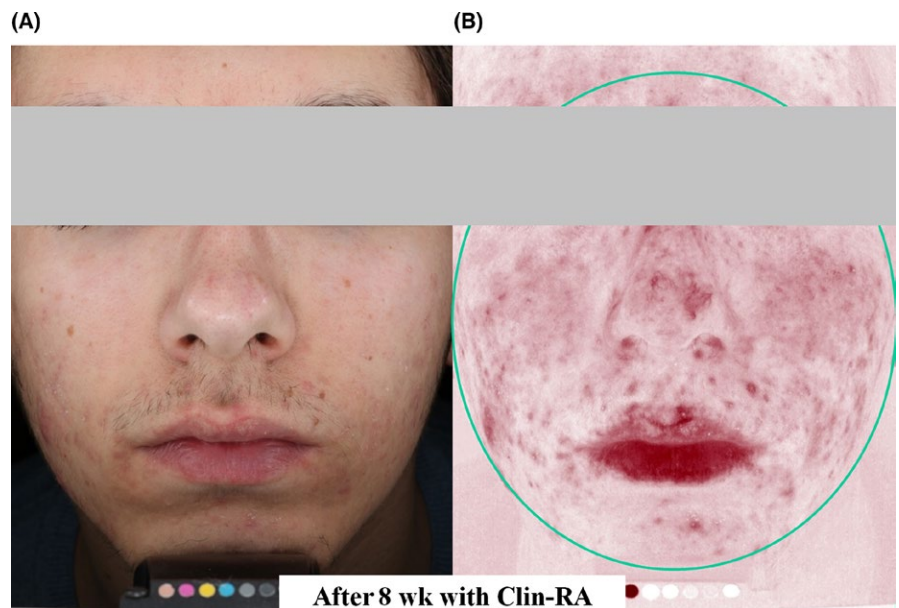
Patient 2 was a 17-year-old male who had moderate facial acne for 8 months. He had previously been treated with clindamycin 1%/benzoyl peroxide 5% for 2 months. However, the patient refused to

continue with this treatment due to persistent irritation. Clinical photographs show that the majority of this patient's acne lesions were rapidly cleared after 8 weeks of treatment with Clin-RA (Figures 3A and 4A). However, these improvements were better highlighted using erythema-directed digital photography (Figures 3B and 4B). This technique also revealed a marked reduction in the background erythema resulting from previous treatment with clindamycin 1%/benzoyl peroxide 5% after 8 weeks of treatment with Clin-RA.

3.3 | Patient 3

Patient 3 was a 22-year-old female who had untreated, mild facial acne for 6 months. Comparison of the standard clinical photograph (Figure 5A) with the erythema-directed digital image (Figure 5B) shows that the latter allows a better visualization of the patient's

FIGURE 4 Patient 2: Clinical (A) and erythema-directed digital images (B) after 8 weeks of treatment with Clin-RA showing visible improvement of the inflammatory lesions as well as of the background erythema. Clin-RA, clindamycin 1%/tretinoin 0.025%



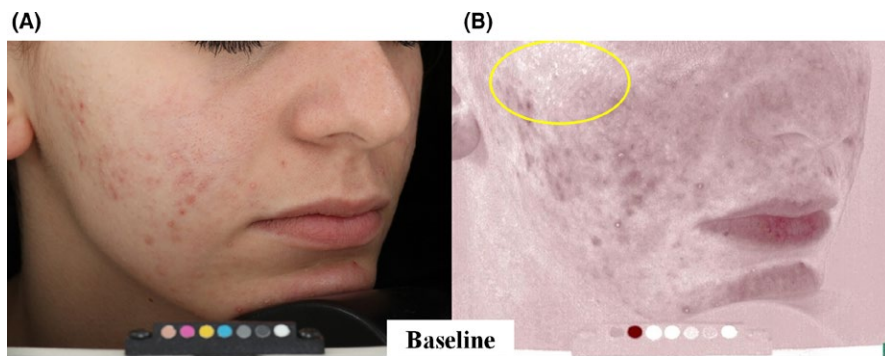


FIGURE 5 Patient 3: Standard clinical photography (A) and VISIA-CR™ digital photography imaging (B) at baseline. Erythema-directed photography by RBX™ using the VISIA-CR™ system enables a better assessment of closed comedones (yellow circle) compared with standard photography

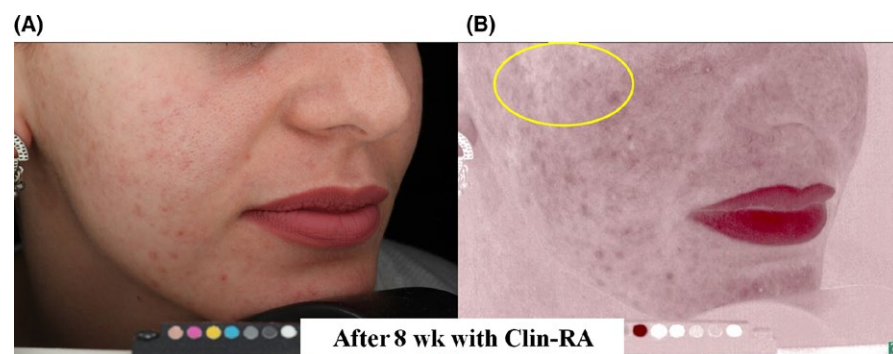


FIGURE 6 Patient 3: Clinical (A) and erythema-directed digital images (B) after 8 weeks of treatment with Clin-RA showing visible improvement of both inflammatory and non-inflammatory lesions. Clin-RA, clindamycin 1%/tretinoin 0.025%

non-inflammatory lesions, i.e. closed comedones, appearing as white spots. Clinical and erythema-directed photographs of the patient after 8 weeks of treatment with Clin-RA show a marked improvement of both inflammatory and non-inflammatory lesions (Figure 6A,B).

4 | DISCUSSION

The cases presented here show for the first time that erythema-directed digital photography can enhance the evaluation of the effects of topical treatments on acne. The technique allows a more accurate assessment of patients' acne lesions before and after treatment compared with clinical assessment alone. Before treatment, the images allow better identification of the extent of the patient's acne, including the inflammatory and non-inflammatory components, which is useful in guiding the patients on where they need to apply their topical therapy to optimize treatment outcomes. Erythema-directed digital photography also enables a patient's erythema to be more precisely evaluated than clinical inspection alone. The imaging technology allows clear differentiation of erythema related to active acne lesions and that resulting from previous treatments (background erythema). After treatment, the images allow an accurate evaluation of a treatment's clinical efficacy. Furthermore, the tolerability of treatment can be assessed by determining the changes in background erythema. The VISIA-CR™ system used in this study has previously been used to accurately and reproducibly auto-classify and count inflammatory and non-inflammatory acne lesions suggesting its potential future use in clinical research to

avoid the tedious and somewhat subjective process of manual lesion counting.⁷

The cases presented here also indicate the potential clinical benefits of Clin-RA, particularly in comparison with other topical therapies for the treatment of facial acne. Two patients refused to continue treatment with alternative topical therapies (benzoyl peroxide 5% and clindamycin 1%/benzoyl peroxide 5%) due to persistent irritation. The background erythema that these treatments caused is evident from the erythema-directed digital photography images. However, after switching to Clin-RA, both patients had a marked improvement in their acne, as well as an improvement in erythema. These cases confirm that Clin-RA is not an irritant and is well-tolerated by patients due to its unique formulation and combination of solubilized and crystalline tretinoin to slowly release the retinoid on the skin surface.¹⁶

The improved tolerability of Clin-RA compared with previous topical treatments is in agreement with the tolerability profile of Clin-RA which was reported in the three pivotal studies of this fixed combination.¹³⁻¹⁵ Furthermore, the results of a 3-week clinical study showed that Clin-RA was better tolerated than adapalene 0.1%/benzoyl peroxide 2.5% being associated with significantly less burning/stinging and itching ($P < .001$) as well as significantly lower trans-epidermal water loss, an objective measure of skin irritation ($P = .005$).¹⁸ In addition, a second 3-week study demonstrated that Clin-RA was better tolerated than tretinoin 0.1% microsphere gel, a retinoid which is considered to have good tolerability. In this study, the cumulative scores for erythema, scaling, burning, stinging, and pruritus were significantly greater with tretinoin 0.1% microsphere gel compared with Clin-RA ($P < .04$).¹⁹

Fixed-dose combinations that combine a retinoid with an antimicrobial agent are recommended for most acne patients by the Global Alliance to Improve Outcomes in Acne group as they are associated with faster and more effective lesion clearance than monotherapies.²⁰ Fixed combinations containing two antimicrobial agents are generally regarded as suboptimal as they do not contain a retinoid to target the microcomedone.

In conclusion, erythema-directed digital photography is a novel approach that may help to enhance and standardize the evaluation of both the efficacy and tolerability of topical acne treatments. The cases reported here also illustrate the clinical benefits of Clin-RA in patients unsuccessfully treated with other topical acne therapies in terms of clearing acne lesions and being associated with improved tolerability.

ACKNOWLEDGMENTS

Medical writing assistance in the preparation of this manuscript was provided by David Harrison (Medscrip Ltd) and Jane Murphy (CircleScience, an Ashfield Company, part of UDG Healthcare plc) and funded by Meda, a Mylan company.

CONFLICT OF INTEREST

None.

ORCID

G. Micali  <http://orcid.org/0000-0002-5157-3939>

REFERENCES

- Williams HC, Dellavalle RP, Garner S. Acne vulgaris. *Lancet*. 2012;379:361-372.
- Krakowski AC, Stendardo S, Eichenfield LF. Practical considerations in acne treatment and the clinical impact of topical combination therapy. *Pediatr Dermatol*. 2008;25(Suppl 1):1-14.
- Witkowski JA, Parish LC. The assessment of acne: an evaluation of grading and lesion counting in the measurement of acne. *Clin Dermatol*. 2004;22:394-397.
- Lucky AW, Barber BL, Girman CJ, Williams J, Ratterman J, Waldstreicher J. A multirater validation study to assess the reliability of acne lesion counting. *J Am Acad Dermatol*. 1996;35:559-565.
- Cunliffe WJ, Poncet M, Loesche C, Verschoore M. A comparison of the efficacy and tolerability of adapalene 0.1% gel versus tretinoin 0.025% gel in patients with acne vulgaris: a meta-analysis of five randomized trials. *Br J Dermatol*. 1998;139(Suppl 52):48-56.
- Dréno B, Thiboutot D, Gollnick H, et al. Global alliance to improve outcomes in acne. Large-scale worldwide observational study of adherence with acne therapy. *Int J Dermatol*. 2010;49:448-456.
- Patwardhan SV, Kaczvinsky JR, Joa JF, Canfield D. Auto-classification of acne lesions using multimodal imaging. *J Drugs Dermatol*. 2013;12:746-756.
- Goldsberry A, Hanke CW, Hanke KE. VISIA system: a possible tool in the cosmetic practice. *J Drugs Dermatol*. 2014;13:1312-1314.
- Xu DT, Yan JN, Cui Y, Liu W. Quantifying facial skin erythema more precisely by analyzing color channels of The VISIA Red images. *J Cosmet Laser Ther*. 2016;18:296-300.
- Dall'Oglio F, Tedeschi A, Fusto CM, Lacarrubba F, Dinotta F, Micali G. A novel cosmetic antifungal/anti-inflammatory topical gel for the treatment of mild to moderate seborrheic dermatitis of the face: an open-label trial utilizing clinical evaluation and erythema-directed digital photography. *G Ital Dermatol Venereol*. 2017;152:436-440.
- Micali G, Dall'Oglio F, Verzi AE, Luppino I, Bhatt K, Lacarrubba F. Treatment of erythemato-telangiectatic rosacea with brimonidine alone or combined with vascular laser based on preliminary instrumental evaluation of the vascular component. *Lasers Med Sci*. 2017. [Epub ahead of print]. <https://doi.org/10.1007/s10103-017-2318-3>.
- Micali G, Gerber PA, Lacarrubba F, Schäfer G. Improving treatment of erythematotelangiectatic rosacea with laser and/or topical therapy through enhanced discrimination of its clinical features. *J Clin Aesthet Dermatol*. 2016;9:30-39.
- Dréno B, Bettoli V, Ochsendorf F, et al. Efficacy and safety of clindamycin phosphate 1.2%/tretinoin 0.025% formulation for the treatment of acne vulgaris: pooled analysis of data from three randomised, double-blind, parallel-group, phase III studies. *Eur J Dermatol*. 2014;24:201-209.
- Schlessinger J, Menter A, Gold M, et al. ZIANA study group. Clinical safety and efficacy studies of a novel formulation combining 1.2% clindamycin phosphate and 0.025% tretinoin for the treatment of acne vulgaris. *J Drugs Dermatol*. 2007;6:607-615.
- Ochsendorf F. Clindamycin phosphate 1.2%/tretinoin 0.025%: a novel fixed-dose combination treatment for acne vulgaris. *J Eur Acad Dermatol Venereol*. 2015;29(Suppl 5):8-13.
- Del Rosso JQ, Jitraphai W, Bhambri S, Momin S. Clindamycin phosphate 1.2%- tretinoin 0.025% gel: vehicle characteristics, stability, and tolerability. *Cutis*. 2008;81:405-408.
- Dall'Oglio F, Tedeschi A, Guardabasso V, Micali G. Evaluation of a topical anti-inflammatory/antifungal combination cream in mild-to-moderate facial seborrheic dermatitis: an intra-subject controlled trial examining treated vs. untreated skin utilizing clinical features and erythema-directed digital photography. *J Clin Aesthet Dermatol*. 2015;8:33-38.
- Goshi R, Samrao A, Ehst BD. A double-blind, randomized, bilateral comparison of skin irritancy following application of the combination acne products clindamycin/tretinoin and benzoyl peroxide/adapalene. *J Drugs Dermatol*. 2012;11:1422-1426.
- Leyden J, Wortzman M, Baldwin EK. Tolerability of clindamycin/tretinoin gel vs. tretinoin microsphere gel and adapalene gel. *J Drugs Dermatol*. 2009;8:383-388.
- Thiboutot D, Gollnick H, Bettoli V, et al. New insights into the management of acne: an update from the global alliance to improve outcomes in acne group. *J Am Acad Dermatol*. 2009;60(5 Suppl): S1-S50.

How to cite this article: Micali G, Dall'Oglio F, Tedeschi A, Lacarrubba F. Erythema-directed digital photography for the enhanced evaluation of topical treatments for acne vulgaris. *Skin Res Technol*. 2018;00:1-5. <https://doi.org/10.1111/srt.12448>