


HER2 status in premalignant dysplastic gastric lesions

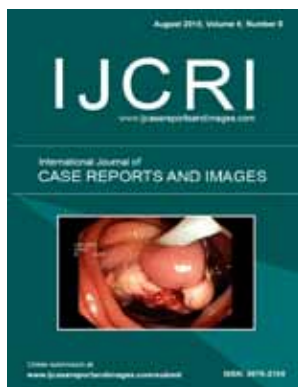
Valeria Barresi, Antonio Ieni, Giovanni Tuccari

ABSTRACT

Abstract is not required for Editorial

 All Articles Open Access

International Journal of Case Reports and Images (IJCRI)



International Journal of Case Reports and Images (IJCRI) is an international, peer reviewed, monthly, open access, online journal, publishing high-quality, articles in all areas of basic medical sciences and clinical specialties.

Aim of IJCRI is to encourage the publication of new information by providing a platform for reporting of unique, unusual and rare cases which enhance understanding of disease process, its diagnosis, management and clinico-pathologic correlations.

IJCRI publishes Review Articles, Case Series, Case Reports, Case in Images, Clinical Images and Letters to Editor.

Website: www.ijcasereportsandimages.com

HER2 status in premalignant dysplastic gastric lesions

Valeria Barresi, Antonio Ieni, Giovanni Tuccari

The epidermal growth factor receptor family is constituted by four members with similar structures: HER1/erbB1, HER2/erbB2, HER3/erbB3 and HER4/erbB4. These receptors play an important role in the processes of proliferation and differentiation of normal cells [1]. The binding of the ligand to these receptors causes the creation of homodimers and heterodimers as well as the activation of downstream signaling pathways [1]. Hence, any aberrations in their structure or function can cause transformation of normal cells to malignant cells with consequent tumor development and progression [1]. However, on the basis of results from an international randomized controlled trial (ToGA), the patients with advanced gastric adenocarcinoma (GC) positive for HER2 over-expression could be eligible for a target treatment with trastuzumab [2]. A significant reduction in the risk of mortality was appreciable when trastuzumab was added to the chemotherapy regimen [2]. There is general agreement with regard to a higher HER2 positivity in gastroesophageal junction cancer (24–35%) compared with GC (9.5–21%) [3]. The rate of HER2 immunoreactivity seemed to be vary variable in relation to the different neoplastic histotype of the stomach [4]. Generally, all studies have reported a prevalence of HER2 amplification in advanced GC of

intestinal type (81.6–91%) in comparison with diffuse or mixed ones (4–7.9%) [4]. In addition, a progressive increase in HER2 overexpression has been appreciated moving from the poorly cohesive WHO histotype to mitochondrion-rich adenocarcinomas (MRC), tubular adenocarcinomas and hepatoid carcinomas (HAS), these latter representing the top rate of HER2 positivity, characterized by an extremely poor prognosis [4]. Furthermore, HER2 overexpression was also significantly associated with a high grade, advanced stage and high Ki67-LI value, becoming thus an additional morphological parameter able to affect the mortality of patients with GC [5]. Finally, some investigations have been recently reported regarding the concordance of HER status in primary gastric cancer and corresponding lymph nodes or distant metastases, with either positive or negative conversion in HER2 overexpression [6, 7].

Generally speaking, chronic atrophic gastritis and intestinal metaplasia of the stomach have been regarded to as pre-neoplastic lesions, even if data from literature points towards the existence of other pathways, in which intestinal metaplasia may not play a role, as described by Japanese authors [8]. However, the true precancerous gastric lesion should be considered dysplasia, which includes cellular and structural atypia, also codified under the term intraepithelial neoplasia (IEN), a pathological condition that lies between atrophic gastritis and GC [9]. It is well known, that IEN may develop in the gastric or intestinal metaplastic epithelium and it can be categorized into four categories: indefinite for intraepithelial neoplasia, low-grade intraepithelial neoplasia (LG-IEN), high-grade intraepithelial neoplasia (HG-IEN) and suspicious for invasive cancer [10]. The IEN histological distinction as low or high-grade depends on the severity of architectural and cytological atypia. In LG-IEN, the mucosal structure is only faintly modified maintaining tubular differentiation with the proliferative zone limited to the outward portion, whereas HG-IEN exhibits increasing distortion of the mucosal architecture, resulting in crowded possibly irregular glands with obvious cellular atypia and proliferative activity distributed throughout the lesion [10]. High-grade intraepithelial neoplasia is

Valeria Barresi¹, Antonio Ieni¹, Giovanni Tuccari¹

Affiliations: ¹Azienda Ospedaliera Universitaria “Gaetano Martino” and Department of Human Pathology “Gaetano Barresi”, Section of Anatomic Pathology, University of Messina, Messina 98123, Italy.

Corresponding Author: Giovanni Tuccari, MD, Full Professor of Pathology Department of Human Pathology, “Gaetano Barresi” University of Messina, A.O.U. “Policlinico G. Martino” - Pad. D, Via Consolare Valeria, 98125 – MESSINA (Italy); Ph: +39-90-2212539; Fax:+39-90-2928150 E-mail: tuccari@unime.it

Received: 16 June 2015

Published: 01 August 2015

associated with a higher risk of developing GC [10]. It has been described, that the genomic copy number aberration of gastric precancerous lesions and carcinoma *in situ* (CIS) have provided the most prominent 8q gain, which was detected most frequently in both HG-IEN and CIS, but was undetected in LG-IEN using array comparative genomic hybridization [11]. Previous studies with HGIN and LGIN were mostly based on several known genes [11], such as p53, HER2 and E-cadherin [12].

Only few studies have described the overexpression of HER2 in gastric dysplastic lesions [13]. In a series of gastrectomies and gastric biopsies, there was a 12.6% of HER2 positivity in HG-IEN, while 2+/3+ reactivity was not seen in benign mucosa, even if some cases have showed a weak membranous reaction in foveolar gland elements and also a cytoplasmic staining in specialized glands [13]. Interestingly, a series of intriguing cases with a discordant HER2 status between dysplastic lesions and invasive carcinomas has been reported [13]. In detail, three cases showed a HER2 positivity limited only to dysplastic epithelium despite the invasive component; conversely in four cases, HER2 expression was encountered only in invasive areas and finally six cases showed a concordant 3+ HER2 reactivity, either in dysplastic or in equivalent invasive part [13]. In addition, a questionable percentage of HER2 positivity should be related to characteristics of biological samples, since bioptic specimens could overestimate as false positive for HER2 the dysplastic epithelium, being misinterpreted as invasive carcinoma [13].

More recently, HER2 overexpression was observed in gastric LG-IEN and HG-IEN, with a significant increase from LG-IEN to HG-IEN. There was a HER2 positivity of 4–8% in LG-IEN and 16–20% in HG-IEN [14]. These results suggest that HER2 may be a part of early stage of gastric carcinogenesis, although the heterogeneity of HER2 status documented in IEN supports that the molecular dysregulation may only affect a subset of the intraepithelial neoplastic cell populations [14]. Similar results have been noted in high-grade dysplastic lesions, suggesting a potential rate of HER2 in early neoplastic transformation of gastric mucosa [14]. Study showed of a score 2+ or 3+ staining in 12/63 (19%) high-grade dysplastic samples and in 7/75 (9%) low-grade dysplastic samples has been elsewhere, reported [15], although the a validation by FISH procedure should be performed in equivocal 2+ cases. However, by using an histomorphological profile, dysplasia has been also classified in adenomatous/type I (intestinal phenotype) and foveolar or pyloric/type II (gastric phenotype) [16]. This distinction was mainly based by an immunohistochemical analysis. The intestinal/adenomatous type was immunopositive for CD10 and CDX2, while the gastric/foveolar type was characterized by a negative CD10 staining and MUC5AC, MUC6 reactivity [17]. Moreover, cases with hybrid differentiation may also occur as well as null cases in which there is no expression of the aforementioned markers [17]. HER2

amplification was observed in cases immunophenotyped as gastric or hybrid, suggesting that this type of dysplasia may be an important player in gastric carcinogenesis. [17]. Therefore, we retain that an extensive investigation of HER2 status in gastric morphological dysplasia may help to identify patients at high risk of developing a certain cancer, even if the relationship between HER2 overexpression and progression of dysplasia towards GC probably requires further investigations.

It is well known that HER2 gene amplification can be acquired during progression of the neoplastic disease or recurrence, either in patients affected by breast or gastric carcinomas [6, 7]. Indeed, precancerous lesions are constituted by cells with different pathological conditions, which are continuously dividing and acquiring genetic instability; therefore, some different cellular clones may coexist showing a HER2 status, able to be subjected to the possibility of its change into overt carcinomas, either with a positive or negative conversion in comparison to that exhibited in dysplastic elements. Consequently, although at present the determination of HER in pre-neoplastic gastric morphological lesions is not still mandatory, it can be argued that the determination of HER2 status - also in short series or in case reports - could be performed as it may influence the therapeutic treatment and affect the prognosis, furnishing in the meantime additional information to the eligibility for trastuzumab treatment [18].

How to cite this article

Barresi V, Ieni A, Tuccari G. HER2 status in premalignant dysplastic gastric lesions. Int J Case Rep Images 2015;6(8):530–533.

doi:10.5348/ijcri-201504-ED-10004

Author Contributions

Valeria Barresi – Substantial contributions to conception and design, Acquisition of data, Analysis and interpretation of data, Drafting the article, Revising it critically for important intellectual content, Final approval of the version to be published

Antonio Ieni – Analysis and interpretation of data, Revising it critically for important intellectual content, Final approval of the version to be published

Giovanni Tuccari – Analysis and interpretation of data, Revising it critically for important intellectual content, Final approval of the version to be published

Guarantor

The corresponding author is the guarantor of submission.

Conflict of Interest

Authors declare no conflict of interest.

Copyright

© 2015 Valeria Barresi et al. This article is distributed under the terms of Creative Commons Attribution License which permits unrestricted use, distribution and reproduction in any medium provided the original author(s) and original publisher are properly credited. Please see the copyright policy on the journal website for more information.

REFERENCES

1. Czyzewska J, Guzinska-Ustymowicz K, Kemon A. Correlation of c-erbB-2, EGF and EGFR expression with postoperative survival of patients with advanced carcinoma of the stomach. *Folia Histochem Cytobiol* 2009;47(4):653–61.
2. Ieni A, Barresi V, Giuffrè G, et al. HER2 status in advanced gastric carcinoma: A retrospective multicentric analysis from Sicily. *Oncol Lett* 2013 Dec;6(6):1591–94.
3. Bang YJ, Van Cutsem E, Feyereislova A, et al. Trastuzumab in combination with chemotherapy versus chemotherapy alone for treatment of HER2-positive advanced gastric or gastro-oesophageal junction cancer (ToGA): a phase 3, open-label, randomised controlled trial. *Lancet* 2010 Aug 28;376(9742):687–97.
4. Giuffrè G, Ieni A, Barresi V, Caruso RA, Tuccari G. HER2 status in unusual histological variants of gastric adenocarcinomas. *J Clin Pathol* 2012 Mar;65(3):237–41.
5. Rüschhoff J, Hanna W, Bilous M, et al. HER2 testing in gastric cancer: a practical approach. *Mod Pathol* 2012 May;25(5):637–50.
6. Kochi M, Fujii M, Masuda S, et al. Differing deregulation of HER2 in primary gastric cancer and synchronous related metastatic lymph nodes. *Diagn Pathol* 2013 Nov 21;8:191.
7. Ieni A, Barresi V, Caltabiano R, et al. Discordance rate of HER2 status in primary breast carcinomas versus synchronous axillary lymph node metastases: a multicenter retrospective investigation. *Onco Targets Ther* 2014 Jul 11;7:1267–72.
8. Nishimura R, Mukaisho K, Yamamoto H, et al. Precursor-derived versus de-novo carcinogenesis depends on lineage-specific mucin phenotypes of intramucosal gland-forming gastric neoplasms. *Histopathology* 2013 Nov;63(5):616–29.
9. Kushima R, Vieth M, Borchard F, Stolte M, Mukaisho K, Hattori T. Gastric-type well-differentiated adenocarcinoma and pyloric gland adenoma of the stomach. *Gastric Cancer* 2006;9(3):177–84.
10. Ruge M, Correa P, Dixon MF, et al. Gastric dysplasia: the Padova international classification. *Am J Surg Pathol* 2000 Feb;24(2):167–76.
11. Correa P, Piazuelo MB, Wilson KT. Pathology of gastric intestinal metaplasia: clinical implications. *Am J Gastroenterol* 2010 Mar;105(3):493–8.
12. Lin LL, Huang HC, Juan HF. Discovery of biomarkers for gastric cancer: a proteomics approach. *J Proteomics* 2012 Jun 18;75(11):3081–97.
13. Hu Y, Bandla S, Godfrey TE, et al. HER2 amplification, overexpression and score criteria in esophageal adenocarcinoma. *Mod Pathol* 2011 Jul;24(7):899–907.
14. Fusco N, Rocco EG, Del Conte C, et al. HER2 in gastric cancer: a digital image analysis in pre-neoplastic, primary and metastatic lesions. *Mod Pathol* 2013 Jun;26(6):816–24.
15. Lodato RF, Maguire HC Jr, Greene MI, Weiner DB, LiVolsi VA. Immunohistochemical evaluation of c-erbB-2 oncogene expression in ductal carcinoma in situ and atypical ductal hyperplasia of the breast. *Mod Pathol* 1990 Jul;3(4):449–54.
16. Lee S, de Boer WB, Fermoye S, Platten M, Kumarasinghe MP. Human epidermal growth factor receptor 2 testing in gastric carcinoma: issues related to heterogeneity in biopsies and resections. *Histopathology* 2011 Nov;59(5):832–40.
17. Valente P, Garrido M, Gullo I, Baldaia H, et al. Epithelial dysplasia of the stomach with gastric immunophenotype shows features of biological aggressiveness. *Gastric Cancer* 2014 Aug 22.
18. Ieni A, Barresi V, Caltabiano R, et al. Discordance rate of HER2 status in primary breast carcinomas versus synchronous axillary lymph node metastases: a multicenter retrospective investigation. *Onco Targets Ther* 2014 Jul 11;7:1267–72.

Access full text article on
other devices



Access PDF of article on
other devices



Edorium Journals: An introduction

Edorium Journals Team

About Edorium Journals

Edorium Journals is a publisher of high-quality, open access, international scholarly journals covering subjects in basic sciences and clinical specialties and subspecialties.

Invitation for article submission

We sincerely invite you to submit your valuable research for publication to Edorium Journals.

But why should you publish with Edorium Journals?

In less than 10 words - we give you what no one does.

Vision of being the best

We have the vision of making our journals the best and the most authoritative journals in their respective specialties. We are working towards this goal every day of every week of every month of every year.

Exceptional services

We care for you, your work and your time. Our efficient, personalized and courteous services are a testimony to this.

Editorial Review

All manuscripts submitted to Edorium Journals undergo pre-processing review, first editorial review, peer review, second editorial review and finally third editorial review.

Peer Review

All manuscripts submitted to Edorium Journals undergo anonymous, double-blind, external peer review.

Early View version

Early View version of your manuscript will be published in the journal within 72 hours of final acceptance.

Manuscript status

From submission to publication of your article you will get regular updates (minimum six times) about status of your manuscripts directly in your email.

Our Commitment

Six weeks

You will get first decision on your manuscript within six weeks (42 days) of submission. If we fail to honor this by even one day, we will publish your manuscript free of charge.

Four weeks

After we receive page proofs, your manuscript will be published in the journal within four weeks (31 days). If we fail to honor this by even one day, we will publish your manuscript free of charge and refund you the full article publication charges you paid for your manuscript.

Most Favored Author program

Join this program and publish any number of articles free of charge for one to five years.

Favored Author program

One email is all it takes to become our favored author. You will not only get fee waivers but also get information and insights about scholarly publishing.

Institutional Membership program

Join our Institutional Memberships program and help scholars from your institute make their research accessible to all and save thousands of dollars in fees make their research accessible to all.

Our presence

We have some of the best designed publication formats. Our websites are very user friendly and enable you to do your work very easily with no hassle.

Something more...

We request you to have a look at our website to know more about us and our services.

We welcome you to interact with us, share with us, join us and of course publish with us.



Edorium Journals: On Web



Browse Journals

CONNECT WITH US

