

*Case report***PERICARDIAL PATCH AS A PALLIATIVE TREATMENT  
IN THREE DOGS AFFECTED BY UNRESECTABLE  
CARDIAC TUMOR**

COLLIVIGNARELLI Francesco<sup>1,2</sup>, VIGNOLI Massimo<sup>2</sup>, DEL SIGNORE  
Francesca<sup>2</sup>, SIMEONI Francesco<sup>2</sup>, TAMBURRO Roberto<sup>2\*</sup>

<sup>1</sup>Policlinico Roma Sud, via Pilade Mazza, 24, 00173 Rome, Italy; <sup>2</sup>University of Teramo, Faculty of  
Veterinary Medicine, 64100 Piano D'Accio, Teramo, Italy.

(Received 01 July, Accepted 19 November 2019)

This report is aimed at describing a pericardial patch for unresectable cardiac tumors as a palliative technique to prevent pleural effusion.

Each dog underwent the same diagnostic protocol including a cardiological assessment, hematology and biochemistry profile, urinary test, abdominal and heart ultrasonography and chest radiographs. Computed tomography was always performed in order to exclude any potential metastatic lesions. All dogs underwent open pericardiectomy: the pericardium was opened and transposed on the mass according to its shape. Biopsy of the mass was always performed. Histopathological evaluation of the masses described two HAS and one chemodectoma. Chemotherapy protocol includes doxorubicin that was weekly administered. Dogs with HSA survived 65 and 85 days respectively without pleural effusion, while the dog with chemodectoma died after six months for reasons unrelated to the tumor.

No evidence of pleural effusion was observed during the heart recheck, monthly performed.

Pericardial patch is a potential choice as a palliative treatment for unresectable cardiac tumors. No pleural effusion was seen in three dogs affected by unresectable cardiac tumors.

**Key words:** Pericardial patch, cardiac tumor, dog

## INTRODUCTION

Cardiac tumors are atypical diseases in the feline and canine population and are often described as incidental findings [1]. The most common types include haemangiosarcoma (HSA), aortic body tumors (chemodectoma and paraganglioma) and lymphoma [2].

---

\*Corresponding author: e-mail: rtamburro@unite.it

Cardiac tumors ideally require surgical treatment, with the aim of removing all the neoplastic tissue, and, associated systemic drug therapy [3]. Alternatively, external beam radiotherapy was recently used in a dog affected by chemodectoma [4].

In cases of unremovable lesions, palliative pericardiectomy has usually been recommended in order to avoid any potential cardiac tamponade and consequent pleural effusions [3-5].

Pericardiectomy has been associated with prolonged survival in dogs with aortic body tumors, but this approach does not slow tumor growth or improve cardiovascular function in dogs with compressive tumors [6,7].

In cases of pleural effusions occurring after pericardiectomy, further palliative treatments may be used such as recurring thoracentesis and pleural port application; recently the insertion of self-expanding stents into the cranial cave vein has been described [8].

We hypothesized that the pericardium may be used as a patch on the cardiac mass to reduce the pleural effusion.

The aim of this study is to describe the application of a pericardial patch in three dogs affected by unresectable cardiac tumors as a palliative treatment to reduce pleural effusions.

## **CASE DESCRIPTION**

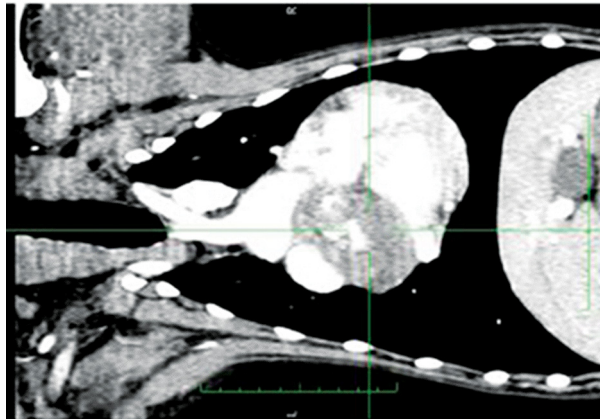
Three dogs (12-year-old entire male German Shepherd, 10-year-old entire male Labrador Retriever, and 10-year-old neutered female Pug) were each presented with a history of exercise intolerance, lethargy, jugular venous distension, and weight loss. On physical examination muffled heart sounds were present.

Each dog underwent the same diagnostic protocol including a cardiological assessment, hematology and biochemistry profile, urinary test, abdominal and heart ultrasonography and thoracic radiographs.

A suspicion of cardiac mass presence was observed. Echocardiography revealed a right atrial mass in two dogs (German Shepherd and Labrador Retriever) and a body aortic mass in the third (Pug). After full staging consisting of blood work, urine examination of total body computed tomography was always performed: no metastatic lesions were observed and all masses were considered unresectable (Fig.1).

According to a presumptive diagnosis based on anatomical location, a biopsy of the mass and pericardial patch application was proposed to the owners as a palliative surgical treatment in order to reduce the pericardial and pleural effusions.

The dogs were sedated with morphine (0.2 mg/kg IM) and acepromazine (0.05 mg/kg IM) 20 min before induction. After preoxygenation for 5 minutes, anesthesia was induced with propofol (4 mg/kg [1.8 mg/lb], IV). Lactated Ringer's solution (2 mL/kg/h) was administered IV to maintain normovolemia, and cefazoline (20 mg/kg, IV) was administered at induction and every 120 min throughout the procedure.



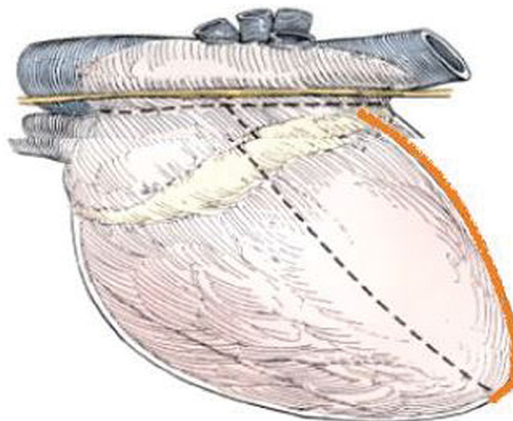
**Figure 1.** 10 year-old neutered female Pug. Dorsal plane reconstruction of a post contrast CT scan shows evidence of a heart based mass.

Dogs were then intubated with a cuffed endotracheal tube and a stable level of anesthesia was achieved with sevoflurane and oxygen.

### **Surgical technique**

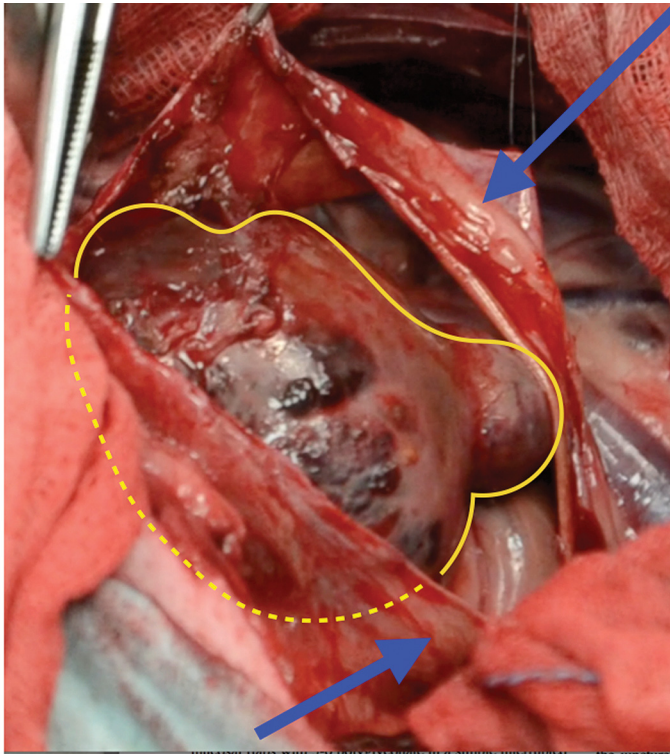
Each patient was positioned in left recumbency; a right thoracotomy performed at the fifth intercostal space was performed. An intercostal retractor was applied between the ribs to expose the thoracic cavity. The lungs were gently retracted using laparotomic swabs.

A T-shaped pericardial incision was performed ventrally to the phrenic nerve. The short side of the T-shaped incision was always parallel to the phrenic nerve while the longer incision was achieved according to the mass position (Fig. 2).



**Figure 2.** Pericardial patch was achieved performing a pericardial T shape incision (dashed line); the long side of the T shape was performed cranially or caudally (red line) opposite to the location of the mass in order to achieve a feasible amount of pericardial tissue.

Following the incision (Fig. 3), the pericardium was transposed in order to cover the mass according to its shape and then sutured with a 4-0 monofilament absorbable continuous suture pattern (Fig. 4). A 6 mm punch was used to achieve a biopsy of the mass.



**Figure 3.** 10 year old neutered female Pug. Intraoperative findings: pericardium (blue arrow) after the first T-shape incision and cardiac mass (yellow line and dashed yellow line)

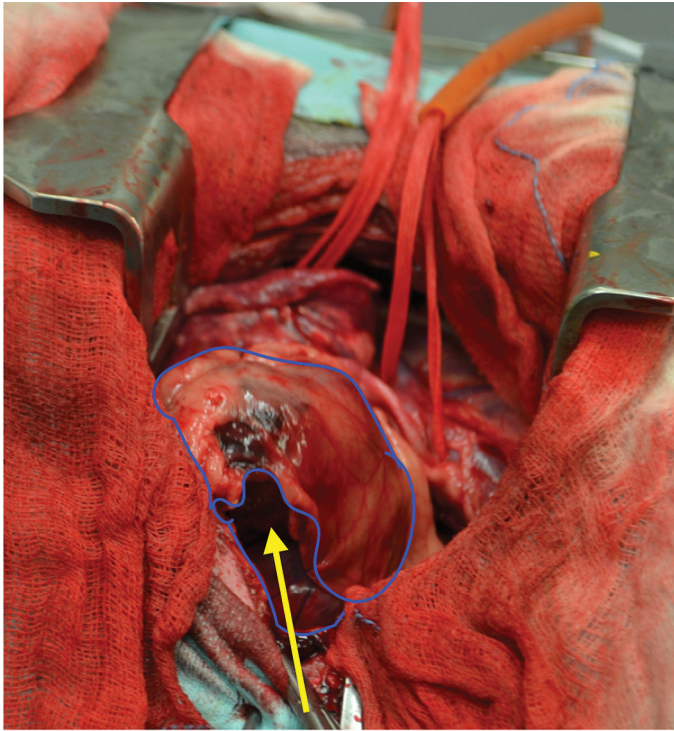
The thoracic cavity was then flushed with a warm sterile solution.

An active chest tube drain was applied and the thoracotomy site was routinely closed.

Negative pressure was then achieved using the drain. A soft bandage was applied around the chest.

### **Postoperative care**

Following surgery, the dogs recovered under close supervision in the intensive care unit. Post-operative medication included methadone (0.2 mg/kg IM every 4-6 hours), intravenous cefazolin (22 mg/kg every 8 hours until the dog accepted oral antibiotics) and continuous intravenous 0.9% NaCl crystalloid therapy. Respiratory rate and effort were monitored.



**Figure 4.** 10 year old neutered female Pug. Intraoperative findings showed the pericardial patch applied on the cardiac tumor (blue line). Pulling the suture the mass will be completely covered by the pericardium

The drain was removed when the postoperative pleural effusion was lower than 2 ml/kg/die.

Following drain removal, dogs were discharged with oral medications including amoxicillin/clavulanic acid (20 mg/kg PO every 12 hours) and tramadol (2–4 mg/kg PO every 8 hours) for up to 7 days after surgery.

There were no major intraoperative complications. Surgical times were 40, 50 and 45 minutes respectively. Histological assessment of the masses revealed HSA in the German Shepherd and Labrador and chemodectoma in the Pug.

Chemotherapy protocol included doxorubicin that was administered through an indwelling intravenous catheter at the dose of 30 mg/m<sup>2</sup>.

X-ray re-examination was performed 30, 60 days post-operatively. No pleural effusion was seen from any of the three dogs.

The dogs with HSA survived 65 and 80 days respectively without pleural effusion, while the last died after six months for reasons unrelated to the tumour.

The goal of the palliative treatment in dogs affected by unresectable heart tumors is to reduce the pericardial effusion. Pleural effusions may additionally develop which can lead to respiratory involvement, pericardial tamponade, and death [9,10].

Pericardiectomy is a surgical procedure aimed to remove the pericardial sac. Neoplastic pericardial effusions may be treated by subtotal pericardiectomy via thoracotomy or by a thoracoscopic pericardial window [11]. Surgeons observed that idiopathic pericardial effusion treated with a subtotal pericardiectomy performed using a thoracotomic approach was associated with a longer disease-free interval (DFI) and median survival time (MST) in comparison to those treated using a thoracoscopic pericardial window [11].

For these reasons, we approached the unresectable heart tumors described in this paper via thoracotomy. The pericardial patch was performed, by applying it onto the mass, without removing the pericardium. Firstly, it is aimed to treat the pericardial effusion as a pericardiectomy by a dorsocaudal transposition of the pericardium, and secondly, to reduce the pleural effusion by a mechanical compression achieved by suturing the pericardium onto the mass.

The pericardial patch was always obtained following a T-shaped pericardial incision. In those patients affected by haemangiosarcoma of the right atrium, the long side of the T-shaped incision was cranially performed in order to cover the mass located in the caudal heart, and in the patient with chemodectoma, the long side of T-shaped incision was caudally performed in order to cover the mass located on the base of the heart.

Re-examination of the three dogs showed no further pleural effusions: dogs affected by HSA died 65 and 80 days post-surgery with pulmonary and hepatic metastasis, while the dog affected by chemodectoma died six months after surgery following a road traffic accident.

Surgical treatment of chronic pleural effusion includes pleuroperitoneal shunting, pleurovenous shunting, pleural port and omentalization of the pleural space [12-15].

All these procedures require the application of pleural port devices or a second lateral abdominal approach.

The pericardial patch may potentially enable concurrent treatment of the pericardial effusion and the consequential pleural effusion by a single thoracotomic approach.

The surgical procedure was easy to perform without evidence of any intraoperative/postoperative complications.

According to the preliminary results, the pericardial patch is a potential choice as a palliative treatment for unresectable cardiac tumors, however, considering the small sample size within this study, further studies would be strongly encouraged for a better understanding of the potential indication of this treatment.

## Authors' contributions

CF performed all the procedures. CF, VM and TR proposed the study design, wrote the paper and given the final approval. DSF and SF conceived of the study and participated in its design and coordination and helped to draft the manuscript.

## Declaration of conflicting interests

The author(s) declared no potential conflicts of interest with respect to the research, authorship, and/or publication of this article.

## REFERENCES

1. Ware WJ, Hopper DL. Cardiac tumors in dogs: 1982-1995. *J Vet Intern Med* 1999; 13: 95-103.
2. Patnaik AK, Liu SK, Hurvitz AI, McClelland AJ. Canine chemodectoma (extra-adrenal paragangliomas)-a comparative study. *J Small Anim Pract* 1975; 16: 785-801.
3. Magestro LM, Geiger TL, Nolan MW. Stereotactic body radiation therapy for heartbase tumors in six dogs. *J Vet Cardiol* 2018; 20(3):186-197.
4. Rancilio NJ, Higuchi T, Gagnon J, McNeil EA. Use of threedimensional conformal radiation therapy for treatment of a heart base chemodectoma in a dog. *J Am Anim Hosp Assoc* 241:472-476.
5. Kelsey KL, Kubicek LN, Bacon NJ, Torres T, Robertson SA. Neuromuscular blockade and inspiratory breath hold during stereotactic body radiation therapy for treatment of heart base tumors in four dogs. *J Am Vet Med Assoc* 2017; 250: 199-204.
6. Vicari Ed, Brown DC, Holt DE, Brockman DJ. Survival times of and prognostic indicators for dogs with heart base masses: 25 cases (1986-1999). *J Vet Med* 2001; 219: 485-487.
7. Ehrhart N, Ehrhart EJ, Willis J, et al. Analysis of factors affecting survival in dogs with aortic body tumors. *Vet Surg* 2002; 31: 44-48
8. Brooks AC, Hardie RJ. Use of the Pleural port device for management of pleural effusion in six dogs and four cats. *Vet Surg* 2011; 40: 935-941.
9. Fossum TW, Evering WN, Miller MW, Forrester SD, Palmer DR, Hodges CC. Severe bilateral fibrosing pleuritis associated with chronic chylothorax in five cats and two dogs. *J Am Vet Med Assoc* 1992; 201:317-324.
10. Little AA, Steffey M, Kraus MS. Marked pleural effusion causing right atrial collapse simulating cardiac tamponade in a dog. *J Am Anim Hosp Assoc* 2007; 43:157-162.
11. Case J, Maxwell M, Aman A, Monnet EL. Outcome evaluation of a thoracoscopic pericardial window procedure or subtotal pericardectomy via thoracotomy for the treatment of pericardial effusion in dogs. *J Am Vet Hosp Assoc* 2013; 15;242(4):493-8
12. Smeak DD, Birchard SJ, McLoughlin MA, et al. Treatment of chronic pleural effusion with pleuroperitoneal shunts in dogs: 14 cases (1985-1999). *J Am Anim Hosp Assoc* 2001; 219:1590-1597.
13. Williams JM, Niles JD. Use of omentum as a physiologic drain for treatment of chylothorax in a dog. *Vet Surg* 1999; 28: 61-65

14. Willauer CC, Breznock EM. Pleurovenous shunting technique for treatment of chylothorax in three dogs. *J Am Vet Hosp Assoc* 1987; 191: 1106–1109.
15. Peterson SL. Postcaval thrombosis and delayed shunt migration after pleuro-peritoneal venous shunting for concurrent chylothorax and chylous ascites in a dog. *Vet Surg* 1996; 25: 228–230.

## **PERIKARDIJALNI “PATCH” KAO PALIJATIVNI TRETMAN KOD TRI PSA SA NEOPERABILNIM TUMOROM NA SRCU**

COLLIVIGNARELLI Francesco, VIGNOLI Massimo, DEL SIGNORE Francesca, SIMEONI Francesco, TAMBURRO Roberto

Ovaj rad ima za cilj da opiše perikardijalnu zakrpu (“*patch*”) tumora na srcu kod kojeg nije moguća resekcija. Postavljenje zakrpe je palijativna tehnika koja ima namenu da spreči nastanak pleuralnih efuzija.

Svaki od tri psa je bio podvrgnut istovetnom dijagnostičkom protokolu koji uključuje kardiološku procenu, hematološki i biohemijski profil, analizu urina, ultrazvuk abdomena i srca i rendgenski snimak grudnog koša. Kompjuterizovana tomografija je rađena svaki put radi isključivanja potencijalnih metastatskih lezija. Svim psima je izvršena perikardiektomija: perikard je otvoren i prenet na tumorsku masu. Biopsija tumora je izvršena kod svih pasa. Histopatološka procena tumora opisuje dva hemangiosarkoma (HAS) i jedan hemodektom. Hemioterapijski protokol uključuje nedeljnu aplikaciju doksorubicina. Psi sa HAS su preživeli 65 i 85 dana bez pleuralne efuzije, dok je pas sa hemodektomom uginuo šest meseci nakon intervencije usled uzroka koji nije bio direktna posledica tumora. Nije ustanovljeno prisustvo pleuralne efuzije tokom mesečnog kontrolnog pregleda.

Perikardijalna zakrpa je potencijalna metoda izbora kao palijativni tretman neoperabilnog tumora srca. Nisu uočene pleuralne efuzije kod posmatranih pasa koji su bolovali od neoperabilnog srčanog tumora.