

PAPER

Innervation and immunohistochemical characteristics of epididymis in Alpaca camelid (*Vicugna pacos*)

Giovanna Liguori,¹ Salvatore Paino,²
Caterina Squillaciotti,¹ Adriana De Luca,¹
Sabrina Ali,¹ Emilia Langella,²
Nicola Mirabella¹

¹Dipartimento di Strutture, Funzioni e
Tecnologie Biologiche, Università di
Napoli Federico II, Italy

²Dipartimento di Scienze delle Produzioni
Animali, Università della Basilicata,
Potenza, Italy

Abstract

Alpacas (*Vicugna pacos*) are domesticated camelids indigenous to south America and recently also bred in Europe and Italy for their high quality wool. There is little data available regarding the innervation of the male reproductive tract of this species. In the present study, the distribution of protein gene product 9.5 (PGP 9.5), neuropeptide Y (NPY), tyrosine hydroxylase (TH), calcitonin gene related peptide (CGRP) and substance P (SP) was analyzed in the epididymis by using immunohistochemical methods. Specimens of the caput, corpus and cauda epididymis were fixed in Bouin's fluid and processed for immunohistochemistry analysis with primary antibodies against PGP 9.5, NPY, TH, CGRP and SP. Immunopositivity to PGP 9.5 and TH and NPY was observed in nerve fibre bundles and in single nerve fibres contained into the peritubular connective tissue. Many TH and NPY immunopositive cells were found to innervate blood vessels. Rare CGRP and SP immunopositive nerves were observed. Several PGP 9.5 and NPY immunopositive epithelial cells were observed in the caput epididymis. The results of the present study suggest a role for the innervations in modulate reproductive functions in the alpaca epididymis.

Introduction

Alpacas are domesticated camelids which play an important socio-economic role in high altitude regions like Andean regions of south

America from Ecuador to southern Chile. Recently, they have become increasingly popular in the USA, Australia and Europe. In particular, in Italy, alpacas are considered producers of high quality wool. Knowledge about the reproduction functions in male alpaca is limited. In south America, alpacas are seasonal breeders for 2-3 months (from December to March) when the availability of food is better (Fowler, 1998). Outside their natural habitat, alpacas are considered non seasonal breeders (Sumar *et al.*, 1999). Alpacas, moreover, are an induced ovulating species (San Martin *et al.*, 1968).

In the male of other camelid species, seasonal histological changes were observed in the testis and epididymis (Zayed, 1994; Saleh, 2002). Up until now, however, histological changes in the genital tract of these species were not yet reported. There are several studies describing male genital tract of alpacas. In particular, Parillo *et al.* (2009a, 2009b, 2012) reported a detailed distribution of glycosidic residues of glycoconjugates in the epididymis, testis and spermatozoa. Wang *et al.* (2011) reported that NGF is expressed in the testis of alpaca. In addition, it has been demonstrated that GnRH directly up-regulates testosterone production in Leydig cells with a postreceptorial mechanism that involves phospholipase C, COX1 and PGF2 (Zerani *et al.*, 2011). Recently, moreover, it has been postulated that orexin and its receptor 1 are involved in the regulation of steroidogenesis in the alpaca testis (Liguori *et al.*, 2012).

The mammalian epididymis is macroscopically divided in three regions: caput (proximal and distal tracts), corpus and cauda and it

Corresponding author: Dr. Giovanna Liguori,
Dipartimento di Strutture, Funzioni e Tecnologie
Biologiche, Facoltà di Medicina Veterinaria,
Università di Napoli Federico II, via Veterinaria
1, 80137 Napoli, Italy.
Tel. +39.081.2536138 – Fax: +39.081.2536097.
E-mail: giovanna.liguori@unina.it

Key words: Alpaca, Cathecolaminergic innervation, Neuropeptides, Epididymal epithelium.

Received for publication: 21 September 2012.

Revision received: 27 November 2012.

Accepted for publication: 13 December 2012.

This work is licensed under a Creative Commons
Attribution NonCommercial 3.0 License (CC BY-
NC 3.0).

©Copyright G. Liguori *et al.*, 2013

Licensee PAGEPress, Italy

Italian Journal of Animal Science 2013; 12:e15

doi:10.4081/ijas.2013.e15

plays a pivotal role in the process of sperm maturation. During the transit through the epididymis, the testicular fluid is modified as a result of the absorbptide and secretory function of the epithelial cells lining the epididymal lumen (Dacheux *et al.*, 2003; Srivastav *et al.*, 2004; Tulsiani, 2006). The autonomic innervation plays a key role in regulation of male genital functions. Anatomical, pharmacological and physiological data (Hib, 1976; Laitinen and Talo, 1981; Pholpramool and Triphon, 1984; Mirabella *et al.*, 2006, 2008; Squillaciotti *et al.*, 2008, 2009) suggest that the role of adrenergic and cholinergic inner-

Table 1. Primary antibodies used in immunohistochemistry.

Primary antibodies	Species	Code	Dilution	Supplier
PGP9.5	Rabbit	7863-0504	1:500	AbD Serorec, Oxford, UK
TH	Mouse	22941	1:250	DiaSorin Inc., Stillwater, MN, USA
NPY	Rabbit	22940	1:250	Immunostar, Hudson, WI, USA
SP	Rabbit	IHC7451	1:250	Peninsula lab., Belmont, CA, USA
CGRP	Guinea pig	T 5027	1:250	Peninsula lab., Belmont, CA, USA

Table 2. Secondary antibodies used in immunohistochemistry.

Secondary antibodies	Code	Dilution	Supplier
Biotinylated anti-mouse IgG	BA- 9200	1:200	Vector Laboratories Inc., Burlingame, CA, USA
Biotinylated anti-goat IgG	BA- 5000	1:200	Vector Laboratories Inc., Burlingame, CA, USA
Biotinylated anti guinea-pig IgG	BA- 7000	1:200	Vector Laboratories Inc., Burlingame, CA, USA
Biotinylated anti-rabbit IgG	BA- 1000	1:200	Vector Laboratories Inc., Burlingame, CA, USA

vation in male genital tract is to regulate epididymis contraction, sperm transport, emission and ejaculation of secretions from the sex accessory glands (Farrel and Lyman, 1937; Sjostrand, 1965; Mirabella *et al.*, 2007) and blood flow (Baumgarten and Holstein, 1968; Kuwahara and Frick, 1974; Damber *et al.*, 1982; Billups *et al.*, 1990; Santamaria *et al.*, 1995). Epithelial exo/endocytic events and ionic exchange between cellular and luminal compartments are other processes that are influenced by autonomic innervations (Mayerhofer *et al.*, 1992; Chan *et al.*, 1994; Kempinas *et al.*, 1995; Lamano-Carvalho *et al.*, 1996; Zhu *et al.*, 1998). Immunohistochemical studies on the mammalian epididymis generally reveal the presence of noradrenergic, cholinergic and peptidergic nerves which have a different distribution within the epididymis (Larsson, 1977; Alm *et al.*, 1978, 1980; Greenberg *et al.*, 1985; Lamano-Carvalho, 1986; Schindermeiser *et al.*, 1989; Tainio, 1994; Lakomy, *et al.*, 1997; Gürtler, 2001). In literature, however, there exist no reports on the innervation of the alpaca epididymis. The aim of present study was, therefore, to describe the local distribution of protein gene product 9.5 (PGP 9.5), neuropeptide Y (NPY), tyrosine hydroxilase (TH), calcitonin gene related peptide (CGRP) and substance P (SP) in the nerves of the alpaca epididymis in order to clarify the role of these neurotransmitters in the male reproductive functions.

Materials and methods

Animals and tissue processing

Five adult male alpacas of six-seven years old and sexually mature were used in the present study. The subjects utilized for this research were from the farm *Domus Alpaca* (Pratola Peligna, AQ, Italy) and tissues were collected on autumn and spring. The animals were anesthetized and surgically operated in accordance to the ethical animal welfare. The testes were removed and epididymis collected. The specimens were divided in caput (proximal and distal tracts), corpus and cauda and fixed in Bouin's fluid for 24-48 h and successively processed for paraffin embedding. Histological sections of 6 μ m thick were obtained.

Immunohistochemistry

The avidin-biotin-peroxidase complex (ABC) method was performed by using the

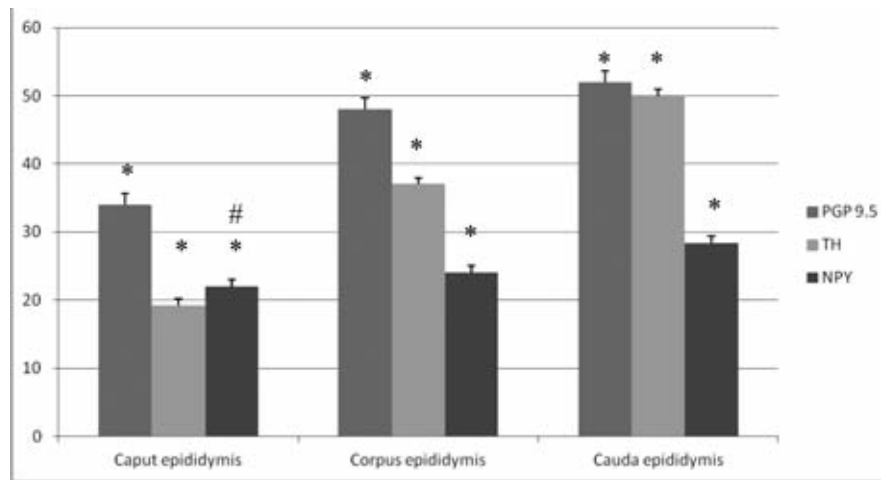


Figure 1. Density of innervation in the different tracts of alpaca epididymis. Immunoreactivity to PGP 9.5, TH and NPY. All data represent media \pm SEM, * $P < 0.01$; NPY caput vs corpus # $P = 0.11$.

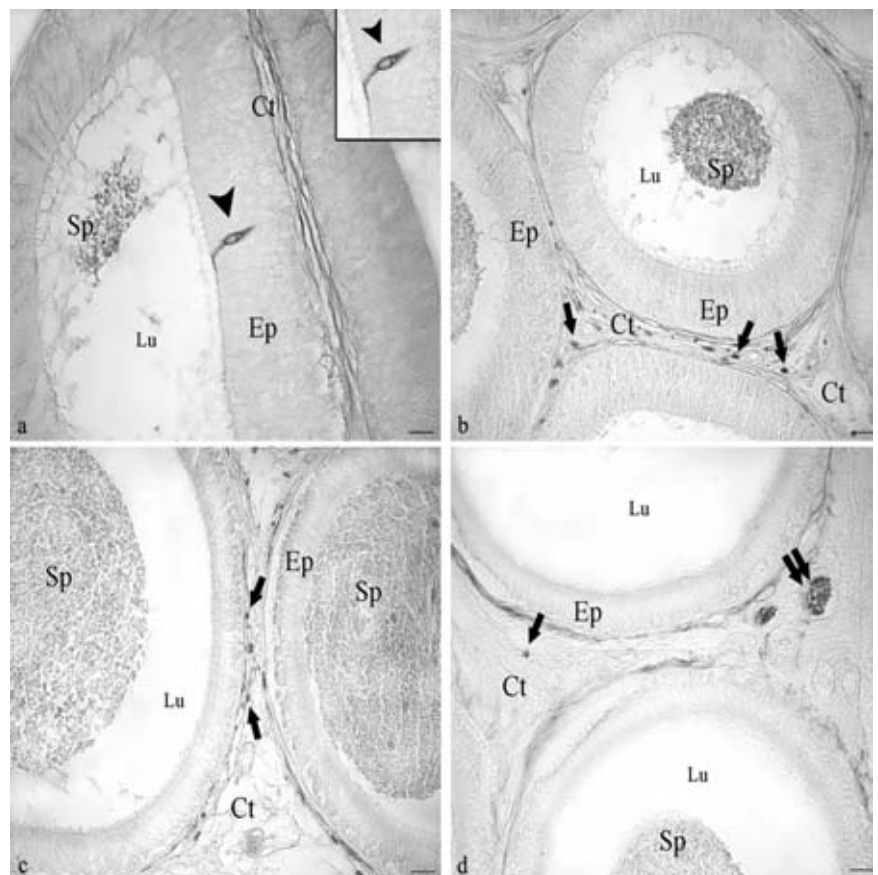


Figure 2. PGP 9.5-immunoreactivity was observed in some principal epithelial cell facing to the tubular lumen (a, arrowhead); many nerve fibers located in the peritubular connective tissue of caput (b, single arrow), corpus (c, single arrow) and cauda (d, single arrow); large nerve bundles in the cauda (d, double arrow). Avidin-biotin immunohistochemical technique. Ep, epithelium; Lu, lumen; Sp, spermatozoa; Ct, connective tissue. Scale bar: 20 μ m.

Vectastain ABC kit (Vector Laboratories, Burlingame, CA, USA) as described more fully elsewhere (Squillaciotti *et al.*, 2011). Primary antibodies were listed in Table 1. Secondary antibodies were listed in Table 2. The specificity of the immunoreactions was tested by omitting the primary antibodies, using PBS and by preadsorption of the primary antibodies with an excess of the antigen.

The numbers of PGP 9.5-, TH- and NPY-positive nerve fibres were counted in 20 randomly chosen microscopic fields per animal by using light microscope Nikon Eclipse E-600 equipped with a Coolpix 8400 digital camera. All data have been expressed as mean \pm SEM. The statistical analysis was performed by using ANOVA Tukey's HSD test for independent samples. For this test, $P < 0.01$ was regarded as significant. The distribution and density of the nerve fibres in the different epididymal tracts are shown in Figure 1.

Results and discussion

PGP 9.5, a marker of the entire innervation (Figure 2), showed the presence of large nerve fibre bundles in the connective tissue encircling the organ and in that distributed among the tubules. Small nerve fibre bundles and single nerve fibres were found around the tubules and around blood vessels. The density of PGP 9.5- positive nerve fibres was evaluated in the different epididymal tracts and it was found to increase from the caput to the cauda (Figure 1). Moreover, several PGP 9.5 immunopositive scattered epithelial cells were observed in the caput. These cells are slender cells without an apparent connection with the epithelial basal lamina and are similar to mitochondria-rich cells. These cells were reported in the initial epididymal segments in men (Fraile *et al.*, 1996) and in other mammalian species (Martinez-Garcia *et al.*, 1995). In the alpaca, they were observed to contain lectins and were postulated to regulate epididymal ionic composition and intraluminal pH (Parillo *et al.*, 2009b).

The catecholaminergic innervation was investigated using TH (Figure 3). TH- positive nerve fibre bundles were found in the connective tissue enveloping the organ and in that distributed among the tubules. TH-positive nerve varicosities were found around the tubules. In addition, TH- immunoreactivity (IR) was observed in the muscle coat of some blood vessels. The number of TH- positive fibres increased from the caput to the cauda (Figure 1). The peptidergic innerva-

tions was investigated using NPY (Figure 4), CGRP (Figure 5 c,d) and SP (Figure 5 a,b). NPY- positive nerve fibre bundles were observed in the connective tissue distributed among the epididymal tubules. NPY- positive varicosities were found around the tubules. In addition, NPY- immunopositive nerve fibres were observed around the blood vessels. The number of NPY- positive fibres increased from the caput to the cauda (Figure 1). Moreover, several NPY immunopositive epithelial cells were observed in the caput. CGRP and SP positive nerve fibres were rarely found in nerve fibre bundles located within the connective tissue distributed around the tubules.

In the present study, the density of nerve

fibres, as revealed by PGP 9.5-, TH- and NPY-IRs, was found to increase from the caput to the cauda of the alpaca epididymis. These results agree with those reported in the cat, dog, guinea pig and human (El Badawi and Schenk, 1967; Norberg *et al.*, 1967; Baumgarten *et al.*, 1968; Hodson *et al.*, 1970; Dail *et al.*, 1993; Gürtler, 2001) including camelus dromedarius (Saleh *et al.*, 2002). The smooth musculature of the caput and corpus epididymis displays spontaneous contraction involving cGMP in the signalling pathway (Risley, 1958; Talo, 1981; Gerendai *et al.*, 2001; Mewe *et al.*, 2006), while the cauda epididymis is normally quiescent until neural input is received during the ejaculatory process (Hib *et al.*, 1982). The localization of

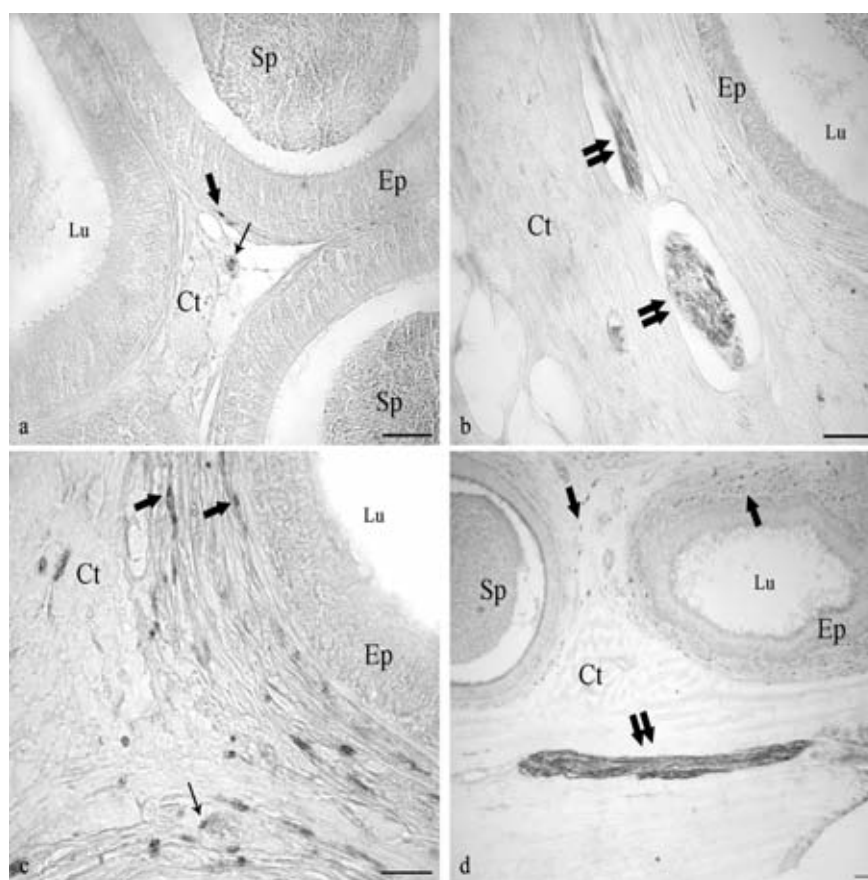


Figure 3. TH-immunopositivity was observed in nerve fibers in the peritubular connective tissue (a,c,d, single arrow); nerve bundles immersed in peritubular connective tissue (b, d, double arrow); muscle coat of blood vessels (a,c, small arrow). Avidin-biotin immunohistochemical technique. Ep, epithelium; Lu, lumen; Sp, spermatozoa; Ct, connective tissue. Scale bar: 20 μ m.

catecholaminergic fibres within the epididymis in peritubular and subepithelial regions suggests that catecholamines play a role in neuromuscular events required for the transport of spermatozoa through the duct and for seminal emission. Studies using surgical and guanethidine induced denervation have shown, moreover, that the decreased contractility observed in the rat epididymis with the loss of adrenergic innervation, induces a delay in cauda luminal transit with a significant increase in the number of spermatozoa present in the cauda epididymis (Billups *et al.*, 1990; Ricker *et al.*, 1996; Kempinas *et al.*, 1998). The presence of TH-immunopositive fibres around blood vessels

suggest a role for the catecholaminergic innervations in regulate epididymal blood flow. These results confirm previous observations in the camel epididymis (Saleh *et al.*, 2002).

Our results showed that the distribution of NPY-IR was similar to that of the catecholaminergic nerves, thus, the possibility that catecholamines and NPY are co-stored in the same nerve fibre vesicles cannot be excluded. In camel epididymis NPY-positive fibres were reported to co-localize with dopamine beta hydroxylase (DBH). A colocalization of NPY with DBH has also been described in the man (Tainio *et al.*, 1994), hamster, (Schindelmeiser *et al.*, 1989), bull, (Rose *et*

al., 1992), cat (Gürtler, 2001) and pig (Kaleczyc *et al.*, 1997, 1999). For this reason NPY seems to be a modulator of adrenergic neurotransmission, playing a role in the ejaculation and sperm transport (Lamano-Carvalho *et al.*, 1986; Mirabella *et al.*, 2003;) and regulation of blood flow (Tainio *et al.*, 1994). The NPY-containing nerves are also distributed intimately with the epithelial cells of the monkey ejaculatory duct which have few ultrastructural features indicating a positive secretory activity (Yokoyama, 1989). CGRP was considered a marker of sensory nerves (Yamada *et al.*, 1977; Ngassapa *et al.*, 1998) and had numerous biological functions like relaxing non vascular smooth musculature (Anouar *et al.*, 1998; Yousufzai and Abdel-Latif, 1998; Hislop *et al.*, 1998) and modulating sensory signals (Häppölä and Lakomy, 1989; Csillik *et al.*, 1993) and together to SP were involved in the control of the pain sensation (Santicioli *et al.*, 1988). Rare SP- and CGRP- positive nerve fibres were found in alpaca, thus confirming the results in the camel epididymis (Saleh *et al.*, 2002). Epithelial cells positive to PGP9.5 and NPY were found in the luminal portion of the alpaca caput epididymis.

These cells could have a possible endocrine/paracrine function taking into account the role of endocrine cells in other apparatuses like gastrointestinal tract and urogenital tract of domestic ungulates and their secretory activity (Arrighi and Domeneghini, 1997, 1998; Kaleczyc *et al.*, 1999). Their role towards growth and differentiation (regulation of mitosis) especially in accessory gland, enables male urogenital endocrine cells in human to act the pathogenesis of cancer and hyperplasia (Yu *et al.*, 2001).

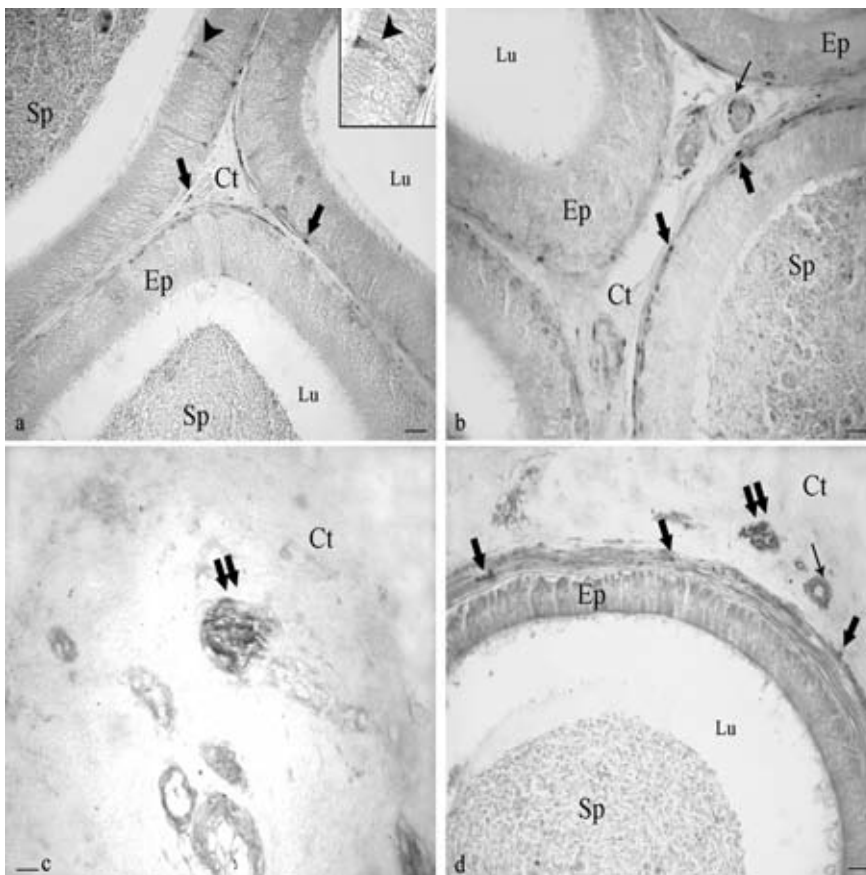


Figure 4. NPY-immunopositivity was observed in some principal epithelial cell in the distal tract of the caput (a, arrow head), nerve fibers, (a, single arrow), corpus (b, single arrow) and (d, single arrow); nerve bundles in peritubular connective tissue (c,d, double arrow); muscle coat of blood vessels (b,d, little arrow). Avidin-biotin immunohistochemical technique. Ep, epithelium; Lu, lumen; Sp, spermatozoa; Ct, connective tissue. Scale bar: 20 μ m.

Conclusions

This research describes the presence of some neurotransmitter in the innervation of alpaca epididymis and provides statistical analysis of their distribution in the three tracts of the organ. The results confirmed those observed in other species and suggest that innervation plays an important role especially in the caudal portion of the organ. Moreover, the presence of epithelial cells containing neuropeptides suggests a specific role for these cells in the regulation of some epididymal epithelial functions.

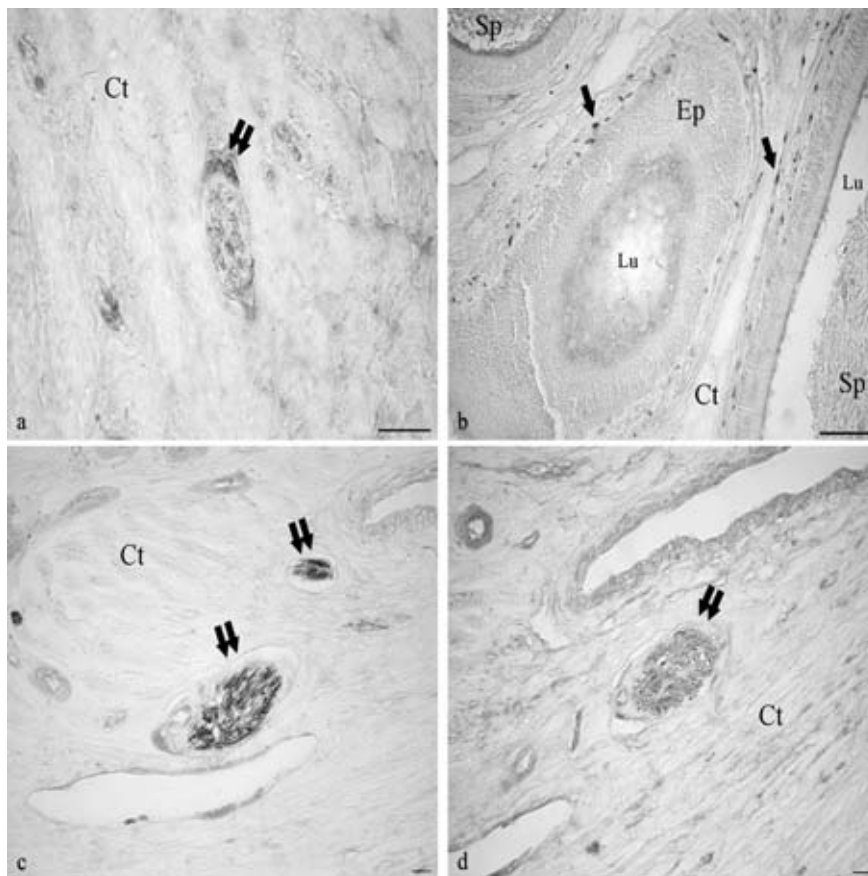


Figure 5. SP-immunopositivity was observed in rare nerve fibers (b, single arrow) and in rare nerve bundle immersed in the connective tissue (a, double arrow). CGRP immunopositivity was observed in rare nerve bundle (c,d, double arrow). Avidin-biotin immunohistochemical technique. Ep, epithelium; Lu, lumen; Sp, spermatozoa; Ct, connective tissue. Scale bar: 20 μm .

cultured rat epididymal cells: regulation of Cl⁻ conductances. *Biol. Reprod.* 51:1040-1045.

- Csillik, E., 1993. Distribution of calcitonin gene-related peptide in vertebrate neuromuscular junctions: relationship to the acetylcholine receptor. *J. Histochem. Cytochem.* 41:1547-1555.
- Dacheux, J.L., Gatti, J.L., Dacheux, F., 2003. Contribution of epididymal secretory proteins for spermatozoa maturation. *Microsc. Res. Techniq.* 61:7-17.
- Dail, W.G., 1993. *Autonome innervation of male genitalia of the urogenital system.* Harwood Publ., Chur, Switzerland.
- Damber, J.E., Lindahl, O., Selstam, G., Tenland, T., 1982. Testicular blood flow measured with a laser Doppler flowmeter: acute effects of catecholamines. *Acta Physiol. Scand.* 115:209-215.
- El Badawi, A., Schenk, E.A., 1967. The distribution of cholinergic and adrenergic nerves in the mammalian epididymis. A comparative histochemical study. *Am. J. Anat.* 121:1-14.
- Farrel, J.I., Lyman, Y.A., 1937. A study of the secretory nerves of, and the action of certain drugs on the prostate gland. *Am. J. Physiol.* 118:64-70.
- Fowler, M.E., 1998. *Medicine and surgery of South American camelids: Llama, Alpaca, Vicuna, Guanaco*, 2nd ed., Iowa State university Press, Ames, IA, USA.
- Fraile, B., Martin, R., De Miguel, M.P., Arenas, M.I., Bethencourt, F.R., Peinado, F., Paniagua, R., Santamaria, L., 1996. Light and Electron microscopic immunohistochemical Localization of protein Gene product 9.5 and Ubiquitin Immunoreactivities in Human Epididymis and Vas Deferens. *Biol. Reprod.* 55:291-297.
- Gerendai, I., Tóth, I.E., Kocsis, K., Boldogkői, Z., Rusvai, M., Halász, B., 2001. Identification of CNS neurons involved in the innervation of the epididymis: a viral transneuronal tracing study. *Auton. Neurosci.-Basic* 92:1-10.
- Greenberg, J., Schubert, W., Metz, J., Yonaiharu, N., Forssmann, W.G., 1985. Studies of the guinea pig epididymis III. Innervation of epididymal segments. *Cell Tissue Res.* 239:395-404.
- Gürtler, A., 2001. *Zur Innervation von Hoden und Nebenhoden der katze. Eine enzym- und immunohistochemische untersuchung.* Degree Diss., University of München, Germany.
- Häppöla, O., Lakomy, M., 1989. Immunohistochemical localization of calcitonin gene-related peptide and

References

- Alm, P., Alumets, J., Brodin, E., Hakanson, R., Nilsson, G., Sjöberg, N.O., Sundler, F., 1978. Peptidergic (Substance P) nerves in the genitor-urinary tract. *Neuroscience* 3:419-425.
- Alm, P., Alumets, J., Hakanson, R., Owman, O., Sjöberg, N.O., Sundler, F., Walles, B., 1980. Origin and distribution of VIP (vasoactive intestinal polypeptide)-nerves in the genitor-urinary tract. *Cell Tissue Res.* 205:337-347.
- Anouar, A., Schran, A., Germain, G., 1998. Relaxant effect of the calcitonin gene-related peptide (CGRP) on the non pregnant and pregnant rat uterus. Comparison with vascular tissue. *N-S Arch. Pharmakol.* 257:440-453.
- Arrighi, S., Domeneghini, C., 1997. Localization of regulatory peptides in the male urogenital apparatus of domestic equidae: a comparative immunohistochemical study in *Equus caballus* and *Equus asinus*. *Histol. Histopathol.* 12:297-310.
- Arrighi, S., Domeneghini, C., 1998. Immunolocalization of regulatory peptides and 5-HT in bovine male urogenital apparatus. *Histol. Histopathol.* 13:1049-1059.
- Baumgarten, H.G., Holstein, A.F., 1968. Adrenergic innervation in the testis and epididymis of the swan (*Cygnus olor*). *Z. Zellforsch. Mik. Ana.* 91:402-410.
- Billups, K.L., Tillman, S., Chang, T.S., 1990. Ablation of the inferior mesenteric plexus in the rat: alteration of sperm storage in the epididymis and vas deferens. *J. Urol.* 143:625-629.
- Chan, H.C., Fu, W.O., Chung, Y.W., Zhou, T.S., Wong, P.Y., 1994. Adrenergic receptors on

- bombesin/gastrin-releasing peptide in nerve fibres of the rat, guinea pig, and pig female genital organs. *Histochemistry* 92:211-218.
- Hib, J., 1976. Effects of autonomic drugs on epididymal contractility. *Fertil. Steril.* 27:915-956.
- Hib, J., Ponzio, R., Vilar, O., 1982. Contractility of rat cauda epididymis and vas deferens during seminal emission. *J. Reprod. Fertil.* 66:47-50.
- Hislop, A.A., Boels, P.J., Deutsch, J., Polak, J.M., Haworth, S.G., 1998. Developmental changes in binding sites and reactivity for CGRP and VIP in porcine pulmonary arteries. *Peptides* 19:703-714.
- Hodson, N., 1970. The nerves of the testis epididymis and scrotum. In: A.D. Johson, W.R. Gomes and N.L. VanDemark (eds.) *The testis*. Academic Press, New York, NY, USA, pp 47-99.
- Kaleczyc, J., Timmermans, J.P., Majewsky, M., Lakomy, M., Scheuermann D.W., 1999. Immunohistochemical properties of nerve fibres supplying accessory male genital glands in the pig. A colocalization study. *Histochem. Cell. Biol.* 111:217-228.
- Kempinas, W.G., Petenusci, S.O., Rosa e Silva, A.A., Faveretto, A.L.V., Lamano-Carvalho, T.L., 1995. The hypophyseal-testicular axis and sex accessory glands following chemical sympathectomy with guanethidine of pre-pubertal to mature rats. *Andrologia* 27:121-125.
- Kempinas, W.D., Suarez, J.D., Roberts, N.L., Strader, L.F., Ferrell, J., Goldman, J.M., Noratsky, M.G., Peneault, S.D., Evenson, D.P., Ricker, D.D., Klinefelter, G.K., 1998. Fertility of rat epididymal sperm after chemically and surgically induced sympathectomy. *Biol. Reprod.* 59:897-904.
- Kuwahara, M., Frick, J., 1974. Hypogastric nerve and transport of spermatozoa through the vas deferens. *Andrologia* 6:125-128.
- Laitinen, L., Talo, A., 1981. Effects of adrenergic and cholinergic drugs on electrical and mechanical activities of the rat cauda epididymis in vitro. *J. Reprod. Fertil.* 63:205-209.
- Lakomy, M., Kalecsyc, J., Majewski, M., 1997. Noradrenergic and peptidergic innervation of the testis and epididymis in the male pig. *Folia Histochem. Cyto.* 35:19-27.
- Lamano-Carvalho, T.L., Guimarães, M.A., Kempinas, W.G., Petenusci, S.O., Rosa e Silva, A.A., 1996. Effects of guanethidine-induced sympathectomy on the spermatogenic and steroidogenic testicular functions of prepubertal to mature rats. *Andrologia* 28:117-122.
- Lamano-Carvalho, T.L., Hodson, N.P., Blank, M.A., Watson, P.F., Mulderry, P.K., Bishop, A.E., Gu, J., Bloom, S.R., Polak, J.M., 1986. Occurrence, distribution and origin of peptide-containing nerves of guinea pig and rat male genitalia and effect of denervation on sperm characteristics. *J. Anat.* 149:121-141.
- Larsson, L.I., 1977. Occurrence of nerves containing vasoactive intestinal polypeptide immunoreactivity in the male genital tract. *Life Sci.* 21:503-508.
- Liguori, G., Assisi, L., Squillacioti, C., Paino, S., Mirabella N., Vittoria, A., 2012. Presence, distribution and steroidogenic effect of the peptides orexin A and receptor 1 for orexins in the testis of the South American camelid alpaca (*Vicugna pacos*). *Gen. Comp. Endocrinol.* 179:137-142.
- Martinez-García, P., Regadera, J., Cobo, P., Paniagua, R., Nistal, M., 1995. The apical mitochondria-rich cells of the mammalian epididymis. *Andrologia* 27:195-206.
- Mayerhofer, A., Steger, R.W., Gow, G., Bartke, A., 1992. Catecholamines stimulate testicular testosterone release of the immature golden hamster via interaction with alpha and beta-adrenergic receptors. *Acta Endocrinol.* 127:526-530.
- Mewe, M., Bauer, C.K., Müller, D., Middendorff, R., 2006. Regulation of spontaneous contractile activity in the bovine epididymal duct by cycling guanosine 5'-monophosphate-dependent pathways. *Endocrinology* 147:2051-2062.
- Mirabella, N., Squillacioti, C., De Luca, A., Paino, G., 2007. Seasonal reproductive activity and innervation of vas deferens and accessory male genital glands in the water buffalo (*Bubalus bubalis*). *Ital. J. Anim. Sci.* 6 (Suppl.2):636-639.
- Mirabella, N., Squillacioti, C., De Luca, A., Paino, G., 2008. Effects of castration on the expression of TrkB and p75NTR in the vas deferens and male accessory genital glands of the rat. *Anat. Histol. Embryol.* 37:118-125.
- Mirabella, N., Squillacioti, C., Paone, I., Ciarcia, R., Russo, M., Paino G., 2006. Effects of castration on the expression of brain-derived neurotrophic factor (BDNF) in the vas deferens and male accessory genital glands of the rat. *Cell Tissue Res.* 323:513-522.
- Mirabella, N., Squillacioti, C., Varricchio, E., Genovese, A., Paino, G., 2003. Innervation of vas deferens and accessory male genital glands in the water buffalo (*Bubalus bubalis*) neurochemical characteristics and relationships to the reproductive activity. *Theriogenology* 59:1999-2016.
- Nagassapa, D., Narhi, M., Horvonem, T., Markkula, I., 1998. Calcitonin gene-related peptide immunoreactive (CGRP-IR) intradental nerves in the dog. *E. Afr. Med. J.* 75:151-155.
- Norberg, K. A., Risley, P. L., Ungerstend, U., 1967. Adrenergic innervation of the male reproductive ducts in some mammals. I: the distribution of the adrenergic nerves. *Z. Zellforsch. Mik. Ana.* 76:278-286.
- Parillo, F., Magi, G.E., Diverio, S., Catone, G., 2009a. Immunohistochemical and lectin histochemical analysis of the alpaca efferent ducts. *Histol. Histopathol.* 24:1-12.
- Parillo, F., Verini Supplizi, A., Macri, D., Catone, G., 2009b. The ductus epididymis of the Alpaca: immunohistochemical and lectin histochemical study. *Reprod. Dom. Anim.* 44:284-294.
- Parillo, F., Verini Supplizi, A., Mancuso, R., Catone, G., 2012. Glycomolecule modifications in the seminiferous epithelial cells and in the acrosome of post-testicular spermatozoa in the alpaca. *Reprod. Domest. Anim.* 47:675-686.
- Pholpramool, C., Triphrom, N., 1984. Effects of cholinergic and adrenergic drugs on intraluminal pressures and contractility of the rat testis and epididymis in vivo. *J. Reprod. Fertil.* 71:181-188.
- Ricker, D.D., Chamness, S.L., Hinton, B.T., Chang, T.S.K., 1996. Changes in luminal fluid protein composition in the rat cauda epididymis following partial sympathetic denervation. *J. Androl.* 17:117-126.
- Risley, P.L., 1958. The contractile behaviour in vivo of the ductus epididymis and vasa efferentia of the rat. *Anat. Rec.* 130:471-478.
- Rose, C., 1992. Regionale Untergliederung und Innervation der Cauda Epididymis beim Rind (*Bos taurus*). Degree Diss., University of Regensburg, Germany.
- Saleh, A.M.M., Alameldin, M.A., Abdelmoniem, M.E., Hassouna, E.M., Wrobel, K.H., 2002. On the intrinsic innervation of the epididymis of the camel (*Camelus dromedarius*). *Ann. Anat.* 184:305-315.
- San-Martín, M., Capaira, M., Zuniga, J., Rodriguez, R., Bustinza, G., Acosta, L., 1968. Aspects of reproduction in the alpaca. *J. Reprod. Fertil.* 16:395-399.
- Santamaria, L., Martín, R., Codesal, J., Ramirez, R., Paniagua, R., 1995. Immunohistochemical quantitative study of the peritubular lamina propria after induction of testicular atrophy induced by epinephrine. *Int. J. Androl.* 18:295-306.

- Santicioli, P., Maggi, C.A., Geppetti, P., Del Bianco, E., Theodorsson, E., Meli, A., 1988. Release of calcitonin gene-related peptide-like immunoreactivity (CGRP-LI) from organs of the genitourinary tract in rats. *Neurosci. Lett.* 92:197-201.
- Schindelmeiser, J., Kuntzner, M., Rolf, L.H., Hofmann, K., 1989. Photoperiodic influence on the innervation of the ductus epididymis and ductus deferens of the Djungarian hamster, *Phodopus sungorus*: electron-microscopic and biochemical results. *Cell Tissue Res.* 256:175-181.
- Sjostrand, N.O., 1965. The adrenergic innervations of the vas deferens and the accessory male genital glands. *Acta Physiol. Scand.* 257:1-82.
- Squillaciotti, C., De Luca, A., Liguori, G., Paino, S., Mirabella, N., 2011. Expression of urocortin and corticotropin-releasing hormone receptors in the bovine adrenal gland. *Gen. Comp. Endocrinol.* 172:416-422.
- Squillaciotti, C., De Luca, A., Paino, S., Langella, E., Mirabella, N., 2009. Effects of castration on the expression of the NGF and TrkA in the vas deferens and accessory male genital glands of the rat. *Eur. J. Histochem.* 53:239-248.
- Squillaciotti, C., De Luca, A., Paino, G., Mirabella, N., 2008. Effects of castration on the immunoreactivity to NGF BDNF and their receptors in the pelvic ganglia of the male rat. *Eur. J. Histochem.* 52:101-106.
- Srivastav, A., Singh, B., Chandra, A., Jamal, F., Kham, M. Y., Chowdury, S. R., 2004. Partial characterization sperm association and significance of N- and O- linked glycoproteins in epididymal fluid of rhesus monkeys (*Macaca mulatta*). *Reproduction* 127:343-357.
- Sumar, J.B., 1999. Reproduction in south America domestic camelids. *J. Rep. Fer. S.* 54:169-178.
- Tainio, H., 1994. Peptidergic innervation of the human testis and epididymis. *Acta Histochem.* 96:415-420.
- Talo, A., 1981. In vitro spontaneous electrical activity of rat efferent ductules. *J. Reprod. Fertil.* 63:17-20.
- Tulsiani, D.R.P., 2006. Glycan-modifying enzymes in luminal fluid of the mammalian epididymis: an overview of their potential role in sperm maturation. *Mol. Cell. Endocrinol.* 250:58-65.
- Yamada, M., Ishikawa, T., Fujimori, A., Goto, K., 1977. Local neurogenic regulation of rat hindlimb circulation: role of calcitonin gene-related peptide in vasodilation after skeletal muscle contraction. *Brit. J. Pharmacol.* 122:703-709.
- Yokoyama, R., 1989. Histochemical and immunohistochemical studies on intraepithelial nerves fibres in the ejaculatory duct of the monkey (*Macaca fuscatus*). *Kurume Med. J.* 36:101-112.
- Yousufzai, S., Abdel-Latif, A.A., 1998. Calcitonin gene-related peptide relaxes rabbit iris dilator smooth muscle via cyclic AMP-dependent mechanisms: cross-talk between the sensory and sympathetic nervous systems. *Curr. Eye Res.* 17:197-204.
- Yu, D.S., Chen, H.I., Chang, S.Y., 2001. The expression of neuropeptides in hyperplastic and malignant prostate tissue and its possible clinical implications. *J. Urol.* 166:871-875.
- Wang, H. Dong, Y., Chen, W., Hei, J., Dong, C., 2011. Expression and localization of nerve growth factor (NGF), in the testis of alpaca (*Lama pacos*). *Folia Histochem. Cyto.* 49:55-61.
- Zayed, A.E., 1994. Morphological studies on the seasonal changes in the testis of the camel. Degree Diss., University of Assiut, Egypt.
- Zerani, M., Catone, G., Quassinti, L., Maccari, E., Bramucci, M., Gobbetti, A., Maranesi, M., Boiti, C., Parillo, F., 2011. In vitro effects of gonadotropin-releasing hormone (GnRH) on Leydig cells of adult alpaca (*Lama pacos*) testis: GnRH receptor immunolocalization, testosterone and prostaglandin synthesis, and cyclooxygenase activities. *Domest. Anim. Endocrin.* 40:51-59.
- Zhu, B., Cavicchia, J.C., Chiochio, S.R., 1998. Testicular denervation-induced nuclear changes in Leydig cell of hemicastrated adult rats. *Tissue Cell* 30:485-491.

Copyright of Italian Journal of Animal Science is the property of PAGEPress and its content may not be copied or emailed to multiple sites or posted to a listserv without the copyright holder's express written permission. However, users may print, download, or email articles for individual use.