

# Delayed Bilateral Symptomatic Vasospasm after Resection of a Skull Base Meningioma: Report on a New Case and Literature Review

Matteo Capozza <sup>1</sup>, Giovanni Barbagli <sup>2\*</sup>, Andrea Boschi <sup>2</sup>, Bahman Ashraf-Noubari <sup>3</sup>, Sergio Nappini <sup>4</sup>, Nicola Limbucci <sup>4</sup>, Arturo Consoli <sup>4</sup>, Leonardo Renieri <sup>5</sup>, Andrea Rosi <sup>5</sup>, Salvatore Mangiafico <sup>6</sup>, Franco Ammannati <sup>7</sup>

<sup>1</sup> MD, Consultant in Neurosurgery, University of Florence, Florence, Italy

<sup>2</sup> MD, Resident in Neurosurgery, University of Florence, Florence, Italy

<sup>3</sup> MD, Consultant in Neurosurgery, Azienda Ospedaliero Universitaria Careggi, Florence, Italy

<sup>4</sup> MD, Consultant in Interventional Neuroradiology, Azienda Ospedaliero Universitaria Careggi, Florence, Italy

<sup>5</sup> MD, Resident in Interventional Neuroradiology, Azienda Ospedaliero Universitaria Careggi, Florence, Italy

<sup>6</sup> MD, Director of Interventional Neuroradiology, Azienda Ospedaliero Universitaria Careggi, Florence, Italy

<sup>7</sup> MD, Director of Neurosurgical Department, AOUC, Florence, Italy

\* Corresponding Author Address: Department of Neurosurgery, University of Florence, Largo Palagi 1, Florence, Italy. Fax: +390552299984. Email: barbagli.giovanni@gmail.com

Article Type: Case Report

Received: January 25, 2016, Last Revised: April 28, 2016, Accepted: April 30, 2016

## Abstract

**Background and Importance:** Symptomatic vasospasm is a well-known pathology associated with ruptured aneurysms. Nevertheless, this condition is rarely found as a result of skull base tumor removal.

**Case Presentation:** We reported a new case of 40-year-old woman previously treated for a tuberculum and diaphragma sellae meningioma showing symptomatic vasospasm after twelve post-operative days without previously documented sub-arachnoid hemorrhage (SAH). A digital subtraction angiography (DSA) was performed, and a bilateral vasospasm was detected. After subsequent endovascular treatments by intra-arterial infusion of nimodipine, the patient experienced a full recovery.

**Conclusion:** Symptomatic vasospasm after meningioma removal is a challenging and life-threatening condition. Early diagnosis is the key for successful treatment.

**Keywords:** Cerebral Vasospasm; Tumor Resection; Tuberculum Sellae; Diaphragma Sellae; Nimodipine; Meningioma

Please cite this paper as: Capozza M, Barbagli G, Boschi A, Ashraf-Noubari B, Nappini S, Limbucci N, Consoli A, Renieri L, Rosi A, Mangiafico S, Ammannati F. Delayed Bilateral Symptomatic Vasospasm after Resection of a Skull Base Meningioma: Report on a New Case and Literature Review. *Iran. J. Neurosurg.* 2016;2(1):25-30.

## Background and Importance

Vasospasm is a well-known complication of a subarachnoid hemorrhage (SAH) subsequent to rupture of intracranial aneurysms. Nevertheless, symptomatic vasospasm due to skull base tumors removal is an uncommon event and only few cases have been previously reported following resection of meningioma (1,2). This condition shares clinical features with the one following SAH and depends on the surgical field site, the location of vasospasm (anterior or posterior circulation), the surgical approach performed and the mass of blood clot. Conversely, mortality and morbidity are very high, both for the lack of clinical suspicion and the delayed treatment (3-5). Early diagnosis and prompt therapy planning are mandatory for a successful treatment.

We performed a complete literature review using proper key-words such as "symptomatic vasospasm", "meningioma resection", "skull base tumors", "postoperative vasospasm", "subarachnoid hemorrhage", "tuberculum sellae", "sphenoid planum", and "nimodipine therapy" on PubMed and MEDLINE databases. We also completely reviewed clinical notes and imaging reports, with the evaluation of short-term clinical follow-up. We considered only cases of symptomatic cerebral vasospasm following a skull base meningioma resection including comprehensive clinical and radiological data.

## Case Presentation

### *Patient's History and Status*

A 40-year-old woman was admitted to our department with recurrent episodes of visual loss associated with right hemifacial pain from some years now. Patient's history showed positivity to HCV infection and a dysplasia of uterine cervix (cervical intraepithelial neoplasia, grade 2). The patient complained about pain on the second trigeminal branch which was evoked in association with decreasing visual acuity on right eye. Subsequently, we noted anisocoria with the diameter of right pupilla greater than the left one.

### *Neuroimaging*

A gadolinium MRI was performed to assess clinical image and reported a lesion with  $3.2 \times 2.7 \times 3.2$  cm, isointense on T1-weight sequences and hyperintense on T2-weight in the region of anterior fossa, showing compatibility with tuberculum and diaphragma sellae meningioma (Figures 1,2). The digital angiography reported a delayed medial impregnation on the clivus region with bilateral A1-segments dislocation which confirmed the suspicious lesion. That study also showed the coexistence of cortical arterio-venous shunt from a parietal feeder of posterior cerebral artery (PCA) with a single shunting by a cortical vein into the sagittal sinus (micro arteriovenous malformation (AVM)).

### *Surgery*

The patient underwent surgery to remove the lesion.

A pterional craniotomy was performed on the right side, and a subfrontal approach revealed a grey and fibrous-like lesion with attachment on the tuberculum and the diaphragma sellae. The right optic nerve was dislocated and thickened and the carotid artery was totally entrapped by the meningioma. After careful dissection of the vascular and neural structures and central debulking, the tumor was completely excised and the dural attachment coagulated with a grade II resection according to Simpson. No intraoperative bleedings were observed, and hemostasis was simple and effective.

cranial Doppler (TCD) study was performed in order to evaluate the progression of symptoms with the evidence of increased flow velocity in both middle cerebral arteries (MCAs) (307 cm/sec on left side; 228 cm/sec on right side), anterior cerebral arteries (ACAs) (174 cm/sec on left side; 128 cm/sec on right side) and in the posterior circulation (88 cm/sec).

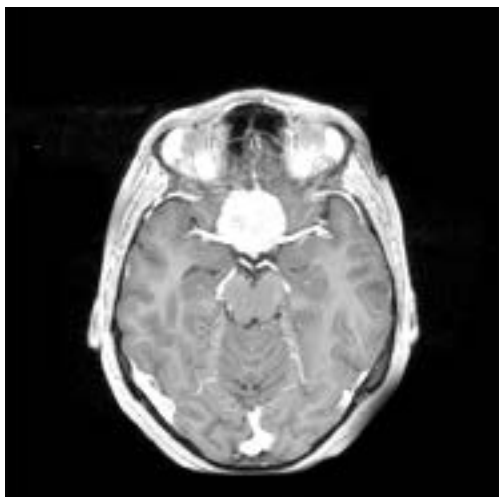


Figure 1. An Axial T1MRI Showing the Diaphragma Sellae Meningioma

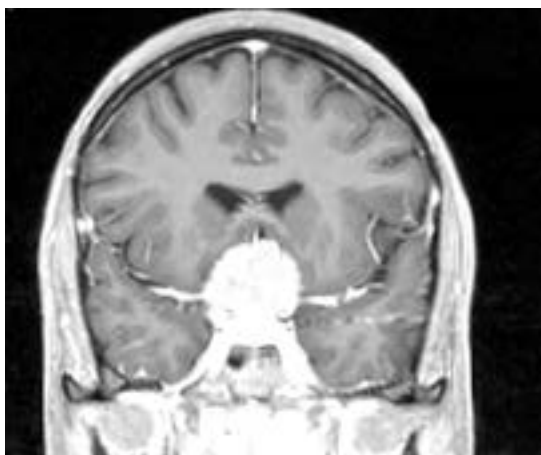


Figure 2. T1 Scan Showing Coronal View of the Meningioma

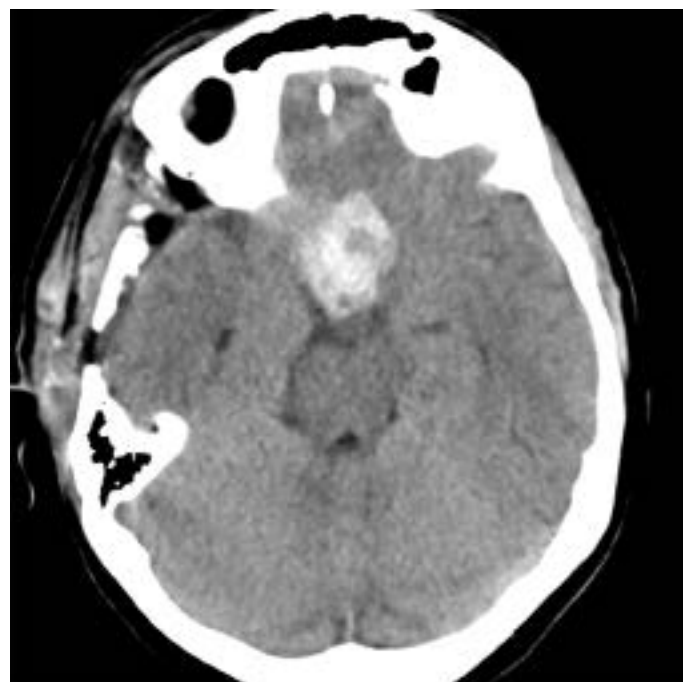


Figure 3. An Axial CT Scan Showing Hemorrhagic Infarction at Surgical Site

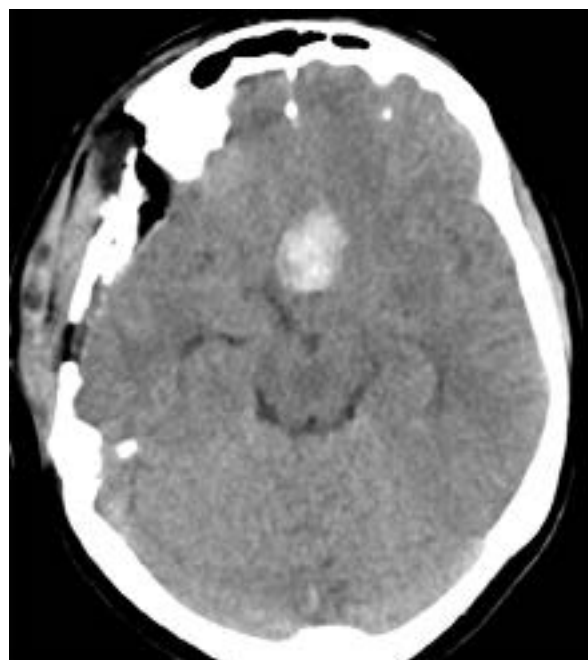


Figure 4. Another View of the Infarction from Axial CT Scan

**Post-operative Course**

After the operation, the patient underwent a post-operative CT scan without evidence of bleeding at the surgical site. After a few days, a total recovery was observed and the patient was discharged without neurological symptoms on fifth post-operative day. One week later, the patient was re-admitted to our emergency department because of accidental fall and mild head trauma, and underwent a CT scan with a limited hemorrhagic infarction in the surgical site (Figures 3-5).

**Second Admission**

The patient was mild febrile for two days, without any other evidence of neurological impairment. The next day, she experienced an early clinical worsening with aphasia, left side weakness and severe consciousness deterioration. A trans-

The diagnosis of symptomatic cerebral vasospasm was therefore suspected, and the medical therapy (triple - H by hypertension, hypervolemia, hemodilution) was immediately started associated with the intravenous administration of nimodipine (2mg/h infusion). Subsequently, the patient immediately

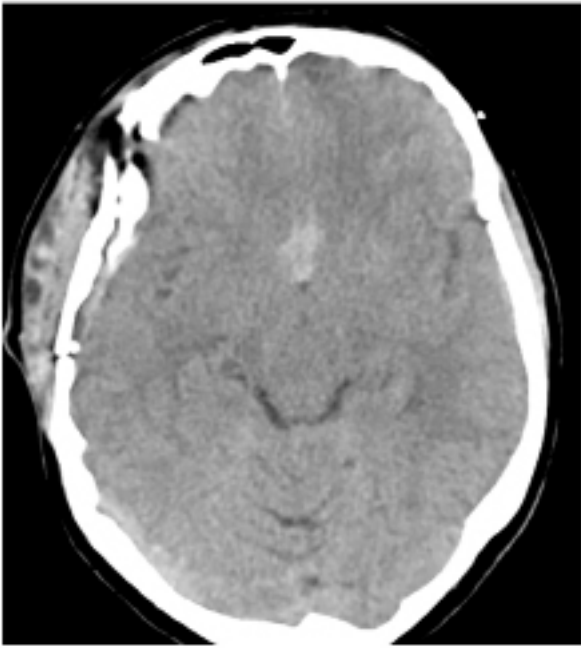


Figure 5. The Infarctions Site Headed at the Top

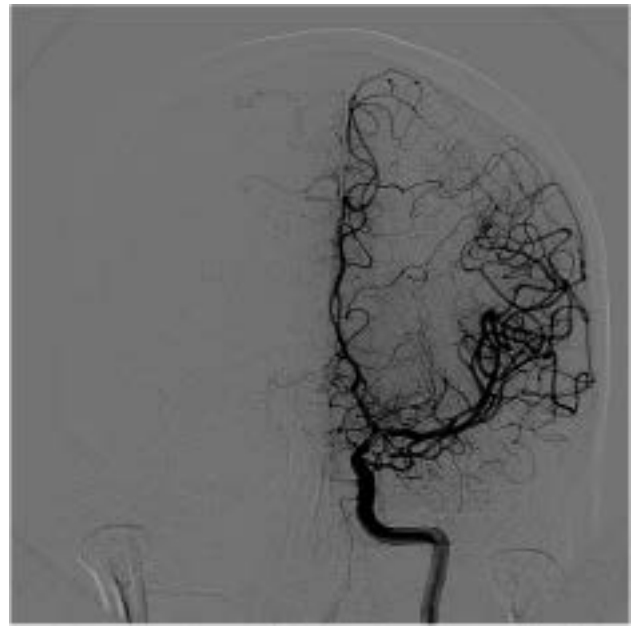


Figure 7. Diffuse Vasospasm on Left Side

underwent a digital subtraction angiography (DSA) which confirmed the diagnosis of severe vasospasm in both MCAs, carotid siphons and ACAs, but more evident on the left A1 tract and the right C4 tract of internal carotid artery (Figures 6-9). A slowing down of blood flow was observed within the vascular territory of the left ACA. No sign of vasospasm was detected within the posterior circulation. Then, the patient underwent endovascular treatment by intra-arterial injection of 12 mg of nimodipine through both internal carotid arteries (ICAs) (6 mg for each side), restoring normal blood flow (Figures 10,11). The same procedure was repeated once a day during the next two days (eight mg during the second day and four mg during the third day) based on the TCD follow-up, and a progressive improvement of clinical status was observed. The patient was discharged eight days later, following a negative CT scan for delayed ischemia (Figures 12,13), and the TCD revealed normal values of flow velocity. No neurological deficits were observed at the time of discharge.

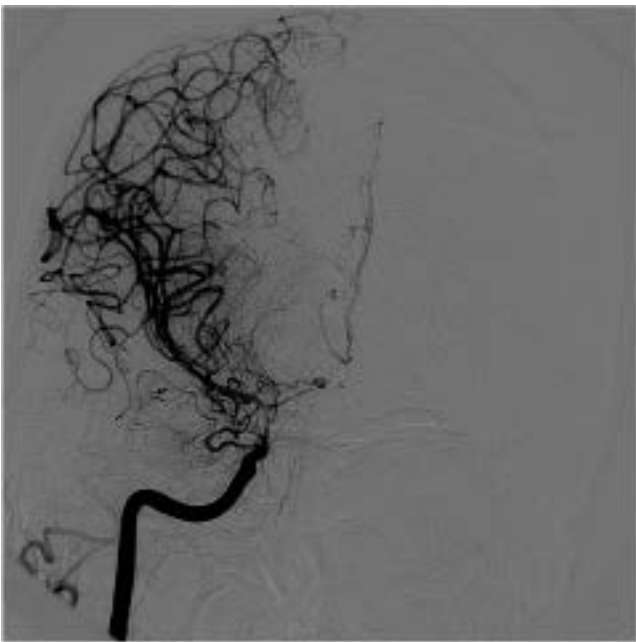


Figure 8. A DSA Showing the Severe C4 Tract Vasospasm on Right Side

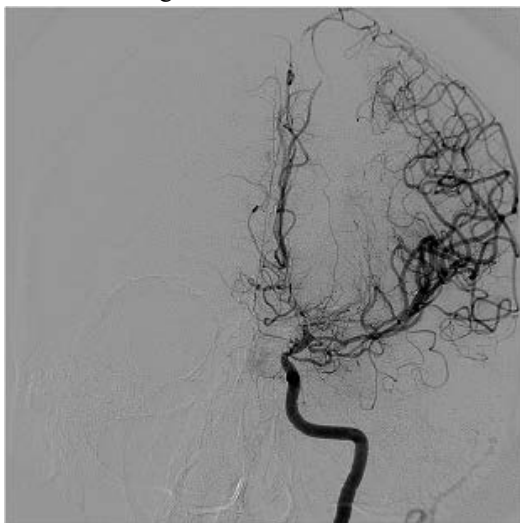


Figure 6. A DSA Exam Showing the Severe Left A1 Vasospasm

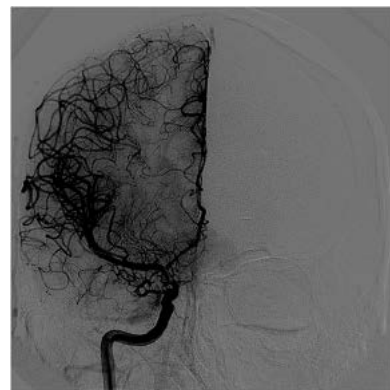


Figure 9. DSA Right Side

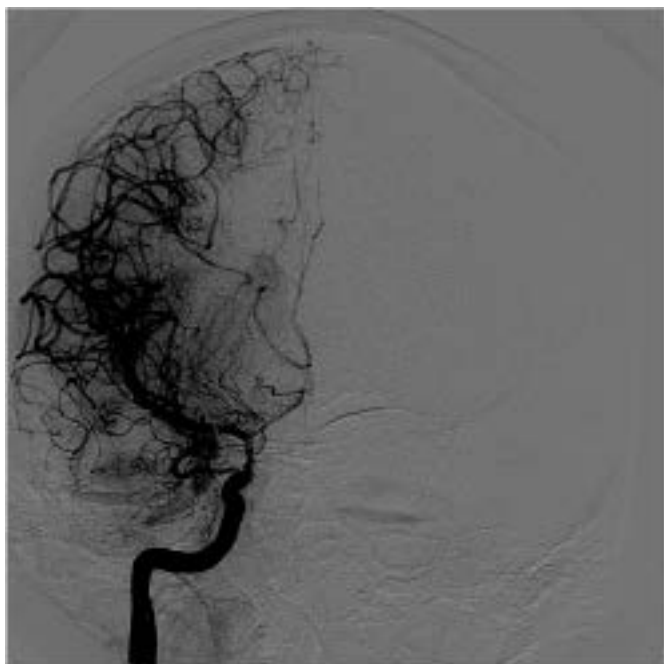


Figure 10. DSA Exam after Endovascular Infusion of Nimodipine (Right Side)

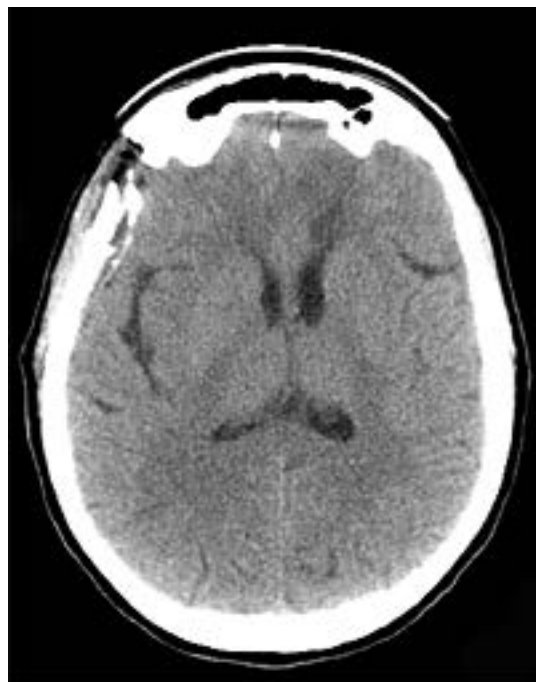

Figure 12. A Post-infusion CT Scan Showing the Absence of Ischemic Areas

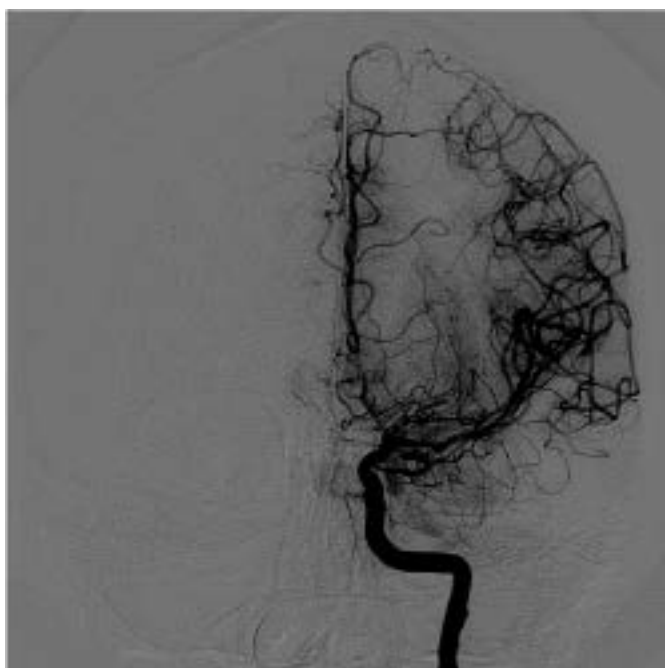

Figure 11. DSA Exam after Endovascular Infusion of Nimodipine (Left Side)

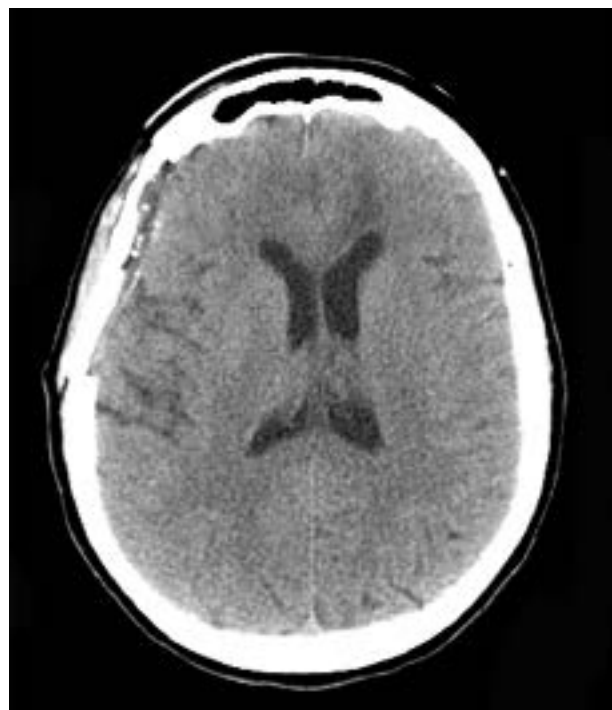


Figure 13. Post-infusion CT Scan: No Ischemia

## Discussion

We performed a comprehensive literature review using “cerebral vasospasm”, “tumor resection” and “meningioma” as key words. According to our criteria, 14 cases of vasospasm associated with meningioma resection were found; 12 patients of whom were symptomatic (Table 1). To our knowledge, we reported the thirteenth case.

Author	Year	Journal	Number of Symptomatic Patients in Reported Cases
Cervoni et al.	2012	J Neuro. Sci.	1 of 5 reported
Taussky P et al.	1999	Surg Neurol.	1
De Monte et al.	1994	J Neurosurgery	1
Bejjani GK et al.	1999	Surg Neurol.	6 of 7 reported
Kusunose M.	1997	No Shinkei Geka	1
LeRoux PD et al.	1991	Surg Neurol.	1 of 2 reported

According to the literature, where the patients affected by symptomatic vasospasm following meningioma resection were young (mean age=41 years) (6), our case presented clinical features at the age of 40. In all reported cases, the lesions of the skull base were located close to the basal cisterns. Post-operative bleeding was also observed in all of them. It is also well known that subarachnoid bleeding leads to vasospasm in a mean time of 7-8 days (7). We found, instead, a delayed vasospasm (12th post-operative day) and that late diagnosis could be explained by an unclear clinical onset (blurred frontal lobe syndrome). The high rate of mortality (30%) once patient becomes symptomatic enforces physicians to begin the proper vasospasm management (8-12). This practice consists in the execution of hyper-dynamic therapy, endovascular pharmacological therapy with nimodipine and mechanical angioplasty (where suitable), as soon as possible (3). A correct and early diagnosis combined with a proper medical/endovascular treatment is the only way to obtain a successful management of this potentially fatal occurrence. In a pathophysiological point of view, a vasospasm following tumor removal may be explained by a peri-operative SAH. In other cases, it might be a consequence of increased sympathetic tone due to diencephalic dysfunction (5) or vasoactive materials from tumor secondary to a surgical site manipulation (2,8,12).

## Conclusion

Symptomatic vasospasm following skull base meningioma resection is a very rare and challenging occurrence, with high mortality/morbidity rates. Nevertheless, the data from literature suggest that the key seems to be the early diagnosis associated with a correct treatment. This practice ensures either the survival or the complete recovery of neurological functions in young patients. Symptomatic vasospasm, associated with skull base meningioma resection, has to be a crucial issue for a correct management.

## Funding

None.

## Conflicts of Interest

The authors have no conflicts of interest.

## References

- Leroux PD, Haglund MM, Mayberg MR, Winn HR. Symptomatic cerebral vasospasm following tumor resection: report of two cases. *Surgical Neurology*. 1991;36(1):25-31.
- Alotaibi NM, Lanzino G. Cerebral vasospasm following tumor resection. *Journal of Neurointerventional Surgery*. 2013;5(5):413-8.
- Bejjani GK, Sekhar LN, Yost AM, Bank WO, Wright DC. Vasospasm after cranial base tumor resection: pathogenesis, diagnosis, and therapy. *Surgical Neurology*. 1999;52(6):577-84.
- Taussky P, Kalra R, Couldwell WT. Delayed vasospasm after removal of a skull base meningioma. *Journal of Neurological Surgery Part A: Central European Neurosurgery*. 2012;73(04):249-52.
- Wilson JL, Feild JR. The production of intracranial vascular spasm by hypothalamic extract. *Journal of Neurosurgery*. 1974;40(4):473-9.
- DeMonte F, Smith HK, Al-Mefty O. Outcome of aggressive removal of cavernous sinus meningiomas. *Journal of Neurosurgery*. 1994;81(2):245-51.
- Kusunose M, Fukuda O, Saito T, Takaku A, Endo S. [Diffuse cerebral artery vasospasm following total resection of posterior fossa meningioma: a case report]. *No shinkei geka. Neurological Surgery*. 1997;25(10):953-7.
- Cooke-Yarborough C, Turner J, Pell M, Sheehy J. Myonecrosis of the middle cerebral artery with thrombosis and cerebral infarction following resection of meningioma. *Pathology*. 1993;25(4):416-9.
- Chang SD, Yap OS, Adler JR. Symptomatic vasospasm after resection of a suprasellar pilocytic astrocytoma: case report and possible pathogenesis. *Surgical Neurology*. 1999;51(5):521-7.
- Bejjani GK, Duong DH, Kalamirides M, Ziyal I, Sullivan BJ. Cerebral vasospasm after tumor resection. A case report. *Neuro-Chirurgie*. 1996;43(3):164-8.
- Bejjani GK, Sekhar LN, Yost AM, Bank WO, Wright DC. Vasospasm after cranial base tumor resection: pathogenesis, diagnosis, and therapy. *Surgical Neurology*. 1999;52(6):577-84.
- Krayenbuhl H. Beitrag zur Frage des cerebralen angiospatischen Insultes. *Schweiz Med Wochenschr*. 1960;90:961-5.

## Comments

Vasospasm associated cerebral ischemia is a rare complication following surgical resection of brain tumors. These neoplasms are usually located within or adjacent to the basal cisterns. With regard to brain tumors, significant vasospasm is reported in the postoperative period in only less than 50 cases throughout the literature (1). This complication can be devastating for the patients as well as the neurosurgeons as the ischemic sequel, severe disability or death is expected in more than 70% of cases. The main reason for such a bad prognosis is believed to be delayed diagnosis. It may easily be confused with cerebral edema or surgical injury, leading to misdiagnosis and inappropriate treatments. Nonetheless, this complication is potentially treatable if recognized soon.

Capozza et al. have nicely reported a case of documented vasospasm following resection of tuberculoma and diaphragma sellae meningioma (2). Although previously reported earlier in the literature (1), the delayed occurrence of symptoms is very rare and apparently an interesting feature of this case, but it seems that this should be interpreted with caution and the main cause of such a complication needs to be further discussed.

The key indicator of surgically related symptomatic cerebral vasospasm is delayed neurological deterioration. The most common manifestation is hemiparesis (1). The interval between tumor resection and the onset of the symptoms is usually three to ten days, just identical to what is expected after aneurysmal SAH, although the complication can occur

even 30 days after the operation (1). The cause appears to be multifactorial and blood spillage into the subarachnoid space, increased sympathetic tone due to diencephalic dysfunction, operative manipulation of vessels and the release of vasoactive substances from the tumor are believed to be the main factors playing role in the pathogenesis (1,3). In this particular case, considering the pathogenesis and natural history of vasospasm, this strong possibility should be kept in mind that the complication could have basically been produced by the delayed hematoma rather than surgical manipulation itself. With delayed hematoma being assumed as the main cause, both the time interval between vasospasm and the surgical intervention and bilateral occurrence of vasospasm will be explainable in a much better fashion.

As a conclusion, I should emphasize on the importance of what the authors mentioned: recognition of such a complication is crucial as any delay in diagnosis can adversely affect the outcome of the patients. The authors managed to treat the patient successfully only because they had proper clinical suspicion and did not miss the diagnosis. Accordingly, mentioning such cases helps clinicians to remember including vasospasm in the list of differential diagnoses when delayed postoperative neurological manifestations occur. In my opinion, the other importance of this report is to mention postoperative intracerebral hematoma as one of the important risk factors of vasospasm, which can happen as a consequence.

*Kourosh Karimi Yarandi MD, Assistant Professor of Neurosurgery, Tehran University of Medical Sciences, Tehran, Iran*

## References

1. Alotaibi, N.M. and Lanzino, G. Cerebral Vasospasm Following Tumor resection. *Journal of Neurointerventional Surgery*, 2013(5):413-418. <http://dx.doi.org/10.1136/neurintsurg-2012-010477>
2. Capozza M, Barbagli G, Boschi A, Barni I, Nappini S, Limbucci N, Consoli A, Renieri L, Rosi A, Mangiafico S, Bahman AN, Ammannati F. Delayed Bilateral Symptomatic Vasospasm after Resection of a Skull Base Meningioma: Report on a New Case and Literature Review. *Iranian Journal of Neurosurgery*. 2016;2(1):25-29.
3. Bejjani, G.K., Sekhar, L.N., Yost, A.M., Bank, W.O. and Wright, D.C. Vasospasm after Cranial Base Tumor Resection: Pathogenesis, Diagnosis, and Therapy. *Surgical Neurology*, 1999(52):577-583. [http://dx.doi.org/10.1016/S0090-3019\(99\)00108-1](http://dx.doi.org/10.1016/S0090-3019(99)00108-1)