

## CASE REPORT

# Fulminant ischemic colitis with a fatal outcome after cocaine snorting: Case report and literature review

Nunziata Barbera <sup>a</sup>, Francesco Paolo Busardò <sup>a,\*</sup>, Francesca Indorato <sup>a</sup>,  
Giovanni Bartoloni <sup>b</sup>, Guido Romano <sup>a</sup>

<sup>a</sup> Department “G.F. Ingrassia”, Laboratory of Forensic Toxicology, University of Catania, Italy

<sup>b</sup> Department “G.F. Ingrassia”, Section of Anatomic Pathology, University of Catania, Italy

Received 5 June 2013; revised 1 August 2013; accepted 12 September 2013

Available online 23 October 2013

### KEYWORDS

Cocaine;  
Snorting/sniffing;  
Fulminant ischemic colitis

**Abstract** Snorting represents the most common route of administration for recreational powdered cocaine, and it is considered less dangerous than other routes of intake (i.e., intravenous; crack inhalation; etc.). A case of fulminant ischemic colitis with a fatal outcome, which occurred in a 19-year-old man after cocaine snorting, is presented in this report. Although several cases are reported in the literature, no one has involved people aged less than 20 years. The young man showed unspecific symptoms, which began about 2 h after the cocaine intake and the physicians were unable to make the diagnosis. This report may assist doctors treating young men who have consumed cocaine to consider this possible complication in all young adults (teenagers) in the presence of unspecific symptoms.

© 2013 Production and hosting by Elsevier B.V. on behalf of Forensic Medicine Authority.

## 1. Introduction

Cocaine is available as cocaine hydrochloride, which is a water-soluble powder and less frequently used as crack.<sup>1</sup>

\* Corresponding author. Address: Department of Anatomy, Biology and Genetics, Legal Medicine, Neurosciences, Diagnostic Pathology, Hygiene and Public Health, “G.F. Ingrassia”, Section of Legal Medicine, Laboratory of Forensic Toxicology, University of Catania, Via S. Sofia 87, Comparto 10, 95123 Catania, Italy. Tel.: +39 095 378 21 64; fax: +39 095 378 21 65.

E-mail address: [fra.busardo@libero.it](mailto:fra.busardo@libero.it) (F.P. Busardò).

Peer review under responsibility of Forensic Medicine Authority.



Production and hosting by Elsevier

Snorting represents the most common route of administration for recreational powdered cocaine, whereas “crack” is inhaled or smoked. Injection is less common, and most cocaine-related deaths reported in the literature are subsequent to the intravenous route of administration. Epidemiological and clinical data show that the smoked and the intravenous routes have greater abuse morbidity and mortality than the intranasal route.<sup>2</sup>

Cocaine is the second most used illicit drug within Europe, after cannabis, with recent reports indicating that nearly 5% of Europeans aged 15–64 (around 15.5 million people) have used cocaine at least once in their life.<sup>3</sup>

The use of cocaine can cause severe pathologic effects that were reported in almost every organ and system, including the brain, heart, lung, kidneys, gastrointestinal tract and musculature involvement.<sup>1</sup>

Herein, a case of fulminant ischemic colitis with a fatal outcome, which occurred in a 19-year-old man after cocaine snorting, is presented.

Several cases are reported in the literature, as shown by Karch<sup>4</sup> who reviewed numerous papers from 1985 to 2005, which describe the patho-physiological features, symptoms and age of people who develop this pathology following cocaine abuse, but none of them has involved people aged less than 20 years. For this reason, the aim of this report is to suggest that physicians who treat young men after cocaine consumption take into consideration this possible complication in the presence of unspecific symptoms, which in the case presented here did not allow the physicians to make a prompt diagnosis.

## 2. Case report

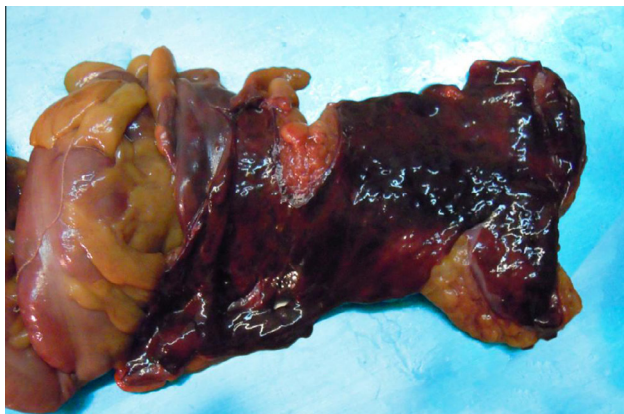
A 19-year-old man was brought in the night to the emergency room in an unconscious state after multiple episodes of bloody diarrhea and marked abdominal pain. From the first reconstruction of the facts, it emerged that, the previous evening, he had a cocaine snorting binge with a friend and after a couple of hours, gastrointestinal symptoms began and became increasingly worse.

Despite treatment provided in the emergency room and the attempts at resuscitation, the young man died approximately 11 h after the cocaine snorting event.

## 3. Materials and methods

A complete autopsy was performed about 24 h after death, including a toxicological investigation of biological fluids (blood, vitreous humor and bile), organs (the brain, lung, liver and kidney) and hair, following the procedure recommended by the *French Society of Analytical Toxicology*<sup>5</sup> (L/L extraction) and purification through solid phase extraction (SPE). The analysis was performed by an Agilent Technologies (AT) 6890 N Gas Chromatograph coupled to a AT 5973 Inert Mass Selective Detector (MSD).

Histological sections of the heart, lungs, kidneys, liver and intestine (ileum, colon and cecum) were stained with hematoxylin and eosin for microscopic examination.



**Figure 1** The ascending and transverse colon show a large necrotic area, which involves the entire wall.

## 4. Results

The external examination did not reveal the presence of injuries, only a marked hematochezia was detected. The autopsy showed a mild to moderate pulmonary edema and no structural anomalies of the heart (weight 375 g). The large intestine showed the ascending and transverse colon affected by a large necrotic area, which involved the entire wall (Fig. 1). The section of the ascending colon showed a severe transmural necrosis and a marked hemorrhage.

The histological examination of specimens of the ascending and transverse colon stained with hematoxylin and eosin revealed a marked hemorrhagic erosive colitis of the ascending (Fig. 2A) and transverse colon (Fig. 2B) and erosions and extensive hemorrhagic necrosis of the whole mucosa.

The results of toxicological analysis performed on viscera and body fluids, collected during autopsy, showed the presence of cocaine and its metabolite benzoylecgonine. All data are reported in Table 1. Neither alcohol nor other drugs were found. In the hair analysis, 1.08 ng/mg of cocaine and 0.31 ng/mg of benzoylecgonine were found.

## 5. Discussion

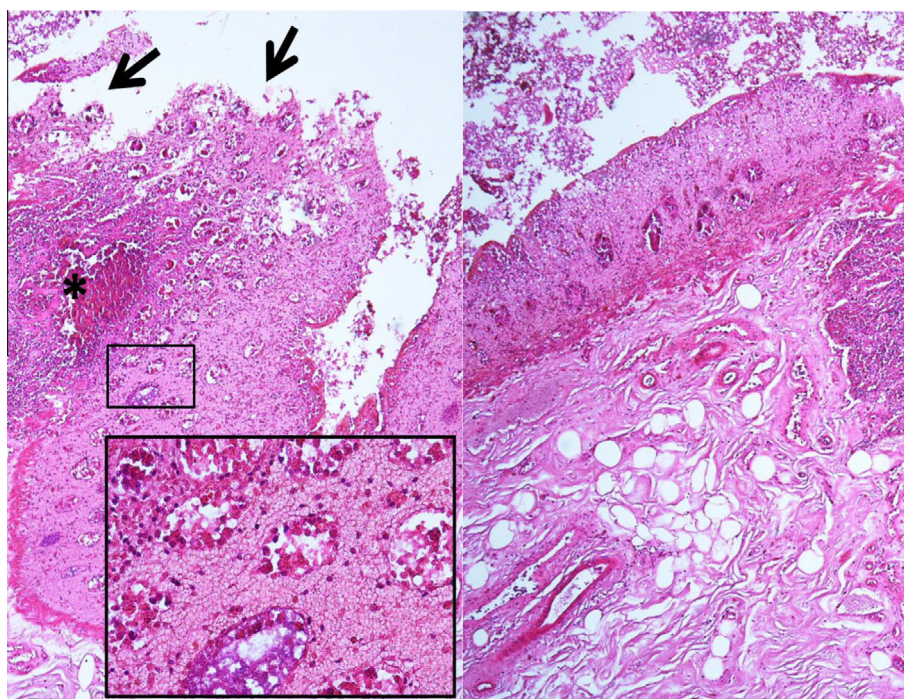
Numerous factors, such as the route of administration, post-mortem absorption and different patterns of metabolism in chronic or occasional users, influence the interpretation of toxicological findings in cocaine-associated deaths and generally, apart from cases of massive drug exposure (e.g., body packers), cocaine-related deaths occur for the most part after prolonged drug use.<sup>6,7</sup>

The complications of cocaine abuse more often involve the cardiovascular and respiratory systems and less frequently the gastrointestinal tract (GT). It has been reported that complications of the upper GT, such as duodenal perforation, happen more frequently than the lower GT complications (intestinal ischemia, gangrene and perforation).<sup>8,9</sup>

Ischemic colitis (IC) is a medical condition in which inflammation and injury of the large intestine result from inadequate blood supply. Although uncommon in the general population, IC occurs with a greater frequency in the elderly and it is the most common form of bowel ischemia.<sup>10</sup> Even if IC in young adults is unusual, cocaine abuse can cause mesenteric ischemia and gangrene; the pathogenic mechanism is the arteriolar vasospasm induced by the increase of a-adrenergic tone or the vasoconstriction through the stimulation of intestinal a-adrenergic receptors, which leads to intestinal ischemia with transmural necrosis.<sup>11,12</sup>

Generally, from drug assumption and symptom's onset, there is an interval of time between 1 h and 2 days, and the most common symptom is the abdominal pain, sometimes associated with bloody diarrhea.<sup>9</sup> The majority of cases reported in the literature have shown ischemia of the small rather than the large intestine.<sup>13</sup>

The case reported here has been investigated following the broadly accepted criteria for the investigation of numerous types of drug deaths, which include: a complete autopsy, a review of investigative findings and the identification and quantification of cocaine and/or its metabolites in biological samples collected during the autopsy,<sup>7,14</sup> moreover, the results of toxicological investigation in blood and brain samples have



**Figure 2** Induced hemorrhagic erosive colitis of the ascending (A) and transversal colon (B): erosions (arrows) and extensive hemorrhagic necrosis of the whole mucosa. The insert shows the selected area with necrotic glandular structures surrounded by macrophages and abundant erythrocytes. (H&E x200; H&E x400).

**Table 1.** Concentrations of cocaine and its metabolite benzoylecgonine found in viscera (ng/mg) and body fluids (ng/mL).

Organs	Cocaine	Benzoylecgonine
Blood	213.3	1382.3
Vitreous humor	382.4	1495.4
Brain	382.1	851.2
Lung	756.4	1323.2
Liver	20.3	1629.4
Kidney	327.6	1712.3
Urine	4218.4	7905.7
Gall	73,836.4	16,896.2

been considered following the interpretative value of the determination of cocaine and benzoylecgonine in blood and brain tissues and their correlation proposed by Spielher and Reed<sup>15</sup> and more recently reviewed by Bertol et al.<sup>7</sup> and the ratio of cocaine and benzoylecgonine concentrations in the blood and brain fell in the range of incidental finding rather than cocaine overdose, confirming that the correlation of blood and tissue cocaine concentrations with toxicity are not strictly related.<sup>16</sup>

In this case, the rapid development of the ischemic colitis induced by “snorting cocaine” affected extensively the transverse tract and the first gastrointestinal symptoms began approximately 2 h after the drug assumption and they rapidly worsened leading to the death of the young man.

## 6. Conclusions

The ischemic colitis for its extent and features (transmural hemorrhagic necrosis) and fulminant course caused the death

of the 19-year-old man approximately 11 h after sniffing cocaine, despite the proper treatment provided in the emergency room.

The present case also demonstrates the risk of fatal intestinal ischemia associated with the recreational use of snorted cocaine in young subjects and the knowledge of this case, which represents the first case involving a teenager reported in the literature, can help to consider this entity in the management of young patients who have snorted cocaine. The diagnosis of IC was made only after the post mortem examination, because the clinical and laboratory data were non-specific and the physicians were unable to diagnose the case.

## Funding

None.

## Conflict of interest

None declared.

## Ethical approval

Ethical approval was taken from University of Catania, Italy.

## References

1. Karch SB. Cocaine cardiovascular toxicity. *South Med J* 2005;98:794–9.
2. Volkow ND, Wang GJ, Fischman MW, Foltin R, Fowler JS, Franceschi D, et al. Effects of route of administration on cocaine-

- induced dopamine transporter blockade in the human brain. *Life Sci* 2000;**67**:1507–15.
3. EU Drug markets report. A strategic analysis. European Monitoring Centre for Drugs and Drug Addiction 2013. p. 33–9 Chapter 3.
  4. Karch SB. Pathology of drug abuse. 4th ed. CRC press: 2009, p. 193–5.
  5. Gaillard Y, Pepin G, Marquet P, Kintz P, Deveaux M, Mura P. Identification and quantification of benzoylecgonine, cocaine, methylecgonine-ester codeine, morphine and 6-acetylmorphine in whole blood. *Toxicorama VIII* 1996;17–22.
  6. Stephens BG, Jentzen JM, Karch SB, Mash DC, Wetli CV. Criteria for the interpretation of cocaine levels in human biological samples and their relation to the cause of death. *Am J Forensic Med Pathol* 2004;**25**:1–10.
  7. Bertol E, Trignano C, Di Milia MG, Di Padua M, Mari F. Cocaine-related deaths: an enigma still under investigation. *Forensic Sci Int* 2008;**176**(2–3):121–3.
  8. Sharma R, Organ Jr CH, Hirvela ER, Henderson VJ. Clinical observation of the temporal association between crack cocaine and duodenal ulcer perforation. *Am J Surg* 1997;**174**:629–33.
  9. Tiwari A, Moghal M, Meleagros L. Life threatening abdominal complications following cocaine abuse. *J R Soc Med* 2006;**99**:51–2.
  10. Brandt LJ, Boley SJ. AGA technical review on intestinal ischemia. *American gastrointestinal association. Gastroenterology* 2000;**118**:954–68.
  11. Loureiro JF, Mansur R, Correa PA, Drigo JM, Teixeira CV, Solak CR, et al. Cocaine-induced ischemic colitis. *Rev Assoc Med Bras* 2012;**58**:14.
  12. Pradhan L, Mundal D, Chandra S, Ali M, Agrawal KC. Molecular analysis of cocaine-induced endothelial dysfunction: role of endothelin-1 and nitric oxide. *Cardiovasc Toxicol* 2008;**8**:161–71.
  13. Wattoo MA, Osundeko O. Cocaine-induced intestinal ischemia. *West J Med* 1999;**170**:4–49.
  14. Jenkins AJ, Levine B, Titus J, Smialek JE. The interpretation of cocaine and benzoylecgonine concentrations in post-mortem cases. *Forensic Sci Int* 1999;**101**:17–25.
  15. Spielher VR, Reed D. Brain concentrations of cocaine and benzoylecgonine in fatal cases. *J. Forensic Sci* 1985;**30**:1003–11.
  16. Karch SB. Interpretation of blood cocaine and metabolite concentrations. *J Emerg Med* 2000;**18**:635–6.