

Case report:

Recurrent primary leiomyosarcoma of the seminal vesicle treated with curative radiotherapy.

Anna Santacaterina¹, Antonino Scimone², Silvana Parisi³, Nicola Settineri⁴, Angelo Platania⁵, Grazia Acquaviva⁶, Stefano Pergolizzi⁷

Abstract

A case of locally recurrent leiomyosarcoma of the left seminal vesicle, previously surgically resected, is described in a 65-year-old man. The patient underwent curative radiation therapy (61 Gy/33 fractions). Initially, he experienced a complete response after irradiation, but 15 months after treatment, progressive disease was recorded both in lung and bone, without evidence of local recurrence. The lack of efficient systemic therapies leads to a poor prognosis in this disease; clinical outcome in this patient seems to suggest the utility of radiotherapy in the very rare *scenario* of locally recurrent seminal vesicle leiomyosarcoma.

Keywords: Radiotherapy; Leiomyosarcoma; Recurrence

Bangladesh Journal of Medical Science Vol. 18 No. 01 January'19. Page : 156-158
DOI: <https://doi.org/10.3329/bjms.v18i1.39569>

Introduction:

Soft tissue genitourinary tract sarcomas are rare and primary leiomyosarcomas of the seminal vesicle are exceedingly rare.¹ In the setting of recurrent disease after a previous radical surgery, there are not guidelines about the best therapeutic approach due to the extreme rarity of this clinical scenario. Surgery is the preferred treatment in primitive disease and there is no a clear role regarding adjuvant therapies. To the best of our knowledge no report exists on the treatment of recurrent disease. Here, we describe the first case of recurrent leiomyosarcoma of the seminal vesicle submitted to curative irradiation.

Case Report:

A 65-year-old Caucasian man consulted our department in March 2013. His past history was relevant because, in July 2011, he underwent surgery for a well-differentiated leiomyosarcoma with no lymph node metastases. In July 2012, a follow-up

abdominal and pelvic computed tomography (CT) revealed an enhanced 2.5-cm mass in left pararectal space suspicious for recurrence of disease. A CT-guided biopsy confirmed the suspicion. Patient underwent surgery and the pathological diagnosis was G2 leiomyosarcoma; moreover, narrow surgical margins very found (<1 mm).

In January 2013, T2-weighted-MR images showed a nodule of 2.1 x 2.7 x 3.5 cm in left pararectal space, compatible with recurrent disease; ¹⁸F-FDG-PET/CT demonstrated high radiopharmaceutical accumulation in that nodule (SUVmax 11.4: Figure 1). The patient was referred to our department.

According to clinical disease history, we choose to deliver a curative radiotherapy course. Patient signed informed consent prior to treatment. No adjuvant chemotherapy was administered. Planning target volume included whole pelvis (as clinical target volume) and the site of recurrent disease

1. Anna Santacaterina, Operative Unit of Radiation Oncology, Papardo Hospital, Messina, Italy.
2. Antonino Scimone, Operative Unit of Medical Oncology, Papardo Hospital, Messina, Italy.
3. Silvana Parisi, Section of Radiological Sciences, Department of Biomedical and Dental Sciences and Morphofunctional Imaging, University of Messina, Messina, Italy.
4. Nicola Settineri, Operative Unit of Radiation Oncology, Papardo Hospital, Messina, Italy.
5. Angelo Platania, Operative Unit of Radiation Oncology, Papardo Hospital, Messina, Italy.
6. Grazia Acquaviva, Operative Unit of Radiation Oncology, Papardo Hospital, Messina, Italy
7. Stefano Pergolizzi, Section of Radiological Sciences, Department of Biomedical and Dental Sciences and Morphofunctional Imaging, University of Messina, Messina, Italy.

Correspondence to: Prof. Stefano Pergolizzi, Department of Biomedical and Dental Sciences and Morphofunctional Imaging, University of Messina, Messina, Viale Gazzi Policlinico Universitario, 98122, IT; **Email** stefano.pergolizzi@unime.it;

(as gross tumour volume). Patient was treated in a prone position on belly board to minimizing dose to small bowel. PET/CT images were used to delineate biological target volume for the boost volume.

Irradiation dose to whole pelvis was 45Gy in 25 fractions followed by a boost dose of 16Gy in 8 fractions on the recurrent disease, with a total dose of 61 Gy. A 3D-conformal therapy was used to minimize radiation doses to nearby critical organs, such as the femoral head, bladder, rectum and small bowel. During radiotherapy treatment the compliance was good, the patient experienced an urinary G1 toxicity, resolved with supportive care, and rectal G2 toxicity, resolved after 2 weeks of completion of radiotherapy. After 6 months, CT and MR images demonstrated a slight reduction of mass; after 12 months, ¹⁸F-FDG-PET/CT showed no evidence of metabolically active disease. After 15 months from treatment, progressive disease was recorded both in lung and bone, without evidence of local recurrence.

Ethical clearance: This paper was submitted for publication after taking approval from the Ethics Committee of University of Messina, Messina, Italy.

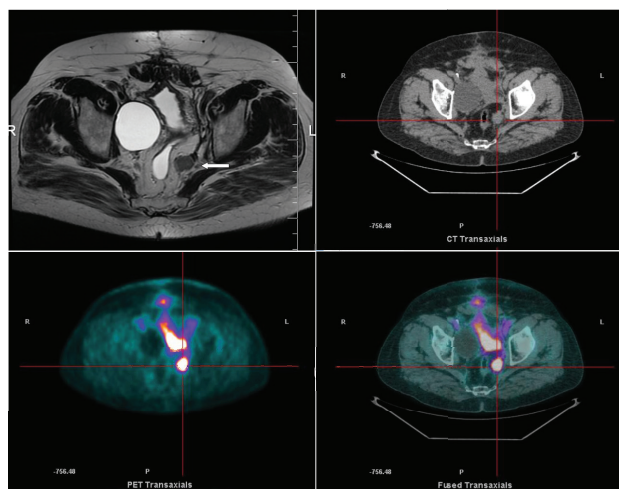


Figure 1. T2-weighted MRI showing recurrence of disease in the left pararectal space (arrow, left upper panel). ¹⁸F-FDG-PET/CT images (CT, right upper panel; PET, left lower panel; fused images, right lower panel) demonstrated high radiopharmaceutical accumulation in the site of recurrence of disease in the left pararectal space.

Discussion

Primary malignant sarcomas arising from the urinary tract and male genital tract has been defined as urological sarcomas; the most common sites of origin are paratesticular space, prostate, bladder and kidney.² Leiomyosarcoma of the seminal vesicles is exceptionally rare.¹ MRI,^{3,4} CT and ¹⁸F-FDG-PET/CT are useful tools in diagnostic workup in this

disease. Prognosis of urological leiomyosarcoma is poor due to both local and distant recurrence rates.⁵ No widely accept guidelines on treatment exist; so, patients are usually treated with radical surgical approach followed in some instances (i.e. incomplete resection and “close” margins) by adjuvant radiotherapy.⁶ A recent paper from Ball et al.⁵ seems to demonstrate that preoperative chemo- and radiotherapy could improve outcome; however, no data about the efficacy of irradiation alone are reported. At least, no definitive suggestions exist about the role of chemotherapy, both in primary and recurrent/disseminated disease; nevertheless, doxorubicin-based regimen seems to ameliorate survival rates.⁷

It is noteworthy to underline that in the present case radiotherapy was able to obtain a local complete response and it is the first time that this result is reported; perhaps, the total dose delivered (>60Gy) could explain this issue, reinforcing the role of irradiation in the management of retroperitoneal soft-tissue sarcomas. Up-to-date, both in adjuvant and preoperative setting, radiation doses of 45-50Gy have been delivered and perhaps, using the new delivering radiation techniques (Intensity-modulated, Volumetric and Stereotactic ones) associated with both advanced imaging studies⁸ and new radiosensitizing tools,^{9,10} the goal to escalated the doses over 60Gy is more feasible.

Conclusion

In conclusion, we can affirm that radiation doses greater than 60Gy, such as in other rare cancers,¹¹ could be able to control recurrent leiomyosarcoma and this therapeutic option should be keep in mind when a surgical approach is not indicated. Additional studies in systemic therapy are auspicated due to the high propensity of this kind of cancer to metastasize.

Conflict of interest: None declared.

Authors' Contributions:

Data gathering and idea owner of this study: Anna Santacaterina

Study design: Anna Santacaterina, Antonino Scimone

Data gathering: Antonino Scimone, Silvana Parisi, Nicola Settineri

Writing and submitting manuscript: Anna

Santacaterina, Angelo Platania, Grazia Acquaviva

Editing and approval of final draft: Anna Santacaterina, Stefano Pergolizzi

References:

1. Cauvin C, Moureau-Zabotto L, Chetaille B, et al. Primary leiomyosarcoma of the seminal vesicle: Case report and review of the literature. *BMC Cancer*. 2011;11:323. <https://doi.org/10.1186/1471-2407-11-323>
 2. Dagur G, Warren K, Suh Y, et al. Detecting diseases of neglected seminal vesicles using imaging modalities: A review of current literature. *Int J Reprod Biomed(Yazd)*. 2016;14(5):293–302. <https://doi.org/10.29252/ijrm.14.5.293>
 3. Gaeta M, Benedetto C, Minutoli F, et al. Use of diffusion-weighted, intravoxel incoherent motion, and dynamic contrast-enhanced MR imaging in the assessment of response to radiotherapy of lytic bone metastases from breast cancer. *Acad Radiol*. 2014;21(10):1286-1293. <https://doi.org/10.1016/j.acra.2014.05.021>
 4. Blandino A, Minutoli F, Scribano E, et al. Combined magnetic resonance urography and targeted helical CT in patients with renal colic: a new approach to reduced delivered dose. *J Magn Reson Imaging*. 2004;20(2):264-271. <https://doi.org/10.1002/jmri.20109>
 5. Ball MW, Sundi D, Reese AC, et al. Multimodal Therapy in the Treatment of Prostate Sarcoma: The Johns Hopkins Experience. *Clin Genitourin Cancer*. 2015;13(5):435-440. <https://doi.org/10.1016/j.clgc.2015.04.011>
 6. Mondaini N, Palli D, Saieva C, et al. Clinical Characteristics and Overall Survival in Genitourinary Sarcomas Treated with Curative Intent: A Multicenter Study. *Eur Urol*. 2005;47(4):468-473. <https://doi.org/10.1016/j.eururo.2004.09.013>
 7. No authors listed. Adjuvant chemotherapy for localised resectable softtissue sarcoma of adults: Meta-analysis of individual data. Sarcoma Meta-Analysis Collaboration. *Lancet* 1997;350(9092):1647–1654. [https://doi.org/10.1016/S0140-6736\(97\)08165-8](https://doi.org/10.1016/S0140-6736(97)08165-8)
 8. Conti A, Pontoriero A, Ricciardi GK, et al. Integration of functional neuroimaging in CyberKnife radiosurgery: Feasibility and dosimetric results. *Neurosurg Focus*. 2013;34(4):E5. <https://doi.org/10.3171/2013.2.FOCUS12414>
 9. Amato E, Italiano A, Pergolizzi S. Gold nanoparticles as a sensitising agent in external beam radiotherapy and brachytherapy: A feasibility study through Monte Carlo simulation. *Int J Nanotechnol*. 2013;10(12):1045-1054. <https://doi.org/10.1504/IJNT.2013.058563>
 10. Amato E, Italiano A, Leotta S, et al. Monte Carlo study of the dose enhancement effect of gold nanoparticles during X-ray therapies and evaluation of the anti-angiogenic effect on tumour capillary vessels. *J Xray Sci Technol*. 2013;21(2):237-247.
 11. Chirico G, Pergolizzi S, Mazziotti S, et al. Primary sphenoid esthesioneuroblastoma studied with MR. *Clin Imaging*. 2003;27(1):38-40. [https://doi.org/10.1016/S0899-7071\(02\)00533-8](https://doi.org/10.1016/S0899-7071(02)00533-8)
-