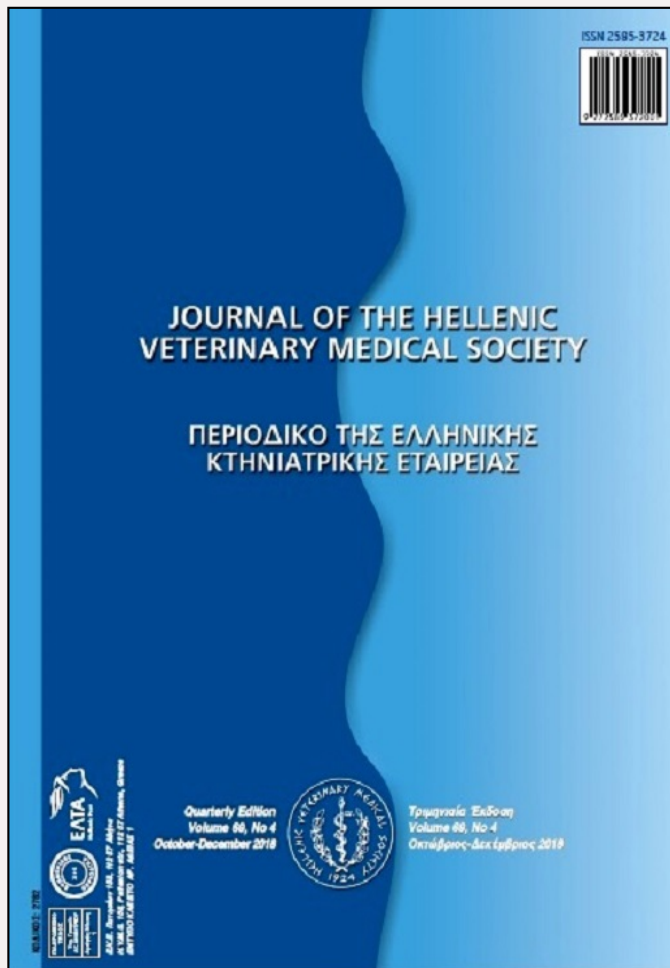

Journal of the Hellenic Veterinary Medical Society

Vol. 69, 2018



Ovarian remnant syndrome after laparoscopic ovariectomy in a cat

Properzi R. Department of Veterinary Science, University of Parma

Boschi P.

Leonardi F. University of Parma, Department of Veterinary Science

<http://dx.doi.org/10.12681/jhvms.15906>

Copyright © 2019 FABIO LEONARDI



To cite this article:

Properzi, R., Boschi, P., & Leonardi, F. (2019). Ovarian remnant syndrome after laparoscopic ovariectomy in a cat. *Journal of the Hellenic Veterinary Medical Society*, 69(4), 1305-1308. doi:<http://dx.doi.org/10.12681/jhvms.15906>

Ovarian remnant syndrome after laparoscopic ovariectomy in a cat

R. Properzi¹, P. Boschi¹, F. Leonardi²

¹*Private Practitioner, Rapallo, Italy*

²*Department of Veterinary Science, University of Parma, Parma, Italy.*

ABSTRACT. The first case of accidental implantation of ovarian tissue at the port site after laparoscopic ovariectomy in a cat was described. A 2-year-old, spayed female, domestic cat showed recurrent behavioral oestrus signs (vocalization, increased playfulness, and lordosis) four months after laparoscopic ovariectomy. Abdominal ultrasound revealed bilateral endometrial hyperplasia and an inhomogeneous mass attached to the abdominal wall at the port site of previous laparoscopic ovariectomy. Ovarian remnant syndrome was supposed. Diagnostic laparoscopy confirmed the presence of a mass that was 2 cm in diameter and macroscopically similar to ovarian tissue. Laparoscopy was converted to laparotomy to remove the abnormal tissue and the uterus. Histopathological findings showed follicles of various maturation stages in the mass, and confirmed endometrial hyperplasia. Histology underscored that ovarian remnant tissue resumed function. No clinical signs consistent with ovarian remnant syndrome were reported six months after excision of the abnormal tissue. In conclusion, removal of the ovaries through the laparoscopic port site may cause fortuitous ovarian tissue implantation at the abdominal wall in the cat.

Keywords: ovarian remnant syndrome, ORS, laparoscopy, ovariectomy, cat

Corresponding Author:

Fabio Leonardi, via del Taglio 10, Department of Veterinary Science,
University of Parma, 43126 Parma, Italy,
e-mail: fabio.leonardi@unipr.it

Date of initial submission: 2-5-2018
Date of revised submission: 30-7-2018
Date of acceptance: 4-8-2018

CASE HISTORY

A 2-year-old, spayed female, 3.6 kg domestic cat was referred for recurrent clinical signs of oestrus (vocalization, increased playfulness, and lordosis) appeared 4 months after laparoscopic ovariectomy.

The queen's vital parameters, serum biochemical parameters and complete blood count were within normal limits. No other clinical signs (i.e. inappetence, dysuria, vomiting, and diarrhea) were reported. Mild abdominal pain was detected during abdominal palpation. Abdominal ultrasound revealed bilateral endometrial hyperplasia and an inhomogeneous mass attached to the abdominal wall. This mass measuring 2 cm in diameter was medial to the left kidney, approximately 1.5 cm caudal to the umbilicus. ORS was supposed based on anamnesis, clinical signs and ultrasound examination. The owner did not give his consent to perform hormonal analysis and vaginal cytology. The queen underwent diagnostic laparoscopy performed by the same surgeon that carried out previous laparoscopic ovariectomy.

The queen was premedicated with methadone (Semfortan[®], Dechra) 0.2 mg/kg, dexmedetomidine (Dexdomitor[®], Orion Pharma Zoetis) 4 µg/kg and ketamine (Lobotor[®], Acme) 2 mg/kg combined and administered intramuscularly. Anesthesia was induced with 2 mg/kg of propofol (Proposure[®], Merial) intravenously (IV), and endotracheal intubation was performed with a cuffed tube. Anesthesia was maintained with isoflurane (Isoflo[®], Esteve) delivered in 100% oxygen via a rebreathing circuit. Ringer's lactate solution at a rate of 10 mL/kg/h was administered IV during surgery. The breathing was supported by intermittent positive pressure ventilation to maintain end-tidal carbon dioxide tension in a range of 30–40 mmHg during surgery. The queen was administered 20 mg/kg, IV, cephazoline (Cefazolina[®], Teva) every 90 minutes throughout surgery and 0.2 mg/kg, subcutaneously, meloxicam (Meloxoral[®], Ati) upon extubation.

The patient was positioned in dorsal recumbency. A 5-mm cannula (T1) (Trocar X-ONE, MedLine) was inserted 1 cm cranially to the umbilicus on midline to create pneumoperitoneum using carbon dioxide by an automatic insufflator (264305 20, Karl Storz Endoscopy) with a pressure of 5–7 mmHg, and to insert a 30° telescope (Hopkins II, Karl Storz Endoscopy). The presence of a mass, shaped like ovarian tissue,

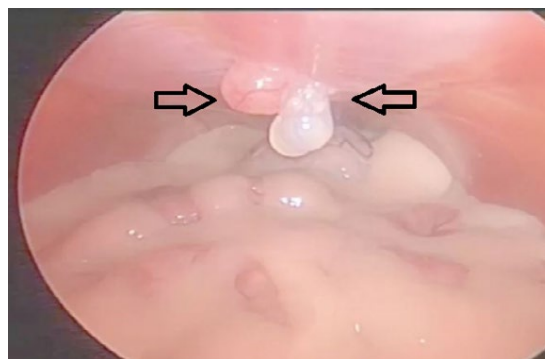


Figure 1. Laparoscopic photograph showing the presence of a mass (arrows) attached to the peritoneum

was confirmed (Fig. 1). The mass was attached to the peritoneal area caudal to the umbilicus, where the laparoscopic port was inserted to perform previous laparoscopic ovariectomy. To exclude incomplete removal of ovarian tissue, each suspensory ovarian ligament was lifted using Wolf grasping forceps (Wolf Medical Instrument, Knittlingen) introduced in a 5-mm cannula (T2) (Trocar X-ONE, MedLine) inserted 2 cm caudally to the umbilicus. During these procedures, hyperplasia of both uterine horns was underscored. Laparoscopic procedure was converted to open surgery (Fig. 2) to remove the mass (Fig. 3) and to perform hysterectomy. The abdominal wall and subcutaneous tissues were closed in a continuous pattern using, respective-

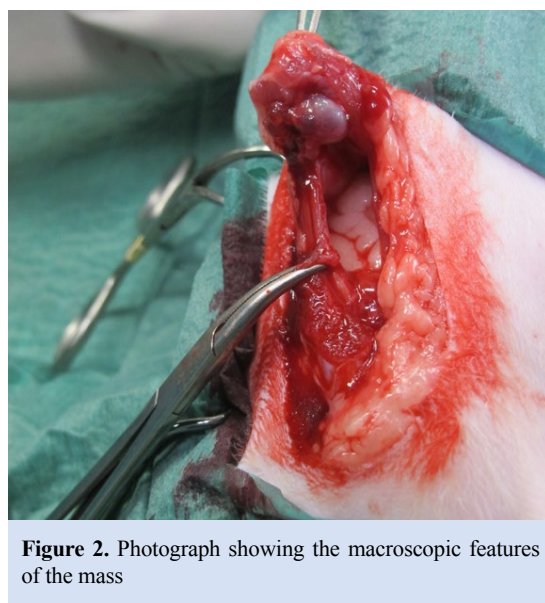


Figure 2. Photograph showing the macroscopic features of the mass

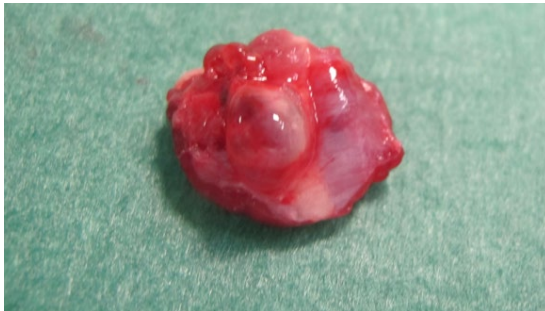

Figure 3. Photograph of the excised mass

ly, 3-0 polydioxanone (PDS[®], Ethicon) and 3-0 polyglactin 910 (Vicryl[®], Ethicon). The skin was closed in an interrupted pattern using 3-0 nylon (Assunyl[®], Assut Europe).

Recovery from anesthesia was uneventfully. The patient was discharged within 24 hours of recovery from surgery with 0.1 mg/kg, orally, SID, meloxicam (Metacam[®], Boehringer Ingelheim) and 22 mg/kg, orally, BID, amoxicillin combined to clavulanic acid (Clavaseptin[®], Vetoquinol) for seven days.

Histology of the uterus showed hyperplastic endometrium and moderately hyperplastic glandular component, with the formation of multiple cystic dilations containing eosinophil secretion. Moderate fibroplasia was observed around the proliferated glandular structures. Histopathologic studies of the mass revealed large follicles of various maturation stages (Fig. 4).

The patient did not show any clinical signs of oestrus

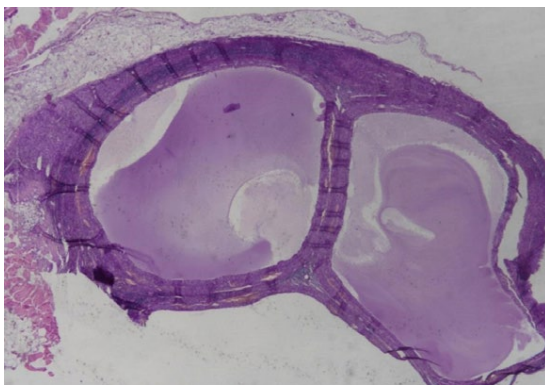


Figure 4. Photomicrograph of the excised mass. There are large follicles of various maturation stages.

in the following 6 months.

DISCUSSION

Ovarian remnant syndrome (ORS) is characterized by the presence of functional ovarian tissue after previous ovariectomy and it is considered a long-term complication of ovariectomy (Miller, 1995; DeNardo et al., 2001). ORS is commonly caused by incomplete removal of ovarian tissue, dropping of a thin piece of ovarian tissue into the abdomen, and accidental implantation of ovarian tissue (Ball et al., 2010). Remnant tissue may contain follicles, corpus lutea, luteoma and germ cells (DeNardo et al., 2001) and cats may show clinical signs of oestrus, mild abdominal pain, endometrial hyperplasia and stump pyometra (Wallace, 1991; Demirel and Acar, 2012).

In women, autograft of ovarian tissue can occur at the incision site after laparoscopic oophorectomy (Marconi et al., 1997; Chao, 2008). Surgical techniques based on laparoscopy are widely applied in dogs. Similarly, laparoscopic ovariectomy is feasible in cats (Van Nimwegen et al., 2007; Coisman et al., 2014). Compared to traditional open surgery, laparoscopic ovariectomy reduces recovery period, postoperative discomfort, pain and the incidence of infection, nevertheless some complications may occur (Van Nimwegen et al., 2007). In the veterinary literature, ORS has not been previously reported after laparoscopic ovariectomy.

The present report describes the first case of ORS after laparoscopic ovariectomy in a cat. Clinical signs of oestrus after previous ovariectomy and histopathological findings confirmed the suspected diagnosis. If ORS is supposed, vaginal cytology and hormonal assay should be performed, although the cytological and endocrine changes during feline cycle are often unpredictable (Wallace, 1991). Consequently, if clinical signs and imaging investigations suggest ORS, diagnostic laparoscopy or explorative celiotomy are recommended. Afterwards, histological findings will confirm the diagnosis of residual ovarian tissue.

This case report adds essential information about the preservation of ovarian tissue in the queen because it underscores that an unexpected and non-experimentally induced ovarian tissue implantation at the peritoneum of the abdominal wall can spontaneously revitalize

and resume function. In fact, ORS related to free ovarian tissue has been only experimentally demonstrated in the queen until today. In four cats, the ovarian cortex was implanted into the peritoneum of the abdominal wall and, after 12 weeks, all cats presented active ovarian tissue (Shemwell and Weed, 1970). Another finding reported that, in eight cats out of nine, free-floating ovarian tissue showed histopathological features of ovarian activity six months after ovariohysterectomy (DeNardo et al., 2001). In the present case report, remnant ovarian tissue resumed its function 4 months after laparoscopic ovariectomy. It is likely that a thin piece of free ovarian tissue spontaneously adhered to the peritoneum with subsequent angiogenesis into the ovarian tissue. These events were probably induced by fibroblast growth factor, transforming growth factor and vascular endothelial growth factor (Demeestere et al., 2009).

In the human literature, only three cases reported residual ovarian tissue on the abdominal wall after laparoscopic surgery (Marconi et al., 1997; Chao, 2008; Na et al., 2013). In the first case, a piece of ovarian tissue remained in the patient's abdominal wall (Marconi et al., 1997), whereas in the other two cases accidental implantation of a fragment of ovarian tissue occurred during the extraction of the ovary through the laparoscopic port (Chao, 2008; Na et al., 2013). Laparoscopic ovariectomy is commonly performed in dogs and

it is similarly feasible in cats, though some complications may occur (Van Nimwegen et al., 2007). The case described here is the first report that underscores ORS after laparoscopic ovariectomy in the veterinary literature. The origin of residual ovarian tissue has not been clearly recognized; nevertheless, it is likely that ovarian tissue may be fragmented during ovary extraction through the trocar. If the size of the ovary is large compared to the diameter of the trocar, removal of the ovary through the port is quite difficult and ovarian tissue may be fragmented. Albeit fragmentation of ovarian tissue is uncommon, it is important to adopt preventive methods as follow: large-diameters trocars, retrieval plastic bags, laparoscopic morcellator and abundant irrigation of the surgical field (Nezhat et al., 2000; Chao, 2008; Na et al., 2013).

In conclusion, the present case report underlines that accidental implantation of a thin piece of ovarian tissue on the abdominal wall is a likely long-term complication of laparoscopic ovariectomy in the cat. Ovarian remnant tissue may resume function and must be excised. Consequently, it is mandatory to take preventive methods to avoid this problem.

CONFLICT OF INTEREST STATEMENT

The authors declare no conflict of interest. ■

REFERENCES

- Ball R, Birchard SJ, May LR, Threlfall WR, Young GS (2010) Ovarian remnant syndrome in dogs and cats: 21 cases (2000-2007). *J Am Vet Med Assoc* 236: 548-553.
- Chao HS (2008) Ovarian remnant syndrome at the port site. *J Minim Invasive Gynecol* 15: 505-507.
- Coisman JG, Case JB, Shih A, Harrison K, Isaza N, Ellison G (2014) Comparison of surgical variables in cats undergoing single-incision laparoscopic ovariectomy using a ligasure or extracorporeal suture versus open ovariectomy. *Vet Surg* 43: 38-44.
- DeNardo GA, Becker K, Brown NO, Dobbins S (2001) Ovarian remnant syndrome: revascularization of free-floating ovarian tissue in the feline abdominal cavity. *J Am Anim Hosp Assoc* 37: 290-296.
- Demeestere I, Simon P, Emiliani S, Delbaere A, Englerte Y (2009) Orthotopic and heterotopic ovarian tissue transplantation. *Hum Reprod Update* 15: 649-665.
- Demirel MA, Acar DB (2012) Ovarian remnant syndrome and uterine stump pyometra in three queens. *J Feline Med Surg* 14: 913-918.
- Marconi G, Quintana R, Rueda-Leverone NG, Vighi S (1997) Accidental ovarian autograft after a laparoscopic surgery: case report. *Fertil Steril* 68: 364-366.
- Miller DM (1995) Ovarian remnant syndrome in dogs and cats: 46 cases (1988-1992). *J Vet Diagn Invest* 7: 572-574.
- Na KY, Sung JY, Won KY, Kim GY, Lim SJ, Lee SH (2013) Ovarian Remnant Syndrome at the Trochar Site: A Report of a Rare Complication Following Laparoscopic Ovarian Surgery. *Korean J Pathol* 47: 304-306.
- Nezhat CH, Seidman DS, Nezhat FR, Mirmalek SA, Nezhat CR (2000) Ovarian remnant syndrome after laparoscopic oophorectomy. *Fertil Steril* 74: 1024-1028.
- Shemwell RE, Weed JC (1970) Ovarian remnant syndrome. *Obstetrics & Gynecology* 70: 64-67.
- Van Nimwegen SA, Kirpensteijn J (2007) Laparoscopic ovariectomy in cats: comparison of laser and bipolar electrocoagulation. *J Feline Med Surg* 9: 397-403.
- Wallace MS (1991) The ovarian remnant syndrome in the bitch and queen. *Vet Clin North Am Small Anim Pract* 21: 501-517.