



New perspectives on difficult-to-treat tuberculosis based on old therapeutic approaches

Michele Mondoni^a, Stefano Centanni^a, Giovanni Sotgiu^{b,*}

^aRespiratory Unit, ASST Santi Paolo e Carlo, San Paolo Hospital, Department of Health Sciences, Università degli Studi di Milano, Milan, Italy

^bClinical Epidemiology and Medical Statistics Unit, Department of Medical, Surgical and Experimental Sciences, University of Sassari, Sassari, Italy

ARTICLE INFO

Article history:

Received 25 January 2020

Received in revised form 18 February 2020

Accepted 19 February 2020

Keywords:

Tuberculosis
Collapse therapy
Hemoptysis
Sanatorium
Sunlight
Vitamin D
Surgery

ABSTRACT

Tuberculosis (TB) is an important clinical and public health issue worldwide. Despite improved treatment success rates following the introduction of antibiotics in daily clinical practice, the expected decline in incidence has been hampered by HIV epidemics and multi- and extensively drug-resistant TB. During the pre-antibiotic era, TB therapies were mainly based on improving hygiene conditions, strengthening the immune system, and targeting the rest of the affected lungs with invasive techniques. Detailed knowledge of old non-pharmacological therapies might support physicians and researchers in the identification of new solutions for difficult-to-treat patients. We performed a narrative literature review on the main old therapeutic options prescribed for patients with TB. The main recommendations and contraindications of sanatorium therapies (i.e., bed rest, fresh air, sunlight) and pulmonary collapse techniques are reviewed, evaluating their physiological basis and their impact on patient outcomes. We report studies describing new interventional pulmonary and surgical techniques and assess new perspectives based on old medical and surgical treatments, whose potential implementation could help complicated patients.

© 2020 Published by Elsevier Ltd on behalf of International Society for Infectious Diseases. This is an open access article under the CC BY-NC-ND license (<http://creativecommons.org/licenses/by-nc-nd/4.0/>).

Introduction

Tuberculosis (TB) is an important clinical and public health issue worldwide (WHO, 2018). The economic and healthcare burden of this disease is underlined by its estimated annual incidence and mortality of 10 million persons and 1.6 million persons, respectively. The World Health Organization (WHO) has planned and recommended several global strategies to tackle TB; however, the expected decline in TB incidence has been hindered by the lack of adoption of WHO strategies at the national and local levels, and by the emergence and spread of TB/HIV co-infection and by multidrug-resistant (MDR) TB (D'Ambrosio et al., 2014; Lönnroth et al., 2015).

The availability of new anti-tuberculosis (e.g., bedaquiline, delamanid, pretomanid) and repurposed (e.g., linezolid, carbapenems) drugs has improved the treatment success rate and reduced the risk of *Mycobacterium tuberculosis* transmission associated with difficult-to-treat cases. However, pharmacological options are not available or sufficient in some low-income, high TB incidence

settings (Collaborative Group et al., 2018; Collaborative Group for the Meta-Analysis of Individual Patient Data in MDR-TB treatment–2017 et al., 2018; Mohr et al., 2018; Mbuagbaw et al., 2019; Pontali et al., 2017, 2018).

Starting in the industrial revolution, beginning around 1750, TB was associated with a high mortality toll worldwide. However, improvements in hygiene and healthcare conditions helped regions of Europe and North America to improve the epidemiological scenario (Daniel, 2006; Pezzella, 2019).

New ideas are now needed for alternative solutions, particularly in the management of difficult-to-treat and drug-resistant forms of TB. Careful evaluation of the options adopted in the past could help shape the near future.

Methods

A non-systematic, narrative literature review was conducted using PubMed as a search engine. The searches were conducted without any time restriction (inception until October 2019). In addition, an extensive private collection of old books and reports was reviewed. Epidemiological studies performed on adult human beings and written in the English, Italian, or German language were selected.

The reference lists of recent articles were used to retrieve articles and books not available in the electronic databases.

* Corresponding author at: Clinical Epidemiology and Medical Statistics Unit, Department of Medical, Surgical and Experimental Sciences, University of Sassari, Via Padre Manzella 4, Sassari, Italy.

E-mail address: gsotgiu@uniss.it (G. Sotgiu).

A short historical background

At the end of the eighteenth century, during the industrial revolution, the incidence of TB (also called "consumption") increased significantly in both Western Europe and the United States (Murray, 2004). Burgeoning industrialization favored a substantial migration of young workers from rural areas to the cities, resulting in increasingly crowded living conditions (Murray, 2004; Daniel, 2006). A large proportion of the urban population lived and worked in cold and damp dwellings and factories. Malnutrition, poor hygiene, and poor healthcare conditions were associated with a dramatic rise in TB cases. In some European cities, TB-related mortality peaked at 800–1000 per 100 000 population per year (Krause, 1928; Daniel, 2006; Grigg, 1958).

Although the incidence of TB among intellectuals and artists led to the portrayal of TB as a romantic disease, the relationship between an infectious etiology and the occurrence of the disease was demonstrated in the second half of the nineteenth century (Daniel, 2006). In 1865, Jean-Antoine Villemin, a French military surgeon, showed TB transmissibility by inoculating the purulent cavity fluid from a dead TB patient into a rabbit (Daniel, 2006; Herzog, 1998). This was confirmed in 1878 by the German physician Hermann Tappeiner, who demonstrated the airborne transmission of TB to dogs when the animals inhaled water emulsions of dried sputum from patients with pulmonary TB (Donald et al., 2018).

In 1882, the German scientist Robert Koch stated his postulates in demonstrating the etiological role of *M. tuberculosis* in TB (Murray, 2004; Daniel, 2006; Herzog, 1998).

In 1890, Robert Koch failed with his idea to introduce tuberculin, i.e., a glycerin concentrate extract of dead tubercle bacilli, as a remedy for TB (Daniel, 2006; Herzog, 1998; Martini et al., 2018a). However, in the early twentieth century, Clemens von Pirquet and Charles Mantoux showed its usefulness in screening individuals with a latent TB infection (Martini et al., 2018a). This diagnostic advance was accompanied by the discovery of X-rays (1895) by Wilhelm Conrad von Röntgen, which could assist in monitoring the course and severity of the disease (Daniel, 2006; Herzog, 1998; Martini et al., 2018a).

Despite this key scientific progress in understanding the etiology, pathogenesis, and diagnosis of TB, therapy for this disease remained ineffective (Riva, 2014). For centuries, bloodletting, purging, and leeches had been the most frequently prescribed therapies for patients with consumption. At the beginning of the nineteenth century, new chemical compounds and old herbal preparations were commonly used in an attempt to cure or relieve the symptoms. Accounts of these include cod liver oil, pills of copper sulfate, decoctions of moss, seeds of water dropwort, and inhalations of sedative or stimulant substances (vapors of tar, iodine).

The only recommendations that consistently had a modicum of success were those first reported by physicians in ancient Rome (e.g., Galen), namely adequate nutrition and fresh air (Daniel, 2006; Herzog, 1998; Riva, 2014).

Nutrition, bed rest, fresh air, and sunlight: the sanatorium movement

In the second half of the nineteenth century, European theories on the effects of climate on the prognosis of TB disease prompted the construction of sanatoria (Daniel, 2006; Herzog, 1998; Martini et al., 2018a, b; Riva, 2014; Williams, 1898; Zubiani, 1898).

The low TB prevalence in people living in mountainous areas convinced Hermann Brehmer, a physician in Prussia, to open the first high-altitude sanatorium in Görbersdorf, in Silesia, in 1854 (Daniel, 2006; Herzog, 1998). Brehmer had been a botany student

who had recovered from pulmonary TB after a stay in the Himalayas. The ecological assumption of the benefit of high altitude was supported by another prominent physician, Henri-Clermont Lombard, who in 1856 claimed that exposure to altitude-related rarefaction of air and the resultant reduction of blood oxygen tension was curative (Martini et al., 2018a, b; Riva, 2014; Williams, 1898). After the infectiousness of TB was demonstrated, sanatoria proved their further public health usefulness by isolating persons with pulmonary TB from the healthy community (Herzog, 1998; Riva, 2014; Martini et al., 2018a).

Frequent and abundant meals to address comorbid malnutrition, fresh air (i.e., aerotherapy) and bed rest, and mild physical exercise were the pillars of sanatorium therapy (Herzog, 1998; Martini et al., 2018a, b; Riva, 2014; Williams, 1898; Zubiani, 1898).

Preliminary successful results were followed by the scale-up of sanatoria, particularly in the Swiss Alps, and then in the United States, where several early sanatoria were established including Edward Livingston Trudeau's Adirondack Cottage Sanatorium at Saranac Lake, New York, and National Jewish Health in Denver, Colorado (Herzog, 1998). Unfortunately, sanatoria were expensive and not affordable for the poor, among whom the highest incidence rates were observed (Zubiani, 1898; McCarthy, 2001).

National anti-TB campaigns, which started in France and Germany, demonstrated the advantages of providing sanatorium-based therapy to socially disadvantaged population groups (Herzog, 1998; Martini et al., 2018a). In Italy, a law issued in 1927 provided for a national insurance for workers and restored the provincial anti-TB associations, 'Consorti', founded in 1919, to coordinate preventive and clinical services (Sagona, 1933; Joseph, 1938). This legislative intervention included TB training for all healthcare providers and the construction of new sanatoria and TB facilities countrywide (Martini et al., 2018a, b; Sagona, 1933; Joseph, 1938; Bonesio and Del Curto, 2011). These efforts included the construction of "Villaggio Morelli", a hospital in Sondalo in northern Italy, which was the largest sanatorium in Europe at the end of the Second World War (Figure 1A) (Bonesio and Del Curto, 2011).

Generally, only patients with mild symptoms and a potential curable disease were admitted to sanatoria, where they usually stayed for 3–6 months, or longer, if necessary, in a small proportion of cases (Martini et al., 2018; Zubiani, 1898; Bartolotti, 1933).

Bed rest, as a therapy for febrile patients, was suggested for the first time by Brehmer and his collaborator (and former patient) Peter Dettweiler, the creator of the sanatorium deck chair and of the pocket spittoon (Herzog, 1998; Bartolotti, 1933). Patients were prescribed to stay in south-facing bedrooms with wide-open windows or on sheltered open-air terraces and porches, lying down on deck chairs, using blankets during the winter months (Figure 1B, C) (Zubiani, 1898; Valtorta and Fanoli, 1907; Bartolotti, 1933; Martini et al., 2018a). When symptomatic patients became afebrile, mild exercises were carefully started under strict medical supervision (Williams, 1898; Valtorta and Fanoli, 1907; Bartolotti, 1933; Martini et al., 2018a).

In 1954, William Dock, an American physician, advanced a physiological theory as to why there was apical localization of adult pulmonary TB (Dock, 1946; Dock, 1954). Dock held that in persons who were upright, the pulmonary blood and lymph flow decreased due to gravity, and this in turn increased the mycobacterial infection and disease in the upper lobes (Dock, 1946; Murray, 2003). In theory, blood flow, more than ventilation, is affected by gravity, favoring a higher oxygen concentration in the upper regions of the lung, and resulting in growth of *M. tuberculosis* (Dock, 1946; Murray, 2003). The recumbent position enjoyed with bed rest resulted in increased blood flow to the apices and the maintenance of lymph flow and oxygen tension similar to those of the lower regions (Murray, 2003).




Figure 1. (A) The 3000-bed sanatorium “Villaggio Morelli” in Sondalo, Italy at the completion of the Second World War was the biggest in Europe. (B) (C) Typical sheltered terraces and porches at a sanatorium, with the characteristic deck chairs for aerotherapy.

Decades later, [West \(1977\)](#), using radioactive gases to study pulmonary blood flow and ventilation, demonstrated definitely that the partial pressure of oxygen in the apices was higher than that in the basal regions ([Dock, 1946](#); [Murray, 2003](#)).

However, in the treatment of pulmonary TB, the optimal number of hours per day to be spent in bed by patients was a matter of debate, with some investigators recommending that long-term exposure be avoided in order to adequately drain pulmonary secretions ([Bartolotti, 1933](#); [Martin, 1946](#)).

In the second phase of the history of sanatoria, sun exposure (i.e., heliotherapy) was implemented together with aerotherapy ([Bartolotti, 1933](#); [Greenhalgh and Butler, 2017](#)). This was prompted by the findings of a study performed by the Danish physician Niels Finsen at the end of the 19th century, who described the beneficial activity of ultraviolet (UV) light (delivered through a special carbon arc lamp with quartz filters) on a cutaneous infection (lupus vulgaris) caused by *M. tuberculosis* ([Jarrett and Scragg, 2017](#); [Scolari, 1936](#); [Palmieri, 1936](#)). In 1903, Auguste Rollier, a Swiss physician, established a sanatorium in Leysin, in Switzerland. Rollier's prescription was 15 days of sun exposure, beginning with exposure to the feet and gradually extending to the entire body surface, followed by daily 3/4-h sun baths ([Greenhalgh and Butler, 2017](#); [Jarrett and Scragg, 2017](#); [Zanoli, 1936](#); [Vacchelli, 1936](#)). Rollier's whole-body sunlight therapy was prescribed for skin and joint TB, and heliotherapy-based facilities became popular throughout Europe and the United States ([Scolari, 1936](#); [Palmieri, 1936](#); [Zanoli, 1936](#); [Vacchelli, 1936](#); [Greenhalgh and Butler, 2017](#); [Jarrett and Scragg, 2017](#)).

However, heliotherapy was recommended only for chronic extrapulmonary TB (i.e., skin, joints, neck lymphadenopathies, serosal and genitourinary tract TB), being of higher risk for those with acute pulmonary TB with fever and hemoptysis ([Howson, 1928](#); [Magrassi, 1933](#); [Scolari, 1936](#); [Palmieri, 1936](#); [Zanoli, 1936](#); [Vacchelli, 1936](#); [Roelandts, 2002](#); [Greenhalgh and Butler, 2017](#); [McCollough and Lehrer, 2018](#)).

In Northern European countries, where sun exposure was naturally limited during the winter, artificial light treatment (i.e., phototherapy) was prescribed ([Palmieri, 1936](#); [Jarrett and Scragg, 2017](#)).

Vitamin D, discovered at the beginning of the twentieth century after its isolation from animal skin and from codfish liver oil

([Norman, 2012](#)), was added to the therapeutic regimen with helio- and phototherapy, following its cutaneous activation after UV-B irradiation ([Jarrett and Scragg, 2017](#); [McCollough and Lehrer, 2018](#); [Norman, 2012](#)). Vitamin D promotes macrophage activation via toll-like receptors and interferon-gamma, and upregulates the expression of the cathelicidin genes in macrophages, leading to the production of an antimicrobial peptide (LL-37) that contributes to death of the *M. tuberculosis* organism. Vitamin D also promotes the reversal of mycobacteria-induced phagosome maturation arrest and autophagy ([Ralph et al., 2013](#); [Brighenti et al., 2018](#)).

Sun exposure also favors the release of nitric oxide from enzymatic and non-enzymatic sources of the innate immune system, which has antibiotic properties ([Greenhalgh and Butler, 2017](#); [Braverman and Stanley, 2017](#)).

However, some have argued about the real benefit of sanatorium therapies, with clinical recovery described only in those with mild disease. Long-term results were fairly disappointing, with many of the patients worsening or dying a few years after their discharge ([Alling and Bosworth, 1960](#); [Cox, 1923](#); [Daniel, 2006](#); [Grzybowski and Enarson, 1978](#); [Herzog, 1998](#); [McCarthy, 2001](#)).

Pulmonary collapse therapies

Beginning in the 1920s, artificial pneumothorax, the first and less invasive pulmonary collapse therapy, was combined with the sanatorium therapies described previously, for cases in which these therapies were not effective in controlling the disease ([Herzog, 1998](#); [Daniel, 2006](#); [Martini et al., 2018a, b](#)).

In 1888, the Italian physician Carlo Forlanini induced the first artificial pneumothorax by filling the pleural cavity with nitrogen, the absorption of which was slower than that of oxygen, injected through a mechanical tool prepared with the support of his engineer brother Enrico ([Forlanini, 1907](#); [Bottero, 1947](#); [Sakula, 1983](#)). This procedure met with academic resistance until 1912, when Forlanini demonstrated several successful cases at the Seventh International Tuberculosis Congress held in Rome ([Bottero, 1947](#); [Sakula, 1983](#)).

A volume of nitrogen equal to 200–250 ml was injected, which was followed by alternate-day administrations and then

administration every 2–3 weeks (Sakula, 1983). During this era, an American thoracic surgeon, John Benjamin Murphy, introduced larger nitrogen volumes (i.e., 1000–3000 ml) using an open technique (i.e., by incising the skin and muscle) and assessed the size of the collapsed lung with a chest X-ray (Costantini and Redaelli, 1933; Omodei Zorini et al., 1940; Sakula, 1983; Herzog, 1998).

Pneumothorax was mostly successful in cases of unilateral and rapidly worsening infiltrative, caseous, and cavitary lesions (Carpi, 1929; Carpi, 1933; De Castro, 1933; Soper, 1935).

Bilateral pneumothorax was performed for cases with bilateral forms, or in unilateral cases after infection of the contralateral lung. Notably, the lower gas volume administered in these cases allowed selective collapse of the less elastic affected lobe to be performed (Carpi, 1929; Ferrari, 1933; Soper, 1935).

The duration of a pneumothorax ranged from 1 to 3–4 years depending on the disease severity, with a long-term success rate of 35–65% (Carpi, 1929; Carpi, 1933; De Castro, 1933; Daniel, 2006).

The basic principles of collapse therapy rely on lung rest, by reducing respiratory movements, relaxing lung tissues, and decreasing cavity volumes, as well as parenchymal oxygen tension and blood flow (Carpi, 1929; Carpi, 1933; De Castro 1933; Sakula, 1983); the subsequent kinking and/or squeezing of the bronchus may explain the sputum smear conversion (Carpi, 1933; De Castro, 1933; Herzog, 1998; Murray, 2003).

Pleural adhesions could prevent lung collapse (Carpi, 1929; De Castro, 1933; Cova, 1933). In 1910, Hans Christian Jacobaeus described the use of a cystoscope to study the pleural cavity (Jacobaeus, 1910; Marchetti et al., 2011). Fibrous adhesions could be managed through thermocautery under direct vision inside the pleural space (intrapleural pneumolysis), inducing collapse of the lung without opening the chest cavity (Jacobaeus, 1916; Jacobaeus, 1922; Cova, 1927; Cova, 1928; Marchetti et al., 2011) (Figure 2A–D). This technique, known as the Jacobaeus operation, formed the basis of modern medical thoracoscopy and video-assisted thoracic surgery (VATS) (Jacobaeus, 1910; Cova, 1928; Marchetti et al., 2011).

Bernou introduced a new methodology, injecting sterile mineral or vegetable oil (paraffin, olive, cotton-seed, gomenol oil), which had long-term efficacy, avoiding the necessity of refilling (De Castro, 1933; Singer, 1936). Recommendations for oleothorax included treatment of pleuro-pulmonary fistulas or empyema occurring after a pneumothorax. It was also performed

after incomplete pneumothorax to prevent premature re-expansion or pleural adhesions (De Castro, 1933; Singer, 1936).

Extrapleural pneumolysis, extrapleural pneumothorax

Extrapleural pneumolysis, known as plompage, was suggested for patients with an apical cavity for whom pneumothorax was contraindicated due to pleural adhesions. After the resection of a portion of at least one rib, the parietal pleura was separated by blunt dissection and different materials were injected (i.e., fat, muscle, gauze, plastic balls, and mainly paraffin) (Redaelli, 1933; De Castro, 1933; Soper, 1935; Singer, 1936; Omodei Zorini et al., 1940; Omodei Zorini et al., 1948) (Figure 3A–D). This intervention could also be prescribed for bilateral lesions, and the long-term treatment success rate was 50–75% (De Castro, 1933; Soper, 1935; Singer, 1936).

Based on this surgical technique, extrapleural pneumothorax was later introduced in the late 1930s. The parietal pleura was extensively detached from the chest wall with the aim of creating an immediate lung collapse, supported by gas resupply. Patients with mild disease who refused thoracoplasty, as well as children and adolescents, were considered suitable for this therapeutic approach (Omodei Zorini et al., 1948).

Phrenicectomy/phrenico-exeresis, neurectomy, scaleniotomy, and Monaldi's tuberculous cavity aspiration

Interruption of the phrenic nerve, associated with paralysis of half of the diaphragm, was recommended in the case of a TB cavity of the lower lobe, following an incomplete or unsuccessful pneumothorax due to adhesions. It was reported that the implementation of this technique was associated with an immediate clinical recovery, with a success rate of 70%. Evulsion (phrenico-exeresis) or crushing of the nerve, for permanent or temporary (6 months) paralysis, respectively, could be performed under local anesthesia (De Castro, 1933; Redaelli, 1933; Soper, 1935; Singer, 1936).

Unilateral multiple intercostal neurectomy, frequently performed before a thoracoplasty, was characterized by the resection of intercostal nerves (from the second to the ninth/eleventh) and a reduction in chest wall mobility (Redaelli, 1933). However, in the late 1920s, intercostal nerve alcoholization (i.e., the injection of a

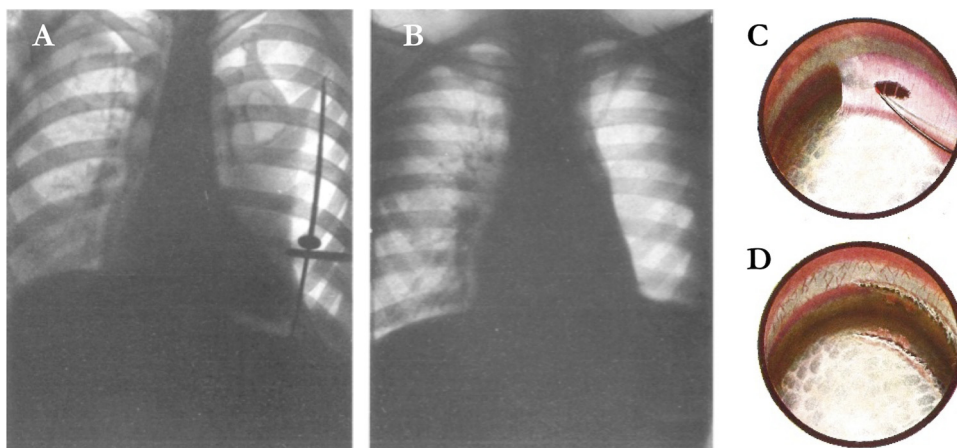


Figure 2. (A) Jacobaeus operation. Left anterolateral adhesion keeping a cavitary lung zone open. Radiographs taken during the intervention. The thoracoscope was introduced horizontally into the pleural cavity; cautery with the cutting edge applied to a pleuro-pulmonary adhesion at the point suitable for resection can be observed. (B) The same case after resection of the adhesion. Complete cavitary and pulmonary collapse may be observed. Another adhesion is still present that did not have an impact on the collapse and so it was not resected (from Cova, 1927 and Costantini and Redaelli, 1933, original description). (C) (D) Jacobaeus operation. The resection of a tent-shaped adhesion (from Cova, 1927 and from Cova, 1928, original description).

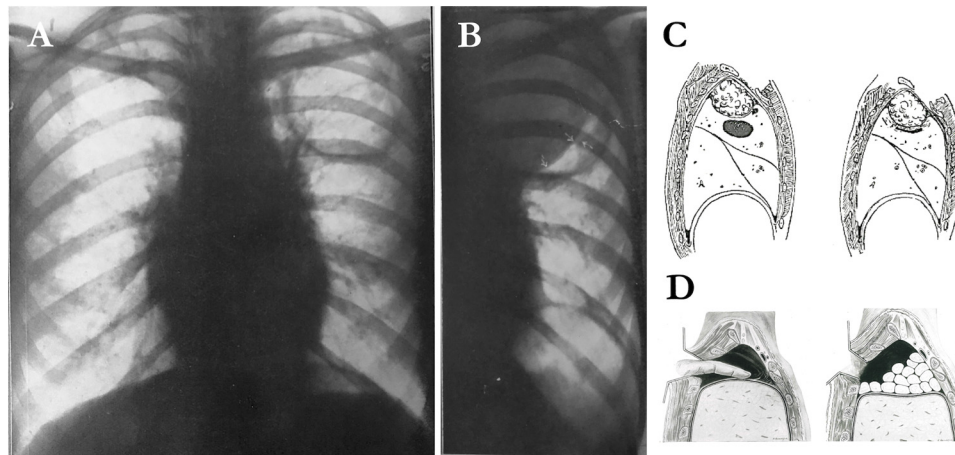


Figure 3. (A) Left pseudo-lobar isolated apical cavity. (B) The same case after paraffin plombage; the cavity edge has collapsed in on itself (arrows) (from [Omodei Zorini et al., 1940](#), original description). (C) Paraffin plombage of a cavity in the apex of the upper lobe (schematic representation) (from [De Castro, 1933](#)). (D) Detachment of the apex of the lung with the finger, and paraffin cylinders introduced into the extrapleural cavity (from [Omodei Zorini et al., 1948](#)).

few milliliters of 80–90° alcohol solution) was frequently prescribed to achieve only a 2/6-month paralysis ([Redaelli, 1933](#)).

In the early 1930s, phrenico-exeresis was performed together with scalenotomy in the case of an apical lung cavity. A section of the anterior (and sometimes of the medium and posterior) scalene muscle released the first and the second ribs to allow retraction of the lung apex ([De Castro, 1933](#); [Redaelli, 1933](#); [Soper, 1935](#)).

In 1938, the Italian physician Monaldi described a method of cavitory drainage by aspiration, for use in the case of failure of other collapse therapies ([Omodei Zorini et al., 1948](#)). A catheter was introduced into the lung cavity with a percutaneous approach, with the opposite end of the tube connected to a continuous suction apparatus. This method could be performed with or without a thoracoplasty ([Omodei Zorini et al., 1948](#)).

Thoracoplasty

Thoracoplasty, which is the most invasive collapse therapy, was first described by the Swiss surgeon De Cérenville in 1885 ([De Castro, 1933](#); [Redaelli, 1933](#); [Soper, 1935](#); [Omodei Zorini et al., 1948](#); [Odell, 2012](#)). The most frequently performed thoracoplasty of Sauerbruch, always associated with phrenico-exeresis, consisted

of extrapleural resection of the posterior segments of the eleven upper ribs without periosteum, followed by a lung volume reduction and collapse ([Sauerbruch, 1928](#)) (Figure 4A–D). It was recommended for patients with fibrous disease and with numerous pleural adhesions or in extensive chronic empyema and for young patients without cardiovascular diseases and other severe comorbidities ([Redaelli, 1933](#); [Soper, 1935](#); [Omodei Zorini et al., 1948](#); [Odell, 2012](#)). It was reported that the intervention was associated with a low mortality rate and a long-term success rate of 55–65% ([Redaelli, 1933](#); [Singer, 1936](#); [Omodei Zorini et al., 1948](#); [Herzog, 1998](#)).

In the case of localized sub-apical cavities, particularly those causing hemoptysis, a partial thoracoplasty based on the resection of a few ribs subperiosteally was successfully performed to spare the healthy pulmonary lungs ([De Castro, 1933](#); [Redaelli, 1933](#); [Singer, 1936](#); [Omodei Zorini et al., 1948](#); [Odell, 2012](#)).

Thoracic deformities associated with postoperative pain syndrome were the most frequent complications ([Singer, 1936](#); [Omodei Zorini et al., 1948](#); [Odell, 2012](#)).

All of the collapse therapies mentioned above (i.e., artificial pneumothorax, plombage, phrenico-exeresis, and partial thoracoplasty) were frequently prescribed for life-threatening and/or

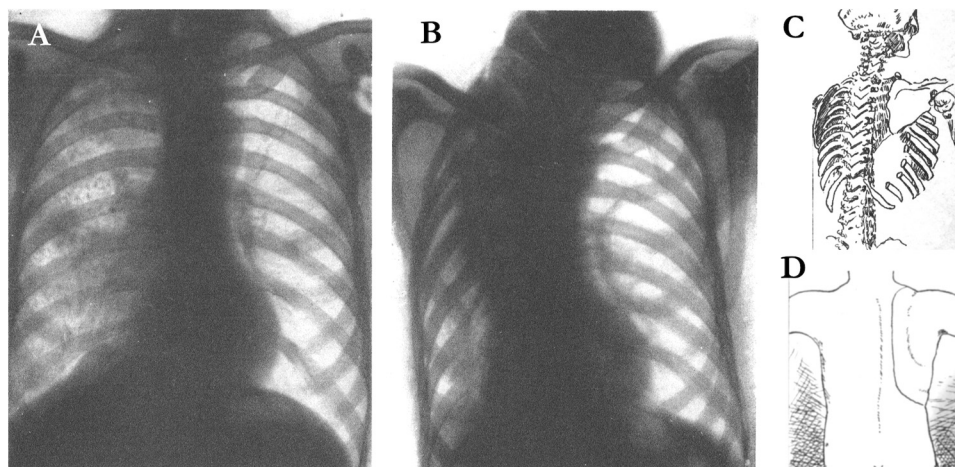


Figure 4. (A) Diffuse fibronodular infiltration of the right lung with dense sclerosis of the upper lobe. Right pleural symphysis. Vicarious hypertrophy of the left lung. (B) The same case at 8 months after the intervention (Sauerbruch thoracoplasty). Right pulmonary cirrhosis with marked vertebral column scoliosis. Pronounced rotation and fall down of the chest wall. Right lung apex elision. The distal stump of the first rib tied to the vertebral stump of the third rib. Procedure performed in one operative session (from [Costantini and Redaelli, 1933](#), original description). (D) Thoracoplasty. Skin incision line of the Sauerbruch–Wilms technique; (C) Thoracoplasty. Rib resection extension with the complete Sauerbruch–Wilms technique (from [De Castro, 1933](#), original description).

recurrent hemoptysis (Carpi, 1929; Veronesi, 1932; Carpi, 1933; De Castro, 1933; Gottardi, 1934). Notably, hemoptysis, which was deemed pathognomonic, is still a challenging symptom in Western countries. However, a recent study showed that TB is an infrequent cause of respiratory tract bleeding in Europe (Mondoni et al., 2016; Mondoni et al., 2018a).

It is difficult to assess the real success rate of all of these treatments. Indeed, no controlled studies assessed the efficacy and safety of these techniques.

Epilogue

After the Second World War, the availability of antibiotics changed the prognosis of TB dramatically (Iseman, 2002; Saltini, 2006). The concomitant discovery of the first two antimycobacterial drugs streptomycin and para-aminosalicylic acid (PAS) in 1944 and the demonstration of combination therapy to prevent drug resistance heralded a new therapeutic approach (Fox and Sutherland, 1956; Iseman, 2002; Saltini, 2006; Daniel, 2006).

At the end of the 1950s, a 12-month randomized controlled trial conducted in Madras, South India, demonstrated that household chemotherapy was equally clinically successful if compared with sanatorium hospitalization (Fox and Sutherland, 1956; Tuberculosis Chemotherapy Centre Madras, 1959; Dawson et al., 1966). Subsequently, sanatorium admissions and their related non-pharmacological therapies were progressively abandoned (Dawson et al., 1966; Iseman, 2002; Daniel, 2006).

New perspectives on old treatments

The emergence and spread of HIV epidemics and of MDR and extensively drug-resistant (XDR) TB has dramatically affected the epidemiology of TB (Getahun et al., 2010; Dheda et al., 2014). Furthermore, intensified migration flows from Africa and Eastern Europe have increased the number of TB cases in low TB incidence countries (Lönnroth et al., 2017; Sotgiu et al., 2017a, b).

Knowledge of old pharmacological and non-pharmacological treatments might be of inspiration for physicians involved in research and treatment of the disease, particularly in cases in which the current pharmacological options are ineffective. For instance, several studies have recently explored the role of vitamin D in the treatment of TB disease (Ralph et al., 2013; Jarrett and Scragg, 2017; Brighenti et al., 2018). Vitamin D deficiency can be found in a high proportion of patients with active TB, but randomized controlled trials have not proven any consistent clinical benefits, despite its immunomodulatory activity (Ralph et al., 2013; Brighenti et al., 2018). Trials of vitamin D supplementation to prevent the development of active TB need large sample sizes and long follow-up (Ralph et al., 2013; Kearns and Tangpricha, 2014; Brighenti et al., 2018).

Interestingly, a recent study showed that vitamin D deficiency was strongly associated with extrapulmonary TB (Pareek et al., 2015). On the basis of these findings, vitamin D supplementation could be kept under consideration for specific population groups, such as MDR/XDR-TB or extrapulmonary TB patients; these groups are expected to increase in Europe (Ralph et al., 2013; Sotgiu et al., 2017a, b; Mondoni et al., 2018a, b; Brighenti et al., 2018). Remarkably, individuals with extrapulmonary disease were those for whom heliotherapy and phototherapy were effective (Scolari, 1936; Palmieri, 1936; Vacchelli, 1936; Jarrett, 2017; McCullough and Lehrer, 2018).

Immediate clinical recovery in patients admitted to sanatoria was shown in cases of mild disease, following immune system strengthening (e.g., vitamin D activation, adequate nutrition, etc.) (Herzog, 1998; Daniel, 2006).

Some authors have recently debated the utility of new sanatorium-like facilities for patients with incurable XDR-TB, offering palliative care, adequate nutrition, separation of contagious patients from the community, and education on basic hygiene principles (Herzog, 1998; Daniel, 2006; Martini et al., 2018b), particularly in resource-limited, high burden countries (Dheda and Migliori, 2012).

Bed rest therapy could be a suitable option for MDR/XDR-TB patients. Although the emergence of *M. tuberculosis* strains resistant to chemical compounds has been shown since 1954, the development of mycobacterial resistance to physical interventions is unlikely (Dock, 1954).

Surgical therapy could have a role, as recently suggested by the WHO (2014). Severe empyema, localized forms of cavitary TB with continuous *M. tuberculosis* excretion, complications and sequelae of the TB process, and difficult-to-treat MDR/XDR-TB patients, could be some of the clinical indications for resective surgery in association with new and repurposed anti-TB drugs (WHO, 2014; Dara et al., 2015; Fox et al., 2016; Subotic et al., 2016; Borisov et al., 2019). Collapse interventions may be indicated for patients unfit for surgical resection due to tracheobronchial disease (i.e., infection directly involving the tracheobronchial mucosa), severe comorbidities, or poor lung function (Motus et al., 2006; Bertin et al., 2007; Dara et al., 2015; Krasnov et al., 2017; Krasnov et al., 2019; Giller et al., 2019) (Table 1).

Forlanini's artificial pneumothorax was recently described in patients with MDR-TB showing apical cavities, in whom pharmacological treatment was ineffective. In particular, Motus et al. described a >80% culture conversion in 109 cases (both new and retreated cases). No adverse events were recorded and VATS was prescribed for a few patients with pleural adhesions (Motus et al., 2006) (Table 1).

Extrapleural pneumolysis and thoracoplasty have also been assessed in a few observational studies (Bertin et al., 2007; Dara et al., 2015; Krasnov et al., 2017; Krasnov et al., 2019; Giller et al., 2019) (Table 1).

Bertin et al. (2007) described a new form of plombage based on the extrapleural placement of a percutaneous tissue expander (i.e., a silicon elastomer envelope inflated with saline solution) in a young MDR-TB patient with multiple large cavities. The lung collapse was associated with clinical recovery (i.e., improvement of symptoms, normal physical aspect of the chest wall, and no sign of local or pulmonary infection at the 30-month follow-up), and an extensive surgical resection (i.e., pneumonectomy) was avoided.

Partial thoracoplasty is performed in countries with a high MDR/XDR-TB burden (e.g., Latvia, Russian Federation) for patients with stable disease but a destructive TB process (Krasnov et al., 2017; Krasnov et al., 2019). The modern thoracoplasty approach is based on a minimally invasive technique, with few and mild adverse events (e.g., low intraoperative blood loss), and has been associated with culture conversion in the vast majority of cases (Krasnov et al., 2017; Krasnov et al., 2019). A case of successful bilateral video-assisted thoracoplasty was recently described in a young patient with bilateral fibro-cavitary XDR-TB. The patient showed clinical and functional progressive improvement and remained sputum smear-negative 4 years after surgery (Giller et al., 2019) (Table 1).

Excellent results have been reported recently with the use of innovative bronchoscopic collapse therapies to induce reversible selective lobar collapse in patients with a cavity caused by drug-resistant *M. tuberculosis* strains (Levin et al., 2016; Corbetta et al., 2016; Lalla et al., 2017; Krasnov et al., 2019) (Table 1). Recent randomized controlled trials have demonstrated favorable outcomes, i.e. bacteriological conversion in >75% of the cases of cavity closure and long-term clinical improvement in >65% of HIV-negative patients with drug-resistant TB and >80% in HIV-positive

Table 1
Summary of recent studies reporting outcomes on the use of old and new pulmonary collapse techniques in patients with pulmonary tuberculosis.

| Author Year | Country | Collapse technique | Study type | Population | Indication | Results | Adverse events |
|---------------|--------------------|---|------------|--|---|--|---|
| Motus 2006 | Russian Federation | Artificial pneumothorax | PCS | 109 cavitary TB patients (78.9% MDR-TB) | Cavity closure | 100% cavity closure (15.5% after VATS for adhesions) 90.8% culture conversion (at 10 months) | None |
| Bertin 2007 | France | Extrapleural pneumolysis (plombage) | CR | 1 patient with lung sequelae after previous MDR-TB (MT culture negative at the time of this case); MDR <i>Pseudomonas aeruginosa</i> and <i>Aspergillus</i> spp. current infection | Unilateral large multiple cavity collapse | Clinical improvement with no signs of infections at 30 days | None |
| Corbetta 2016 | Italy | Endobronchial valve placement | CS | 1 XDR-TB, 3 MDR-TB, 1 NTM, 1 TB/DRESS ^a cavitary patients | Cavity collapse | 100% cavity closure; 80% culture conversion (1 patient NR) | 1 small PNT |
| Levin 2016 | Russian Federation | Endobronchial valve placement | RCT | 102 cavitary MDR-TB patients | Cavity closure | Cavity closure (at 1 year): 67.3% valve group vs 20.7% control group (RR 2.72); patients cured (at 3 years): 80.5% valve group vs 25% control group (RR 3.44) | 4 acute bronchitis; 4 mild COPD exacerbation |
| Krasnov 2017 | Russian Federation | Minimally invasive thoracoplasty + endobronchial valve placement in 85.3% of patients | PCS | 191 cavitary TB (88.9% MDR/XDR-TB) patients | Single/multiple cavity closure | Culture conversion (at 1 year): 80.4%; Cavity closure (at 1 year): 83.2%; Patients cured (at 2 years): 88.5% | 1 severe intra-operative blood loss; 10 PNT; 1 bleeding, 3 wound infections, 6 respiratory failure; 8 pneumonia |
| | | Conventional thoracoplasty + endobronchial valve placement in 85.7% of patients | PCS | 223 cavitary TB (86.1% MDR/XDR-TB) patients | Single/multiple cavity closure | Culture conversion (at 1 year): 69.3%; Cavity closure (at 1 year): 70%; Patients cured (at 2 years): 79.7% | 69 severe intra-operative blood loss; 28 PNT; 10 bleeding; 5 wound infections; 22 respiratory failure; 12 pneumonia |
| Lalla 2017 | South Africa | Endobronchial valve placement | CR | Mechanically ventilated HIV patient with TB | Life-threatening hemoptysis | Hemoptysis-free at 6 months | None |
| Krasnov 2019 | Russian Federation | Endobronchial valve placement | RCT | 125 cavitary TB–HIV patients (60.8% MDR-TB) | Cavity closure | Cavity closure (at 1 year): 55.9% valve group vs 28.1% control group ($p = 0.0004$); Culture conversion (at 1 year): 75% valve group vs 42% control group ($p = 0.0002$) | 1 early valve migration |
| Giller 2019 | Russian Federation | Bilateral video-assisted thoracoplasty | CR | Fibro-cavitary XDR-TB patient | Multiple cavity closure | Clinical improvement and smear negativity (at 2 months) Cavity closure (at 5 months) Culture conversion up to 4 years | None |

COPD, chronic obstructive pulmonary disease; CR, case report; CS, case series; DRESS, drug reaction with eosinophilia and systemic symptoms; HIV, human immunodeficiency virus; MDR-TB, multidrug-resistant tuberculosis; MT, *Mycobacterium tuberculosis*; NR, not reported; NTM, non-tuberculous mycobacteria; PCS, prospective cohort study; PNT, pneumothorax; RCT, randomized controlled trial; RR, risk ratio; TB, tuberculosis; VATS, video assisted thoracic surgery; XDR-TB, extensively drug-resistant tuberculosis.

^a The patient was diagnosed with DRESS syndrome after 1 month of administration of the standardized regimen recommended by the World Health Organization for drug susceptible TB.

patients with destructive cavitary pulmonary TB (Levin et al., 2016; Krasnov et al., 2019).

New collapse therapies may be key for life-threatening hemoptysis, as old collapse techniques have been shown to be useful in the case of severe respiratory bleeding (Veronesi, 1932; Ferrari, 1933; Redaelli, 1933; Lalla et al., 2017). Flexible bronchoscopy and imaging techniques (i.e., computed tomography, angiography) may now accurately detect the site of the disease and localize the source of the bleeding (Mondoni et al., 2015; Lalla et al., 2017; Sferrazza Papa et al., 2017; Mondoni et al., 2017; Mondoni et al., 2019).

Bronchoscopic endobronchial valve placement was recently described in a young HIV-positive patient who was intubated and mechanically ventilated for severe TB causing life-threatening hemoptysis (refractory to two bronchial arterial embolizations) and who was unfit for surgery (Lalla et al., 2017). Once the source of the bleeding had been detected endoscopically, an endobronchial valve was implanted to induce the collapse of the affected lobe. The hemoptysis stopped and the patient was weaned from mechanical ventilation. Bleeding did not relapse for the duration of the entire hospital stay. The final outcome of this patient is unknown; it was not described in the case report. Moreover, the patient remained hemoptysis-free during the following 6 months and the valve was then successfully removed (Lalla et al., 2017).

Based on the current slow progress being made towards immediately available pharmacological therapies, these approaches should be investigated in both observational and experimental studies. New scientific evidence is needed to address the clinical and public health issue of TB. As evoked by the Latin saying '*historia est magistra vitae*', the experiments conducted in the past with few available therapeutic options could help in the investigation of new types of medical and surgical intervention, whose potential implementation could be more rapid if compared with the long process of a drug authorization. Notably, antibiotics should be administered in the case that in vitro tests show drug susceptibility.

The balance between modern technologies and old scientific ideas could be summarized in the imperative 'back to the future' to address the clinical and public health issue of difficult-to-treat TB in low and high-income countries.

Funding

This research did not receive any specific grant from funding agencies in the public, commercial, or not-for-profit sectors.

Ethical approval

Ethical approval was not needed for this review.

Conflict of interest

The authors declare no conflicts of interest.

Acknowledgements

This article is part of a supplement entitled *Commemorating World Tuberculosis Day March 24th, 2020: "IT'S TIME TO FIND, TREAT ALL and END TUBERCULOSIS!"* published with support from an unrestricted educational grant from QIAGEN Sciences Inc.

References

Alling DW, Bosworth EB. The after-history of pulmonary tuberculosis. VI. The first fifteen years following diagnosis. *Am Rev Respir Dis* 1960;81:839–49.

Bartolotti C. La terapia climatica della tubercolosi polmonare. In: Campani A, Costantini G, editors. *La fisiologia nella pratica medica*. Pubblicazione A. Wasserman & C. Milano, Cromotopia Ettore Sormani; 1933. p. 1163–86.

Bertin F, Labrousse L, Gazaille V, Vincent F, Guerlin A, Laskar M. New modality of collapse therapy for pulmonary tuberculosis sequels: tissue expander. *Ann Thorac Surg* 2007;84(3):1023–5.

Bonesio L, Del Curto D. Il Villaggio Morelli. Identità paesaggistica e patrimonio monumentale. Reggio Emilia, Edizioni Diabasis; 2011. p. 1–289.

Borisov SE, D'Ambrosio L, Centis R, Tiberi S, Dheda K, Alffenaar JW, et al. Outcomes of patients with drug-resistant-tuberculosis treated with bedaquiline-containing regimens and undergoing adjunctive surgery. *J Infect* 2019;78(1):35–9.

Bottero A. Carlo Forlanini inventore del pneumotorace artificiale. Milano: Ulrico Hoepli; 1947. p. 1–123.

Braverman J, Stanley SA. Nitric oxide modulates macrophage responses to *Mycobacterium tuberculosis* infection through activation of HIF-1 α and repression of NF- κ B. *J Immunol* 2017;199(5):1805–16.

Brightenti S, Bergman P, Martineau AR. Vitamin D and tuberculosis: where next? *J Intern Med* 2018;284:145–62.

Carpi U. La collasoterapia nella tubercolosi polmonare e nelle lesioni distruttive del polmone. Milano: Editrice Cooperativa Farmaceutica; 1929. p. 1–257.

Carpi U. Il pneumotorace artificiale di fronte alla pratica. In: Campani A, Costantini G, editors. *La fisiologia nella pratica medica*. Pubblicazione A. Wasserman & C. Milano, Cromotopia Ettore Sormani; 1933. p. 999–1036.

Collaborative Group for the Meta-Analysis of Individual Patient Data in MDR-TB treatment–2017, Ahmad N, Ahuja SD, Akkerman OW, Alffenaar JC, Anderson LF, et al. Treatment correlates of successful outcomes in pulmonary multidrug-resistant tuberculosis: an individual patient data meta-analysis. *Lancet* 2018;392(10150):821–34.

Corbetta L, Tofani A, Montinaro F, Michieletto L, Ceron L, Moroni C, et al. Lobar collapse therapy using endobronchial valves as a new complementary approach to treat cavities in multidrug-resistant tuberculosis and difficult-to-treat tuberculosis: a case series. *Respiration* 2016;92(5):316–28.

Costantini G, Redaelli M. Atlante clinico-radiologico della tubercolosi polmonare. II Edizione Bologna: Stabilimenti Poligrafici Riuniti; 1933. p. 1–206 A cura di A. Wasserman & C. Milano.

Cova F. Toracosopia, Operazione di Jacobaeus. Milano: Sperling & Kupfer; 1927.

Cova F. Atlas Thoracoscopicon. Milano: Sperling & Kupfer; 1928. p. 1–49.

Cova F. Toracosopia e Operazione di Jacobaeus (resezione delle aderenze). In: Campani A, Costantini G, editors. *La fisiologia nella pratica medica*. Pubblicazione A. Wasserman & C. Milano, Cromotopia Ettore Sormani; 1933. p. 1131–40.

Cox GL. Sanatorium treatment contrasted with home treatment. After-histories of 4,067 cases. *Br J Tuberc* 1923;17:27–30.

D'Ambrosio L, Dara M, Tadolini M, Centis R, Sotgiu G, van der Werf MJ, et al. Tuberculosis elimination: theory and practice in Europe. *Eur Respir J* 2014;43(5):1410–20.

Daniel TM. The history of tuberculosis. *Respir Med* 2006;100(11):1862–70.

Dara M, Sotgiu G, Zaleskis R, Migliori GB. Untreatable tuberculosis: is surgery the answer? *Eur Respir J* 2015;45(3):577–82.

Dawson JJ, Devadatta S, Fox W, Radhakrishna S, Ramakrishnan CV, Somasundaram PR, et al. A 5-year study of patients with pulmonary tuberculosis in a concurrent comparison of home and sanatorium treatment for one year with isoniazid plus PAS. *Bull World Health Organ* 1966;34(4):533–51.

De Castro A. Chirurgia della tubercolosi polmonare. Milano: Ulrico Hoepli Editore-Libraio della Real Casa; 1933. p. 1–215.

Dheda K, Migliori GB. The global rise of extensively drug-resistant tuberculosis: is the time to bring back sanatoria now overdue? *Lancet* 2012;379(9817):773–5.

Dheda K, Gumbo T, Gandhi NR, Murray M, Theron G, Udawadia Z, et al. Global control of tuberculosis: from extensively drug-resistant to untreatable tuberculosis. *Lancet Respir Med* 2014;2(4):321–38.

Dock W. Apical localization of phthisis; its significance in treatment by prolonged rest in bed. *Am Rev Tuberc* 1946;53:297–305.

Dock W. Effect of posture in alveolar gas tension in tuberculosis: explanation for favored sites of chronic pulmonary lesions. *AMA Arch Intern Med* 1954;94(5):700–8.

Donald PR, Diacon AH, Lange C, Demers AM, von Groote-Biddlingmeier F, Nardell E. Droplets, dust and guinea pigs: an historical review of tuberculosis transmission research, 1878–1940. *Int J Tuberc Lung Dis* 2018;22(9):972–82.

Ferrari V. Il pneumotorace bilaterale nella cura della tubercolosi polmonare. Milano: Casa Editrice Sperling & Kupfer S.A.; 1933. p. 1–146.

Forlanini C. Cura della tisi polmonare col pneumotorace prodotto artificialmente. Due conferenze tenute alla associazione sanitaria milanese. Prima conferenza. Milano: Premiato stabilimento tipo-litografico succ. Marelli; 1907. p. 1–27.

Fox W, Sutherland I. A five-year assessment of patients in a controlled trial of streptomycin, para-aminosalicylic acid, and streptomycin plus para-aminosalicylic acid, in pulmonary tuberculosis. *Q J Med* 1956;25(98):221–43.

Fox GJ, Mitnick CD, Benedetti A, Chan ED, Becerra M, Chiang CY, et al. Surgery as an adjunctive treatment for multidrug-resistant tuberculosis: an individual patient data metaanalysis. *Clin Infect Dis* 2016;62(7):887–95.

Getahun H, Gunneberg C, Granich R, Nunn P. HIV infection—associated tuberculosis: the epidemiology and the response. *Clin Infect Dis* 2010;50 Suppl 3:S201–207.

Giller DB, Giller GV, Giller BD, Papkov AV, Scherbakova GV, Koroev VV, et al. Case of video-assisted thoracoplasty application in pulmonary tuberculosis treatment. *Ann Thorac Surg* 2019; [Epub ahead of print].

Gottardi G. Terapia delle emottisi tubercolari. Belluno: Istituto Veneto Arti Grafiche; 1934. p. 1–84.

Grigg ERN. The arcana of tuberculosis with a brief epidemiologic history of the disease in the USA. *Am Rev Tuberc Pulm Dis* 1958;78:151–72.

- Greenhalgh I, Butler AR. Sanatoria revisited: sunlight and health. *J R Coll Physicians Edinb* 2017;47(3):276–80.
- Grzybowski S, Enarson DA. The fate of cases of pulmonary tuberculosis under various treatment programmes. *Bull Int Union Against Tuberc* 1978;53:70–5.
- Herzog H. History of tuberculosis. *Respiration* 1998;65(1):5–15.
- Howson CR. Heliotherapy in pulmonary tuberculosis—its possibilities and dangers. *Cal West Med* 1928;29(1):25–30.
- Iseman MD. Tuberculosis therapy: past, present and future. *Eur Respir J Suppl* 2002;36:87s–94s.
- Jacobaeus HC. Über die Möglichkeit die Zystoskopie bei Untersuchung seröser Höhlungen anzuwenden. *Munch Med Woch* 1910;57:2090–2.
- Jacobaeus HC. Endopleurale Operationen unter Leitung des Thorakoskops. *Beitr Klin Tuberk* 1916;35:1–35.
- Jacobaeus HC. The cauterization of adhesions in artificial pneumothorax therapy of tuberculosis. *Am Rev Tuberc* 1922;6:871–97.
- Jarrett P, Scragg R. A short history of phototherapy, vitamin D and skin disease. *Photochem Photobiol Sci* 2017;16(3):283–90.
- Joseph TJ. The Campaign against Tuberculosis in Italy. *Ind Med Gaz* 1938;73(9):522–5.
- Kearns MD, Tangpricha V. The role of vitamin D in tuberculosis. *J Clin Transl Endocrinol* 2014;1(4):167–9.
- Krasnov D, Krasnov V, Skvortsov D, Felker I. Thoracoplasty for tuberculosis in the twenty-first century. *Thorac Surg Clin* 2017;27(2):99–111.
- Krasnov DV, Skluev SV, Petrova YK, Skvortsov DA, Krasnov VA, Felker IG, et al. Modern collapse therapy for pulmonary tuberculosis. *Thorac Surg Clin* 2019;29(1):47–58.
- Krause AK. Tuberculosis and public health. *Am Rev Tuberc* 1928;18:271–322.
- Lalla U, Allwood BW, Sinha Roy S, Irusen EM, Koegelenberg CFN. Endobronchial valve used as salvage therapy in a mechanically ventilated patient with intractable life-threatening haemoptysis. *Respiration* 2017;93(6):436–40.
- Levin A, Sklyuev S, Felker I, Tceymach E, Krasnov D. Endobronchial valve treatment of destructive multidrug-resistant tuberculosis. *Int J Tuberc Lung Dis* 2016;20(11):1539–45.
- Lönnroth K, Migliori GB, Abubakar I, D'Ambrosio L, de Vries G, Diel R, et al. Towards tuberculosis elimination: an action framework for low-incidence countries. *Eur Respir J* 2015;45(4):928–52.
- Lönnroth K, Mor Z, Erkens C, Bruchfeld J, Nathavitharana RR, van der Werf MJ, et al. Tuberculosis in migrants in low-incidence countries: epidemiology and intervention entry points. *Int J Tuberc Lung Dis* 2017;21:624–36.
- Magrassi A. L'elioterapia naturale e artificiale. In: Campani A, Costantini G, editors. *La tisiologia nella pratica medica*. Milano: Cromotipia Ettore Sormani; 1933. p. 1187–206.
- Marchetti GP, Pinelli V, Tassi GF. 100 years of thoracoscopy: historical notes. *Respiration* 2011;82(2):187–92.
- Martin A. Bed rest in tuberculosis. *Mod Hosp* 1946;66:102–4.
- Martini M, Besozzi G, Barberis I. The never-ending story of the fight against tuberculosis: from Koch's bacillus to global control programs. *J Prev Med Hyg* 2018a;59(3):E241–7.
- Martini M, Gazzaniga V, Behzadifar M, Bragazzi NL, Barberis I. The history of tuberculosis: the social role of sanatoria for the treatment of tuberculosis in Italy between the end of the 19th century and the middle of the 20th. *J Prev Med Hyg* 2018b;59(4):E323–7.
- Mbuagbaw L, Guglielmetti L, Hewison C, Bakare N, Bastard M, Caumes E, et al. Outcomes of bedaquiline treatment in patients with multidrug-resistant tuberculosis. *Emerg Infect Dis* 2019;25(5):936–43.
- McCarthy OR. The key to the sanatoria. *J R Soc Med* 2001;94(8):413–7.
- McCullough PJ, Lehrer DS. Vitamin D, cod liver oil, sunshine, and phototherapy: safe, effective and forgotten tools for treating and curing tuberculosis infections — a comprehensive review. *J Steroid Biochem Mol Biol* 2018;177:21–9.
- Mohr E, Hughes J, Reuter A, Trivino Duran L, Ferlazzo G, Daniels J, et al. Delamanid for rifampicin-resistant tuberculosis: a retrospective study from South Africa. *Eur Respir J* 2018;51(6).
- Mondoni M, D'Adda A, Terraneo S, Carlucci P, Radovanovic D, Di Marco F, et al. Choose the best route: ultrasound-guided transbronchial and transesophageal needle aspiration with echobronchoscope in the diagnosis of mediastinal and pulmonary lesions. *Minerva Med* 2015;106(5 Suppl 1):13–9.
- Mondoni M, Sferazza Papa GF, Sotgiu G, Carlucci P, Pellegrino GM, Centanni S. Haemoptysis: a frequent diagnostic challenge. *Eur Respir J* 2016;47(1):348–50.
- Mondoni M, Repossi A, Carlucci P, Centanni S, Sotgiu G. Bronchoscopic techniques in the management of patients with tuberculosis. *Int J Infect Dis* 2017;64:27–37.
- Mondoni M, Carlucci P, Job S, Parazzini EM, Cipolla G, Pagani M, et al. Observational, multicentre study on the epidemiology of haemoptysis. *Eur Respir J* 2018a;51(1).
- Mondoni M, Viganò O, Ferrarese M, Bimbatti M, Cavallini M, Codecasa L, et al. Haemoptysis and fever in a young refugee from Somalia. *Int J Infect Dis* 2018b;77:57–60.
- Mondoni M, Carlucci P, Cipolla G, et al. Bronchoscopy to assess patients with hemoptysis: which is the optimal timing?. *BMC Pulm Med* 2019;19(1):36.
- Motus IY, Skorniakov SN, Sokolov VA, Egorov EA, Kildyusheva EI, Savel'ev AV, et al. Reviving an old idea: can artificial pneumothorax play a role in the modern management of tuberculosis?. *Int J Tuberc Lung Dis* 2006;10(5):571–7.
- Murray JF. Bill Dock and the location of pulmonary tuberculosis: how bed rest might have helped consumption. *Am J Respir Crit Care Med*. 2003;168(9):1029–33.
- Murray JF. Mycobacterium tuberculosis and the cause of consumption: from discovery to fact. *Am J Respir Crit Care Med* 2004;169(10):1086–8.
- Norman AW. The history of the discovery of vitamin D and its daughter steroid hormone. *Ann Nutr Metab* 2012;61(3):199–206.
- Odell JA. The history of surgery for pulmonary tuberculosis. *Thorac Surg Clin* 2012;22(3):257–69.
- Omodei Zorini A, Scorpati G, Cerutti G. Atlante anatomico-radiologico della tubercolosi polmonare. Roma: "Universitas" Società Editrice; 1940. p. 1–307.
- Omodei Zorini A, Biancalana L, Di Paola N, Ruggieri E. Terapia chirurgica della tubercolosi polmonare. Roma: Società Editrice Universo; 1948. p. 1–715.
- Palmieri GC. Attinoterapia, Roentgenoterapia, Radioterapia. In: Donati M, editor. *La tubercolosi extrapulmonare*. Pubblicazione A. Wasserman & C. Milano, Cromotipia Ettore Sormani; 1936. p. 345–99.
- Pareek M, Innes J, Sridhar S, Grass L, Connell D, Wolmann G, et al. Vitamin D deficiency and TB disease phenotype. *Thorax* 2015;70(12):1171–80.
- Pezzella AT. History of pulmonary tuberculosis. *Thorac Surg Clin* 2019;29(1):1–17.
- Pontali E, D'Ambrosio L, Centis R, Sotgiu G, Migliori GB. Multidrug-resistance tuberculosis and beyond: an updated analysis of the current evidence on bedaquiline. *Eur Respir J* 2017;49: pii: 1700146; doi:10.1183/13993003.00146-2017.
- Pontali E, Sotgiu G, Tiberi S, Tadolini M, Visca D, D'Ambrosio L, et al. Combined treatment of drug-resistant tuberculosis with bedaquiline and delamanid: a systematic review. *Eur Respir J* 2018;52(1).
- Ralph AP, Lucas RM, Norval M. Vitamin D and solar ultraviolet radiation in the risk and treatment of tuberculosis. *Lancet Infect Dis* 2013;13(1):77–88.
- Redaelli M. Le cure chirurgiche nelle tubercolosi polmonare. In: Campani A, Costantini G, editors. *La tisiologia nella pratica medica*. Pubblicazione A. Wasserman & C. Milano, Cromotipia Ettore Sormani; 1933. p. 1055–130.
- Riva MA. From milk to rifampicin and back again: history of failures and successes in the treatment for tuberculosis. *J Antibiot* 2014;67(9):661–5.
- Roelands R. The history of phototherapy: something new under the sun?. *J Am Acad Dermatol* 2002;46:926–30.
- Sagona L. L'organizzazione antitubercolare in Italia. In: Campani A, Costantini G, editors. *La tisiologia nella pratica medica*. Pubblicazione A. Wasserman & C. Milano, Cromotipia Ettore Sormani; 1933. p. 1513–46.
- Sakula A. Carlo Forlanini, inventor of artificial pneumothorax for treatment of pulmonary tuberculosis. *Thorax* 1983;38(5):326–32.
- Saltini C. Chemotherapy and diagnosis of tuberculosis. *Respir Med* 2006;100(12):2085–97.
- Sauerbruch F. *Chirurgie der Brustorgane*. Berlin, Heidelberg: Springer-Verlag; 1928.
- Scolari EG. Tubercolosi cutanee propriamente dette. In: Donati M, editor. *La tubercolosi extrapulmonare*. Pubblicazione A. Wasserman & C. Milano, Cromotipia Ettore Sormani; 1936. p. 515–63.
- Singer JJ. Collapse therapy in pulmonary tuberculosis. *Cal West Med* 1936;45(2):120–5.
- Sferazza Papa GF, Mondoni M, Volpicelli G, Carlucci P, Di Marco F, Parazzini EM, et al. Point-of-care lung sonography: an audit of 1150 examinations. *J Ultrasound Med* 2017;36(8):1687–92.
- Soper WB. A present view of collapse therapy in pulmonary tuberculosis. *Yale J Biol Med* 1935;7(4):291–303.
- Sotgiu G, Dara M, Centis R, Matteelli A, Solovic I, Gratzou C, et al. Breaking the barriers: migrants and tuberculosis. *Presse Med* 2017a;46:e5–e11.
- Sotgiu G, Falzon D, Hollo V, Ködmön C, Lefebvre N, Dadu A, et al. Determinants of site of tuberculosis disease: an analysis of European surveillance data from 2003 to 2014. *PLoS One* 2017b;12(11):e0186499.
- Subotic D, Yablonskiy P, Sulis G, Cordos I, Petrov D, Centis R, et al. Surgery and pleuro-pulmonary tuberculosis: a scientific literature review. *J Thorac Dis* 2016;8(7):E474–85.
- Tuberculosis Chemotherapy Centre Madras. A concurrent comparison of home and sanatorium treatment of pulmonary tuberculosis in South India. *Bull World Health Organ* 1959;21:51–144.
- Vacchelli S. Elio-climatoterapia nei sanatori montani. In: Donati M, editor. *La tubercolosi extrapulmonare*. Pubblicazione A. Wasserman & C. Milano, Cromotipia Ettore Sormani; 1936. p. 400–14.
- Valtorta M, Fanoli G. *La tubercolosi*. Milano: Ulrico Hoepli Editore-libraio della Real Casa; 1907. p. 1–291.
- Williams CT. A lecture on the open-air treatment of pulmonary tuberculosis as practiced in German sanatoria: delivered at the hospital for consumption and diseases of the chest, Brompton. *Br Med J* 1898;1(1951):1309–11.
- Veronesi E. Trattamento d'urgenza delle emottisi tubercolari. *Rivista Medica*. Milano: Archetipografia di Milano; 1932. p. 1–12.
- West JB. *Ventilation/perfusion flow and gas exchange*. 3rd ed. Oxford: Blackwell Scientific; 1977. p. 38–48.
- WHO Regional Office for Europe. The role of surgery in the treatment of pulmonary TB and multidrug- and extensively drug-resistant TB. Copenhagen: WHO Regional Office for Europe; 2014.
- World Health Organization. *Global tuberculosis report 2018*. Geneva: World Health Organization; 2018 Document WHO/CDS/TB/2018.20 Licence: CC BY-NC-SA 3.0 IGO.
- Zanoli R. Elio-climatoterapia nei sanatori marini. In: Donati M, editor. *La tubercolosi extrapulmonare*. Pubblicazione A. Wasserman & C. Milano, Cromotipia Ettore Sormani; 1936. p. 400–14.
- Zubiani A. *La cura razionale dei tisiici e i sanatori*. Milano: Ulrico Hoepli Editore-Libraio della Real Casa; 1898. p. 1–64.