

# Injection therapy in hip osteoarthritis: one year in review

Mirian De Souza,<sup>1,2</sup> Alessandro Sinelli,<sup>1,2</sup> Orazio De Lucia<sup>1</sup>

<sup>1</sup>Department of Rheumatology and Clinical Sciences, Clinical Rheumatology Unit, ASST G. Pini-CTO, Milan; <sup>2</sup>Department of Clinical Science and Community Health, University of Milan, Milan, Italy

## Abstract

Hip osteoarthritis affects a substantial and growing number of people worldwide. Its incidence and prevalence are increasing due to ageing and obesity. It is estimated that it affects between 10 and 18% of individuals over 60 years of age and up to 1 in 3 patients over the age of 85 with a substantial proportion of them experiencing persistent pain, loss of function and decline in health-related quality of life. Our work was aimed at updating the latest data on this field.

We searched the following terms on PubMed: 'injection therapy', 'osteoarthritis' and 'hip'. We limited our search to the period from 1-1-2018 until 22-6-2019 and to the English language. We retrieved 31 works. We decided to divide the works into three groups: hyaluronic acid in hip OA, other therapies in hip OA and emerging radiological techniques to measure the efficacy of injection therapy.

So far, in the literature there is no solid evidence that supports the efficacy of intra-articular infiltration therapies in hip osteoarthritis. The international guidelines reflect this lack of solid scientific evidence. We believe that only original works that show high-level evidence can highlight the benefits of these therapies.

## Introduction

Osteoarthritis (OA) is a chronic disease characterized by joint pain, stiffness and swelling, which affects mainly hands, knees and

hips. In this review we focused on hip osteoarthritis, which affects a substantial and growing number of people worldwide. Its incidence and prevalence are increasing due to ageing and obesity. It is estimated that it affects between 10 and 18% of individuals over 60 years of age and up to 1 in 3 patients over the age of 85,<sup>1</sup> with a substantial proportion of them experiencing persistent pain, loss of function and decline in health-related quality of life.<sup>2</sup> In the latest years many treatments have emerged with the aim of reducing pain, disability and delaying hip arthroplasty.

## Materials and Methods

We searched the following terms on PubMed: 'injection therapy', 'osteoarthritis' and 'hip'. We limited our search to the period from 1-1-2018 until 22-6-2019 and to the English language. We retrieved 18 works (Figure 1). We decided to divide the works into three groups: hyaluronic acid in hip OA, other therapies in hip OA and emerging radiological techniques to measure the efficacy of injective therapy.

Among the pharmacological options currently available for the treatment of hip osteoarthritis, the most commonly used are intra-articular corticosteroid and hyaluronate injections. However, other therapeutic options have emerged in recent years, including platelet-rich plasma, stem cell therapy and botulinum toxin (Table 1).

We provide here an analytic report of the works retrieved and divided by the different types of substances.

## Intra-articular hyaluronic acid

Hyaluronic acid (HA) is a constituent of the synovial fluid in normal joints and is synthesized by chondrocytes and synoviocytes. It has a chondroprotective and anti-inflammatory effect.<sup>3</sup> In osteoarthritis there is a reduction both in the quantity and in the molecular weight of hyaluronic acid. Over the last few years, different formulations of hyaluronic acid with different molecular weights have been developed for the treatment of osteoarthritis.

The therapeutic effects of viscosupplementation in knee osteoarthritis are still controversial,<sup>4</sup> and are even more controversial in symptomatic hip osteoarthritis.

Clementi *et al.*<sup>5</sup> in a prospective, randomized, comparative study, investigated the efficacy of intra-articular injections of an ultra-high molecular weight viscosupplement with a medium molecular weight hyaluronan in 50 patients affected by hip OA. The patients were randomly assigned to two different treatment groups. Patients in the first group received 2-dose intra-articular injections of Medium Molecular Weight (MMW)-HA solution. The treatment was repeated after 3–4 weeks. Patients in the second group received

Correspondence: Orazio De Lucia, ASST Centro Traumatologico Ortopedico G.Pini-CTO, Piazza Cardinal Ferrari 1, 20122 Milano, Italy. Tel.: +39.02.58296.1.

E-mail: orazio.delucia@asst-pini-cto.it

Key words: Hip osteoarthritis; injection; hyaluronic acid; steroid injection.

Contributions: all the authors contributed equally to the review of the literature and to the writing of the present article.

Received for publication: 31 July 2019.

Revision received: 23 December 2019.

Accepted for publication: 9 April 2020.

©Copyright: the Author(s), 2020

Licensee PAGEPress, Italy

Beyond Rheumatology 2020; 2:22

doi:10.4081/br.2020.22

This article is distributed under the terms of the Creative Commons Attribution Noncommercial License (by-nc 4.0) which permits any noncommercial use, distribution, and reproduction in any medium, provided the original author(s) and source are credited.

1-dose intra-articular injections of Ultra High Molecular Weight (UHMW)-HA. The two groups of patients were matched for age, gender, side affected and body mass index. All injections in both groups were unilateral. No significant difference was found between the two groups in terms of Visual Analogue Scale (VAS) score, Western Ontario and McMaster Universities Osteoarthritis Index (WOMAC) and Lequesne index preoperatively or at 1, 3, 6 and 12 months after viscosupplementation. The authors concluded that UHMW viscosupplement is a safe and effective treatment for hip osteoarthritis. A single dose was as effective as two doses of MMW hyaluronan, resulting in similar reductions in pain and disability. The main limitation of this study was the lack of a placebo group and the sample size, which was too small to draw accurate conclusions. Furthermore, the follow-up period of 1 year did not allow an assessment to be made of whether treatment with UHMW-HA determined a delay in the need for total hip arthroplasty.

Brander *et al.*<sup>6</sup> performed a multicenter, double-blind, parallel-group, saline placebo-controlled randomized study that compared the efficacy of single image-guided hyaluronic acid (hylan G-F 20) to saline in subjects with mild-to-moderate primary hip OA. In this study a significant improvement was achieved in walking pain, hip pain, and self-assessment up to 6 months in both groups without significant differences between HA and saline group. Although the treatment effects observed in this study were significant, the authors concluded that also saline performed well as a treatment. The merits of this study are a high number of patients (357 patients), and the design as a multicentric RCT trial. A flaw of the study is the short follow up (6 months).

As regards this topic, we can say that several studies described the injected placebo as a very effective OA treatment with a relevant effect size.<sup>7</sup> There is a very elegant review by Bannuru *et al.*<sup>8</sup> where the authors analyzed 149 studies including more than 39.000 participants, incorporating both active treatments and alternative routes of placebo administration, but focusing exclusively on knee osteoarthritis. Nevertheless, some interesting considerations could be extended to the hip. The purpose of this study was not to determine the presence *versus* absence of an absolute placebo effect, but rather to determine the relative effects of different placebo interventions. The findings of the authors agreed with the conclusions by Zhang<sup>7</sup> *et al.* that intra-articular and topical placebos have broader effects than oral placebos on pain in patients with osteoarthritis. Zhang, however, compared uncontrolled case series, exposing his work to numerous biases; therefore, Bannuru's findings, which used most information from the randomized controlled trials, are described as more robust. A limitation was the scarcity of direct evidence from comparing different placebo interventions. In fact, only one randomized trial compared oral *versus* topical placebo. Moreover, they could not rule out the psychological therapeutic effect of the patient–healthcare provider relationship, when calculating the effect of placebos, which may be largely independent of any placebo intervention. The conclusion was that placebos were not equal. Some of them could trigger clinically relevant responses. Differential placebo effects could substantially alter estimates of the relative efficacies of active treatments. This is a very important consideration for the design of clinical trials and interpretation of their results.

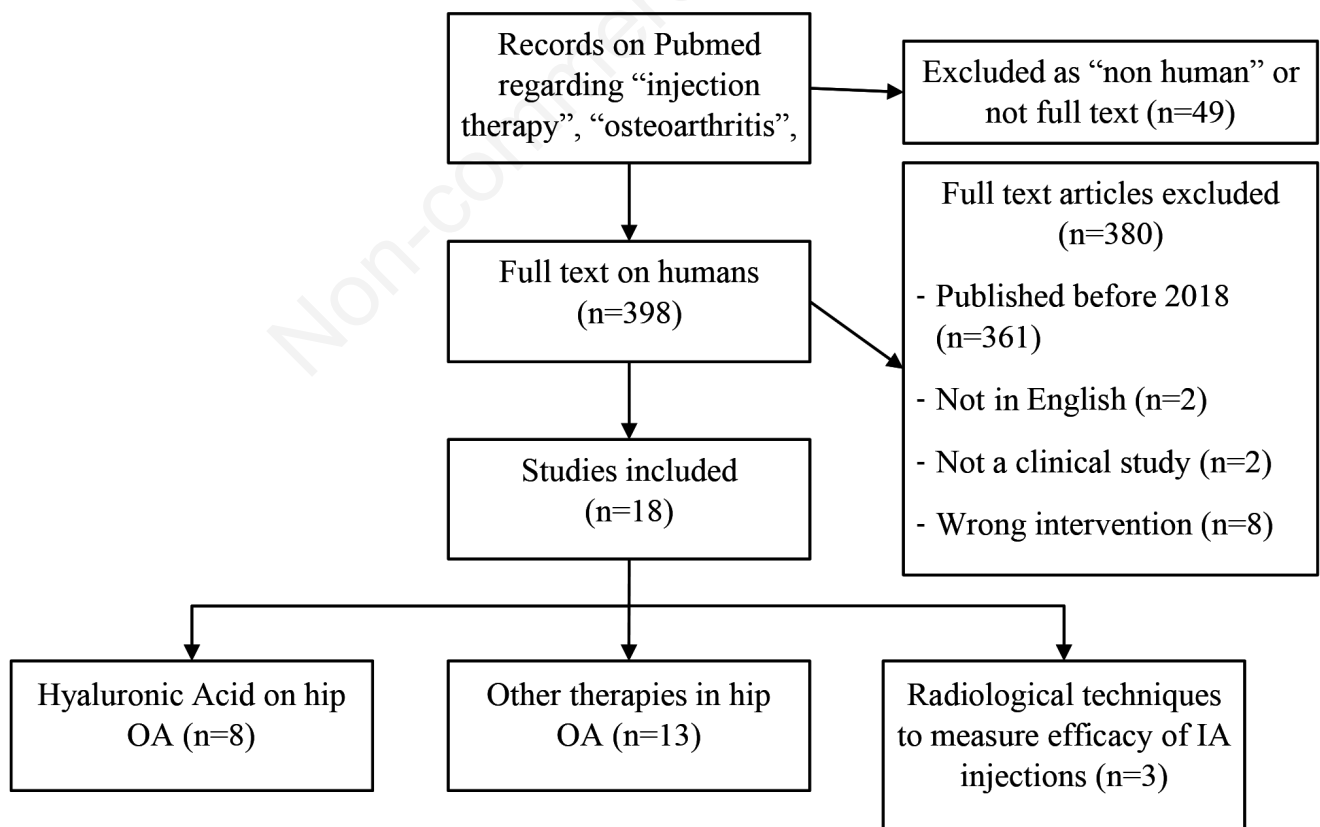


Figure 1. Flow chart of the research work conducted (some studies consider more than one product).

In a prospective observational study Pogliacomi *et al.*<sup>9</sup> evaluated the efficacy of an ultrasound-guided intra-articular (IA) hip injection of a single dose of high molecular weight hyaluronic acid (2.5% sodium hyaluronate) in patients affected by painful hip OA. Inclusion criteria were mono or bilateral hip OA (Kellgren-Lawrence stage 1-2-3), good or full joint mobility and hip disease persisting for at least 3 months. Patients with severe hip OA were excluded due to the difficulty to recognize the joint space the X-rays (Kellgren-Lawrence stage 4). During a 1-year follow up, no patients underwent hip surgery or needed additional IA injection of HA. No adverse effects were reported. An improvement in WOMAC scale and Harris Hip Score was observed in all patients after treatment. Patients with a moderate grade of osteoarthritis (Kellgren-Lawrence stage 2) had the greatest benefits from viscosupplementation. In this study there was no placebo control group.

Several meta-analyses evaluated the efficacy of intra-articular hyaluronic acid *versus* other substances. Ye *et al.*<sup>10</sup> in a meta-analysis of randomized controlled trials compared the efficacy of intra-articular injections of HA and platelet-rich plasma (PRP) for the treatment of hip osteoarthritis. This meta-analysis showed that PRP and HA

were both effective in reducing pain at 2 months, without significant differences in terms of outcome after 6 and 12 months. However, there are some limitations to this meta-analysis, like the heterogeneity of doses, products used and the small number of patients evaluated in single studies. Another meta-analysis was performed by Leite *et al.*<sup>11</sup> to assess the efficacy of viscosupplementation on pain and disability in hip OA and the occurrence of related adverse events (AEs) compared with other active substances (PRP, steroids and mepivacaine) or placebo, all administered by intra-articular injections. The authors hypothesized that viscosupplementation was more efficacious than placebo and not superior to the other substances. The results showed that HA was not superior to placebo for AEs and not superior to methylprednisolone for all outcomes. Moreover, HA was not superior to PRP in pain reduction at 6 and 12 months, even if the level of evidence was very low.

There was a previous single study comparing HA and mepivacaine<sup>12</sup> that showed that HA was superior to mepivacaine in reducing VAS pain and Lequesne index at 3 and 6 months. The authors suggested that viscosupplementation should be considered a therapeutic option for patients affected by hip OA.

**Table 1. List and brief report of the studies analysed.**

First Author	Products analyzed	Number of patients	Type of study	Results
Leite	Hyaluronic acid (HA) vs Placebo	4 RCT	Meta analysis of RCTs	HA not superior to placebo for pain at 3 months
Leite	HA vs Platelet Rich Plasma (PRP)	3 RCT	Meta analysis of RCTs	HA not superior to PRP for pain at 1 month
Leite	HA vs Methylprednisolone (MPDN)	3 RCT	Meta analysis of RCTs	HA not different from MPDN for pain at 1 month and AEs
Leite	HA vs Mepivacaine	1 RCT	RCT	HA not recommended
Lai	Methylprednisolone + Ropivacaine	78 patients	Retrospective	Not effective in long term on pain relief
Ebell	Steroid	Not specified	Review of literature	IA steroid effective in short term on function and pain relief
Ebell	HA	Not specified	Review of literature	IA HA ineffective
Courseau	Botulinum Toxin	6 studies (382 patients)	Meta analysis	Botulinum Toxin effective in short term on NRS pain
Clementi	HA (UHMW, MMW)	50 patients	RCT	HA safe and effective on pain and disability
Ye	PRP vs HA	4 RCT (303 patients)	Meta analysis of RCTs	PRP better than HA on VAS pain at 2 months
Ferrero	HA on MRI cartilage	49 patients (hip)	<i>In vivo</i> evaluation	Correlation between T2 relaxation times on MRI after HA injection and pain reduction in grade II-III chondropathy at 3 months
Paskins	Steroid+anaesthetic	204 patients	RCT	Ongoing
Tassara	Autologous conditioned serum (ACS)	3 patients (hip)	Retrospective	Number of patients too low to evaluate effectiveness
Walter	Steroid	113 patients	Retrospective	No change in Patient Reported Outcomes (PROs) up to 6 months
Steer	Steroid	97 patients	Observational	WOMAC pain, function, and stiffness scores improvement at 2 months
Brander	Hylan G-F 20 vs Saline placebo	357 patients	Double-blind randomized	Significant pain and function improvements up to 6 months; no differences between HA and saline placebo
Pogliacomi	2.5% sodium hyaluronate	226 patients	1-year observational	No patients underwent hip surgery, no AE, improvement in WOMAC and HHS. Best results in Kellgren grade 2
Hess	Steroid	109 patients	Retrospective	21 cases of rapidly destructive osteoarthritis (RDOA). Risk factors: elderly people, more severe OA, "white people"
Northumbria	PRP	3 RCT (115 patients)	Meta analysis of RCTs	US-guided PRP injections may be efficacious in long-term and clinically significant pain reduction
Darrow	Bone Marrow Concentrate (BMC)	4 patients	Case series	Decreased pain and improved functionality compared with baseline
Eleopra	AbobotulinumtoxinA (Dysport®) vs Placebo	46 patients	Prospective randomized double-blind	At Week 4 HHS and VAS score significantly improved compared to placebo
Deseyne	HA (HAnox-M-XL)	60 patients	Observational	Lower HIMRISS (hip MRI inflammatory scoring system) femoral BML and HIMRISS total score predict better responses

In the past years many authors tried to evaluate whether hip viscosupplementation with HA can decrease pain compared to placebo or other agents, how long the pain relief effect lasts, and whether one of the HA formulations is clearly superior in pain relief.<sup>13</sup> The overall quality of the data was however insufficient to determine the real clinical reduction seen in VAS pain.

Another elegant meta-analysis<sup>14</sup> suggested that intra-articular HA in hip OA is safe and can significantly reduce pain and improve functional recovery. However, no significant differences between HA and saline or other treatments were seen.

The 2012 American College of Rheumatology (ACR)<sup>15</sup> and the 2019 Osteoarthritis Research Society International (OARSI) guidelines<sup>16</sup> for management of hip OA do not recommend intra-articular HA, because only very few hip-specific RCTs have been published so far. According to OARSI, the main treatments recommended for hip OA are non-pharmacologic interventions. Also, the American Academy of Orthopaedic Surgeons (AAOS)<sup>17</sup> guidelines do not recommend the use of intra-articular HA in hip OA, because it does not perform better than placebo in terms of function, stiffness, and pain in patients with symptomatic osteoarthritis of the hip.

The recommendations of the European Viscosupplementation Consensus Group (EUROVISCO)<sup>18</sup> is to treat with viscosupplementation patients with mild to moderate knee and hip OA, with normal weight or moderate overweight, who did not improve sufficiently with first-line therapies (analgesics, nonsteroidal anti-inflammatory drugs and nonpharmacological therapies), or do not wish to take an oral treatment or have contraindications to analgesics. The group considered the patient's wishes as a key element in therapeutic decision making.

## Intra-articular corticosteroid

The evidence supporting the use of intra-articular corticosteroid injection for hip OA is limited. Some studies tried to evaluate the real clinical benefits of intra-articular corticosteroid injection in patients with moderate-severe hip OA.

A randomized trial<sup>19</sup> is still investigating the clinical and cost effectiveness of corticosteroid injections in reducing pain in patients with hip OA. In this trial 204 patients with moderate-to-severe hip OA were randomized on an equal basis (1:1:1 ratio) to one of three interventions: i) best current treatment (paracetamol, NSAIDs, opiates and exercise therapy), ii) best current treatment plus ultrasound-guided intra-articular hip injection of corticosteroid (triamcinolone acetonide 40 mg) with 1% lidocaine hydrochloride; or iii) best current treatment plus an ultrasound-guided intra-articular hip injection of 1% lidocaine hydrochloride alone. According to the authors this trial will make an important contribution to the management of hip OA in primary care.

Walter *et al.*<sup>20</sup> performed a retrospective study that evaluated clinical and patient-reported outcomes after image-guided intra-articular steroid (triamcinolone) + anaesthetic (ropivacaine) hip injections in a large cohort of patients (113 patients) with osteoarthritis-related hip pain. They did not find significant differences in patient-reported outcomes measured at 1 and 6 months post-injection overall and among subgroups with short- and long-term follow-up.

Lai *et al.*<sup>21</sup> conducted a study to evaluate the duration of efficacy of intra-articular steroid therapy and identify the predictive factors on injection response. In this study most patients (close to 70%) had no long-lasting pain reduction (less than 2 weeks). More-

over, gender, age, BMI, duration of symptoms, and radiographic severity of disease did not predict the injection response. The authors concluded that intra-articular hip steroid injections may be less effective in the long term, and surgical management may be considered earlier.

Hess *et al.*<sup>22</sup> assessed the relationship between rapidly destructive osteoarthritis (RDOA) of the hip and intra-articular steroid injections. The true incidence of RDOA is unknown and intra-articular steroids have been reported as a possible cause. In this study the authors reported that 21% of patients who received an intra-articular steroid hip injection develop RDOA of the hip. They suggested that patients contemplating intra-articular steroid injections of the hip should be informed about the possibility of RDOA or the progression of pre-existing arthritic process, especially those who are elderly or have higher Kellgren and Lawrence scores before injection.

According to Ebell<sup>23</sup> in a review on osteoarthritis, corticosteroid injections may be helpful only for short-term pain relief, but repeated injections can lead to a more rapid cartilage loss with no long-term benefits.

The guidelines of ACR<sup>15</sup> and AAOS<sup>17</sup> on knee and hip OA recommend the use of steroids in hip OA for a short-term pain relief. Use of steroids is not included in the latest OARSI<sup>16</sup> and European League Against Rheumatism (EULAR) recommendations.<sup>24</sup>

## Intra-articular therapies other than hyaluronic acid and steroids

### Platelet-rich plasma

PRP is an autologous concentration of platelets rich in cytokines and growth factors, which can stimulate cell growth, collagen synthesis and tissue regeneration. In recent years, it has emerged as a promising therapeutic option in hip osteoarthritis. Ali *et al.*<sup>25</sup> conducted a systematic review of the literature to determine the effectiveness of PRP injections in improving clinical outcomes in patients with hip osteoarthritis. They concluded that hip intra-articular PRP injections may be effective in the long term in improving pain and function in patients with hip OA and appear to be well tolerated, but the quality of evidence is very low.

In a retrospective study, Tassara *et al.*<sup>26</sup> evaluated 28 patients affected by symptomatic osteoarthritis (25 knee OA and 3 hip OA) treated with autologous conditioned serum (ACS). They reported significant improvement in pain and range of motion for all grades of OA. In this study there was no control group, but the authors concluded that ACS could be a valid option in case of symptomatic OA, when surgery is contraindicated or refused by the patient.

### Stem cell therapy

Another promising therapeutic option for osteoarthritis is the use of mesenchymal stem cells from bone marrow concentrate (BMC). Most studies reported their use in knee osteoarthritis,<sup>27,28</sup> yet there is little evidence regarding their use in hip osteoarthritis. Darrow<sup>29</sup> reported the outcomes of 4 hip OA patients, who underwent 4 BMC injections each. On average, the last follow-up was administered 3.5 months after the first injection. The outcomes were the evaluation of changes in resting and active pain, overall improvement and joint function. All patients experienced decreased pain and improved functionality compared to baseline. The results suggested that mesenchymal stem cells (MSCs) could play a role in cartilage regeneration due to its capacity to secrete trophic factors

and to stimulate cartilage growth. The authors of this case series supposed that multiple BMC injections in a short time period might enable the hip to have an effective cartilage repair and might be more effective than treating patients with a single BMC injection.

### Botulinum toxin type A

Eleopra *et al.*<sup>30</sup> performed a prospective multi-center randomized double-blind study in a larger population of patients with hip OA to confirm previous findings regarding the efficacy and clinical benefit of abobotulinumtoxinA (aboBoNT-A) injections to improve hip range of motion and pain.<sup>31</sup> In this study 46 patients with hip OA were recruited and randomized 2:1 to either the Treatment Group (TG; vial 500 U) or the Placebo Group (PG). The choice of the 2:1 proportion was decided before the beginning of the study in order to have more subjects in TG to evaluate the Abo-BoNT safety. Each subject received 250 U in the adductor longus muscle and 150 U in the adductor magnus muscle of the thigh of the hip affected by OA under electromyography guided-assistance. The patients of PG received 1.6 mL of saline solution (placebo). The patients were examined at baseline and after injections at 2, 4 and 12 weeks. According to the authors there was a good improvement in range of motion and pain recorded at week 4 after Abo-BoNT injections compared to placebo, when a maximal peak of effect is expected. No adverse events were detected in both treatment groups.

Courseau<sup>32</sup> in a systematic review and meta-analysis evaluated the efficacy of intra-articular injections of botulinum toxin A (produced by the anaerobic bacterium *Clostridium Botulinum*) in patients affected by painful osteoarthritis. Although many studies indicate that the botulinum toxin can reduce pain through the reduction of peripheral and central sensitization, in this meta-analysis no significant improvement was found in patients affected by hip or knee OA.

Due to the low level of evidence, the international guidelines (OARSI<sup>16</sup> and AAOS<sup>17</sup>) do not recommend this kind of therapies.

### Focus on radiology

Ferrero<sup>33</sup> in an interesting study used T2 mapping to quantify the effect of intra-articular hyaluronic acid administration (IAHAA) on cartilage with correlation to clinical symptoms. T2 relaxation times are expected to increase in degenerative conditions, compared to healthy controls, due to the loss of cartilaginous matrix, and a consequent higher content of free water. However, in this study, after HA injection, the authors observed that T2 relaxation times increased to similar values to those shown in cases with more severe damage and also found a significant correlation between T2 increase and pain reduction at 3 months follow-up. In order to explain this paradoxical result, the authors argued that T2 mapping does not only evaluate the water content of the cartilage, but also the collagen content and collagen fiber orientation in the extracellular matrix. In treated patients the same volume of cartilage contains more HA, but less collagen. Unfortunately, HA does not treat cartilage damage (which may lead to low relaxation times), but it can contribute to slowing down the degeneration process by providing lubrication and hydration. Thus, they supposed that higher relaxation times in treated patients are the reflection of increased cartilage water content, favored by HA.

Deseyne *et al.*<sup>34</sup> described a multi-center study that assessed the predictive factor (clinical and imaging) of response, according to hip MRI inflammatory scoring system (HIMRISS), after intra-articular hyaluronate (HANox-M-XL) injection in patients with hip OA. Clinical outcomes were assessed at baseline and 3 months after HA injection by WOMAC. On hip MRI performed before HA in-

jection, bone marrow lesion (BML) and synovitis were assessed by HIMRISS. Associations between MRI features and clinical data were assessed. Logistic regression (univariate and multivariate) was used to explore associations between MRI features and response to HA injection, according to WOMAC50 response at 3 months. In this study, there was no association between baseline BML and clinical outcomes, but there was a correlation between HIMRISS synovitis-effusion and WOMAC-Function at baseline. Moreover, they found that patients with low HIMRISS BML femoral and low HIMRISS total score have a better chance of being responders, thus HA injection may be more effective in those patients with lower active lesions and is much less likely to be effective in those with extensive involvement with BML.

Steer *et al.*<sup>35</sup> performed an observational study to predict response to intra-articular steroid injections in hip OA using baseline clinical, ultrasound, and MRI data. At baseline and 8 weeks they obtained hip MRI, grey scale and Doppler ultrasound and clinical parameter. Effusion-synovitis reflecting inflammation can be reliably measured at the hip on ultrasound and MRI, but in this study at 8 weeks post-injection there were no significant changes in ultrasound, MRI, or Doppler indices. Baseline variables were not significantly different between responders and non-responders. The Authors concluded that ultrasound and MRI have little clinical utility in predicting response to a steroid treatment.

### Conclusions

There is no solid evidence in literature that supports the efficacy of intra-articular infiltration therapies in hip osteoarthritis. The international guidelines reflect this lack of solid scientific evidence. In the clinical practice, intra-articular steroid injections are quite effective in the short term especially for effusion-synovitis with inflammation, but repeated injections can lead to cartilage loss with no benefit in long-term. Hyaluronic acid, on the other hand, is a valid alternative in patients who have contraindications to steroid therapy and it may be effective in those patients who do not benefit or cannot receive standard therapies. The level of evidence for the other therapies is, at present, very low.

We also underline the presence of numerous reviews and meta-analysis in the literature on this topic, yet there is a very small number of original works with high level of evidence. We think that original works with high level of evidence are the only way to highlight the benefits of these therapies.

### References

1. Murphy LB, Helmick CG, Schwartz TA, et al. One in four people may develop symptomatic hip osteoarthritis in his or her lifetime. *Osteoarthr. Cartil* 2010;18:1372-9.
2. McDonough CM, Jette AM. The Contribution of Osteoarthritis to Functional Limitations and Disability. *Clin Geriatr Med* 2010;26:387-99.
3. Moreland, LW. Intra-articular hyaluronan (hyaluronic acid) and hylans for the treatment of osteoarthritis: mechanisms of action. *Arthritis Res Ther* 2003;5:64-7.
4. Rutjes AWS, Jüni P, da Costa BR, et al. Viscosupplementation for Osteoarthritis of the Knee: A Systematic Review and Meta-analysis. *Ann Intern Med* 2012;157:180.

5. Clementi D, D'Ambrosi R, Bertocco P, et al. Efficacy of a single intra-articular injection of ultra-high molecular weight hyaluronic acid for hip osteoarthritis: a randomized controlled study. *Eur J Orthop Surg Traumatol* 2018;28:915-22.
6. Brander V, Skrepnik N, Petrella RJ, et al. Evaluating the use of intra-articular injections as a treatment for painful hip osteoarthritis: a randomized, double-blind, multicenter, parallel-group study comparing a single 6-mL injection of hylan G-F 20 with saline. *Osteoarthritis and Cartilage* 2019;27:59-70.
7. Zhang W, Robertson J, Jones AC, et al. The placebo effect and its determinants in osteoarthritis: meta-analysis of randomised controlled trials. *Ann Rheum Dis* 2008;67:1716-23.
8. Bannuru RR, McAlindon TE, Sullivan MC, et al. Effectiveness and Implications of Alternative Placebo Treatments: A Systematic Review and Network Meta-analysis of Osteoarthritis Trials. *Ann Intern Med* 2015;163:365.
9. Pogliacomini F, Schiavi P, Paraskevopoulos A, et al. When is indicated viscosupplementation in hip osteoarthritis? *Acta Bio Medica Atenei Parmensis* 2018;90:67-74.
10. Ye Y, Zhou X, Mao S, et al. Platelet rich plasma versus hyaluronic acid in patients with hip osteoarthritis: A meta-analysis of randomized controlled trials. *Int J Surg* 2018;53:279-87.
11. Leite VF, Daud Amadera JE, Buehler AM. Viscosupplementation for Hip Osteoarthritis: A Systematic Review and Meta-Analysis of the Efficacy on Pain and Disability, and the Occurrence of Adverse Events. *Archiv Phys Med Rehabil* 2018;99:574-583.e1.
12. Migliore A, Massafra U, Bizzi E, V et al. Comparative, double-blind, controlled study of intra-articular hyaluronic acid (Hyalubrix®) injections versus local anesthetic in osteoarthritis of the hip. *Arthritis Res Ther* 2009;11:R183.
13. Lieberman JR, Engstrom SM, Solovyova O, et al. Is Intra-Articular Hyaluronic Acid Effective in Treating Osteoarthritis of the Hip Joint? *J Arthroplasty* 2015;30:507-11.
14. Wu B, Li Y-M, Liu Y-C. Efficacy of intra-articular hyaluronic acid injections in hip osteoarthritis: a meta-analysis of randomized controlled trials. *Oncotarget [Internet]* 2017 [cited 2019 Dec 18];8. Available from: <http://www.oncotarget.com/full-text/20995>
15. Hochberg MC, Altman RD, April KT, et al. American College of Rheumatology 2012 recommendations for the use of non-pharmacologic and pharmacologic therapies in osteoarthritis of the hand, hip, and knee. *Arthritis Care Res* 2012;64:465-74.
16. Bannuru RR, Osani MC, Vaysbrot EE, et al. OARSI guidelines for the non-surgical management of knee, hip, and polyarticular osteoarthritis. *Osteoarthritis Cartilage* 2019;S1063458419311161.
17. American Academy of Orthopaedic Surgeons. Management of osteoarthritis of the hip. *Evid-Based Clin Pract Guideline* 2017.
18. Conrozier T, Monfort J, Chevalier X, et al. EUROVISCO Recommendations for Optimizing the Clinical Results of Viscosupplementation in Osteoarthritis. *Cartilage* 2018;194760351878345.
19. Paskins Z, Hughes G, Myers H, et al. A randomised controlled trial of the clinical and cost-effectiveness of ultrasound-guided intra-articular corticosteroid and local anaesthetic injections: the hip injection trial (HIT) protocol. *BMC Musculoskeletal Disord* 2018;19:218.
20. Walter WR, Bearison C, Slover JD, et al. Clinical and patient-reported outcomes after image-guided intra-articular therapeutic hip injections for osteoarthritis-related hip pain: a retrospective study. *Skeletal Radiol* 2019;48:713-9.
21. Lai WC, Arshi A, Wang D, et al. Efficacy of intraarticular corticosteroid hip injections for osteoarthritis and subsequent surgery. *Skeletal Radiol* 2018;47:1635-40.
22. Hess SR, O'Connell RS, Bednarz CP, et al. Association of rapidly destructive osteoarthritis of the hip with intra-articular steroid injections. *Arthroplasty Today* 2018;4:205-9.
23. Ebell MH. Osteoarthritis: Rapid Evidence Review. *Am Fam Physician* 2018;97:523-6.
24. Fernandes L, Hagen KB, Bijlsma JWJ, et al. EULAR recommendations for the non-pharmacological core management of hip and knee osteoarthritis. *Ann Rheum Dis* 2013;72:1125.
25. Northumbria Healthcare NHS Foundation Trust, North Shields, United Kingdom, Ali M, Mohamed A, Health Education North East, Newcastle, United Kingdom, Elamin Ahmed H, South Tyneside District Hospital, South Shields, United Kingdom, et al. The use of ultrasound-guided platelet-rich plasma injections in the treatment of hip osteoarthritis: a systematic review of the literature. *J Ultrason* 2018;18:332-7.
26. Tassara M, De Ponti A, Barzizza L, et al. Autologous conditioned serum (ACS) for intra-articular treatment in Osteoarthritis: Retrospective report of 28 cases. *Transfus Apher Sci* 2018;57:573-7.
27. Centeno C, Pitts J, Al-Sayegh H, Freeman M. Efficacy of Autologous Bone Marrow Concentrate for Knee Osteoarthritis with and without Adipose Graft. *BioMed Res Int* 2014;2014:1-9.
28. Centeno CJ, Al-Sayegh H, Bashir J, et al. A dose response analysis of a specific bone marrow concentrate treatment protocol for knee osteoarthritis. *BMC Musculoskeletal Disord* 2015;16:258.
29. Darrow M, Shaw B, Darrow B, Wisz S. Short-Term Outcomes of Treatment of Hip Osteoarthritis With 4 Bone Marrow Concentrate Injections: A Case Series. *Clin Med Insights Case Rep* 2018;11:117954761879157.
30. Eleopra R, Rinaldo S, Lettieri C, et al. A botulinum toxin A: A New Therapy for Hip Osteoarthritis. A Prospective Randomized Double-Blind Multicenter Study. *Toxins (Basel)* 2018;10.
31. Marchini C, Acler M, Bolognari MA, et al. Efficacy of botulinum toxin type A treatment of functional impairment of degenerative hip joint: Preliminary results. *J Rehabil Med* 2010;42:691-3.
32. Courseau M, Salle PV, Ranoux D, et al. Efficacy of Intra-Articular Botulinum Toxin in Osteoarticular Joint Pain: A Meta-Analysis of Randomized Controlled Trials. *Clin J Pain* 2018;34:383-9.
33. Ferrero G, Sconfienza LM, Fiz F, et al. Effect of intra-articular injection of intermediate-weight hyaluronic acid on hip and knee cartilage: in-vivo evaluation using T2 mapping. *Eur Radiol* 2018;28:2345-55.
34. Deseyne N, Conrozier T, Lellouche H, et al. Hip Inflammation MRI Scoring System (HIMRISS) to predict response to hyaluronic acid injection in hip osteoarthritis. *Joint Bone Spine* 2018;85:475-80.
35. Steer KJD, Bostick GP, Woodhouse LJ, et al. Can effusion-synovitis measured on ultrasound or MRI predict response to intra-articular steroid injection in hip osteoarthritis? *Skeletal Radiol* 2019;48:227-37.