

Non-invasive methods for the assessment of hepatic fibrosis: transient elastography, hyaluronic acid, ¹³C-aminopyrine breath test and cytokeratin 18 fragment

Gian Paolo Caviglia,* Alessia Ciancio,** Chiara Rosso,* Maria Lorena Abate,* Antonella Olivero,* Rinaldo Pellicano,** Giovanni Antonio Touscoz,** Antonina Smedile,** Mario Rizzetto**

* Department of Internal Medicine, University of Turin, Turin, Italy.

** Department of Gastroenterology and Hepatology, San Giovanni Battista University Hospital (Molinette), Turin, Italy.

ABSTRACT

Background. In the management of chronic hepatitis C (CHC) patients, liver biopsy is the gold standard for liver fibrosis assessment despite some technical limits and risks. Non-invasive approaches have been proposed as alternative methods to evaluate structural liver damage. **Aim.** To investigate the diagnostic accuracy of transient elastography, ¹³C-aminopyrine breath test (¹³C-ABT), serum hyaluronic acid (HA) and cytokeratin 18 Asp396 fragment (CK-18) as non-invasive methods of liver fibrosis assessment at their correlation to METAVIR score. **Material and methods.** In a cohort of 57 CHC patients, liver stiffness, cumulative percentage of administered dose of ¹³C-aminopyrine at 120 min, serum HA and serum CK-18 concentration were determined. Diagnostic accuracy in detecting significant fibrosis (F ≥ 2), severe fibrosis (F ≥ 3) and cirrhosis (F = 4) was assessed by the area under the receiver operating characteristic curve. **Results.** Liver fibrosis score showed a strong correlation with liver stiffness (r = 0.667; p < 0.0001) and a significant inverse correlation with ¹³C-ABT results (r = -0.418; p = 0.0012). A weaker correlation was found with CK18 (r = 0.329; p = 0.0126) and no correlation with HA. Areas under the curve of elastography, ¹³C-ABT, HA and CK18 were: 0.98, 0.75, 0.69, 0.64, respectively, for F ≥ 2; 0.97, 0.69, 0.80, 0.66, respectively, for F ≥ 3; 0.95, 0.64, 0.70, 0.56, respectively, for F = 4. **Conclusion.** Elastography has the best diagnostic accuracy for the assessment of the degree of liver fibrosis in CHC patients. Its application can provide an alternative useful tool for monitoring the disease evolution.

Key words. Chronic hepatitis C. Liver fibrosis. Liver biopsy. Fibroscan. Non-invasive fibrosis markers.

INTRODUCTION

Prognosis and management of chronic hepatitis C (CHC) patients is strongly influenced by the degree of liver fibrosis, in fact a precise definition of the hepatic fibrosis stage is an important parameter to assess the risk of disease progression and to prompt immediate antiviral therapy.^{1,2}

Liver biopsy (LB) is the gold standard for the evaluation of hepatic fibrosis and provides useful information on many parameters like inflammation, necrosis, steatosis and hepatic iron, allowing to identify suspected or unexpected cofactors and comorbidities.³ Unfortunately, LB has some limitations and risks that make it unsuitable for patients tight monitoring: it is an invasive procedure and it

can lead to complications such as bleeding, pain at biopsy site, infection and accidental injury to a nearby organ.⁴ Other limitations include sampling error and pathologist's inter-observer variability.⁵ Therefore, there is a need for accurate non-invasive methods for measuring the degree of liver fibrosis. Non-invasive approaches can be distinguished in direct markers of fibrogenesis, as expression of either deposition or removal of extra cellular matrix (ECM) in the liver,³ or indirect markers of fibrosis, which reflect liver changes induced by fibrosis without a direct link with fibrogenesis mechanisms,⁶ and imaging methods.⁷ Direct markers include hyaluronic acid (HA), laminin, type IV collagen, type III collagen N-terminal peptide, matrix metalloproteinases and cytokines, such as tumor necrosis factor- α and transforming growth factor- β .^{4,7} Indirect markers are obtained by combining together routinely performed blood tests to calculate scores to identify alterations in liver function. They include aspartate aminotransferase (AST) to platelet ratio index (APRI), FibroTest™ and Forns' index.⁶ Imaging methods refer to ultrasonography, magnetic resonance imaging and transient elastography.⁷

Correspondence and reprint request: Rinaldo Pellicano, M.D.
Department of Gastroenterology and Hepatology, San Giovanni Battista
University Hospital, C.so Bramante n.88/90, 10100 Turin, Italy.
Tel: +391 1633-3532. Fax: +391 1633-3976
E-mail: rinaldo_pellican@hotmail.com

Manuscript received: January 24, 2013.

Manuscript accepted: March 15, 2013.

Hyaluronic acid is a glycosaminoglycan component of ECM, synthesized by hepatic stellate cells.⁸ Elevated levels of HA are due to increased production, decreased hepatic removal or both.⁹ High concentrations of serum HA have been detected in CHC patients and have been related to different degrees of liver fibrosis.¹⁰

Cytokeratin 18 Asp 396 fragment (CK-18) is a serological marker of apoptosis that has been widely associated with fibrosis and steatosis in nonalcoholic steatohepatitis (NASH).^{11,12} Nevertheless, a recent study found higher levels of CK-18 in CHC patients compared to healthy controls.¹³ Additionally, the same study found a significant correlation of serum CK-18 titer and degree of fibrosis.¹³

¹³C-aminopyrine breath test (¹³C-ABT) is a dynamic function test based on the use of a labelled substrate selectively metabolized within the liver. It has been shown to be useful in the evaluation of hepatocyte microsomal function providing a quantitative information on liver function activity.¹⁴ A recent study compared ¹³C-ABT measurements of CHC and Child-Pugh class A cirrhosis patients to those of normal subjects and found that ¹³C-ABT was able to distinguish different degrees of liver function impairment with a partial correlation to histology.¹⁵

Transient elastography (Fibroscan™) (FS) is an ultrasonographic method for assessing liver fibrosis. It evaluates liver stiffness measuring the velocity of propagation of an elastic wave through the hepatic tissues. The speed of transmission of the elastic wave is directly related to tissue stiffness and consequently to fibrosis amount.^{1,5,6} Several large-scale prospective studies already tested the effectiveness of this method in patients with chronic liver diseases, especially in CHC.^{16,17}

Since data are few or conflicting, the reliability of these non-invasive methods as alternative to LB is not fully known, particularly for CK-18, ¹³C-ABT and HA. We examined the hypothesis whether non-invasive tests adequately assess liver fibrosis. If our hypothesis is true this may decrease the need for liver biopsies.

MATERIAL AND METHODS

This study included 57 consecutive CHC patients (32M, 25F; mean age 52.5 ± 11.9) tested positive for anti-HCV (Ortho HCV SAvE 3.0, Raritan, NJ, USA) and HCV RNA (TaqMan, Roche, detection limit 15 IU/mL). Patients with other etiologies of chronic hepatitis, such as chronic hepatitis B, NASH, autoimmune hepatitis, primary biliary cirrhosis, alcoholic

liver disease and hemochromatosis were excluded. The study protocol was conformed to the principles of the 1975 Declaration of Helsinki. All patients gave their written informed consent prior to recruitment.

Liver histology

All patients underwent LB in the year preceding non-invasive liver fibrosis assessment (from 6 to 12 months).¹⁸ All biopsy specimens were analyzed by an experienced pathologist blinded to the clinical results of the patients. Liver specimens shorter than 20 mm were excluded from the analysis. Liver fibrosis was staged according to METAVIR score:

- **F0:** absence of fibrosis.
- **F1:** portal fibrosis without septa.
- **F2:** portal fibrosis with few septa.
- **F3:** numerous septa without cirrhosis.
- **F4:** cirrhosis.

Serum markers

A blood sample was obtained on the same day of liver stiffness assessment by transient elastography and breath test. After centrifugation, serum samples were stored -80°C for further analysis. Measurements of serum HA and CK-18 were performed according to manufacturer's recommendations by ELISA assays: Hyaluronic Acid Test Kit (Corgenix, Westminster, Colorado, USA) and M30-Apoptosense ELISA (PEVIVA, Sweden). Concentrations were given in ng/mL.

Transient elastography

Liver stiffness measurements were performed by FS (Echosens, Paris, France) on the right lobe of the liver through intercostal spaces on patients lying in the dorsal decubitus position with the right arm in maximal abduction. Details have been described in previous studies.¹ Measurement depth was between 25 mm and 65 mm below the skin surface. The success rate was calculated as the ratio of the number of the successful measurements over the total number of acquisitions. Liver stiffness was expressed in kilopascals (KPa) as the median value of the successful measurements. Only liver stiffness data with at least 10 successful measurements, success rate higher than 60% and interquartile ratio (IQR) inferior to 30%, were considered reliable.

Breath test

^{13}C -ABT was performed as previously described.¹⁹ A basal breath sample was collected after an overnight fast; then a dose of 2 mg/kg of ^{13}C -aminopyrine (EXPIROLiver, Sofar, Italy) was dissolved in 200 mL of water and administered orally. The percentage of the exhaled dose per hour and the cumulative percentage of metabolized dose in 2 h were dynamically monitored. Results obtained from ^{13}C -ABT were expressed as cumulative percentage dose of ^{13}C recovered (%) over time (at 120 min after ingestion of labelled aminopyrine).

Statistical analysis

Correlation among studied parameters and the degree of liver fibrosis was performed using

Table 1. Demographic, biochemical and histological characteristics of patients

Characteristics	n = 57
Gender (M/F)	32/25
Age (range)	52.5 (25-77)
ALT, IU/L (mean \pm SD)	85 \pm 47
GGT, IU/L (mean \pm SD)	72 \pm 57
Platelet count (10^9 /L)	195 \pm 74
Fibrosis score (METAVIR)	
F0	2 (3.5%)
F1	18 (31.6%)
F2	10 (17.5%)
F3	9 (15.8%)
F4	18 (31.6%)

M: male. F: female. ALT: alanine aminotransferase. GGT: γ -glutamyltransferase.

Table 2. Mean values and standard deviations of liver stiffness, HA, ^{13}C -ABT and CK-18 according to fibrosis METAVIR score.

	FS (KPa)	HA (ng/mL)	^{13}C -ABT (%)	CK-18 (ng/mL)
F0	4.5 \pm 0.6	10 \pm 2	32.3 \pm 10.8	133 \pm 28
F1	6.7 \pm 1.0	67 \pm 78	24.2 \pm 7.9	226 \pm 112
F2	9.1 \pm 1.7	40 \pm 20	17.3 \pm 4.4	247 \pm 196
F3	11.9 \pm 2.3	155 \pm 107	16.3 \pm 7.7	407 \pm 314
F4	22.7 \pm 12.5	166 \pm 158	16.3 \pm 8.7	289 \pm 210

FS: fibroscan. HA: hyaluronic acid. ^{13}C -ABT: ^{13}C -aminopyrine breath test. CK18: cytokeratin 18 asp 396 fragment.

Table 3. Correlation coefficient between the parameters studied and the degree of fibrosis according to METAVIR score.

Fibrosis	FS	HA	^{13}C -ABT	CK-18
r	0.667	0.140	-0.418	0.329
p	< 0.0001	0.2990	0.0012	0.0126

FS: fibroscan. HA: hyaluronic acid. ^{13}C -ABT: ^{13}C -aminopyrine breath test. CK-18: cytokeratin 18 asp 396 fragment.

Spearman's nonparametric correlation. A multiple regression analysis was used to assess the association between the results obtained by the different non-invasive methods tested and liver fibrosis, while controlling for patients age and gender. Diagnostic performance, sensitivity and specificity for all possible cut-off values of FS, HA, ^{13}C -ABT, CK-18 and their combination was assessed by using receiver operating characteristic (ROC) curves. A P-value < 0.05 was considered statistically significant. All statistical procedures were performed using SPSS version 18.0 for Windows (SPSS Inc., Chicago, IL).

RESULTS

The main demographic characteristics of the studied patients are reported in table 1. Mean values of liver stiffness, HA, ^{13}C -ABT and CK-18 categorized according to fibrosis METAVIR score are reported in table 2. At univariate analysis, liver fibrosis showed a strong correlation with liver stiffness ($r = 0.667$; $p < 0.0001$) and a significant inverse correlation with ^{13}C -ABT results ($r = -0.418$; $p = 0.0012$). A weaker correlation was found with CK18 ($r = 0.329$; $p = 0.0126$) and no correlation with HA (Table 3). In a multiple regression model including age, gender and ALT, liver stiffness ($p < 0.0001$) remained the only factor associated with fibrosis degree (Table 4).

Figure 1 shows the areas under the curve (AUCs) calculated by ROC analysis of FS, HA, ^{13}C -ABT and CK18 for the diagnosis of significant fibrosis (A), severe fibrosis (B) and cirrhosis (C). Corresponding AUCs, cut off values that maximized sensitivity and specificity, positive predictive values (PPV) and negative predictive values (NPV) are shown in table 5.

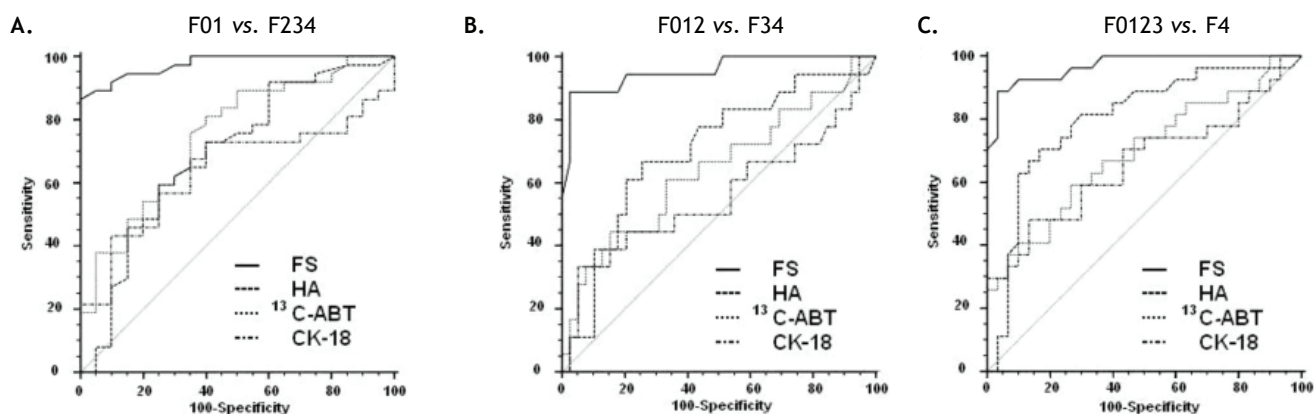


Figure 1. ROC curves for FS, HA, ¹³C-ABT and CK18 in the diagnosis of significant fibrosis (A), severe fibrosis (B) and cirrhosis (C). FS: fibroscan. HA: hyaluronic acid. ¹³C-ABT: ¹³C-aminopyrine breath test. CK-18: cytokeratin 18 asp396 fragment.

Table 4. Multiple regression analysis of the parameters studied and the degree of hepatic fibrosis according to METAVIR score.

Variable	t	p
Age	1.184	0.2424
Gender	0.897	0.3742
ALT	-0.543	0.5894
FS	4.454	< 0.0001
HA	0.401	0.6905
¹³ C-ABT	0.924	0.3601
CK-18	1.868	0.0678

ALT: alanine aminotransferase. FS: fibroscan. HA: hyaluronic acid. ¹³C-ABT: ¹³C-aminopyrine breath test. CK-18: cytokeratin 18 asp 396 fragment.

All possible combinations of FS, HA, ¹³C-ABT and CK-18 for the diagnosis of fibrosis stage compared to histology were evaluated. No statistically significant improvement in AUC values compared to liver stiffness alone was found (data not shown).

DISCUSSION

In recent years, transient elastography has become a widely used method for the assessment of liver fibrosis degree.^{1,5} Among the non-invasive approaches evaluated in this study (Figure 2), FS obtained an excellent diagnostic accuracy in predicting

Table 5. Sensitivity, specificity and area under the curve of the non-invasive methods studied for the diagnosis of significant fibrosis (F ≥ 2), severe fibrosis (F ≥ 3) and cirrhosis (F = 4).

METAVIR	AUC	95% CI	Cut off	Se	Sp	PPV	NPV
F ≥ 2							
FS	0.98	0.90-1.00	8.6 KPa	86.5	100	100	80
HA	0.69	0.55-0.81	61 ng/mL	59.5	75	81.5	50
¹³ C-ABT	0.75	0.62-0.86	23.3%	81.1	60	78.9	63.2
CK-18	0.64	0.50-0.76	268 ng/mL	43.2	90	88.9	46.2
F ≥ 3							
FS	0.97	0.89-1.00	9.9 KPa	88.9	96.7	96	90.6
HA	0.80	0.67-0.89	73 ng/mL	70.4	83.3	79	75.8
¹³ C-ABT	0.69	0.56-0.81	17.3%	59.3	73.3	66.7	66.7
CK-18	0.66	0.52-0.78	288 ng/mL	48.1	86.7	76.5	65
F = 4							
FS	0.95	0.86-0.99	13.8 KPa	88.9	97.4	94.1	95
HA	0.70	0.57-0.82	92 ng/mL	66.7	74.4	54.5	82.9
¹³ C-ABT	0.64	0.50-0.76	12.0%	44.4	84.6	57.1	76.7
CK-18	0.56	0.42-0.69	471 ng/mL	33.3	94.9	75	75.5

FS: fibroscan. HA: hyaluronic acid. ¹³C-ABT: ¹³C-aminopyrine breath test. CK-18: cytokeratin 18 asp396 fragment. AUC: area under the curve. 95% CI: 95% confidence interval. Se: sensitivity. Sp: specificity. PPV: positive predictive value. NPV: negative predictive value.

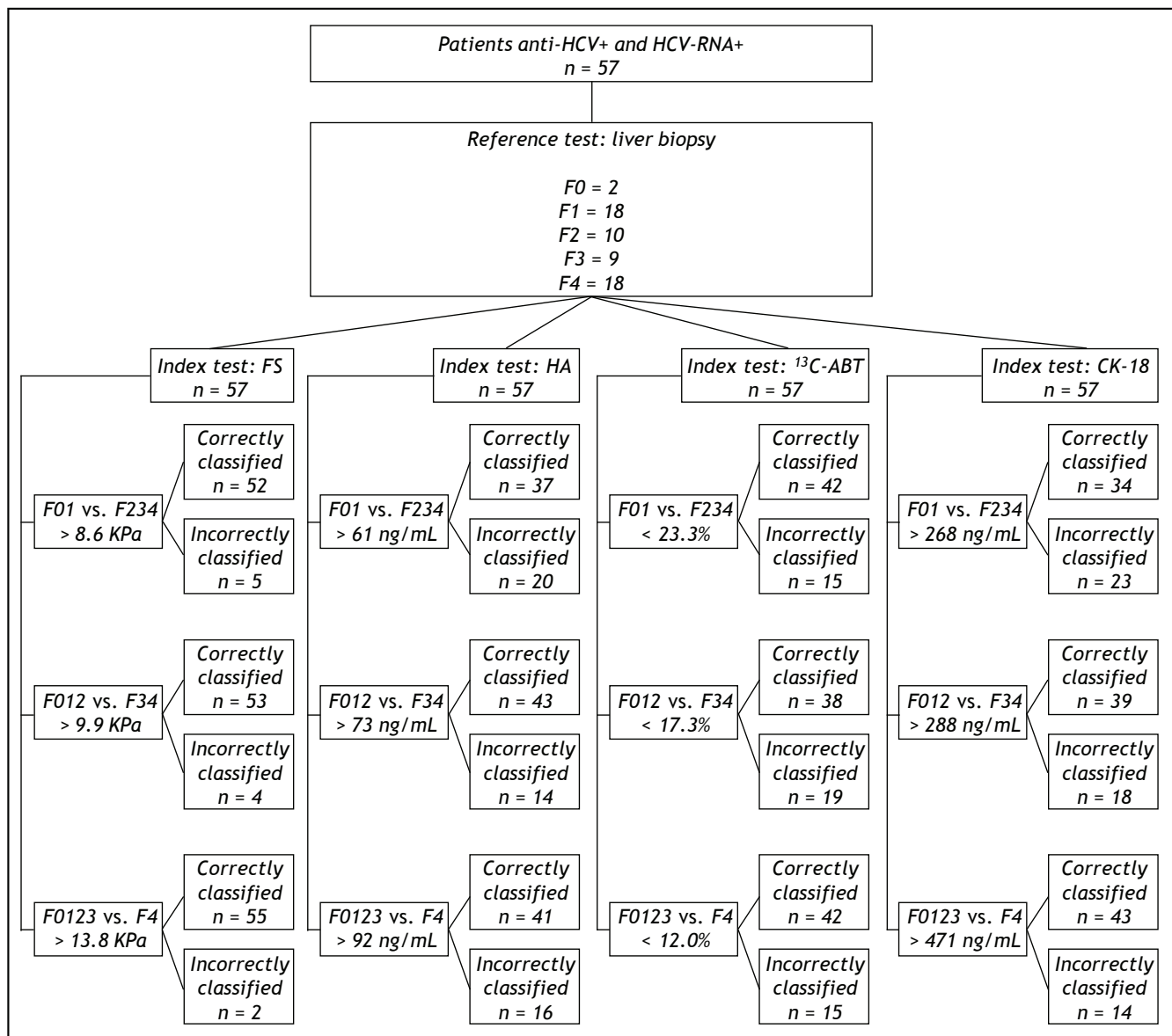


Figure 2. Flow chart of the study. N: number of patients. FS: fibroscan. HA: hyaluronic acid. ¹³C-ABT: ¹³C-aminopyrine breath test. CK-18: cytokeratin 18 asp396 fragment.

significant fibrosis (AUC = 0.98), severe fibrosis (AUC = 0.97) and cirrhosis (AUC = 0.95) compared to LB. Using 8.6 KPa, 9.9 KPa and 13.8 KPa as cut off values for significant fibrosis, severe fibrosis and cirrhosis respectively, we obtained PPV of 100%, 96% and 94.1% and NPV of 80%, 90.6% and 95%. Sensitivity and specificity values were 86.5% and 100% respectively, for $F \geq 2$; 88.9% and 96.7% respectively, for $F \geq 3$; 88.9% and 97.4% respectively, for $F = 4$. In contrast to previous reports^{1,20} and meta-analysis,²¹⁻²³ where FS showed to perform slightly better in the diagnosis of cirrhosis than in detecting significant fibrosis, our

data shows FS usefulness for early detection of significant fibrosis also. However, this discrepancy could be due to the small number of patients enrolled in our study. Infact, Castéra, *et al.*¹ reported a FS AUC value of 83% in a cohort of 183 patients with CHC, and similarly, in a study population of 251 subject with CHC, Zioli, *et al.*²⁰ reported a FS diagnostic accuracy of 79% in detecting significant fibrosis.

Regarding serum markers, previous reports showed a good performance in the diagnosis of both cirrhosis and significant fibrosis, emphasizing an elevated sensivity and specificity for HA.^{10,24}

Another study suggested that the simple non-invasive measurement of serum HA could be used to exclude the presence of cirrhosis in CHC patients at least.²⁵ In agreement with other reports,²⁶ we did not find a correlation of HA to the degree of liver fibrosis and, moreover, AUC values indicated only a moderate diagnostic accuracy for cirrhosis detection.

A recent study showed that serum CK18 levels are higher in CHC patients compared to healthy controls and are associated with significant hepatic fibrosis, despite of a considerable overlap in serum CK-18 concentrations distribution.¹³ Given that the mechanisms leading to caspases activation and cytokeratin 18 Asp 396 fragment release in the blood are not well understood, we evaluated this marker in our cohort. As expected, we found a weak correlation with histological fibrosis at the univariate analysis and the AUC values revealed a low diagnostic accuracy (AUC < 0.7).

We performed the ¹³C-ABT to evaluate the correlation between liver function and hepatic fibrosis. A significant inverse correlation between ¹³C-ABT results ($r = -0.418$; $p = 0.0012$) and liver fibrosis degree was found. However, as for CK18, when multiple regression analysis including age and gender was performed, ¹³C-ABT lost statistical significance. In the evaluation of this method to discriminate patients on the basis of significant fibrosis, severe fibrosis and cirrhosis, we found AUC values of 0.75, 0.69 and 0.64 respectively, hence ¹³C-ABT did not reliably distinguish between any fibrosis stages.

The present study is limited by the rather small number of patients included, however, the proportion of patients with different degrees of liver fibrosis was well balanced. Another limitation of our analysis could be the different timing between liver biopsy sampling and non-invasive assessments. However, in the majority of patients with chronic hepatitis C the progression of fibrosis is linear and slow,²⁷ therefore a liver biopsy taken from 6 to 12 months before non-invasive assessments is unlikely to be a bias.

Despite the small size of the study cohort, our results show that transient elastography performs significantly better than other tested methods. Although liver biopsy is still necessary to assess the presence of comorbidity and metabolic disorders, the present data suggest that transient elastography is a useful tool for monitoring the disease evolution in CHC patients and a suitable non-invasive procedure that limits the need to perform a liver biopsy for fibrosis assessment.

ABBREVIATIONS

- **AST:** aspartate aminotransferase.
- **AUC:** area under the curve.
- **CHC:** chronic hepatitis C.
- **CK-18:** cytokeratin 18 asp 396 fragment.
- **ECM:** extra cellular matrix.
- **HA:** hyaluronic acid.
- **LB:** liver biopsy.
- **NASH:** nonalcoholic steatohepatitis.
- **NPV:** negative predictive value.
- **PPV:** positive predictive value.
- **¹³C-ABT:** ¹³C-aminopyrine breathtest.

FINANCIAL SUPPORTS

None to declare.

CONFLICT OF INTEREST

None to declare.

REFERENCES

1. Castéra L, Vergniol J, Foucher J, Le Bail B, Chanteloup E, Haaser M, Darriet M, et al. Prospective comparison of Transient Elastography, Fibrotest, APRI, and Liver Biopsy for the assessment of fibrosis in chronic hepatitis C. *Gastroentero* 2005; 128: 343-50.
2. Van Gulick JJ, Lamers MH, Drenth JP. Hepatitis C virus infection management in 2012. *Panminerva Med* 2012; 54: 1-9.
3. Sebastiani G, Alberti A. Non invasive fibrosis biomarkers reduce but not substitute the need for liver biopsy. *World J Gastroenterol* 2006; 12: 3682-94.
4. Attallah AM, Abdallah SO, Attallah AA, Omran MM, Farid K, Nasif WA, Shiha GE, et al. Diagnostic value of fibronectin discriminant score for predicting liver fibrosis stages in chronic hepatitis C virus patients. *Ann Hepatol* 2013; 12: 44-53.
5. Coco B, Oliveri F, Maina AM, Ciccorossi P, Sacco R, Colombatto P, Bonino F, et al. Transient elastography: a new surrogate marker of liver fibrosis influenced by major changes of transaminases. *J Viral Hepat* 2007; 14: 360-9.
6. Ladero JM. Noninvasive evaluation of liver fibrosis in patients with chronic hepatitis C. *Hepat Mon* 2011; 11: 698-700.
7. Torok NJ. Recent advantages in the pathogenesis and diagnosis of liver fibrosis. *J Gastroenterol* 2008; 43: 315-21.
8. Grigorescu M. Noninvasive biochemical markers of liver fibrosis. *J Gastrointest Liver Dis* 2006; 15: 149-59.
9. Isman FK, Kucur M, Bayal B, Ozkan F. Evaluation of serum hyaluronic acid level and hyaluronidase activity in acute and chronic hepatitis C. *J Int Med Res* 2007; 35: 346-52.
10. Halfon P, Bourlière M, Pénaranda G, Deydier R, Renou C, Botta-Fridlund D, Tran A, et al. Accuracy of hyaluronic acid level for predicting liver fibrosis stages in patients with hepatitis C virus. *Comp Hepatol* 2005; 4: 6.
11. Wieckowska A, Zein NN, Yerian LM, Lopez AR, McCullough AJ, Feldstein AE. In vivo assessment of liver cell apoptosis

- as a novel biomarker of disease severity in nonalcoholic fatty liver disease. *Hepatology* 2006; 44: 27-33.
12. Feldstein AE, Wieckowska A, Lopez AR, Liu YC, Zein NN, McCullough AJ. Cytokeratin-18 fragment levels as noninvasive biomarkers for nonalcoholic steatohepatitis: a multicenter validation study. *Hepatology* 2009; 50: 1072-8.
 13. Jazwinski AB, Tompson AJ, Clark PJ, Naggie S, Tillmann HL, Patel K. Elevated serum CK18 levels in chronic hepatitis C patients are associated with advanced fibrosis but not steatosis. *J Viral Hepat* 2012; 19: 278-82.
 14. Perri F, Pastore M, Annese V, Andriulli A. The aminopyrine breath test. *Ital J Gastroenterol* 1994; 26: 306-17.
 15. Giannini E, Fasoli B, Chiarbonello B, Malfatti P, Romagnoli F, Botta F, Testa E, et al. ¹³C-Aminopyrine breath test to evaluate severity of disease in patients with chronic hepatitis C virus infection. *Aliment Pharmacol Ther* 2002; 16: 717-25.
 16. Castéra L, Forns X, Alberti A. Non-invasive evaluation of liver fibrosis using transient elastography. *J Hepatol* 2008; 48: 835-47.
 17. Gaia S, Carenzi S, Barilli AL, Bugianesi E, Smedile A, Brunello F, Marzano A, et al. Reliability of transient elastography for the detection of fibrosis in non-alcoholic fatty liver disease and chronic viral hepatitis. *J Hepatol* 2011; 54: 64-71.
 18. Actis GC, Olivero A, Lagget M, Pellicano R, Smedile A, Rizzetto M. The practice of percutaneous liver biopsy in a Gastrohepatology day hospital: a retrospective study on 835 biopsies. *Dig Dis Sci* 2007; 52: 2576-9.
 19. Rocco A, De Nucci G, Valente G, Compare D, D'Arienzo A, Cimino L, Perri F, et al. ¹³C-Aminopyrine breath test accurately predicts long-term outcome of chronic hepatitis C. *J Hepatol* 2012; 56: 782-7.
 20. Ziol M, Handra-Luca A, Kattaneh A, Christidis C, Mal F, Kazemi F, de Lédinghen V, et al. Non-invasive assessment of liver fibrosis by measurement of stiffness in patients with chronic hepatitis C. *Hepatology* 2005; 41: 48-54.
 21. Talwalkar JA, Kurtz DM, Schoenleber SJ, West CP, Montori VM. Ultrasound-based transient elastography for the detection of hepatic fibrosis: systematic review and meta-analysis. *Clin Gastroenterol Hepatol* 2007; 5: 1214-20.
 22. Friedrich-Rust M, Ong MF, Martens S, Sarrazin C, Bojunga J, Zeuzem S, Hermann E. Performance of transient elastography for the staging of liver fibrosis: a meta-analysis. *Gastroenterol* 2008; 134: 960-74.
 23. Stebbing J, Farouk L, Panos G, Anderson M, Jiao LR, Mandalia S, Bower M, et al. A meta-analysis of transient elastography for the detection of hepatic fibrosis. *J Clin Gastroenterol* 2010; 44: 214-9.
 24. Parise ER, Oliverira AC, Mendes-Figueiredo C, Lanzoni V, Martins J, Nader H, Ferraz ML. Noninvasive serum markers in the diagnosis of structural liver damage in chronic hepatitis C virus infection. *Liver Int* 2006; 26: 1095-9.
 25. McHutchison JG, Blatt LM, De Medina M, Craig JR, Conrad A, Schiff ER, Tong MJ. Measurement of serum hyaluronic acid in patients with chronic hepatitis C and its relationship to liver histology. *J Gastroenterol Hepatol* 2000; 15: 945-51.
 26. Tamano M, Kojima K, Akima T, Murohisa T, Hashimoto T, Uetake C, Sugaya T, et al. The usefulness of measuring liver stiffness by transient elastography for assessing hepatic fibrosis in patients with various chronic liver diseases. *Hepato-Gastroenterol* 2012; 59: 826-30.
 27. Marcellin P, Asselah T, Boyer N. Fibrosis and disease progression in hepatitis C. *Hepatology* 2002; 36: S47-S56.