

# Cochlear Implant Surgery: How to Fix Receiver/Stimulator Avoiding Extrusion



Annalisa Gatto, MD<sup>1</sup>, Margherita Tofanelli, MD<sup>1</sup> , Alice Piccinato, MD<sup>1</sup> ,  
Jamile Karina Antonio, MD<sup>1</sup>, Simone Zucchini, MD<sup>1</sup>,  
Vittorio Pietro Achilli, MD<sup>2</sup>, and Giancarlo Tirelli, MD<sup>1</sup>

## Abstract

Cochlear implant (CI) surgery is generally safe and associated with a limited number of complications, among which the extrusion of the receiver/stimulator (R/S) or the electrode misplacement and migration might require a CI re-implantation. The aim of this pilot study is to describe a new technique to firmly fix the R/S using the Mitek suture anchors system (Depuy Mitek Surgical Products, Inc. Raynham, Massachusetts). We tested two different models and in our experience, the web of suture created with this device can improve the stability of the bond of the R/S to the underlying curved bone surface. So, this system resulted in a less laborious manner keeping low the complication rate.

## Keywords

cochlear implant, receiver/stimulator extrusion, hearing loss, postoperative complications, fixation technique

## Introduction

Cochlear implants (CIs) are nowadays the best treatment modality for patients with severe-to-profound sensorineural hearing loss. Cochlear implant surgery is generally safe and associated with a limited number of complications and adverse events<sup>1</sup> categorized into major and minor medical complications or hard and soft device failures. The latter class comprises different causes of implant malfunctions whose incidence rate ranges from 0.6% to 7%.<sup>2</sup> Medical complications are usually due to flap problems, wound dehiscence and infections, extrusion of the receiver/stimulator (R/S), electrode misplacement, and migration. Consequently, the device explantation with possible reimplantation might be indicated.

The most frequent causes of CI extrusion are related to technical accuracy used in each surgical step, and the incidence rate reported in the literature ranges from 1.5% to 5%,<sup>2,3</sup> but it should also be kept in mind that silicone allergy could be a rare cause of delayed CI extrusion.<sup>4</sup> The aim of this pilot study is to illustrate an alternative system to firmly fix the R/S using the Mitek suture anchors system (Depuy Mitek Surgical Products, Inc, Raynham, Massachusetts).

## Materials and Methods

In this pilot study, we used a new technique to securely fix the R/C in CI surgery in a cohort of 7 patients, 4 males and 3

females with an average age of  $43 \pm 7$  years. The patients were all treated unilaterally using the same CI type. The system we tested is the Mitek suture anchor (Depuy Mitek Surgical Products, Inc) that we had previously described in oncologic oral surgery.<sup>5-7</sup> This device is produced in different sizes and types: We used 2 different models to fix the R/S to the bony recess preventing extrusion or misplacement: the MINILOK QUICKANCHOR Plus (MQP) (Depuy Mitek Surgical Products, Inc) in 3 cases and the Mini QUICKANCHOR (MM) (Depuy Mitek Surgical Products, Inc) in the remaining 4 cases.

The MM device is made of a body and 2 wings composed of nickel and titanium, while the MQP has the same shaft and a blue polylactide absorbable anchor. Ready-to-use anchor is prepackaged with absorbable 2.0 sutures charged in the insertion device.<sup>5</sup>

<sup>1</sup> Department of Otorhinolaryngology, Head and Neck Surgery, University of Trieste, Cattinara Hospital, Trieste, Italy

<sup>2</sup> ENT Department, Maggiore Hospital, Lodi, Italy

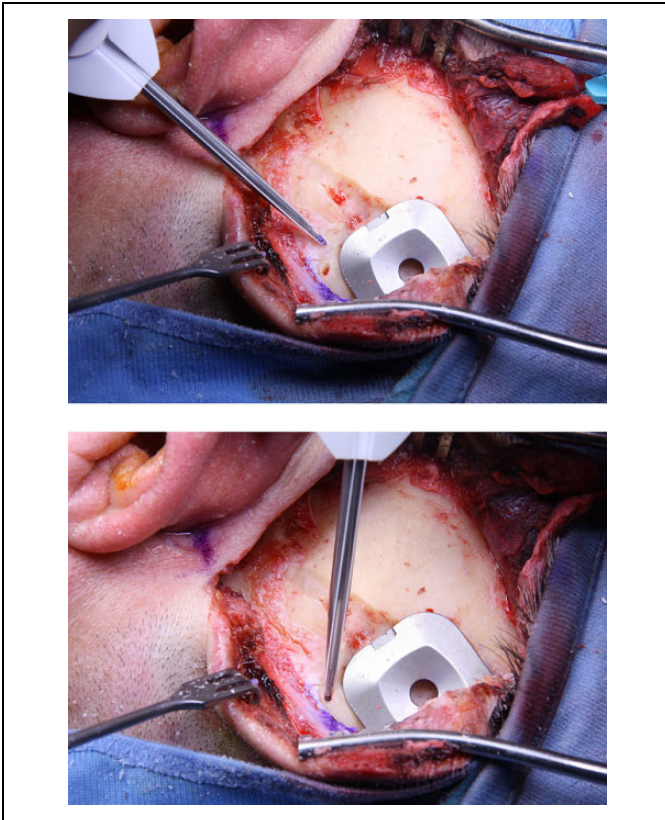
Received: May 27, 2019; revised: September 06, 2019; accepted: September 13, 2019

### Corresponding Author:

Margherita Tofanelli, MD, ENT Department, University of Trieste, Cattinara Hospital, Strada di Fiume 447, Trieste 34149, Italy.

Email: margheritatofanelli@hotmail.com





**Figure 1.** The MINILOK QUICKANCHOR Plus precharged in the insertion device and, below, the positioning into the bony pilot hole at 9-o'clock position.

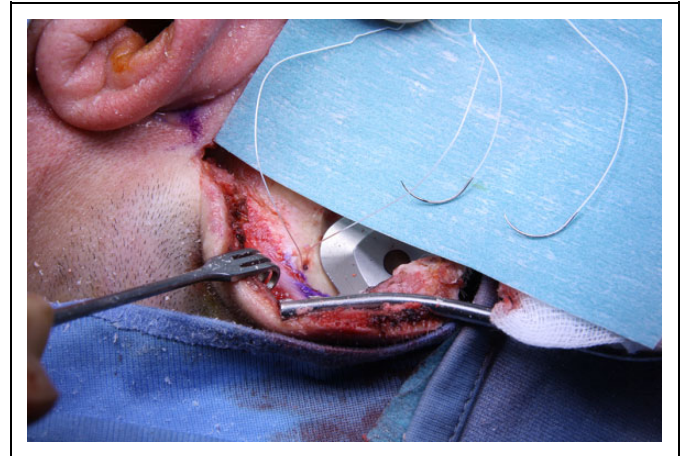
Similar to the suspension wiring technique,<sup>8</sup> we prepared 2 calibrated holes, 2.3-mm wide and 9-mm deep, using the drill bit supplied in the package at 3- and 9-o'clock positions of the receiver pocket. Through these pilot holes, we suggest placing the anchor obliquely across the R/S keeping a 30° angle, thus maximizing the entire bony thickness avoiding anchor over-penetration and dura mater damages. Moreover, the anchor itself acts as blockage reducing bleeding (Figure 1).

The MM is positioned with the aid of the insertion tool that keeps the wings collapsed, and, after the extrusion, the wings spread out to the resting position; differently, the MQP is set in the predrilled hole applying a gradual tension to the suture. The anchors should be inserted before the R/S to avoid CI movements with consequent electrode misplacement (Figure 2).

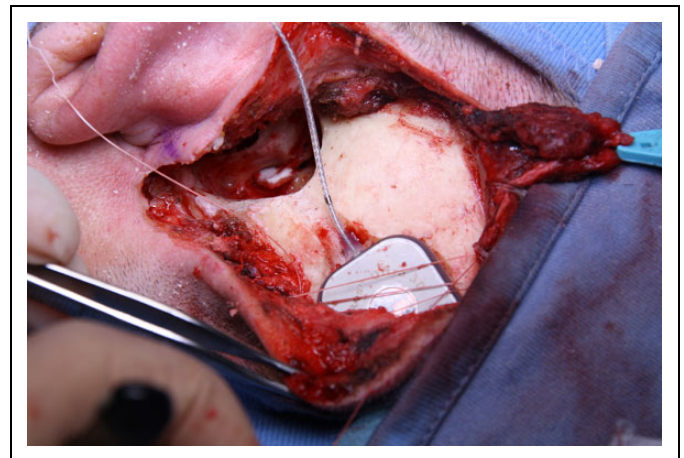
After that, we used 1 couple of precharged sutures to create a web of tie-down sutures to firmly fix the R/S (Figure 3). The other pair fixes the musculoperiosteal flap to the bone also in its central portion facilitating the taking root to the bare bone and avoiding a sort of “sagging” effect.

## Discussion

The standard surgical procedure to fix R/S in CI surgery consists of a first step in which, after skin incision, a musculoperiosteal flap is harvested. Beneath the flap, the bone is exposed



**Figure 2.** The anchor is inserted in the pilot hole, and the couple of 2.0 absorbable sutures is ready for use.



**Figure 3.** The web of tie-down sutures firmly fixes the receiver/stimulator (R/S).

and drilled to create a 2- to 3-mm-deep R/S-shaped pocket in which the R/S is precisely placed; this sort of R/S-shaped pocket improves the R/S stability. Then the flap is used to cover the implant, maintaining it adherent to the bone at the end of the surgery. Once mastoidectomy, posterior tympanotomy, and exposure of the round window have been done, the CI is carefully positioned.<sup>9</sup> In our opinion, the insertion is facilitated by keeping wet the array with hyaluronic acid to favor its sliding.<sup>10</sup> To perform the R/S fixation, different techniques may be adopted depending on distinct device features.

Some types of CI should be fixed using screws, and the R/S comes with preformed holes. In other models without holes, the R/S well has to be drilled out following the template provided by the manufacturer or it can be positioned in the pocket beneath the musculoperiosteal flap with a nonsutured fixation.<sup>11</sup>

The problems described using these techniques are various. The screws system is slightly thicker than the models without holes, thus exposing this system to increased risk of extrusion. Using the drill-out well technique,<sup>9</sup> 2 small bony canals are

created for passage of nonresorbable tie-down sutures. An excessive bleeding may occur due to the damage of the dura mater itself and its blood supply. Moreover, the superficial thin bony bridge is quite fragile, and it often can be broken during the suturing process, and the insertion of R/S is more hazardous when the skull cortical bone is particularly thin. Finally, drilling a shaped pocket into the bone in which place the CI is not sufficient to assure the adherence between the curved bone surface and the R/S, because the CI is not flexible enough and tends to preserve its original straight shape. This condition may cause a CI migration resulting in an array dislocation. So, the web of suture created with this technique can improve the stability of the bond of the R/S to the underlying curved bone surface, reducing the palpable thickness beneath the scalp. In our experience, the suture anchor system resulted in a less laborious manner to firmly fix CI in the receiver pocket decreasing the risk of intraoperative bleeding and R/S extrusion or migration, thus keeping the complication rate low. In fact, this technique allowed reducing the rate of hematoma or seroma (Supplemental file). The possibility to diagonally insert the anchor allowed a successful outcome also in cases with thin cortical bone.

We summarize some technical tips and tricks as follows:

1. The calibrated holes should be performed diagonally across the R/S to optimize stability while preserving the entire thickness of the bone by avoiding anchor overpenetration.
2. This technique might be performed using only 1 suture anchor; nevertheless, we suggest to use 2 anchors because the first pair of sutures is needed to create the web of suture and the second pair serves to fix the musculoperiosteal flap.
3. The suture should fix the musculoperiosteal flap also in its central portion, facilitating the taking root to the bare bone and avoiding the “sagging” effect.
4. Both these types of anchors are suitable for magnetic resonance imaging, and in our experience, they did not interfere with radiologic examinations during follow-up.<sup>6</sup>



### Declaration of Conflicting Interests

The author(s) declared no potential conflicts of interest with respect to the research, authorship, and/or publication of this article.

### Funding

The author(s) received no financial support for the research, authorship, and/or publication of this article.

### ORCID iD

Margherita Tofanelli  <https://orcid.org/0000-0002-5999-7883>  
 Alice Piccinato  <https://orcid.org/0000-0002-2619-5489>

### Supplemental Material

Supplemental material for this article is available online.

### References

1. Wang JT, Wang AY, Psarros C, Da Cruz M. Rates of revision and device failure in cochlear implant surgery: a 30-year experience. *Laryngoscope*. 2014;124(10):2393-2399.
2. Sunde J, Webb JB, Moore PC, Gluth MB, Dornhoffer JL. Cochlear implant failure, revision, and reimplantation. *Otol Neurotol*. 2013;34(9):1670-1674.
3. Jiang Y, Gu P, Li B, et al. Analysis and management of complications in a cohort of 1,065 minimally invasive cochlear implantations. *Otol Neurotol*. 2017;38(3):347-351.
4. Kunda LD, Stidham KR, Inserra MM, Roland PS, Franklin D, Roberson JB Jr. Silicone allergy: a new cause for cochlear implant extrusion and its management. *Otol Neurotol*. 2006;27(8):1078-1082.
5. Arnež ZM, Novati FC, Ramella V, et al. How we fix free flaps to the bone in oral and oropharyngeal reconstructions. *Am J Otolaryngol*. 2015;36(2):166-172.
6. Arnež ZM, Ramella V, Tofanelli M, Tirelli G. Suture anchors to fix free flaps in oral and oropharyngeal reconstruction. *Br J Oral Maxillofac Surg*. 2016;54(1):e5-e6.
7. Tirelli G, Tofanelli M, Boscolo Nata F, Ramella V, Arnež ZM. Anchors for sutures to fix pedicled flaps to the floor of the mouth in reconstructions for cancer. *Br J Oral Maxillofac Surg*. 2017;55(7):e41-e42.
8. Rizzo R, Maglione M, Tofanelli M, Tirelli G. Immediate obturator stabilization (ISO) in severely atrophic edentulous maxilla: suspension wiring technique. *Am J Otolaryngol*. 2016;37(2):125-127.
9. Sanna M, Free R, Merkus P, et al. Cochlear implantation. In: *Surgery for Cochlear and Other Auditory Implants*. Stuttgart, Germany: Thieme; 2015.
10. Marcuzzo AV, Tofanelli M, Boscolo Nata F, Gatto A, Tirelli G. Hyaluronate effect on bacterial biofilm in ENT district infections: a review. *APMIS*. 2017;125(9):763-772.
11. Boscolo-Rizzo P, Muzzi E, Barillari MR, Trabalzini F. Non-sutured fixation of the internal receiver-stimulator in cochlear implantation. *Eur Arch Otorhinolaryngol*. 2011;268(7):961-965.