

Appendix

Dyspnea: when the preliminary imaging is unconvincing

Angelica Moretti, Francesca Croci, Franco Carmassi

Non-commercial use only

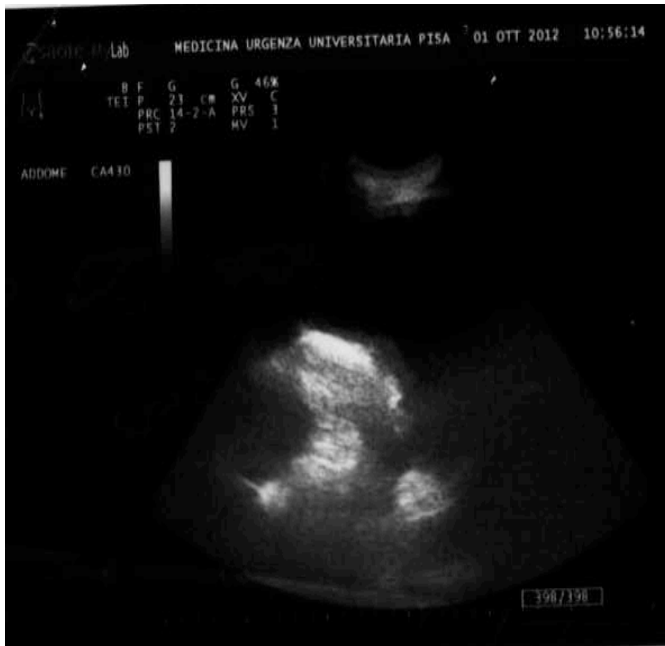

Figure 1

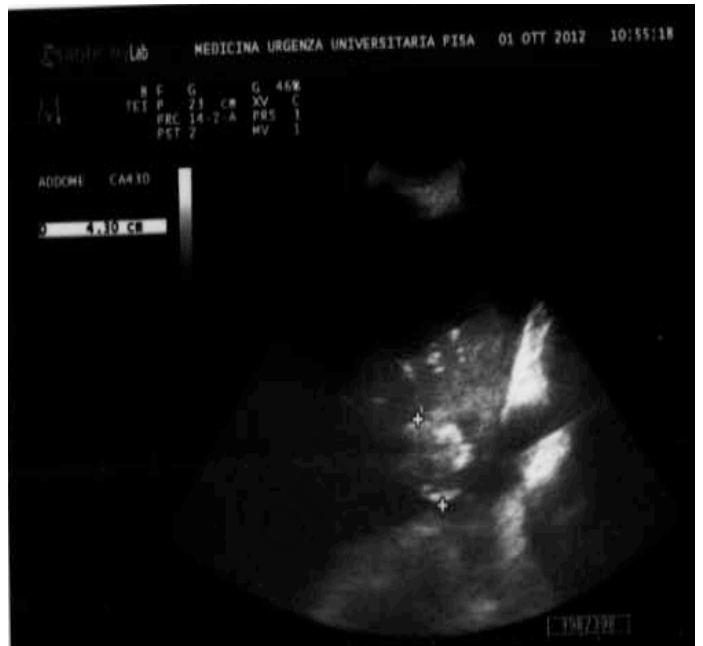

Figure 2

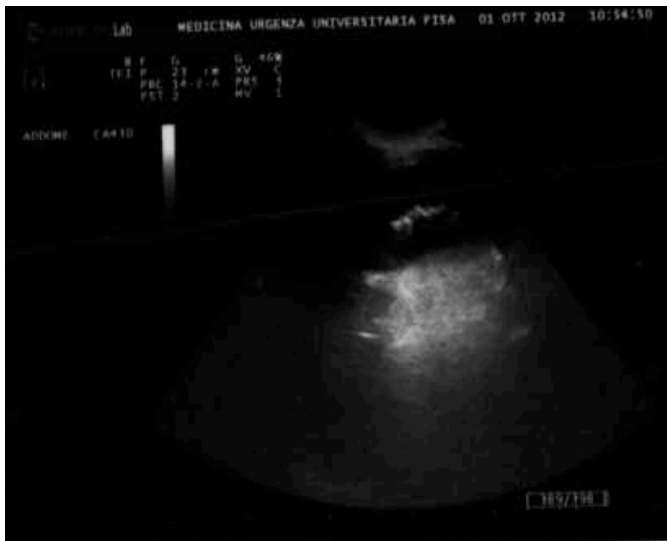

Figure 3

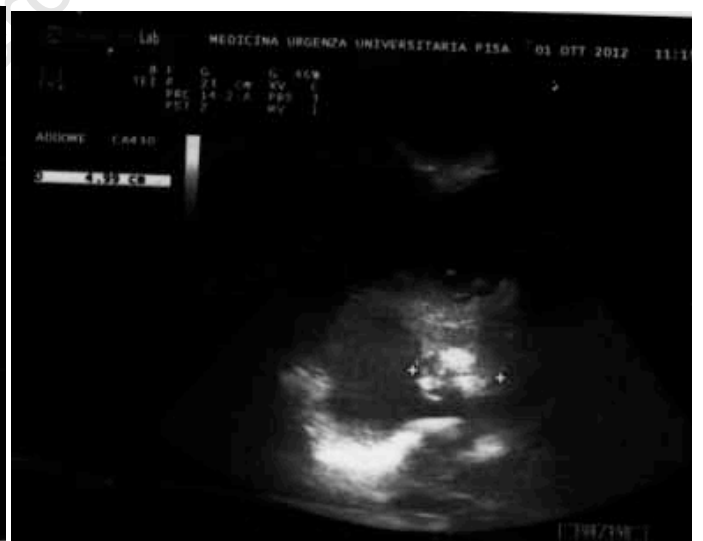

Figure 4

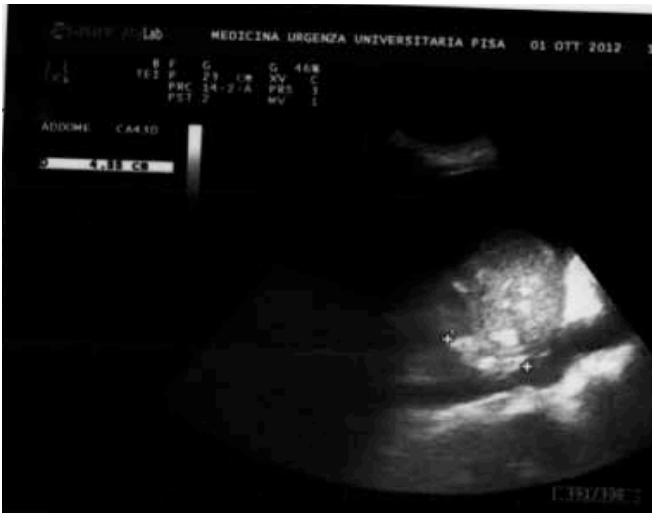

Figure 5

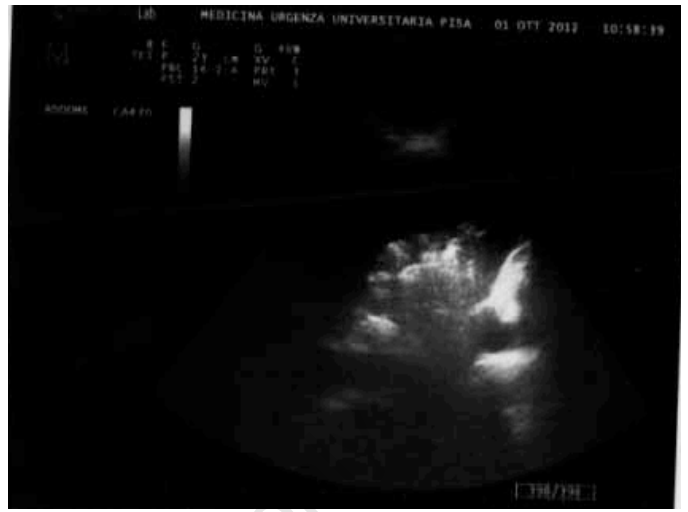

Figure 6

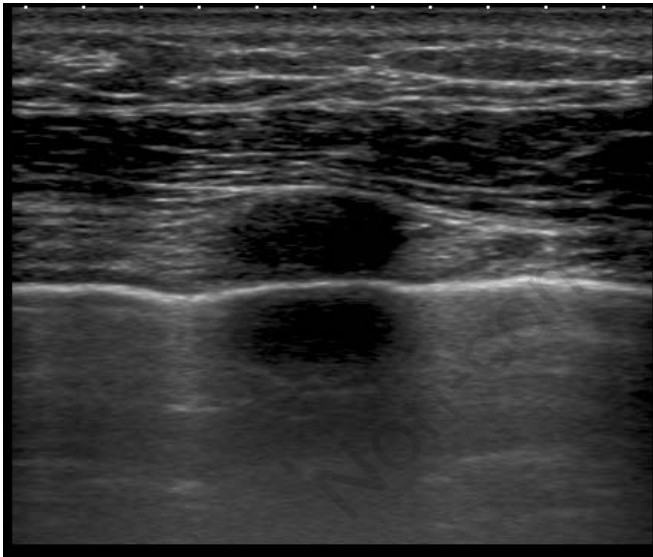


Figure 7

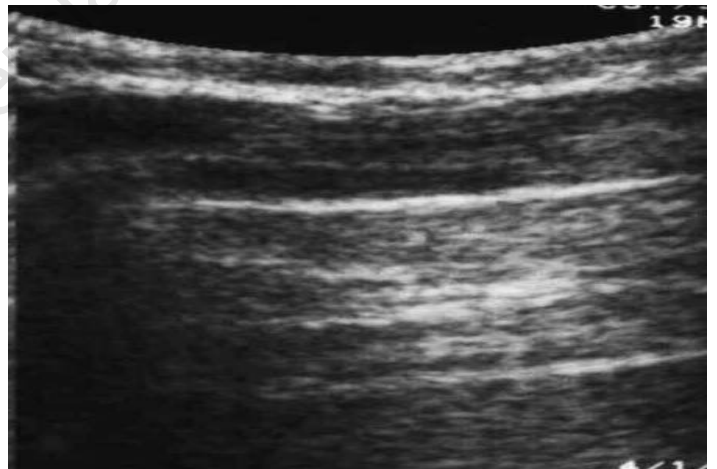


Figure 8

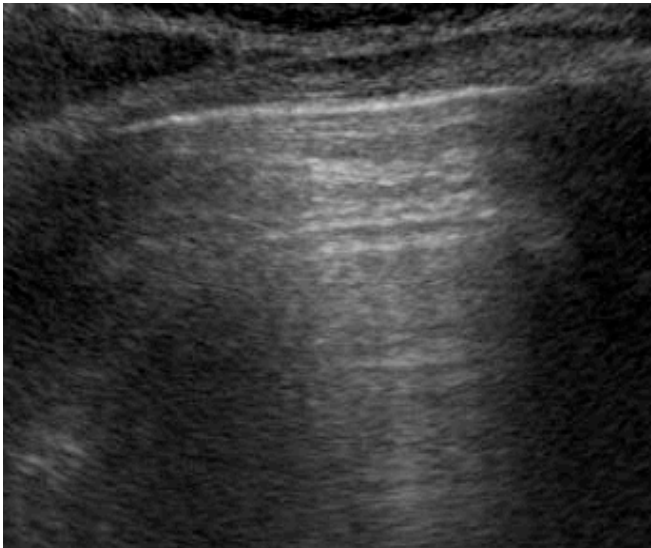

Figure 9

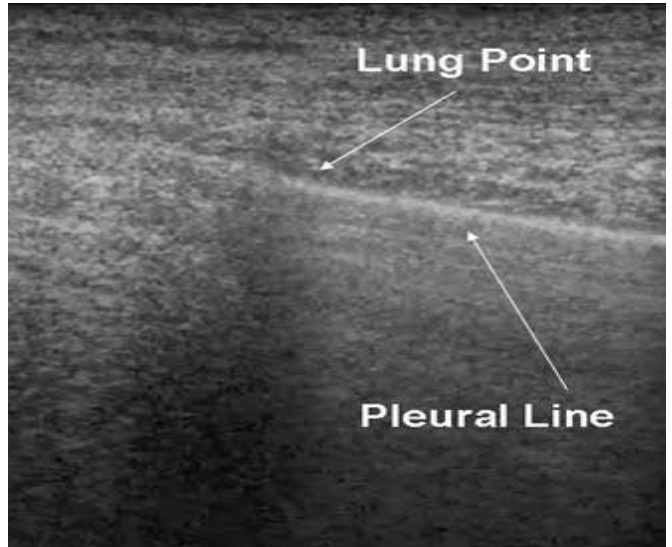


Figure 10

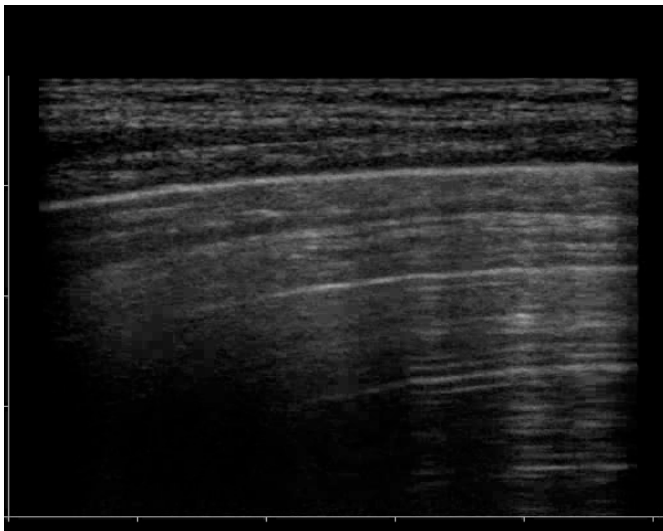


Figure 11

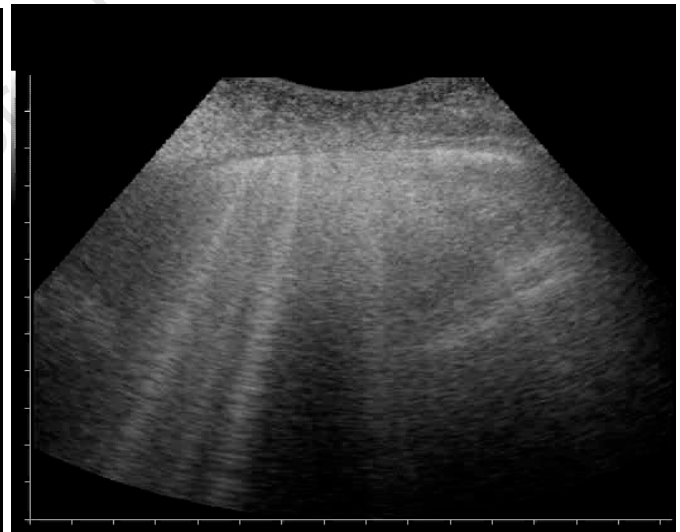


Figure 12

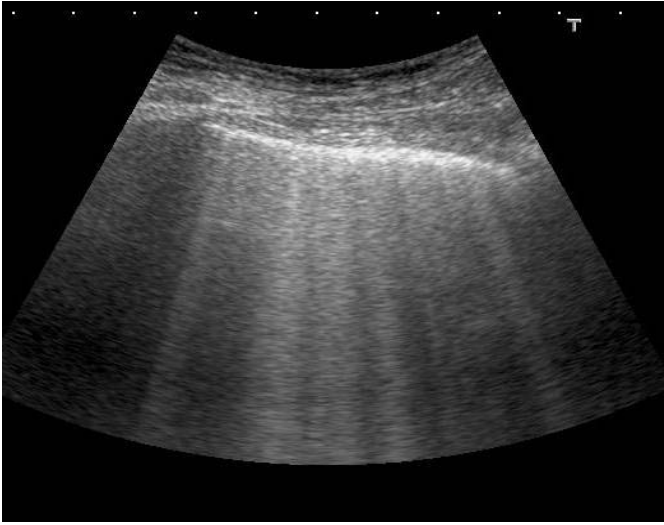


Figure 13

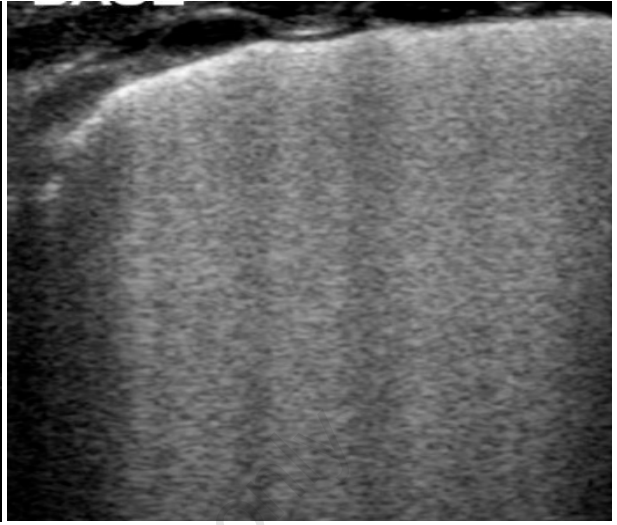


Figure 14

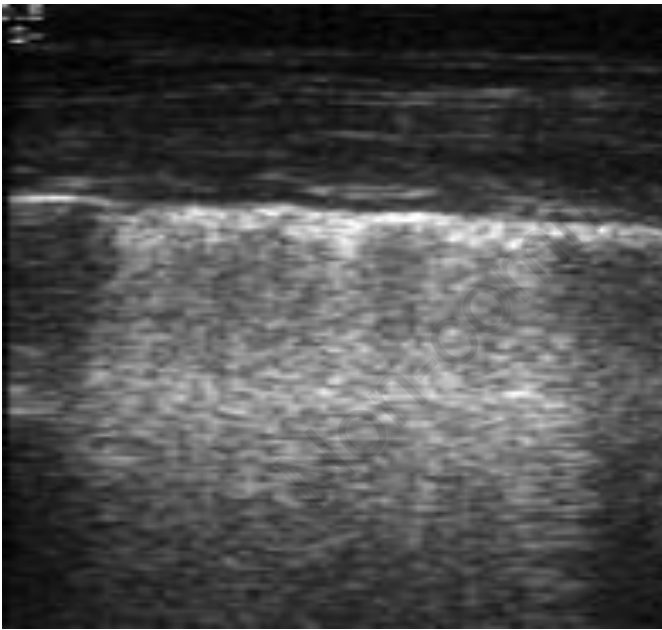


Figure 15

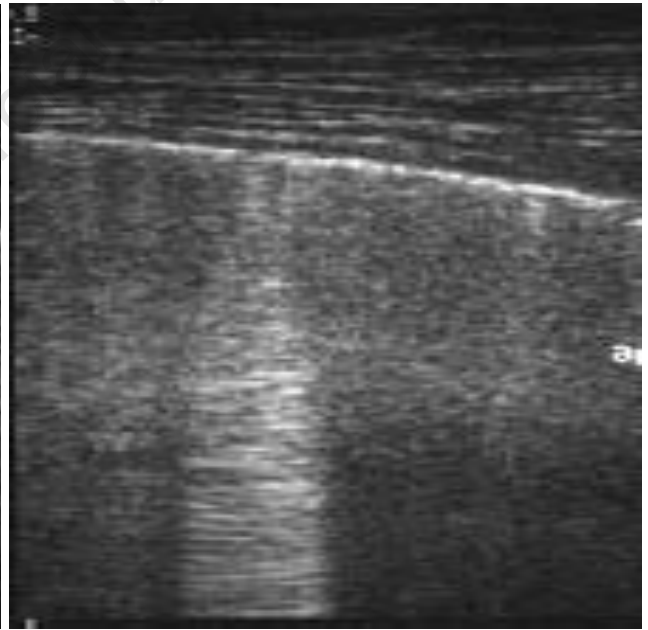


Figure 16

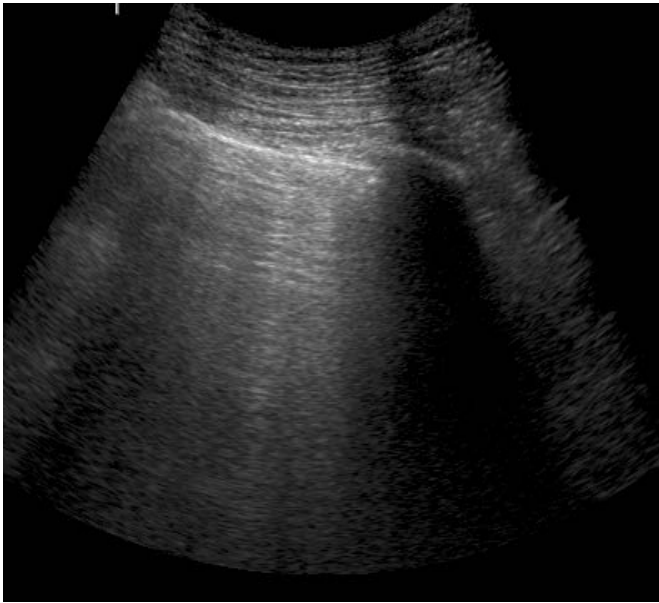


Figure 17

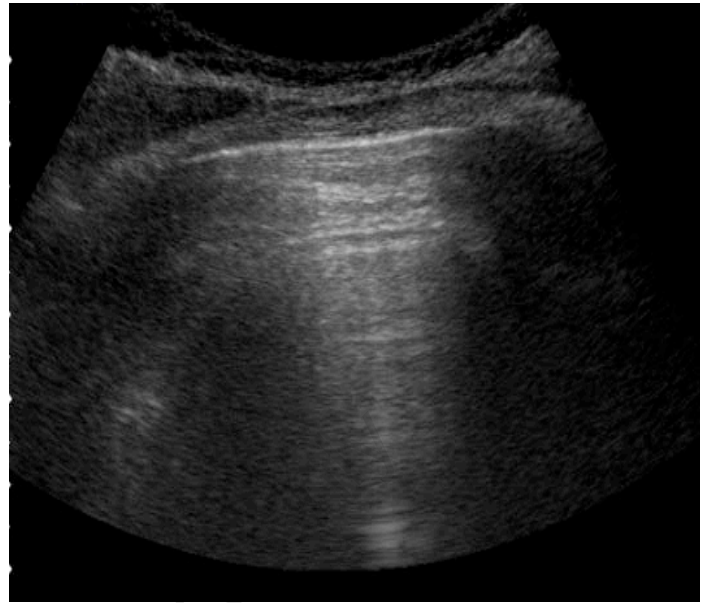


Figure 18

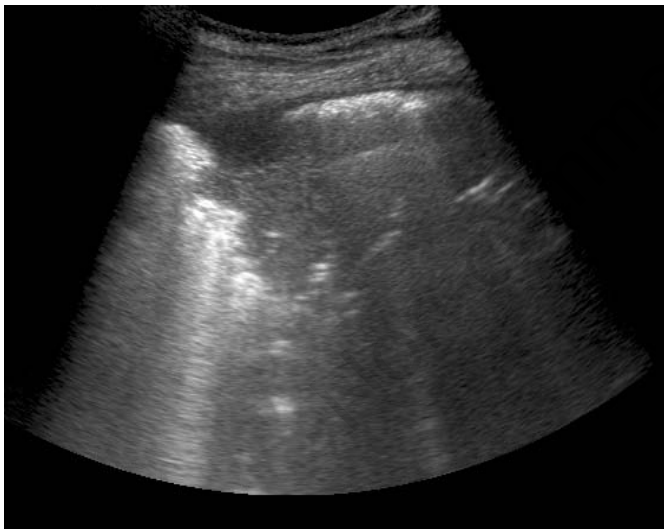

Figure 19

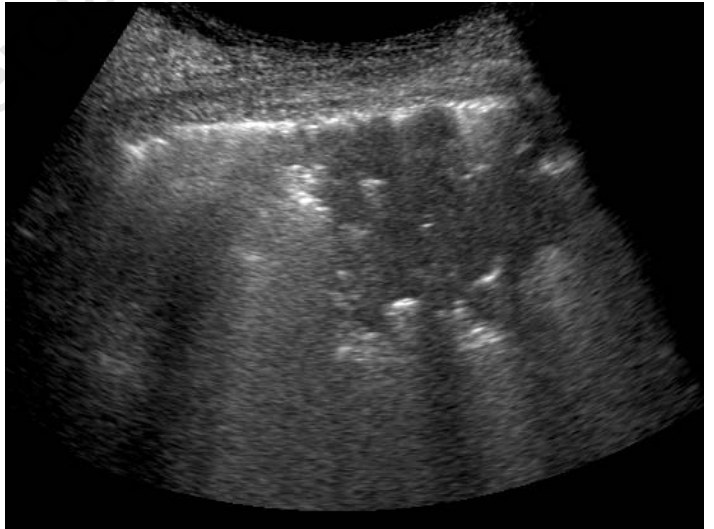


Figure 20

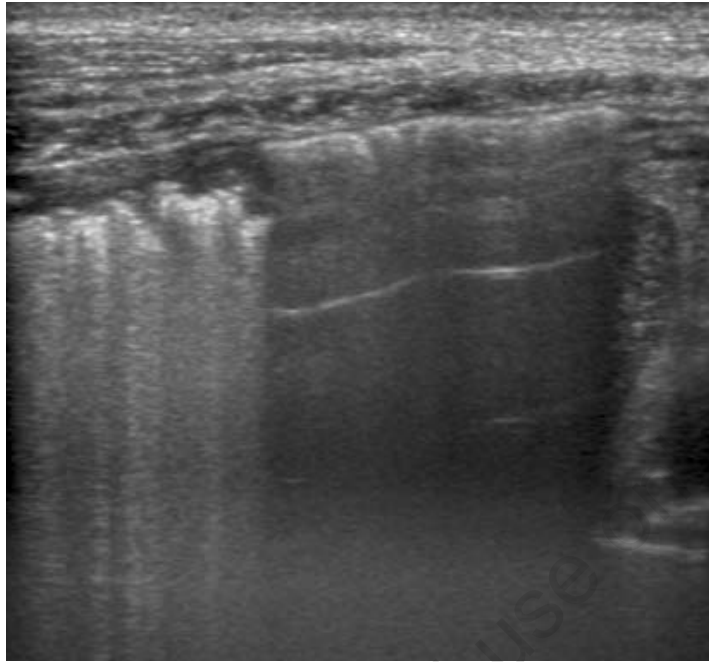


Figure 21

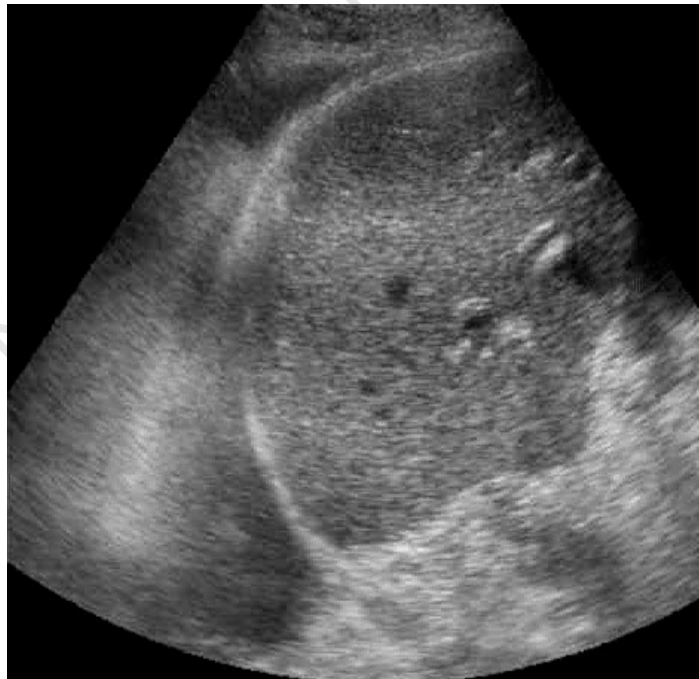

Figure 22

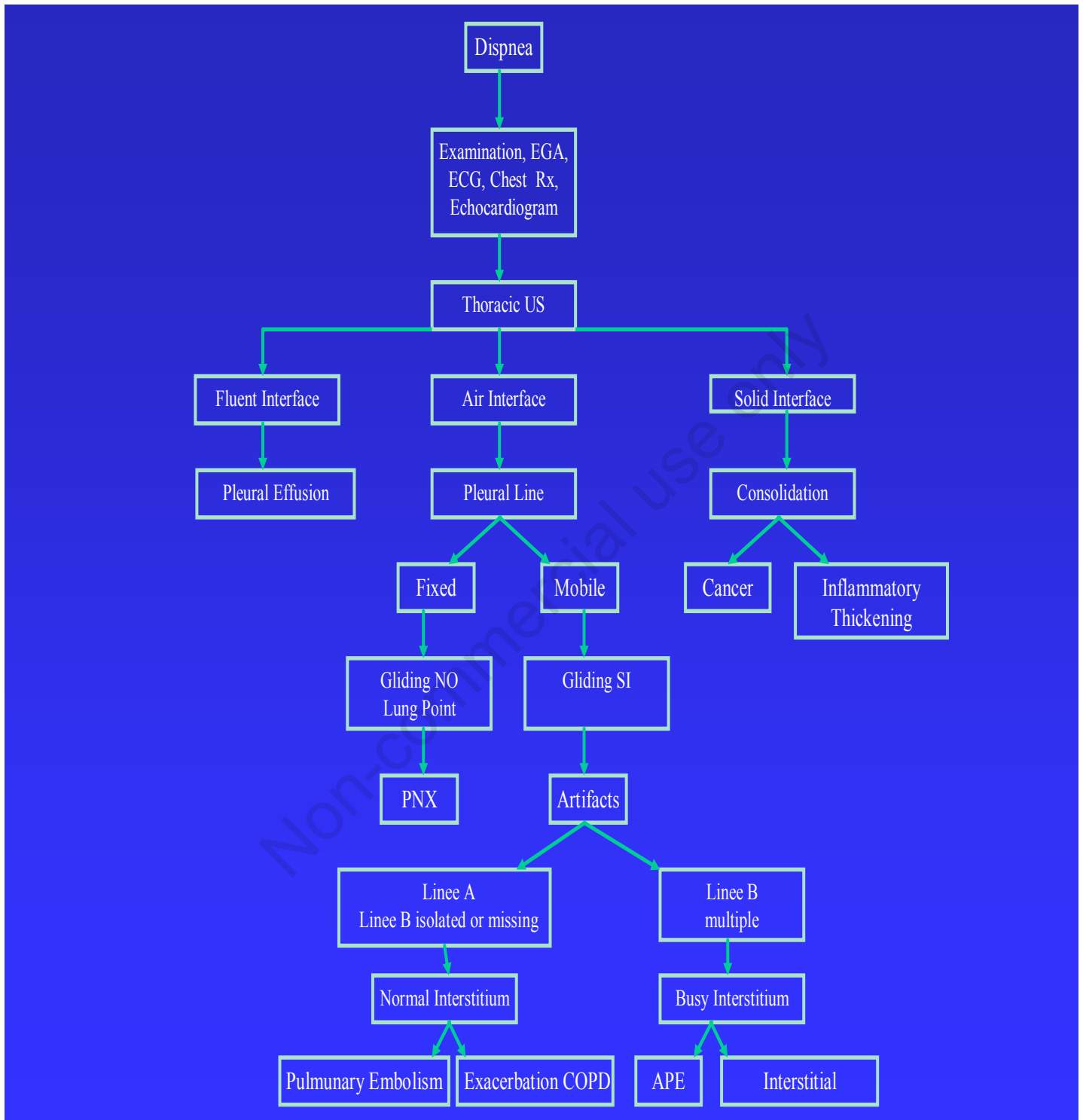


Figure 23. Flow-chart: role of thoracic ultrasound in patients with dyspnea (amended by flow-chart of Dr. Gian A. Cibinel-Pinerolo-Turin).