



# Laparoscopic-assisted nephroureterectomy for shaped urolithiasis and xanthogranulomatous pyelonephritis: Case report and review of literature

Valentina Pastore, Francesco Niglio, Angela Basile, Raffaella Cocomazzi, Maria Grazia Faticato, Gabriella Aceto<sup>1</sup>, Fabio Bartoli

## ABSTRACT

We report a case of xanthogranulomatous pyelonephritis (XGP) complicated by shaped urolithiasis, severe hydronephrosis and kidney exclusion treated by laparoscopic-assisted nephroureterectomy. A 9 year-old boy was referred to us for recurrent episodes of urinary tract infection, abdominal pain and severe hydronephrosis. Abdominal CT and a Tc-99m MAG3 scan showed a non-functioning obstructed kidney with shaped urolithiasis of the distal ureter. XGP was suspected, and nephroureterectomy was performed by laparoscopic distal ureterectomy and open extraperitoneal nephrectomy. This technique avoided the need for a more extended nephrectomy incision or even a second iliac incision. It also ensured complete excision of the distal ureter with minimal risk of developing the ureteral stump syndrome, which sometimes follows nephroureterectomy. We believe that laparoscopic-assisted nephroureterectomy may be a suitable technique in those cases of difficult nephrectomy where a ureteral stump syndrome is likely to develop.

**Key words:** Children, laparoscopic nephroureterectomy, urolithiasis, xanthogranulomatous pyelonephritis

## INTRODUCTION

Xanthogranulomatous pyelonephritis (XGP) is a severe, atypical chronic inflammatory disease accounting for 6/1000 surgically proved cases of chronic pyelonephritis,

characterized by destruction and replacement of renal parenchyma with granulomatous tissue containing histiocytes and foamy cells. XGP was first described in 1916 in adults, while the first paediatric case was observed in 1963.<sup>[1]</sup> It is commonly associated with chronic urinary obstruction, UTI, urolithiasis and severe renal damage. The peak incidence is in the sixth to seventh decade, with a female predominance, and the left kidney is more often affected.<sup>[2]</sup> Its aetiology is still unclear, though as many as six causes have been proposed: 1) urinary obstruction, 2) urinary tract infection (UTI), 3) abnormal lipid metabolism, 4) lymphatic obstruction, 5) altered immune response and 6) vascular occlusion.<sup>[3]</sup> The finding of lipids and cholesterol accumulation in the lesions has not been clarified yet.<sup>[4]</sup> Two forms of XGP have been described: A) diffuse (83-90%) and b) focal (10-17%). The focal form has been defined “the great imitator” because is often misdiagnosed as renal neoplasm. Malek and Elder have proposed a staging for XGP, STAGE I: The lesion is confined to the kidney; STAGE II: There is infiltration of Gerota’s space; STAGE III: XGP extends to perinephric space and other retroperitoneal structures.<sup>[5]</sup> Pseudoinflammatory tumours such as XGP can affect many organs such as gallbladder, appendix, bone<sup>[6]</sup>, ovarian<sup>[7]</sup>, bladder<sup>[8]</sup>, rectum<sup>[9]</sup>, prostate<sup>[10]</sup>, epididymis<sup>[11]</sup> and endometrium.<sup>[12]</sup> The most common symptoms are: Abdominal pain, fever, palpable mass, anorexia and weight loss, urinary tract infection with antibiotics-resistance, haematuria and dysuria. Laboratory findings are anaemia, leucocytosis and increased erythrocyte sedimentation rate (ESR).<sup>[13]</sup> *Escherichia coli* and *Proteus mirabilis* are the most common offending micro-organism<sup>[14]</sup> even if about one third of the patients have sterile urine. Rare complications are amyloidosis (described in four patients, one was a child)<sup>[15]</sup>, renocolic fistula<sup>[16]</sup>, psoas/paranephric abscess<sup>[17]</sup>, ischaemic colitis (involving transverse and descending colon)<sup>[18]</sup>, emphysematous pyelonephritis<sup>[19]</sup> and liver lesion.<sup>[20]</sup>

Department of Clinical and Surgical Medicine, Paediatric Surgery Unit, University of Foggia, Foggia, <sup>1</sup>Biomedicine of Evolutive Age, Paediatric Nephrology Unit, University of Bari, Bari, Italy

### Address for correspondence:

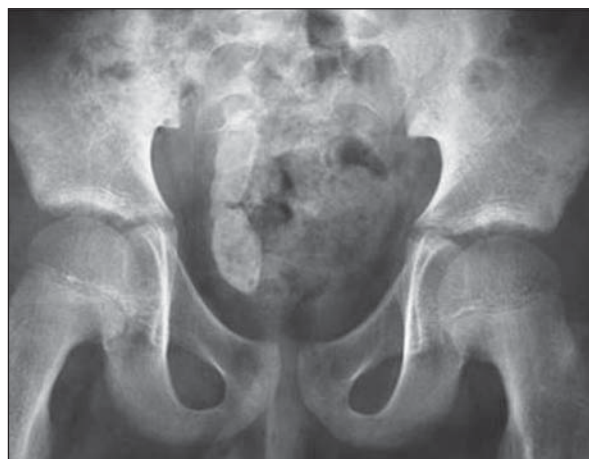Dr. Valentina Pastore, Paediatric Surgery Unit, University of Foggia, Viale Pinto 1-71122, Foggia, Italy.  
E-mail: valentina.pastore@teletu.it

Diagnostic procedures are abdominal plain x-ray, ultrasounds, CT scan intravenous pyelography (IVP) and MAG3/DTPA renal scan. Radiologically, plain x-ray of the abdomen reveals the presence of calculi, especially staghorn ones. Ultrasound of diffuse XGP shows an enlarged kidney with thinned parenchyma, calculus in renal pelvis, multiple fluid-filled masses, dilated pelvicaliceal system.<sup>[21]</sup> CT scan is probably the most valuable radiological technique in evaluating patients with XGP, because it helps establish the differentiation of the renal mass and determines the involvement of adjacent organs. Diagnosis is made by the presence of an enlarged, non-functioning kidney with staghorn calculus, caliceal dilatation, low attenuation areas replacing the renal parenchyma secondary to inflammatory infiltrate and perinephric standing.<sup>[22]</sup> A non-functioning or poorly functioning kidney is the most common finding on IVP and MAG3/DTPA renal scan. Pre-operative diagnosis and management of paediatric XGP is still obscure due to the limited number of cases and even if XGP could be supposed, only histopathological findings can confirm the diagnosis. XGP is commonly misdiagnosed preoperatively with pyelonephritis, tuberculosis, perirenal/ psoas abscess, renal clear-cell carcinoma and Wilm's tumour.<sup>[21]</sup> Histopathological diagnosis of resected kidney is mandatory.<sup>[2]</sup> Macroscopically, the kidney with diffuse XGP is enlarged with single/multiple yellow to orange nodules that can mimic tumour. Central necrosis with abscess formation, diffuse cortical scarring with effacement of the normal renal architecture and cortical atrophy could be observed. Microscopic changes diffusely or focally involve renal parenchyma and perirenal tissue, and granulomatous mixed inflammatory infiltrate (xanthomatous histiocytes with foamy cytoplasm, lymphocytes, plasma cells and multinucleated giant cells) are present. Renal tubular

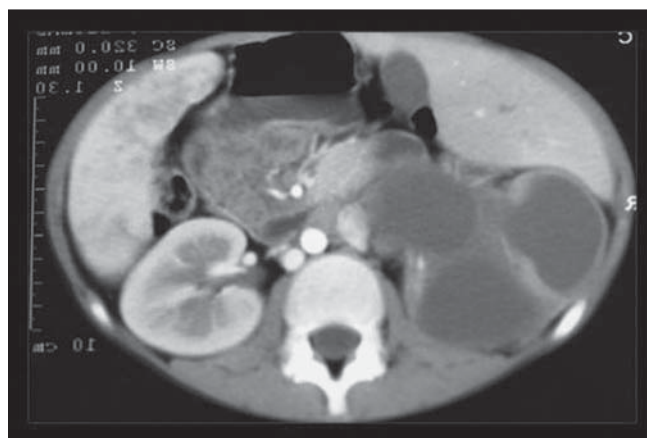
atrophy, focal squamous metaplasia of the urothelium, microabscess, and lymphoid aggregates with germinal centre formation can also be found.<sup>[23]</sup> In children with obstructive nephropathy, we observed high tissue expression and urinary levels of monocyte chemotactic protein-1 (a potent and specific chemotactic substance for monocytes) and, on the contrary, down-regulation of epidermal growth factor (which plays a key role in the modulation of renal growth, glomerular haemodynamics, renal metabolism and tubular epithelial turnover).<sup>[24,25]</sup> These findings seem to be even more pronounced in children with XGP.<sup>[26]</sup> Nephrectomy (partial or total) is the gold standard treatment, though technically difficult owing to extensive adhesions to the retroperitoneum, psoas muscle and surrounding structures. We report on a single patient with renal XGP and shaped distal urolithiasis treated by laparoscopic-assisted nephroureterectomy.

## CASE REPORT

A 9 year-old boy referred for severe right hydronephrosis, recurrent pyelonephritis and urolithiasis. His history was uneventful until 4 years of age when he experienced episodes of unexplained recurrent fever treated with antibiotics. He then remained asymptomatic until the age of 8 when he was admitted to the local General Surgery Unit because of acute abdominal pain on the right iliac area. Initial appendicitis was diagnosed and treated with i.v. antibiotics. A few months later, he developed recurrent episodes of UTI and pyelonephritis with weight loss, anaemia and abdominal pain. The renal ultrasound and contrast CT-scan showed severe right hydronephrosis with enlarged kidney [Figure 1] and shaped distal urolithiasis, [Figure 2] with functional exclusion of the kidney. The cystography was negative



**Figure 1: Plain abdominal x-ray: On the right side, the distal ureter is filled with radio-opaque stones**



**Figure 2: Contrast abdominal CT-scan: The kidney is enlarged with severe hydronephrosis and poor contrast enhancement**

for VUR. The Tc-99m MAG3 scan confirmed a mute kidney on the right and good compensatory function on the left. The pre-operative diagnosis was obstructive megaureter complicated by shaped urolithiasis and exclusion of renal function secondary to XGP.

### Operative procedure

After general and epidural anaesthesia, the child was placed in a supine position slightly rotated on the left. Then, a transperitoneal laparoscopic distal ureterectomy<sup>[27]</sup> was started. A caudal-cranial dissection began just proximal to the point where the vas deferens crosses the ureter and taken to a point just above the iliac vessels. Then, the ureter was divided and the stones removed. Both ureteral extremities were ligated between endoloops as distally as possible. Because laparoscopic kidney dissection was expected to be very difficult, nephrectomy was completed via the standard open extraperitoneal approach without changing the patient's position. The post-operative course was uneventful, and the child was discharged on the 3<sup>rd</sup> day. The histopathologist confirmed the diagnosis of XGP.

### DISCUSSION

Despite nephrectomy is considered the gold standard, antibiotic treatments have been proposed in children with rare bilateral and focal XGP (with functioning kidney).<sup>[28,29]</sup> However, pre-operative and post-operative broad-spectrum antibiotics and symptomatic management (i.e., percutaneous drainage of the abscess) can contribute to successful management of XGP.<sup>[30]</sup> The role of laparoscopic nephrectomy for XGP is still controversial but, although challenging, can be successfully performed, even in children.<sup>[31]</sup> However, a high conversion rate (27%) and longer operative time should be expected in adults<sup>[32]</sup> and in children.<sup>[33]</sup> Furthermore, nephrectomised children, especially those with vesico-ureteral reflux (VUR), may experience complications related to persistence of the distal ureteral stump. In our patient, the laparoscopic-assisted approach was chosen to remove the distal stone and, at the same time, minimize the residual ureteral stump. In fact, long ureteral stump may become symptomatic in the follow-up.<sup>[27]</sup> Laparoscopic distal ureterectomy was easily performed by starting the dissection just above the vas deferens crossing the ureter. As expected, nephrectomy was difficult because of dense inflammatory adhesions between the renal capsula and surrounding tissue. The laparoscopic-assisted approach avoided the need for a more extended nephrectomy incision or even a second iliac cut, which is often required in these cases.<sup>[34]</sup> Despite the operative

time was just higher when compared to standard open nephrectomy, the patient was discharged early with excellent functional and aesthetic results.

In conclusion, laparoscopic-assisted nephroureterectomy may be suitable for children who need a very distal ureterectomy and where nephrectomy, i.e., in XGP, cannot be accomplished laparoscopically because the kidney dissection is expected to be very difficult.

### REFERENCES

1. Avnet NL, Roberts TW, Goldberg HR. Tumefactive xanthogranulomatous pyelonephritis. *Am J Roentgenol Radium Ther Nucl Med* 1963;90:89-96.
2. Quinn FM, Dick AC, Corbally MT, McDermott MB, Guiney EJ. Xanthogranulomatous pyelonephritis in childhood. *Arch Dis Child* 1999;81:483-6.
3. Levy M, Baumal R, Eddy AA. Xanthogranulomatous pyelonephritis in children. Etiology, pathogenesis, clinical and radiologic features, and management. *Clin Pediatr* 1994;33:360-6.
4. Matthews GJ, McLoire GA, Churchill BA, Steckler RE, Khoury AE. Xanthogranulomatous pyelonephritis in pediatric patients. *Ped Urol* 1995;153:1958-9.
5. Malek RS, Elder JS. Xanthogranulomatous pyelonephritis: A critical analysis of 26 cases and review of the literature. *J Urol* 1978;119:589-93.
6. Cozzuto C. Xanthogranulomatous osteomyelitis. *Arch Pathol Lab Med* 1984;108:973-6.
7. Pace EH, Voet RL, Melacon JT. Xanthogranulomatous oophoritis: An inflammatory pseudotumour of the ovary. *Int J Gynecol Pathol* 1984;3:398-402.
8. Walther M, Glenn FJ, Vellios F. Xanthogranulomatous cystitis. *J Urol* 1985;134:745-6.
9. Davis M, Whitley ME, Haque HK, Fenoglio-Preiser C, Waterman R. Xanthogranulomatous abscess of a mullerian duct remnant. A rare lesion of the rect and anus. *Dis Colon Rectum* 1986;29:755-59.
10. Miekos E, Wlodarczyk W, Szram S. Xanthogranulomatous prostatitis. *Int Urol Nephrol* 1986;18:433-7.
11. Wiener LB, Riehl PA, Baum N. Xanthogranulomatous epididymitis: A case report. *J Urol* 1987;138:621-2.
12. Russack B, Lammers RJ. Xanthogranulomatous endometritis. Report of six cases and a proposed mechanism of development. *Arch Pathol Lab Med* 1990;114:929-32.
13. Siddapa S, Ramprasad K, Muddegowda MK. Xanthogranulomatous pyelonephritis: A retrospective review of 16 cases. *Korean J Urol* 2011;52:421-4.
14. Gupta G, Singh R, Kotasthane DS, Kotasthane VD, Kumar S. Xanthogranulomatous pyelonephritis in a male child with renal vein thrombus extending into the inferior vena cava: A case report. *BMC Pediatr* 2010;10:47.
15. Querfield U, Waldherr R, Twittenhoff W, Möhring K, Schäfer K. Generalized amyloidosis secondary to xanthogranulomatous pyelonephritis. *Eur J Pediatr*. 1986;145:565-8.
16. Matsuoka Y, Arai G, Ishimaru H, Takagi K, Aida J, Okada Y. Xanthogranulomatous pyelonephritis with a renocolic fistula caused by a parapelvic cyst. *Int J Urol* 2006;13:433-5.
17. Alan C, Ataus S, Tunc B. Xanthogranulomatous pyelonephritis with psoas abscess: 2 cases and review of the literature. *Int Urol Nephrol* 2004;36:489-93.
18. Su YJ, Lai YC, Chou CY, Chang H. Ischemic colitis secondary to xanthogranulomatous pyelonephritis. *Int J Infect Dis* 2009;13:e89-91.

19. Wen YK, Chen ML. Xanthogranulomatous pyelonephritis complicated by emphysematous pyelonephritis in a hemodialysis patient. *Clin Nephrol* 2007;68:422-7.
20. Karaman A, Samdanci E, Dogan M, Aksoy RT, Sigirci A, Demircan M. Xanthogranulomatous pyelonephritis with unconnected liver lesion. *Urology* 2011;78:189-91.
21. Li L, Parwani AV. Xanthogranulomatous pyelonephritis. *Arch Pathol Lab Med* 2011;135:671-4.
22. Craig WD, Wagner BJ, Travis MD. Pyelonephritis: Radiologic-pathologic review. *Radiographics* 2008;28:255-77.
23. Antonakopoulos GN, Chapple CR, Newman J, Crocker J, Tudway DC, O'Brien JM, *et al.* Xanthogranulomatous pyelonephritis: A reappraisal and immunohistochemical study. *Arch Pathol Lab Med* 1988;112:275-81.
24. Bartoli F, Gesualdo L, Paradies G, Caldarulo E, Infante B, Grandaliano G, *et al.* Renal expression of monocytes chemotactic protein-1 and epidermal growth factor in children with obstructive hydronephrosis. *J Pediatr Surg* 2000;35:569-72.
25. Grandaliano G, Gesualdo L, Bartoli F, Ranieri E, Monno R, Leggio A, *et al.* MCP-1 and EGF renal expression and urine excretion in human congenital nephropathy. *Kidney Int* 2000;58:182-92.
26. Bartoli F, Gesualdo L, Niglio F, Gentile O, Penza R, Leggio S, *et al.* Xanthogranulomatous pyelonephritis is associated with higher tissue expression of monocyte chemotactic protein-1. *Eur J Pediatr Surg* 2007;17:365-9.
27. Casale P, Grady RW, Lee RS, Joyner BD, Mitchell ME. Symptomatic refluxing distal ureteral stumps after nephroureterectomy and heminephroureterectomy. What should we do? *J Urol* 2005;173:204-6.
28. Gasmi M, Jemai R, Fitouri F, Ben Slama A, Sahli S, Hamzaoui M. Xanthogranulomatous pyelonephritis in childhood: Diagnosis difficulties and success of conservative treatment. *Tunis Med* 2010;88:427-9.
29. Gupta S, Araya CE, Dharnidharka VR. Xanthogranulomatous pyelonephritis in paediatric patients: Case report and review of literature. *J Pediatr Urol* 2010;6:355-8.
30. Dwivedi US, Goyal NK, Saxena V, Acharya RL, Trivedi S, Singh PB, *et al.* Xanthogranulomatous pyelonephritis: Our experience with review of published reports. *ANZ J Surg* 2006;76:1007-9.
31. Joshi AA, Parashar K, Chandran H. Laparoscopic nephrectomy for xanthogranulomatous pyelonephritis in children: The way forward. *J Pediatr Urol* 2008;4:203-5.
32. Arvind NK, Singh O, Ali Q, Gupta SS, Sahay S. Laparoscopic nephrectomy in xanthogranulomatous pyelonephritis: 7-year single-surgeon outcome. *Urology* 2011;78:797-801.
33. Holbrook C, Abdel Salam S, Kulkarni M, Mathur A. Laparoscopic complete/partial nephroureterectomy in children in a single institution-nearly a decade of experience: What have we learned? *Pediatr Surg Int* 2011;27:501-4.
34. Ku JH, Yeo WG, Kim HH, Choi H. Laparoscopic nephrectomy for renal disease in children: Is there a learning curve? *J Pediatr Surg* 2005;40:1173-6.

**Cite this article as:** Pastore V, Niglio F, Basile A, Cocomazzi R, Faticato MG, Aceto G, Bartoli F. Laparoscopic-assisted nephroureterectomy for shaped urolithiasis and xanthogranulomatous pyelonephritis: Case report and review of literature. *Afr J Paediatr Surg* 2013;10:285-8.

**Source of Support:** Nil. **Conflict of Interest:** No.

Copyright of African Journal of Paediatric Surgery is the property of Medknow Publications & Media Pvt. Ltd. and its content may not be copied or emailed to multiple sites or posted to a listserv without the copyright holder's express written permission. However, users may print, download, or email articles for individual use.