

Technical notes & surgical techniques

Repair of a spinal pseudomeningocele in a delayed postsurgical cerebrospinal fluid leak using titanium U-clips: Technical note



Giovanni Federico Nicoletti^a, Giuseppe Emmanuele Umana^b, Francesca Graziano^c, Agatino Florio^a, Gianluca Scalia^{a,d,*}

^a Division of Neurosurgery, Highly Specialized Hospital of National Importance "Garibaldi", Catania, Italy

^b Department of Neurosurgery, Cannizzaro Hospital, Trauma Center, Gamma Knife Center, Catania, Italy

^c Department of Experimental Biomedicine and Clinical Neurosciences, School of Medicine, Postgraduate Residency Program in Neurological Surgery, Neurosurgical Clinic, AOUP "Paolo Giaccone", Palermo, Italy

^d Division of Neurosurgery, Department of Biomedical and Dental Sciences and Morpho-Functional Imaging, University of Messina, Messina, Italy

ARTICLE INFO

Keywords:

Spine surgery
Durotomy
Cerebrospinal fluid leak
Titanium
U-clips

ABSTRACT

Introduction: Chronic cerebrospinal fluid leak (CCFL) represents a possible event following spine surgery, with an incidence rate ranging from 5 to 18%. In literature have been reported few modification techniques that involved the use of titanium U-clips with the aim to reduce dural traumatism during its closure but only after non-accidental durotomy.

Case illustration: We report the case of a 47-year-old female with history of L5-S1 microsurgical discectomy. After one year the patient was admitted to our unit because she presented progressive skin swelling in the lumbar region, intermittent headache and recurrent episodes of lipothymia. One-year MRI showed a voluminous subcutaneous cerebrospinal fluid (CSF)-like intensity collection in the T2-weighted sequences and communicating with the right L5-S1 interlaminar space. A second surgery revealed pseudomeningocele and a 5 mm dural defect is identified. At first, a tobacco pouch was created, and a suture with Prolene 6-0, a non-absorbable, synthetic monofilament, is made on the previously dissected tissue. In a second step, 2 medium/short non-penetrating titanium U-clips are applied with a multi-clip applier. There was no sign of recurrent pseudomeningocele in the 2-year follow-up.

Conclusion: The authors presented a novel use of titanium U-clips to manage an insidious and complex case of pseudomeningocele in a CCFL. U-clips represent a safe and effective tool in CCFL repair.

1. Introduction

Chronic cerebrospinal fluid leak (CCFL) represents a possible event following spine surgery, with an incidence rate ranging from 5 to 18%. [1,2] Cerebrospinal fluid (CSF) post-operative leakage is usually a benign complication which resolves spontaneously and when not properly treated can lead to major insidious sequelae like frontotemporal brain sagging syndrome, subdural hygroma or hematoma, arachnoiditis, meningitis, pseudomeningocele, cutaneous fistula, infections, and delay in wound healing causing patient's discomfort [3,4] with increased overall comorbidity and hospital costs. [5] With the aim of effectively face this insidious pathological entity, technical modifications to the surgical procedure of the non-accidental durotomy repair have been

reported [6,7]. Standard dural closure is accomplished with monofilament suturing [8,9] but unfortunately, the suturing wire produces further dural perforation while it passes through the dura and can induce dural and or arachnoid irritation [10]. In literature have been reported few modification techniques involving the use of titanium U-clips with the aim to reduce dural traumatism during its closure but only in non-accidental durotomy. We present the a novel use of non-penetrating titanium U-clips applied with a multi-clip applier for the treatment of a complex case of chronic spinal CSF leakage.

Abbreviations: CCFL, chronic cerebrospinal fluid leak; CSF, cerebrospinal fluid; MRI, magnetic resonance imaging

* Corresponding author at: Division of Neurosurgery, Department of Biomedical and Dental Sciences and Morpho-Functional Imaging, University Hospital Policlinico "G. Martino", Via Consolare Valeria, 1, 98124 Messina, Italy.

E-mail address: gianluca.scalia@outlook.it (G. Scalia).

<https://doi.org/10.1016/j.inat.2020.100742>

Received 26 March 2020; Received in revised form 29 March 2020; Accepted 12 April 2020

2214-7519/© 2020 The Authors. Published by Elsevier B.V. This is an open access article under the CC BY-NC-ND license (<http://creativecommons.org/licenses/by-nc-nd/4.0/>).

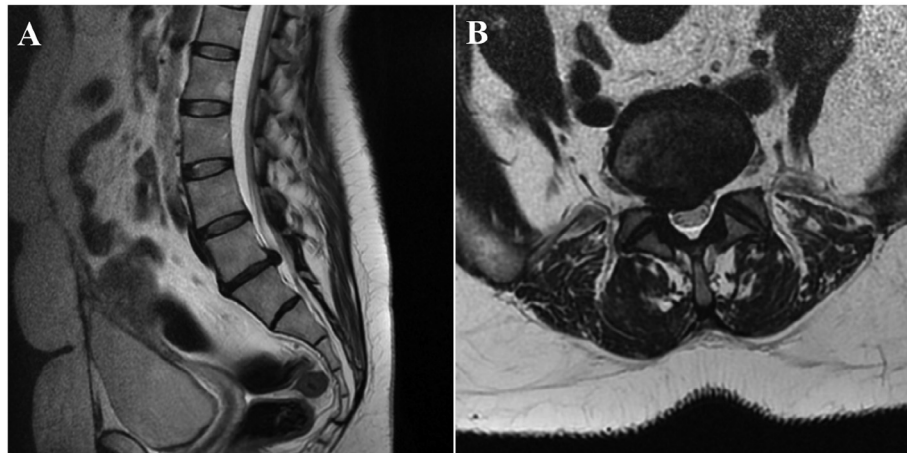


Fig. 1. Preoperative sagittal (A) and axial (B) T2-weighted MRI sequences showing a median-paramedian right L5-S1 disc herniation.

2. Case description

2.1. History and physical examination

We report the case of a 47-year-old female patient who underwent L5-S1 microsurgical discectomy with a right interlaminar approach, due to the presence of severe right lumbosciatica secondary to median-paramedian right L5-S1 disc herniation. (Fig. 1) Unintended durotomy during surgery was not recorded. The patient presented a regular post-operative course with complete regression of the symptoms. After one year, the patient was admitted to our unit with a history of about three months of progressive skin swelling in the lumbar region, intermittent headache and recurrent episodes of lipothymia.

2.2. Imaging

Lumbosacral spine MRI showed the presence of a voluminous subcutaneous cerebrospinal fluid (CSF)-like signal collection in the T2-weighted images and communicating with the right L5-S1 interlaminar space, site of previous surgery. The presence of a pseudomeningocele caused by a chronic CSF leak was postulated. (Fig. 2) Following the failure of conservative treatment consisting of acetazolamide administration and external lumbar CSF drainage, the patient underwent surgical treatment to repair the dural defect.

2.3. Surgical technique

The patient is placed prone on the operating table. The previous surgical scar is enlarged at the cranial and caudal ends. Immediately

after the skin incision is accessed the cavity of the pseudomeningocele which has a pearly appearance, due to the fibrotic inflammatory reaction. Following placement of a self-retaining retractor, the dural defect of about 5 mm is identified. A circular shaped microsurgical dissection of the fibrotic tissue is carried out, creating a tobacco pouch around the dural leak. (Fig. 3A) At first, a suture with Prolene 6-0, a non-absorbable, synthetic monofilament, is made on the previously dissected tissue. (Fig. 3 B) In a second step, 2 medium/short non-penetrating titanium U-clips are applied with a multi-clip applier (Ligaclip®, Ethicon, LLC, Medical GmbH, Norderstedt, Germany). (Fig. 3 C-E, Video 1) Then, additional double layer TachoSil® gelatine sponge fibrin sealant (Baxter, Deerfield, IL, USA) and Tisseel® (Baxter, Deerfield, IL, USA) sealant liquid glue is applied over the U-clips. (Fig. 3 F, G). A meticulous verification of the dural closure is performed after intraoperative Valsalva maneuver and reverse Trendelenburg position. Finally, the upper surgical layers are meticulously sutured eliminating dead spaces.

2.4. Postoperative course

Following surgery, the patient maintained flat bed rest and a compressive dressing for 48 h. On the post-operative day 7, the patient was discharged without presenting symptoms and short-term complications. 6-weeks lumbosacral spine MRI revealed no further subcutaneous CSF collections. At the last follow-up (2 years) the patient is still in good clinical status.

3. Discussion

In literature only few authors report the utility of titanium non

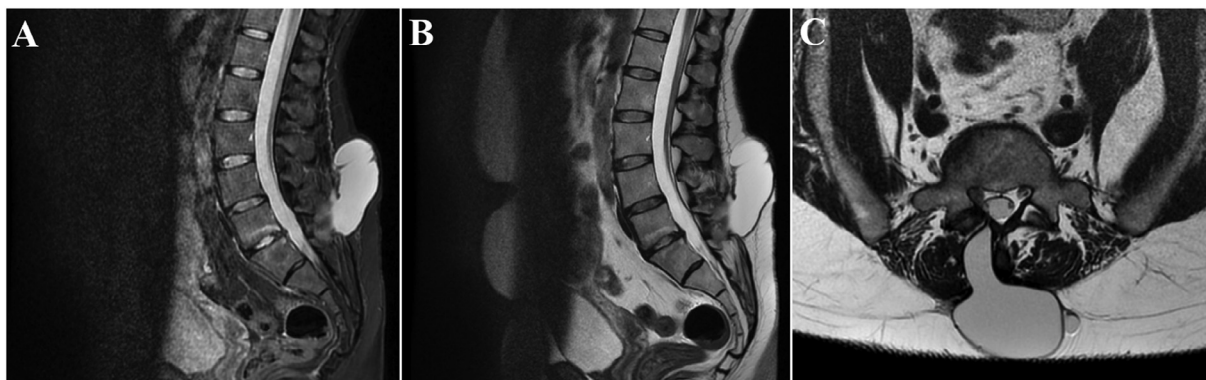


Fig. 2. Lumbosacral spine MRI performed after one year after the previous surgery showing a voluminous subcutaneous CSF-like signal collection in sagittal FLAIR (A), sagittal (B) and axial T2-weighted images (C), communicating with the right L5-S1 interlaminar space, strongly suspected for pseudomeningocele.

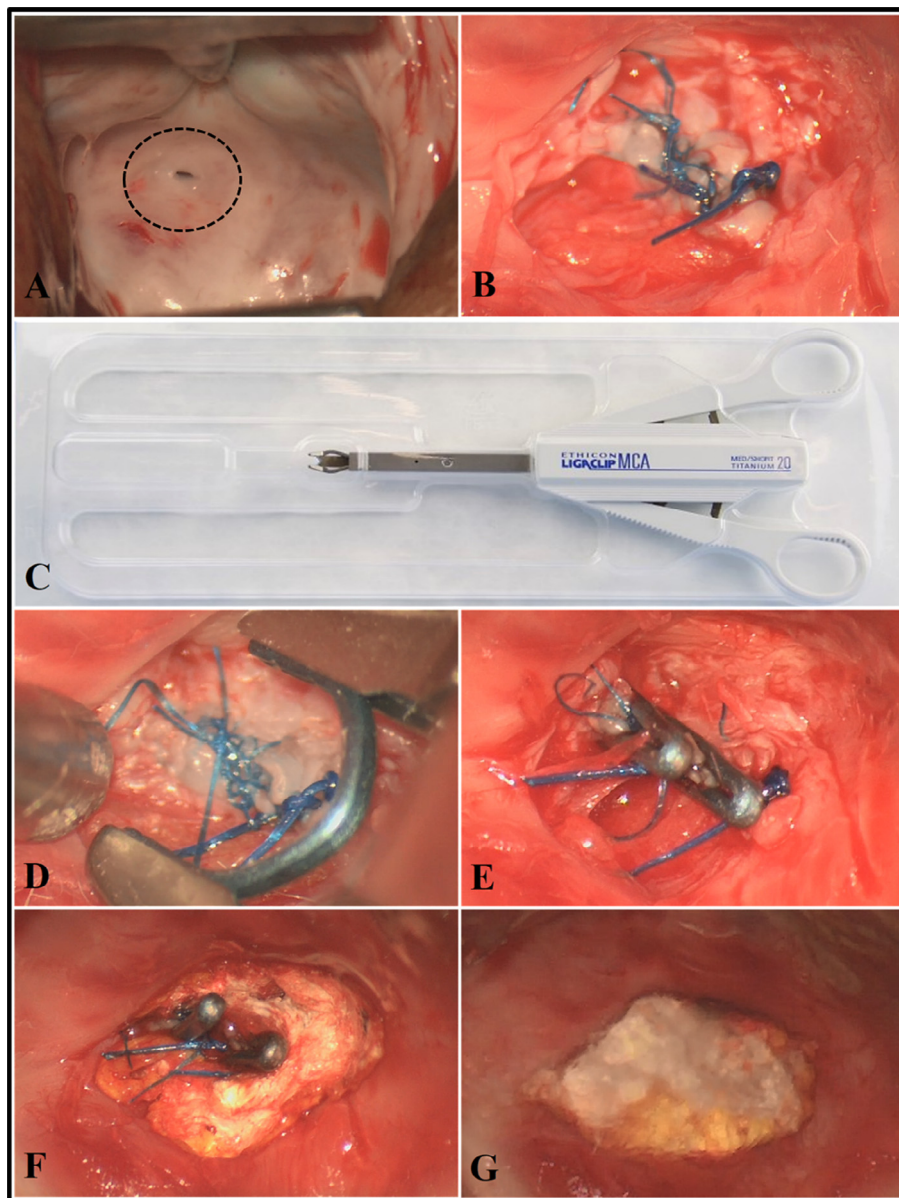


Fig. 3. A circular shaped microsurgical dissection of the fibrotic tissue is carried out, creating a tobacco pouch around the dural leak. (dash circle) (A) At first, a suture with Prolene 6-0, a non-absorbable, synthetic monofilament, is made on the previously dissected tissue. (B) In a second step, 2 medium/short non-penetrating titanium U-clips are applied with a multi-clip applier (Ligaclip®, Ethicon, LLC, Medical GmbH, Norderstedt, Germany). (C-E) Then, additional double layer TachoSil® gelatine sponge fibrin sealant (Baxter, Deerfield, IL, USA) and Tisseel® (Baxter, Deerfield, IL, USA) sealant liquid glue is applied over the U-clips. (F, G).

penetrating U-clips in non-accidental durotomy [5,10,11]. Titanium U-clips have been also described in the pediatric population [12].

A rare cause of spinal CSF leak is an unrecognized durotomy, and our case may be counted among them. Fang et al. reported an incidence of unrecognized durotomy during spinal surgery of about 6.8%. [13]

In our case, the delay in clinical presentation of the spinal CSF leak and pseudomeningocele could be due to an alteration between the pressures at the level of the subarachnoid and epidural space with a significant increase in this latter. In particular, the use of corticosteroids and weight gain would have led to an increase in CSF pressure and consequently of the inversion of the pressure gradient, with a progressive CSF leak from a minor resistantia locus represented by the dissected ligamentum flavum and not recognized intraoperatively.

Cobb and Ehni [14] stated that the smaller the dural defect, the greater the probability of pseudomeningocele formation, through a valve mechanism and a unidirectional flow of CSF.

There are three main causes of pseudomeningocele: iatrogenic, post-

traumatic and congenital. Certainly, the most frequent cause is iatrogenic with an incidence ranging from 0.3% to 13% in lumbar laminectomy procedures. [15] In the event of trauma, the development of CSF dural leak and pseudomeningocele at the cervical level, unlike the lumbar spine, is not associated with vertebral fractures but is determined by avulsions of the nerve roots. [16] Finally, syndromes have been described (Marfan syndrome and neurofibromatosis) in which there may be a congenital defect of collagen synthesis, with the development of congenital radicular or ganglion CSF cysts at the thoracolumbar level that can cause the spontaneous intracranial hypotension [17].

Several spinal CSF leak repair techniques have been reported to date from primary closure with sutures with or without fibrin sealant augmentation to a wide range of auto or allografts and patches [9,18,19].

In particular, the use of an autologous fat graft in the repair of spinal CSF leak has been widely described. Fat tissue is in fact the ideal sealant as it is waterproof. This should be used in association with fibrin glues

and/or sponge fibrin sealant to be more effective, covering the entire exposed dural surface and not just the dural defect [20].

The suture technique is based on surgeon experience with the primary goal of achieving a watertight dural closure. Dafford et al. [21] reported that in suture with a large needle diameter such as prolene, CSF leakage is often passing through the inlet and outlet of the suture needle despite a technically adequate closure. To confirm this, standard dural closure with stitches using monofilament suture presents 8% of CSF leakage risk [22-26].

In our case, chronic spinal CSF leak repair can be defined as indirect, as the margins of the previously dissected fibrotic tissue around the dural defect have been sutured, creating a tobacco pouch. In a second step we further positioned two U-clips, reaching the goal of a watertight dural closure.

The mechanical efficacy of U-clips has been verified, since by determining and immediate hydrostatic strength can be compared to the intact dura [27]. Moreover, the time of using and positioning of the U-clips is far less than any suturing technique. Despite that, Timothy et al. [28] reported a CSF leakage incidence of 13.7% after adult spine surgery in which the titanium clips were used to dural closure. An undesirable effect is represented by the reduction of the intrathecal sac space caused by the need of evert the dural edges necessary to apply the clips. On the other hand, in a large series of patients have been demonstrated that such reduction of diameter is asymptomatic [5]. It is easy to understand that U-clips are more comfortably used if the durotomy is was carried out dorsally, conversely their use to repair lateral or anterior defect can be technical demanding and sometimes not feasible [9]. Radiological follow-up is not compromised by titanium clips that are MRI compatible and do not cause significant artifacts [29]. The utility of non-penetrating titanium U-clips for dural closure has been previously described but only in non-accidental durotomy and it is effective, simple reducing the impact of the surgeon's skills as a risk factor for CSF leakage [12,30,31].

4. Conclusion

The authors presented a technical report in which U-clips are used to manage an insidious case of CCFL. In the case described, the dural defect was easily closed with the U-clips, after performing a tobacco pouch. U-clips represent a safe and effective alternative option in CCFL repair.

5. Authorship contributions

Category 1

Conception and design of study:

Acquisition of data: Gianluca Scalia, Giuseppe Emmanuele Umama, Agatino Florio.

Analysis and/or interpretation of data: Giovanni Federico Nicoletti, Gianluca Scalia, Giuseppe Emmanuele Umama, Agatino Florio.

Category 2

Drafting the manuscript: Gianluca Scalia, Giuseppe Emmanuele Umama, Giovanni Federico Nicoletti, Francesca Graziano.

Revising the manuscript critically for important intellectual content: Gianluca Scalia, Giovanni Federico Nicoletti, Giuseppe Emmanuele Umama, Francesca Graziano.

Category 3

Approval of the version of the manuscript to be published (the names of all authors must be listed): Giovanni Federico Nicoletti MD, Giuseppe Emmanuele Umama MD, Francesca Graziano MD, PhD, Agatino Florio MD, Gianluca Scalia MD.

Acknowledgement

None.

Declaration of patient consent

Patient's consent not required as patient's identity is not disclosed or compromised.

Funding support and sponsorship

This research did not receive any specific grant from funding agencies in the public, commercial, or not-for-profit sectors.

Ethics approval

There is no ethical issue in this paper.

Conflicts of interest

There are no conflicts of interest.

Appendix A. Supplementary data

Supplementary data to this article can be found online at <https://doi.org/10.1016/j.inat.2020.100742>.

References

- [1] D.K. Ahn, H.S. Park, D.J. Choi, K.S. Kim, T.W. Kim, S.Y. Park, The surgical treatment for spinal intradural extramedullary tumors, *Clin. Orthop. Surg.* 1 (2009) 165–172.
- [2] K.I. Arnautovic, M. Kovacevic, CSF-related complications after intradural spinal tumor surgery: utility of an autologous fat graft, *Med. Arch.* 70 (2016) 460–465.
- [3] J. Koo, R. Adamson, F.C. Wagner Jr, D.B. Hrdy, A new cause of chronic meningitis: infected lumbar pseudomeningocele, *Am. J. Med.* 86 (1989) 103–104.
- [4] E.F. Verner, D.M. Musher, Spinal epidural abscess, *Med. Clin. North Am.* 69 (1985) 375–384.
- [5] F.M. Marin Laut, E.A. Gómez Cárdenas, J.R. Dormido, N.M. Molina, J.A. López López, Spinal dural closure without suture: Minimizing the risk of CSF leakage with a flat non-penetrating titanium U-clip, *Neurocirugia (Astur)* 30 (4) (2019) 173–178.
- [6] S.J. Bosacco, M.J. Gardner, J.T. Guille, Evaluation and treatment of dural tears in lumbar spine surgery: a review, *Clin. Orthop. Relat. Res.* 389 (2001) 238–247.
- [7] F. Girgis, M. Shing, S. Duplessis, Thoracic epidural blood patch for spontaneous intracranial hypotension: case report and review of the literature, *Turk. Neurosurg.* 25 (2015) 320–325.
- [8] F.J. Eismont, S.W. Wiesel, R.H. Rothman, Treatment of dural tears associated with spinal surgery, *J. Bone Jt. Surg. Am.* 63 (1981) 1132–1140.
- [9] Y.X. Chen, L.E. Chen, A.V. Seaber, J.R. Urbaniak, Comparison of continuous and interrupted suture techniques in microvascular anastomosis, *J. Hand Surg. Am.* 26 (2001) 530–539.
- [10] S.J. Palm, W.M. Kirsch, Y.H. Zhu, N. Peckham, S. Kihara, R. Anton, et al., Dural closure with nonpenetrating clips prevents meningoneural adhesions: an experimental study in dogs, *Neurosurgery* 45 (1999) 875–81, discussion 881–2.
- [11] D.I. Levy, V.K. Sonntag, Titanium dural clip testing. Technical note, *J. Neurosurg.* 81 (1994) 947–949.
- [12] B.A. Kaufman, A.E. Matthews, M. Zwienerberg-Lee, S.M. Lew, Spinal dural closure with nonpenetrating titanium clips in pediatric neurosurgery, *J. Neurosurg. Pediatr.* 6 (2010) 359–363.
- [13] Z. Fang, R. Tian, Y.T. Jia, T.T. Xu, Y. Liu, Treatment of cerebrospinal fluid leak after spine surgery, *Chin. J. Traumatol.* 20 (2) (2017) 81–83, <https://doi.org/10.1016/j.cjtee.2016.12.002>.
- [14] C. Cobb III, G. Ehni, Herniation of the spinal cord into an iatrogenic meningocele. Case report, *J. Neurosurg.* 39 (1973) 533–536.
- [15] A.A. Jones, J.L. Stambough, R.A. Balderston, et al., Long-term results of lumbar spine surgery complicated by unintended durotomy, *Spine* 14 (1989) 443–446.
- [16] L.V. Perrett, Traumatic meningoceles, *Australas. Radiol.* 7 (1) (1963) 63–67.
- [17] J.P. Lin, S.D. Zhang, F.F. He, M.J. Liu, X.X. Ma, The status of diagnosis and treatment to intracranial hypotension, including SIH, *J. Headache Pain* 18 (1) (2017) 4, <https://doi.org/10.1186/s10194-016-0708-8>.
- [18] F.J. Eismont, S.W. Wiesel, R.H. Rothman, Treatment of dural tears associated with spinal surgery, *J. Bone Joint Surg. Am.* 63A (1981) 1132–1136.
- [19] F.H. Mayfield, K. Kurokawa, Watertight closure of spinal dura mater. Technical note, *J. Neurosurg.* 43 (1975) 639–640.
- [20] P. Black, Cerebrospinal fluid leaks following spinal surgery: use of fat grafts for prevention and repair. Technical note, *J. Neurosurg.* 96 (2 Suppl.) (2002) 250–252 PubMed PMID: 12450290.
- [21] E.E. Dafford, P.A. Anderson, Comparison of dural repair techniques, *Spine J.* 15 (2015) 1099–1105.
- [22] V. Albanese, N. Platania, Spinal intradural extramedullary tumors. Personal experience, *J. Neurosurg. Sci.* 46 (2002) 18–24.
- [23] W. el-Mahdy, P.J. Kane, M.P. Powell, H.A. Crockard, Spinal intradural tumours:

- Part I – Extramedullary, *Br. J. Neurosurg.* 13 (1999) 550–557.
- [24] M.F. Fraioli, M.G. Marciani, G.E. Umana, B. Fraioli, Anterior microsurgical approach to ventral lower cervical spine meningiomas: indications, surgical technique and long term outcome, *Technol. Cancer Res. Treat.* (2014), <https://doi.org/10.7785/tcrt.2012.500418> Online ahead of print. PMID: 24645744.
- [25] R. Fiori, I. Coco, M. Nezzo, G. Kabunda, G.E. Umana, M.F. Fraioli, G. Simonetti, Spinal hydatidosis relapse: a case report, *Case Rep. Orthop.* 2014 (2014) 207643, <https://doi.org/10.1155/2014/207643> Epub 2014 Jul 21. PMID: 25143850 Free PMC article.
- [26] F. Novegno, G. Umana, L. Di Muro, B. Fraioli, M.F. Fraioli, Spinal intramedullary arachnoid cyst: case report and literature review, *Spine J.* 14 (6) (2014) e9–e15, <https://doi.org/10.1016/j.spinee.2013.10.051> Epub 2013 Nov 18. PMID: 24262859 Review.
- [27] N.D. Faulkner, M.A. Finn, P.A. Anderson, Hydrostatic comparison of non-penetrating titanium clips versus conventional suture for repair of spinal durotomies, *Spine (Phila Pa 1976)* (37) (2012) E535–E539.
- [28] J. Timothy, S.J. Hanna, N. Furtado, M. Shanmuganathan, A. Tyagi, The use of titanium non-penetrating clips to close the spinal dura, *Br. J. Neurosurg.* 21 (2007) 268–271.
- [29] P. Ferroli, A. Franzini, G. Messina, G. Tringali, G. Broggi, Use of self-closing U-clips for dural repair in mini-invasive surgery for herniated disc, *Acta Neurochir. (Wien)* 150 (2008) 1103–1105.
- [30] K. Ito, T. Seguchi, T. Nakamura, A. Chiba, T. Hasegawa, A. Nagm, et al., Evaluation of metallic artifacts caused by nonpenetrating titanium clips in postoperative neuroimaging, *World Neurosurg.* 96 (2016) 16–22.
- [31] M.H. Khan, J. Rihn, G. Steele, R. Davis, W.F. Donaldson 3rd, J.D. Kang, et al., Postoperative management protocol for incidental dural tears during degenerative lumbar spine surgery: a review of 3,183 consecutive degenerative lumbar cases, *Spine (Phila Pa 1976)* (31) (2006) 2609–2613.