

Targeted molecular therapies in thyroid carcinoma

Terapias moleculares direcionadas em câncer de tireoide

Serena Romagnoli¹, Sonia Moretti¹, Pasquale Voce¹, Efsio Puxeddu¹

ABSTRACT

Thyroid cancer incidence has significantly increased in the last three decades and many patients seek medical attention for its treatment every year. Among follicular cell-derived tumors, the majority are differentiated thyroid carcinomas (DTC), whose prognosis is very good with only 15% of the cases presenting disease persistence or recurrence after initial treatment. Medullary thyroid carcinoma has a worse prognosis, especially in patients with diffused cancers at the time of initial surgery. Traditional treatment options for persistent or recurrent disease include additional surgery, radioiodine treatment and TSH-suppression in DTC patients; external beam radiotherapy, and cytotoxic chemotherapy, often have low efficacy and many patients with advanced disease ultimately die. In the last two decades many of the molecular events involved in cancer formation have been uncovered. This knowledge has prompted the development of novel therapeutic strategies mainly based on the inhibition of key molecular mediators of the tumorigenic process. In particular the class of small-molecule tyrosine kinase inhibitors was enriched by many compounds that have reached clinical trials and in some cases have had approval for clinical use in specific cancers. Many of these compounds entered clinical trials also for locally advanced or metastatic thyroid carcinomas showing very promising results. *Arq Bras Endocrinol Metab.* 2009;53(9):1061-73

Keywords

Thyroid carcinoma; radioiodine therapy; external beam radiation therapy; cytotoxic chemotherapy; targeted therapies; tyrosine kinase inhibitors

RESUMO

O câncer de tireoide tem aumentado significativamente nas últimas três décadas e muitos pacientes têm buscado cuidados médicos para o tratamento a cada ano. Entre os tumores derivados de células foliculares, a maioria é carcinoma diferenciado de tireoide (CDT), cujo prognóstico é muito bom, em que somente em 15% dos casos a doença é persistente ou recorrente após o tratamento inicial. O carcinoma medular de tireoide tem um prognóstico pior, especialmente em pacientes com câncer difuso no momento da cirurgia inicial. As opções no tratamento tradicional para a doença persistente ou recorrente incluem cirurgia adicional, radioiodoterapia e supressão de TSH em pacientes CDT; a radioterapia externa e a quimioterapia citotóxica apresentam com frequência uma baixa eficácia e muitos pacientes com doença avançada não sobrevivem. Nas últimas duas décadas, muitos dos eventos envolvidos na formação do câncer tornaram-se conhecidos. Esse conhecimento possibilitou o desenvolvimento de novas estratégias terapêuticas, baseadas principalmente na inibição de mediador molecular-chave no processo tumorigênico. Em particular, a classe das pequenas moléculas inibidoras de tirosina-quinase foi enriquecida por muitos compostos investigados em estudos clínicos e alguns casos foram aprovados para uso clínico em tipos específicos de câncer. Muitos desses compostos foram aplicados em estudos clínicos de câncer de tireoide com extensa invasão local ou metástase, mostrando resultados muito promissores. *Arq Bras Endocrinol Metab.* 2009;53(9):1061-73

Descritores

Câncer de tireoide; radioiodoterapia; radioterapia externa; quimioterapia citotóxica; terapias direcionadas; inibidores de tirosina-quinases

¹ Department of Internal Medicine, University of Perugia, Perugia, Italy

Correspondence to:

Efsio Puxeddu
Dipartimento di Medicina Interna
Via E. dal Pozzo SNC
06126 Perugia, Italy
efσιο.puxeddu@unipg.it

Received on Nov/25/2009

Accepted on Dec/4/2009

INTRODUCTION

Thyroid cancer is the most common malignancy of the endocrine system, representing approximately 1% of all malignancies in Western countries (1). Among human cancers, thyroid cancer has the most rapidly increasing incidence rates in women, and the second most rapid in men, with an annual percentage change of approximately 5%, making it the sixth most common cancer in women (2). In the U.S., it is estimated that 37,200 men and women (10,000 men and 27,200 women) will be diagnosed with and 1,630 men and women will die of thyroid cancer in 2009 (3).

The more common forms of thyroid carcinoma are follicular-cell and C-cell-derived neoplasms. The former include papillary (about 80% of thyroid carcinomas), follicular (less than 10%), poorly differentiated (about 5%) and anaplastic (less than 1%) histotypes. The latter include medullary thyroid carcinomas (about 5%).

Treatment strategies for these two types of tumor categories differ significantly.

Differentiated thyroid carcinomas (DTC), which include papillary and follicular tumors, are initially treated by surgery (usually total thyroidectomy; eventually associated, in the case of papillary thyroid carcinoma, to prophylactic central lymph node dissection or compartment-oriented lymph node removal if metastatic lymph nodes are present), and followed by radioiodine treatment in patients at risk for persistent or recurrent disease (4). Subsequent thyroxine treatment allows restoration of euthyroidism or achievement of TSH suppression in high risk patients (4). Both post-surgical treatment options are very efficacious either in the adjuvant or curative setting due to the capacity of differentiated thyroid carcinoma cells to concentrate iodine and to express a functional TSH receptor. Loss of differentiation is associated with the progressive failure of these treatment strategies as happens in poorly differentiated and anaplastic thyroid carcinomas for which surgery is usually insufficient and efficacious post-surgical treatment options are presently not available (5).

Conversely, medullary thyroid carcinoma cells maintain features of the parental C-cells of neuroendocrine origin and from the beginning are unable to retain iodine and do not express the TSH receptor. Thus, the major therapeutic option for this cancer is represented by surgery (usually total thyroidectomy associated to a less or more aggressive neck lymph node dissection) (6).

EPIDEMIOLOGY OF INCURABLE THYROID CANCERS AND TRADITIONAL THERAPEUTIC OPTIONS

More than 85% of patients with DTC present with limited disease and become disease-free after initial treatment (7). However, 10%-15% of patients with this type of thyroid cancer have persistent/recurrent disease. In 75% of cases it is located in the neck, most often in the lymph nodes. In 25% of cases it is represented by distant metastases that can occur in the lungs (50%), bones (25%), lungs and bones (20%) or at other sites (5%).

Therapeutic options for patients with persistent/recurrent follicular cell-derived thyroid cancers include, when feasible, additional surgery, radioiodine treatment in presence of radioiodine uptake in tumor foci, other local treatments (dependent on location and extent of disease) such as external beam radiation therapy, embolization, radiofrequencies, and cement injection (4). Reported 10-year-survival rates after recurrence of neck disease range from 49% to 68%, and neck lesions are responsible for one third of cancer-related deaths (8-10). Ten-year-survival rates in patients with distant metastases are even lower ranging from 25% to 42% (11-13). If surgery is not feasible or not radical, only radioiodine treatment can allow the achievement of a complete remission. Less than one third of patients with distant metastases is cured with radioiodine and usually achieves this result with a cumulative activity lower than 600 mCi (11). Typically, these patients are younger, have well differentiated tumors, high radioiodine uptake, small metastases, location in the lung, stable or slow progressive disease and low uptake of fluorodeoxyglucose on 18-FDG PET scan (7). The remaining patients show initial radioiodine uptake but poor or no response to the treatment or no initial uptake of the halogen at all. Typically, these patients are older, have poorly differentiated tumors, large metastases, location in bones, rapidly progressive disease and high uptake of fluorodeoxyglucose on 18-FDG PET scan (7). Until very recently, the only additional therapeutic option for this category of patients was represented by cytotoxic chemotherapy (7). The real impact of this approach is actually unknown, because only a few studies have addressed the problem and the available ones are plagued by small numbers of patients, aggregation of heterogeneous histologies (differentiated, medullary and anaplastic), confounding interpretations, and variable definitions of responses (14). Doxorubicin alone or

in combination with cisplatin yielded tumor response rates ranging from 0% to 22% (15-17). The responses were always partial, lasted only a few months and were associated with significant toxicity. No studies are available on the use of the most recent cytotoxic agents such as taxanes, gemcitabine or type I topoisomerase inhibitors. Thus, treatment with cytotoxic chemotherapy has generally been limited to patients with symptomatic or rapidly progressive metastatic disease unresponsive to or unsuitable for surgery, radioiodine, and external beam radiotherapy.

In medullary thyroid carcinoma, a biochemical cure is obtained in 75%-90% of patients without lymph node involvement, but even with aggressive surgery, in only 20%-30% of patients with lymph node metastases, and rarely (4%) in patients with more than 10 lymph node metastases (18). This clearly demonstrates how treatment at an early stage is a highly significant prognostic factor in medullary thyroid carcinoma patients.

Therapeutic options for patients with persistent/recurrent medullary thyroid carcinoma include when feasible additional surgery and other local treatments, as seen for follicular cell-derived cancers, such as external beam radiation therapy, embolization, radiofrequencies and cement injection (6). Conversely, treatment with radioactive iodine is pointless, because C-cells do not take up the halogen. Radioactive iodine covalently linked to specific compounds such as MIBG and DTPA or Yttrium 90 covalently linked to somatostatin analogues appeared poorly effective in patients with large metastases (6). Doxorubicin alone or in combination with cisplatin yielded tumor responses in less than 20% of patients (19). In this case the responses were also always partial, lasted only a few months and were associated with significant toxicity. Various combinations of 5-fluorouracil (5-FU), dacarbazine, streptozotocin, cyclophosphamide and vincristine have produced similar response rates (about 20%) with symptomatic improvement in some patients, but no benefit was found on survival rate (20). Thus, also in the case of medullary thyroid carcinoma the use of cytotoxic chemotherapy has been limited to the few patients with rapidly progressive metastatic disease. Conversely, in more typical patients with stable or slowly progressive disease, the regimens currently available appear to offer little benefit, if any.

During the last decade, by taking advantage of the knowledge of cancer pathogenesis, new therapies have been developed in the field of oncology to interfere

with the activity of specific oncoproteins believed to be important in disease causation. The first notable success was with Imatinib (Gleevec) in Philadelphia chromosome/BCR-ABL (+) chronic myelogenous leukemia (21), but several other compounds have reached clinical application. Many of the events that initiate thyroid cancer have already been investigated as potential targets for treatment, making molecular targeted therapies an attractive new approach for the treatment of advanced follicular cell-derived or medullary thyroid carcinomas.

MOLECULAR AND BIOLOGICAL BASES OF THYROID CARCINOMA PATHOGENESIS

Activating genetic alterations in mediators of signal transduction pathways occurs commonly in thyroid cancers and typically involves tyrosine kinase receptors, such as RET and neurotrophic tyrosine receptor kinase (NTRK), G-proteins, such as RAS, signaling kinases, such as BRAF and PI3K and nuclear transcription factors, such as protein box 8 (PAX8), peroxisome proliferator-activated receptor γ (PPAR γ) and p53. All these mutations appear to sustain tumor development and/or progression (22) (Figure 1).

The RET proto-oncogene encodes a membrane receptor of the family of the tyrosine kinase receptors that is normally not expressed in thyroid follicular cells. Conversely, in papillary thyroid carcinoma, RET appears activated (23-24). This activation occurs through chromosomal recombination resulting in illegitimate expression of a fusion protein consisting of the intracellular tyrosine kinase (TK) domain of RET coupled to the N-terminal fragment of a heterologous gene. Several forms have been identified so far that differ according to the 5' partner gene involved in the rearrangement. The more common are RET/PTC1 (RET kinase fused with the H4 gene product) and RET/PTC3 (RET kinase fused with the RFG gene product). In sporadic papillary thyroid carcinomas from adults the prevalence of RET/PTC rearrangements ranges from 5 to 40%, but it is more common in children and after radiation exposure during childhood (up to 80%).

NTRK1 is another rearrangement, involving the neurotrophic tyrosine receptor kinase, which occurs less commonly in papillary thyroid carcinomas (5-13%) (25).

RAF is a serine/threonine-selective protein kinase involved in the mitogen-activated protein kinase (MAPK) pathway. Of the three functional RAF isoforms

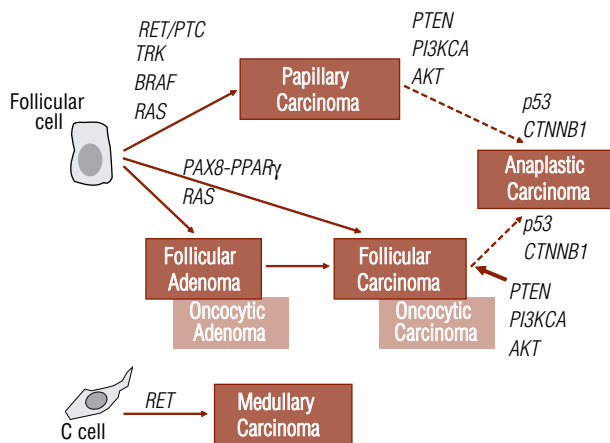


Figure 1. Classification of thyroid carcinoma histotypes and genetic events involved in their development. RET/PTC and TRK rearrangements and BRAF and RAS activating mutations are involved in initiation and progression of papillary thyroid carcinoma. PAX8-PPAR γ rearrangements and RAS activating mutations are involved either in follicular adenoma or follicular carcinoma formation. Loss of differentiation of papillary thyroid carcinomas and follicular thyroid carcinomas involves activation of mediators of the PI3K-AKT pathway. Transition to completely dedifferentiated or anaplastic carcinomas depends on p53 and β -catenin mutation or dysregulation. Conversely, activating mutations of the proto-oncogene RET are involved in the formation of all familial medullary thyroid carcinomas and of a part of the sporadic counterpart.

ms described in humans, the most potent MAPK pathway activator is BRAF. The importance of BRAF mutation in thyroid cancer was revealed by several studies which showed the frequent occurrence of this genetic alteration in PTC, with a prevalence ranging from 29% to 83% (mean 44%) (26). A unique somatic T1799A transversion in exon 15, resulting in a V600E (valine to glutamate) amino acid substitution (BRAF^{V600E}), has been detected in virtually every case analyzed so far, with few exceptions (27). The presence of a BRAF mutation has been associated with a slightly poorer prognosis in patients with papillary thyroid carcinoma (28-29).

The four classical RAS proto-oncogenes encoding H-RAS, K-RAS A, K-RAS B and N-RAS belong to an extended family of small G-proteins. RAS proteins are plasma membrane GTPases activated by growth factor receptors, non-receptor tyrosine kinases, and to a lesser extent by G-protein-coupled receptors, leading to activation of downstream effector pathways. Mutations of RAS isoforms are found in thyroid carcinomas but also in benign follicular adenomas and some hyperplastic nodules (30). In detail, RAS mutations are found in 0-21% papillary thyroid carcinomas and 20%-50% follicular thyroid carcinomas with the following relative frequencies: N-RAS > H-RAS > K-RAS. The presence of RAS mutations in both follicular adenomas and car-

cinomas suggests that RAS activation is an early step in thyroid carcinogenesis, although this has not been conclusively proven.

The PAX8-PPAR γ fusion protein (PPFP) results from a balanced translocation of the paired box gene 8 (PAX8) and peroxisome proliferator-activated receptor γ (PPAR γ) genes (31). PPAR γ plays a role in adipogenesis and insulin sensitization, cell-cycle control, inflammation, atherosclerosis, apoptosis and carcinogenesis through its influence on gene expression involving multiple cell signaling pathways. PPFP may be an early event in the development or progression of follicular thyroid cancer and perhaps the follicular variant of papillary thyroid carcinoma. Together, RAS and PAX8-PPAR γ mutations are identified in approximately 80% of follicular carcinomas (32). However, as mentioned above, PAX8-PPAR γ like RAS, is also detected in a sub-group of follicular adenomas. This finding supports once again the existence of a stepwise adenoma to carcinoma transition, or indicates the existence of not recognized in situ carcinomas.

Interestingly, mutations of RET, RAS and BRAF result in the activation of the same signaling pathway, namely the MAPK pathway. The observation that mutations of these genes are mutually exclusive of one another and that each mutation seems to be capable - on its own - of triggering follicular cell transformation, underscores the importance of MAPK signaling in thyroid tumorigenesis (33). In addition, activation of RET and RAS also results in the activation of the phosphatidylinositol 3-kinase and the ral guanine nucleotide exchange factor pathways which might also contribute to follicular cell transformation.

Mutations of mediators and regulators of the phosphatidylinositol 3-kinase pathway, including PI3KCA, AKT and PTEN, have rarely been described, mainly in advanced and dedifferentiated follicular cell-derived carcinomas (34-35). These mutations thus appear to arise during cancer progression.

Finally, mutations of the p53 tumor suppressor gene are also a common feature of poorly differentiated or undifferentiated thyroid cancers, and could be responsible, together with β -catenin dysregulation/CTNNB1 exon 3 mutations for the loss of differentiation during progression (36-37).

While the RET proto-oncogene is normally not expressed in thyroid follicular cells, it is expressed in thyroid parafollicular or C-cells and activating point mutations of RET, either germline or somatic, are in-

involved in medullary thyroid carcinoma development (38-39). About 25% of these cancers are hereditary while the remaining are sporadic. Familial forms develop in the context of Multiple Endocrine Neoplasia type 2 (MEN 2) syndrome, an autosomal dominant disease, in which medullary thyroid carcinoma can be the sole manifestation or be associated with other tumors, including pheochromocytoma, parathyroid hyperplasia/neoplasia and neuromas and body dimorphisms. In detail, MEN 2A is the association of medullary thyroid carcinoma (nearly 100% penetrance), pheochromocytoma (35%-50% penetrance), and parathyroid hyperplasia/neoplasia (5%-25% penetrance). MEN 2B is the association of medullary thyroid carcinoma (100% penetrance) and pheochromocytoma (35%-50% penetrance) with neuromas in the oral mucosa and throughout the gastrointestinal tract (90% penetrance). In addition, affected individuals have thickened nerves, and features of Marfan's syndrome. Finally, familial medullary thyroid carcinoma (FMTC) consists of pedigrees in which medullary thyroid carcinoma is transmitted as an autosomal dominant trait without other manifestations of MEN 2. Germline mutations of the proto-oncogene RET confer predisposition to all forms of familial medullary thyroid carcinoma. At present, more than 50 different mutations of RET have been detected in the MEN 2 families analyzed so far. The mutations fall into two main groups: (a) Those affecting the extracellular domain: These particularly involve cysteine residues 609, 611, 618 and 620 (exon 10), and 634 (exon 11). (b) Those affecting the RET TK domain: These involve primarily codons 768, 790 and 791 (exon 13), 804 (exon 14), 883 and 891 (exon 15) and 918 (exon 16). Mutations of codons 883 and 918 are strictly associated with the more aggressive MEN 2B phenotype. All the others have been revealed either in MEN 2A or in milder FMTC cases, although mutation of codon 634, and particularly that resulting in a Cysteine to Arginine substitution, predicts with high probability the complete MEN 2A phenotype. Screening of RET germline mutations is now practiced on a routine basis in medullary thyroid carcinoma patients because it allows one to discriminate the familial forms (sometimes clinically silent due to a low penetrance of the thyroid cancer) from the sporadic ones. Finding of a RET mutation allows screening first degree relatives of the proband for MEN 2 and to perform prophylactic thyroidectomy in the carriers. Moreover, knowledge of the involved mutation

allows prediction probability to develop other features of the disease and the potential aggressivity of the medullary thyroid carcinoma. Finally, some prediction on responsiveness to novel targeted therapies might also be formulated, knowing that codon 804 mutants are resistant to treatment with the tyrosine kinase inhibitor vandetanib (40).

At variance, sporadic MTCs have no detectable germline abnormalities in RET. However, a significant proportion of these cancers have acquired a mutation in RET as a somatic event during the course of tumor initiation or progression (41-42). Here, the mutation is present only in the tumor, and most often involves codon 918 (Met918Thr), although other RET mutations have also been reported, such as some at codons 634 and 883. Estimates of prevalence of somatic RET mutations in sporadic MTC range from 23% to 70%. There are indications that tumors with RET mutations may carry a worse prognosis.

Other molecular abnormalities have also been seen in thyroid tumors, and are believed to be secondary events (7). Overexpression of tyrosine kinase receptors has been noted in thyroid cancer cells, including those for fibroblast growth factor, epidermal growth factor (EGF), hepatocyte growth factor (C-Met), vascular endothelial growth factor (VEGF), insulin, and insulin-growth factor 1. The ligands for these receptors are also often overexpressed. In particular, overexpression of pro-angiogenic factors drives angiogenesis which plays a critical role in tumor cell growth and metastasis, supplying nutrients and oxygen, removing waste products, and facilitating cell diffusion. Of the identified pro-angiogenic factors, vascular endothelial growth factor (VEGF) is key, binding to two receptor tyrosine kinases, VEGF receptor (VEGFR)-1 (fms-like tyrosine kinase-1) and VEGFR-2 (fetal liver kinase-1/kinase insert domain-containing receptor) that also trigger MAPK signaling (43).

Loss of differentiation of the tumors is also frequently detected and can include the loss of radioiodine uptake in follicular cell-derived cancers (7). This loss is related to the low or absent expression of the sodium iodide symporter (NIS) protein. Loss of expression of thyroid functional genes is generally the consequence of gene promoter hypermethylation and/or chromatin remodeling due to modification of histone acetylation or methylation status. In addition, these epigenetic events are generally secondary to the expression of activated oncoproteins, such as mutated BRAF (28).

NOVEL TARGETED THERAPIES FOR ADVANCED THYROID CARCINOMAS

Development of specific inhibitors of the etiologic oncogenes involved in cancer formation finds its rationale in a specific hypothesis: the oncogene addiction hypothesis (44). According to it, a genetic alteration that drives cell transformation is believed to become the cornerstone of the abnormal signaling events involved in the stepwise transition from normal cell to cancer cell. Thus, it is expected that inhibition of that etiologic oncogene leads to either tumor stabilization or regression. Therefore, interest arose in the therapeutic potential of kinase inhibitors for cancer and in particular also for thyroid cancer.

Another strategy to block tumor growth contemplates cutting blood flow through the inhibition of angiogenesis (43). The result is a reduced delivery of oxygen and nutrients to the tumor cells and a reduced removal of waste and CO₂, which ultimately compromises cell proliferation or even vitality.

Two categories of tyrosine kinase inhibitors have been developed: 1) small molecules that fit in the catalytic pocket of tyrosine kinases and block ATP access; 2) humanized antibodies that bind to specific membrane tyrosine kinase receptors and impair their functions. Other targeted therapies foresee the use of other humanized antibodies against key growth factor such as Epidermal Growth Factor or Vascular Endothelial Growth Factor.

Because the catalytic domains of tyrosine kinases are very similar, the small-molecule inhibitors are often characterized by lack of specificity that however in some contexts, such as thyroid carcinoma, might be advantageous. Indeed, the capacity of kinase inhibitors to block not only specific oncogenes, but also other receptors or signaling mediators involved in cancer progression potentiate their anti-tumoral action. In particular, inhibition of VEGFRs, Platelet-Derived Growth Factor Receptor (PDGFR) and possibly other pro-angiogenic receptors, by blocking tumor angiogenesis, significantly contribute to the impairment of cancer growth. However, the low specificity of many of these molecules is also responsible for their side effects that sometimes can be severe.

The principal tyrosine kinase inhibitors (TKI) that have reached human experimentation in clinical trials for thyroid carcinoma all belong to the family of small-molecule TKIs and include Axitinib, Motesanib, Sorafenib, Sunitinib, Vandetanib and XL184 (14).

In the following paragraphs, we will summarize the most recent acquisitions coming from the clinical trials performed in advanced thyroid carcinoma with these drugs (Table 1).

Axitinib

Axitinib is an oral TKI that effectively blocks VEGFRs at subnanomolar concentrations (VEGFR1 IC₅₀ of 1.2 nM; VEGFR2 IC₅₀ of 0.25 nM; VEGFR3 IC₅₀ of 0.29 nM) (45). Moreover, it appears to inhibit c-KIT (IC₅₀ of 1.7 nM) and PDGFRβ (IC₅₀ of 2.5 nM). A multicenter, open-label, phase II study examined the efficacy of axitinib in advanced or metastatic thyroid carcinoma (46), starting at a dose of 5 mg twice daily. Sixty patients with advanced thyroid carcinoma of all histological sub-types (50% papillary thyroid carcinoma, 25% follicular thyroid carcinoma, including Huerthle cell variants, 18% medullary thyroid carcinoma) were enrolled. Among the 45 evaluable patients, according to RECIST¹ criteria, 18 (30%) experienced a partial response (31% DTC, 18% medullary thyroid carcinoma, one of two anaplastic thyroid carcinomas) and 23 (38%) presented stable disease lasting ≥ 16 weeks, yielding an objective response rate of 30% and a disease control rate of 68%. Median progression-free survival was 18.1 months. Axitinib was generally well tolerated, with the most common Grade ≥ 3 treatment-related adverse event being hypertension (n = 7; 12%). Analysis of soluble VEGF in serum showed increased levels of the biomarker, indicating effective angiogenesis inhibition.

Another multicenter, open-label, phase II study, evaluating the safety and efficacy of Axitinib in patients with ¹³¹I-refractory metastatic or unresectable locally-advanced thyroid cancer, is currently recruiting patients (for more information please check the National Institute of Health <http://clinicaltrials.gov> site).

Motesanib

Motesanib diphosphate is an oral TKI that effectively blocks VEGFRs at nanomolar concentrations (VEGFR1 IC₅₀ of 2 nM; VEGFR2 IC₅₀ of 3 nM; VEGFR3 IC₅₀ of 6 nM) (48). Moreover, it appears to inhibit c-KIT (IC₅₀ of 8 nM), PDGFRβ (IC₅₀ of 84 nM) and RET (IC₅₀ of 59 nM) either wild type or mutated. A multicenter, open-label, single group, phase II study examined the efficacy of motesanib in progressive, lo-

¹ RECIST: Response Evaluation Criteria in Solid Tumors. [For detailed description see (47)]

Table 1. Results summary of the more important clinical trials conducted in advanced thyroid carcinoma

Drug	Type of study	Cancer histologies	# enrolled patients	Objective responses (%)	Disease control rate (%)	Progression free survival (months)
Axitinib	Phase II (46)	PTC, FTC, MTC, ATC	60	30	68	18.1
Motesanib	Phase II (49)	DTC	93	14	81	9.3
	Phase II (50)	MTC	91	2	83	11.2
Sorafenib	Phase II (52)	PTC, FTC, MTC, ATC	30	23	76	18.4
	Phase II (53)	PTC	41	15	71	15
		FTC	11	0	54	/
	Phase II (54)	PTC, FTC	48	25	59	13.5
Sunitinib	Phase II (58)	DTC	31	13	81	/
		MTC	6	0	81	/
Vandetanib	Phase II (300) (63)	Familial MTC	30	20	50	/
	Phase II (100) (64)	Familial MTC	19	10.5	41.1	/
XL184	Phase I (66)	MTC	Extension cohort of 23	55	84	/

PTC: papillary thyroid carcinoma; FTC: follicular thyroid carcinoma; DTC: differentiated thyroid carcinoma; MTC: medullary thyroid carcinoma; ATC: anaplastic thyroid carcinoma. (300) and (100) indicate the dosage of Vandetanib in mg used in the trials.

cally advanced or metastatic, radioiodine-resistant differentiated thyroid cancer (49), using a dose of 125 mg administered orally once daily. Ninety-three patients were enrolled, 57 (61%) of whom had papillary thyroid carcinoma and 32 (34%) follicular thyroid carcinoma, including Hürthle cell variant. Thirteen patients (14%) presented a partial response according to RECIST criteria assessed by an independent radiographic review. Stable disease was achieved in 62 patients (67%), and stable disease was maintained for 24 weeks or longer in 33 (35%); 7 patients (8%) had progressive disease as the best response. The median estimate of progression-free survival was 40 weeks. In summary, the study yielded an objective response rate of 14% and a disease control rate of 81%. The most common treatment-related adverse events were diarrhea (in 59% of the patients), hypertension (56%), fatigue (46%), and weight loss (40%). Among the 75 patients in whom thyroglobulin analysis was performed, 61 (81%) had decreased serum thyroglobulin concentrations during treatment, as compared with baseline levels. Interestingly, a correlation was observed between a decrease from baseline of 50% or more in thyroglobulin concentration and a decrease from baseline of 30% or more in the sum of the longest diameter of target tumor lesions. Noteworthy, although the drug does not inhibit BRAF, tumors harboring the BRAF mutation were less likely to progress. An explanation for this phenomenon is that BRAF^{V600E} expressing cancers might be more dependent on VEGF-mediated angiogenesis.

Motesanib was also employed in a multicenter phase II study aimed at investigating its efficacy and tolerability in advanced medullary thyroid cancer patients (50), using a dose of 125 mg administered orally once daily. Ninety-one patients with locally advanced or metastatic, progressive or symptomatic medullary thyroid carcinomas were enrolled. Only two patients (2%) experienced a confirmed partial response, whose duration lasted 32 and 21 weeks, respectively. Stable disease was achieved in 74 patients (81%), and stable disease was maintained for 24 weeks or longer in 44 (48%); 7 patients (8%) had progressive disease as the best response. The median progression-free survival was 48 weeks. In summary, the study yielded an objective response rate of 2% and a disease control rate of 83%. Unexpectedly, in pharmacokinetic analyses the maximum and trough plasma concentrations of the drug in medullary thyroid carcinoma patients were lower than reported with other solid tumor patients, including differentiated thyroid cancer patients and these differing pharmacokinetic analyses may have contributed to the lower response rate. Among patients with tumor marker analysis, 69 (83%) of 83 and 63 (75%) of 84 had decreased serum calcitonin and carcinoembryonic antigen during treatment, respectively, when compared with baseline.

In both studies, an unanticipated side effect of motesanib therapy was a 30% increase in the mean dosages of L-thyroxine required to maintain TSH suppression or euthyroidism, respectively, in DTC and medullary thyroid carcinoma cohorts, and 60-70% of patients ex-

perienced peak TSH concentration out of the therapeutic ranges.

Sorafenib

Sorafenib is an oral TKI that effectively blocks VEGFR2 (IC₅₀ of 90 nM), VEGFR3 (IC₅₀ of 20 nM), RET (IC₅₀ of 47 nM), RET/PTCs (for RET/PTC3 IC₅₀ of 50 nM), the serine-threonine kinase BRAF (IC₅₀ of 22 nM), PDRGRβ (IC₅₀ of 47 nM) and c-KIT (IC₅₀ of 68 nM) (51). Sorafenib is approved by the Food and Drug Administration and other medicine controlling agencies throughout the world as treatment for advanced renal cell carcinoma and unresectable hepatocellular carcinoma. Three open-label, phase II studies have been conducted to determine the efficacy of sorafenib in advanced thyroid carcinomas of follicular origin.

In the first study (52), thirty patients with metastatic, iodine-refractory thyroid carcinoma of all histological sub-types (60% papillary thyroid carcinoma, 30% follicular thyroid carcinoma, including Huerthle cell variants, 3% medullary thyroid carcinoma and 7% poorly differentiated/anaplastic thyroid carcinoma) were enrolled. Patients received sorafenib 400 mg twice daily for a minimum of 16 weeks and responses were evaluated radiographically every 2-3 months according to RECIST criteria. Seven patients (23%) had a partial response lasting 18+ to 84 weeks while 16 patients (53%) had stable disease lasting 14 to 89+ weeks, yielding an objective response rate of 23% and a disease control rate of 76%. The median progression-free survival was 79 weeks. The most common or significant toxicities included hand-foot syndrome, rash, fatigue, diarrhea, and hypertension, although a single patient died of liver failure that was likely to be treatment related. Seventeen (95%) of 19 patients for whom serial thyroglobulin levels were available showed a marked and rapid response in thyroglobulin levels with a mean decrease of 70%.

A second phase II study (53) used a Simon minimax two-stage design characterized by the enrollment of 16 or 25 chemotherapy-naïve metastatic PTC patients in an arm A (accessible tumor for biopsy) and the remaining patients with other subtypes of thyroid carcinoma or prior chemotherapy in an arm B (tumor biopsy not required). Patients received 400 mg orally twice per day of sorafenib. Response was assessed every 2 months using RECIST criteria. Of 41 papillary thyroid carcinoma patients, 6 patients had a partial response (15%) and 23 patients (56%) had stable disease longer than 6 months (objective response rate of 15% and a disease

control rate of 71%). Median duration of partial responses was 7.5 months while median progression-free survival was 15 months. In 14 (78%) of 18 Tg-assessable papillary thyroid carcinoma patients, Tg declined more than 25%. BRAF mutation was detected in 17 (77%) of 22 papillary thyroid carcinomas analyzed. Four of 10 paired tumor biopsies from papillary thyroid carcinomas patients showed a reduction in levels of vascular endothelial growth factor receptor phosphorylation, ERK phosphorylation, and in VEGF expression during sorafenib therapy. No partial responses were noted among non-papillary thyroid carcinomas patients, although 6 patients out of 11 (54%) with follicular thyroid carcinoma, including Huerthle cell variants, and 1 patient out of 4 (25%) with anaplastic thyroid carcinoma had stable disease longer than 6 months (in follicular thyroid carcinoma objective response rate of 0% and a disease control rate of 54%).

The last phase II study (54) was a 26-week prospective study with an open ended extension exploring the effects of sorafenib on the re-induction of radioiodine uptake and tumor progression in progressive metastatic or locally advanced radioiodine refractory DTC. Thirteen patients with papillary thyroid carcinoma, 3 patients with the follicular variant of papillary thyroid carcinoma and 15 patients with follicular thyroid carcinoma were enrolled and treated with 400 mg orally twice per day of sorafenib. At 26 weeks of sorafenib therapy, no reinduction of radioiodine uptake at metastatic sites was observed, but 8 patients had partial response (25%) and 11 stable disease (34%), yielding an objective response rate of 25% and a disease control rate of 59%. Seven patients had progressive disease (22%). Sorafenib was significantly less effective in patients with bone metastases. The estimated median progression-free survival was 58 weeks. In general, when present, a drop in thyroglobulin was observed after a median period of time of 3 months and reflected radiological responses.

A few other phase II trials exploring the efficacy of sorafenib in advanced thyroid carcinoma are still ongoing (for more information please check the National Institute of Health <http://clinicaltrials.gov> site). However, more importantly, a double-blind, randomized phase III study evaluating the efficacy and safety of sorafenib compared to placebo in locally advanced/metastatic radioiodine-refractory differentiated thyroid cancer, sponsored by Bayer HealthCare and Onyx Pharmaceutical has just started enrollment. The results obtained from this study should allow registration of

sorafenib for advanced differentiated thyroid carcinoma treatment.

The anti-RET activity of sorafenib (51) makes medullary thyroid carcinoma another potential target for this drug. One complete response and one partial response were described in 2 patients with symptomatic metastatic medullary thyroid carcinoma out of 5 treated with sorafenib in a small pilot study (55). All 5 patients also experienced a reduction of serum calcitonin associated with symptomatic improvement. In a recent phase I study (56) evaluating the safety, maximum tolerated dose, pharmacokinetics, and biological effects of the combination of sorafenib with the farnesyltransferase inhibitor tipifarnib, six of eight patients with medullary thyroid cancer had durable stable disease ($n = 3$) or partial remissions ($n = 3$), lasting 12 to 26+ months.

A larger open-label, phase II study evaluating the efficacy of sorafenib in treating patients with metastatic, locally advanced or recurrent medullary thyroid cancer was recently started (for more information please check the National Institute of Health <http://clinicaltrials.gov> site).

The encouraging results coming from the clinical trials described above have prompted many physicians to prescribe sorafenib off-label in selected advanced thyroid carcinoma patients who cannot participate or do not apply to ongoing clinical trials. In these cases it is very important not only to focus on the possible benefits of the treatment, but also on the side effects and toxicities that are very common but can also be very severe, including development of keratoacanthomas and other malignant cutaneous squamous cell lesions (14).

Sunitinib

Sunitinib is an oral TKI that effectively blocks VEGFR1 (IC_{50} of 2 nM), VEGFR2 (IC_{50} of 9 nM), VEGFR3 (IC_{50} of 17 nM), RET (IC_{50} of 41 nM), RET/PTCs (for RET/PTC3 IC_{50} of 224 nM) and PDRGR β (IC_{50} of 2nM) (57). Sunitinib, like sorafenib, is approved by the Food and Drug Administration and other medicine controlling agencies throughout the world as treatment for advanced renal cell carcinoma.

In an initial open-label, phase II study (58), 43 patients with metastatic, iodine-refractory thyroid carcinoma of all histological sub-types (37 DTCs and 6 medullary thyroid carcinomas) were enrolled. Patients received 6-week cycles of sunitinib malate 50 mg once daily on a 4-week on/2-week off schedule and responses were evaluated radiographically according to

RECIST criteria and biochemically. Best response in 31 evaluable DTC patients who completed 2 cycles was partial response in 13%, stable disease in 68%, progressive disease in 10% and not evaluable in 9%, yielding an objective response rate of 13% and a disease control rate of 81%. Best response in MTC patients was stable disease in 83% and progressive disease in 17%, yielding an objective response rate of 0% and a disease control rate of 81%. The most common drug-related adverse events included fatigue (79%), diarrhea (56%), palmar-plantar erythrodysesthesia (53%), neutropenia (49%), and hypertension (42%). Grade 3-4 toxicity included neutropenia (26%), thrombocytopenia (16%), hypertension (16%), fatigue (14%), palmar-plantar erythrodysesthesia (14%), and gastrointestinal tract events (14%, 2 diarrhea, 1 tracheo-esophageal fistula, 1 gastric hemorrhage, 1 gastric ulcer, and 1 gastritis).

Preliminary analysis from a second open-label, phase II trial reported partial responses or stable disease for greater than 12 weeks in 2 of 12 DTC and 3 of 8 medullary thyroid carcinoma patients (59).

Interestingly, different phase II studies are ongoing (for more information please check the National Institute of Health <http://clinicaltrials.gov> site). One of these studies appears very innovative. In detail, it is a two-stage, phase II with historical controls, single center, targeted therapy trial, enrolling patients with stage 2 (for patients younger than 45 years of age), 3 or 4 differentiated thyroid cancer, with evidence of persistent disease. It will explore if sunitinib treatment combined to therapy with radioactive iodine will target cancer cells and delay disease progression better than standard therapy alone in advanced disease. The primary objective is indeed to assess progression-free survival in this population in comparison to historical controls. Sunitinib will be given orally at 37.5 mg daily for one year, or 13 cycles according to the 4-week on/2-week off schedule, following a course of ^{131}I therapy.

Like sorafenib, sunitinib is available for off-label use in selected advanced thyroid carcinoma patients who cannot participate or do not apply to ongoing clinical trials.

In kidney cancer patients, Sunitinib has been shown to frequently induce hypothyroidism with mechanisms that still need to be clarified (60). A few cases of drug-induced thyrotoxicosis have also been described. In thyroid cancer patients who are already treated with L-thyroxine attention should be given to administering increased dosages of thyroid hormone when necessary in order to avoid spikes of TSH or development of frank hypothyroidism.

Vandetanib

Vandetanib is an oral TKI that effectively blocks VEGFR2 (IC₅₀ of 40 nM), VEGFR3 (IC₅₀ of 110 nM), RET (IC₅₀ of 130 nM), RET/PTCs (for RET/PTC3 IC₅₀ of 100 nM) and EGFR (IC₅₀ of 500 nM) (61-62).

A number of phase II studies with vandetanib in medullary thyroid carcinoma patients have been performed. In detail, two phase II intervention studies (administering vandetanib 300 and 100 mg per day, respectively) in patients with locally advanced or metastatic familial medullary thyroid carcinoma were have been concluded. An international, phase II, randomized, double-blinded, placebo-controlled, multicenter study to assess the efficacy of vandetanib versus placebo in subjects with unresectable, locally advanced or metastatic medullary thyroid carcinoma, has concluded recruitment (328 enrollments) and is ongoing. Finally, a phase I/II trial of vandetanib in children and adolescents with hereditary MTC is still recruiting patients at the National Institute of Health (for more information on the latter 2 studies please check the National Institute of Health <http://clinicaltrials.gov> site).

Preliminary data are available for the first two studies. The open-label, phase II intervention study with 300 mg per day of vandetanib (63) as monotherapy recruited 30 patients with locally advanced or metastatic familial forms of MTC. Preliminary results indicate that 20% (6/30) of patients experienced a partial response (duration of response 59-260 days) and another 30% (9/30) of patients experienced stable disease (≥ 24 weeks), yielding an objective response rate of 20% and a disease control rate of 50%. In 19 patients, plasma calcitonin levels showed a greater than 50% decrease from baseline that was maintained for at least 6 weeks. Adverse events occurring in more than 50% of patients were rash (73%), diarrhea (67%), fatigue (57%) and nausea (53%). Most adverse events were Grade 1 or 2; Grade 3 adverse events included asymptomatic QTc prolongation (5 patients), rash and diarrhea (both 3 patients), all of which were manageable.

The second phase II, open-label, intervention study with 100 mg per day of vandetanib (64) as monotherapy recruited 19 patients with locally advanced or metastatic familial forms of medullary thyroid carcinoma. Preliminary objective tumor assessments demonstrate partial responses in 2/19 patients, stable disease ≥ 24 weeks in 6/19 patients and progressive disease in 2 patients, yielding an objective response rate of 10.5% and a disease control rate of 41.1%.

A randomized, double blind, placebo-controlled phase II, multicenter study to assess the efficacy and safety of vandetanib in patients with locally advanced or metastatic papillary or follicular thyroid carcinoma failing or unsuitable for radioiodine therapy is also ongoing (for more information please check the National Institute of Health <http://clinicaltrials.gov> site).

Finally, a targeted phase I/II trial of vandetanib plus the proteasome inhibitor, bortezomib, in adults with solid tumors with a focus on hereditary or sporadic, locally advanced or metastatic medullary thyroid carcinoma is actively recruiting patients (for more information please check the National Institute of Health <http://clinicaltrials.gov> site).

XL184

XL184 is an oral TKI that effectively blocks VEGFR2 (IC₅₀ of 0.35 nM), RET (IC₅₀ of 4 nM) and C-MET (IC₅₀ of 1.8 nM) (65). A phase I, dose-finding study (66) which enrolled patients with various cancers, including an expansion cohort of 23 medullary thyroid carcinoma, showed some degree of tumor shrinkage in almost all patients of the latter group with 55% (12/22 patients with ≥ 3 months of follow-up) qualifying for partial responders according to RECIST criteria. All together 84% of medullary thyroid carcinoma patients presented partial response or stable disease lasting more than 3 months. The majority of the adverse events were of Grade 1 or 2 in severity with only a few Grade 3 events. The most common adverse events included diarrhea, nausea, anorexia, fatigue, mucositis, hypertension, hand-foot syndrome, elevation of AST, ALT and lipase. The protocol defined a maximum tolerated dose of 175 mg per day.

The brilliant results obtained with XL184 in medullary thyroid cancer patients in the phase I study prompted the development of a registration phase III, randomized, double-blind, placebo-controlled trial to determine the efficacy of the drug against placebo in patients with unresectable, locally advanced or metastatic medullary thyroid carcinoma. This trial is currently recruiting patients (for more information please check the National Institute of Health <http://clinicaltrials.gov> site).

The property of XL184 to also inhibit C-MET has been postulated to be relevant for its superior efficacy. Indeed, whereas pure angiogenesis inhibitors, blocking blood flow to the tumor, trigger hypoxia of cancer cells with activation of secondary mechanisms to overcome the blockade, such as up-regulation of the Hepatocyte

Growth Factor-C-MET axis, XL184 simultaneously prevents the primary (primarily VEGFR-mediated) and compensatory (C-MET-mediated) mechanisms involved in cancer angiogenesis (67).

DIFFERENTIATING THERAPIES

Another strategy to overcome thyroid cancer growth and progression contemplates the re-induction of cancer cell differentiation and in particular the restoration of NIS expression and radioiodine up-take in order to ultimately sensitize the tumor cells to treatment with ¹³¹I (7). Attempts to achieve this goal in small cohorts of patients with bexarotene (68), a synthetic analogue of the retinoid X receptor, desipeptide (69), a histone deacetylase inhibitor, and rosiglitazone (70), a peroxisomal proliferator-activated receptor γ agonist, have failed so far and were burdened by significant adverse events. Thus, the differentiating strategy does not appear to represent a major path at least alone in the direction of thyroid cancer cure.

CONCLUSIONS AND PERSPECTIVES

In summary, advanced thyroid carcinoma treatment continues to represent a significant challenge for the different professional figures involved in its cure, including the endocrine oncologist, the endocrine surgeon, the nuclear medicine specialist and the radiotherapist. Ultimately, most of patients with locally advanced disease that is not surgically resectable or with metastatic disease, not responsive to radioiodine or to other therapeutic options, will die. This scenario has probably just started to change with the introduction of targeted therapies and in particular of TKIs. Indeed, with these novel drugs, we have started to experience tumor shrinkage or disease stabilization lasting for a significant amount of time even in clearly progressive cancers. With the exception of a few anecdotal cases, no other treatment, other than radioiodine when effective, has given such good results in advanced thyroid carcinoma in the past. Interestingly, the disease control rate (partial responses + disease stabilizations) obtained with the novel TKIs appears to be very high, in the order of 50%-80%, although limited in time. Moreover, it should also be noticed that complete remissions are not obtainable with any of the available drugs.

At the present time, physicians dealing with these patients should follow a few general recommendations:

1. When possible enroll the patients in clinical trials (as recommended by the ATA Guidelines (4)) which allow a safer use of the new drugs and a more controlled collection of the clinical data.

2. When using other TKIs, such as sorafenib and sunitinib off-label, start with the lower effective dose (for sorafenib 400 mg per day; for sunitinib 25 mg per day) that can be slowly increased to obtain a more satisfactory response.

3. Convince the patients that a long lasting stabilization of the disease is more convenient than a tumor shrinkage of short duration.

4. Not forget that these treatments are burdened by many and sometimes significant side effects and that they are very expensive.

Several questions remain open:

1. In which measure will the results obtained with TKIs impact on overall survival of the patients?

2. What will be the strategy to obtain complete remissions with these drugs?

3. Which is the best moment during the natural history of a progressive thyroid carcinoma to initiate a TKI in order to obtain the greatest and most durable result?

4. How can we anticipate the responsiveness of a patient to a selected drug or combination of drugs?

Answers to the above questions will surely come from ongoing and future clinical trials. However, a refinement in the search of molecular targeted therapies is needed. The efficacy of this strategy requires novel methods, including integrative genomics and systems biology, to identify the state of oncogene addiction (i.e., the “Achilles heel”) in specific cancers (44). Combination therapy (i.e., different TKIs or TKI + cytotoxic chemotherapy or TKI + radioiodine when feasible) may also be required to prevent the escape of cancers from a given state of oncogene addiction and/or to obtain more durable remissions.

Ultimately, a more detailed understanding of the genetics and biology of thyroid carcinoma, coupled with advances in medicinal chemistry and a strict collaboration between scientists and clinicians, will yield new therapies that will overcome possible tumor resistance to treatment and improve the outcome of advanced thyroid carcinoma patients.

Acknowledgments: We wish to thank Mrs. Katherine Brandt Tonato for her editorial assistance. This work was supported by “Fondazione Cassa di Risparmio di Perugia” and “Associazione Italiana per la Ricerca sul Cancro (IG 9338)”.

Disclosure: no potential conflict of interest relevant to this article was reported.

REFERENCES

1. Sherman SI. Thyroid carcinoma. *Lancet*. 2003;361:501-11.
2. Surveillance Research Program CSB Surveillance, Epidemiology and End Results (SEER) Program, November 2003 (Edn) National Cancer Institute 2004.
3. Horner MJ, Ries LAG, Krapcho M, Neyman N, Aminou R, Howlader N, et al. SEER Cancer Statistics Review, 1975-2006, National Cancer Institute. Bethesda, MD, http://seer.cancer.gov/csr/1975_2006/, based on November 2008 SEER data submission, posted to the SEER web site, 2009. Last accessed November 25th 2009.
4. American Thyroid Association (ATA) Guidelines Taskforce on Thyroid Nodules and Differentiated Thyroid Cancer, Cooper DS, Doherty GM, Haugen BR, Kloos RT, Lee SL, Mandel SJ, Mazzaferri EL, McIver B, Pacini F, Schlumberger M, Sherman SI, Steward DL, Tuttle RM. Revised American Thyroid Association management guidelines for patients with thyroid nodules and differentiated thyroid cancer. *Thyroid* 2009;19:1167-214.
5. Patel KN, Shaha AR. Poorly differentiated and anaplastic thyroid cancer. *Cancer Control*. 2006;13:119-28.
6. American Thyroid Association Guidelines Task Force, Kloos RT, Eng C, Evans DB, Francis GL, Gagel RF, Gharib H, Moley JF, Pacini F, Ringel MD, Schlumberger M, Wells SA Jr. Medullary thyroid cancer: management guidelines of the American Thyroid Association. *Thyroid*. 2009;19:565-612.
7. Baudin E, Schlumberger M. New therapeutic approaches for metastatic thyroid carcinoma. *Lancet Oncol*. 2007;8:148-56.
8. Tubiana M, Schlumberger M, Rougier P, Laplanche A, Benhamou E, Gardet P, et al. Long-term results and prognostic factors in patients with differentiated thyroid carcinoma. *Cancer*. 1985;55:794-804.
9. Rouxel A, Hejblum G, Bernier MO, Boëlle PY, Ménégau F, Mansour G, et al. Prognostic factors associated with the survival of patients developing loco-regional recurrences of differentiated thyroid carcinomas. *J Clin Endocrinol Metab*. 2004;89:5362-8.
10. Eustatia-Rutten CF, Corssmit EP, Biermasz NR, Pereira AM, Romijn JA, Smit JW. Survival and death causes in differentiated thyroid carcinoma. *J Clin Endocrinol Metab*. 2006;91:313-9.
11. Durante C, Haddy N, Baudin E, Leboulleux S, Hartl D, Travaglini JP, et al. Long-term outcome of 444 patients with distant metastases from papillary and follicular thyroid carcinoma: benefits and limits of radioiodine therapy. *J Clin Endocrinol Metab*. 2006;91:2892-9.
12. Casara D, Rubello D, Saladini G, Masarotto G, Favero A, Girelli ME, et al. Different features of pulmonary metastases in differentiated thyroid cancer: natural history and multivariate statistical analysis of prognostic variables. *J Nucl Med*. 1993;34:1626-31.
13. Dinneen SF, Valimaki MJ, Bergstralh EJ, Goellner JR, Gorman CA, Hay ID. Distant metastases in papillary thyroid carcinoma: 100 cases observed at one institution during 5 decades. *J Clin Endocrinol Metab*. 1995;80:2041-5.
14. Sherman SI. Advances in chemotherapy of differentiated epithelial and medullary thyroid cancers. *J Clin Endocrinol Metab*. 2009;94:1493-9.
15. Shimaoka K, Schoenfeld DA, DeWys WD, Creech RH, DeConti R. A randomized trial of doxorubicin versus doxorubicin plus cisplatin in patients with advanced thyroid carcinoma. *Cancer*. 1985;56:2155-60.
16. Williams SD, Birch R, Einhorn LH. Phase II evaluation of doxorubicin plus cisplatin in advanced thyroid cancer: a Southeastern Cancer Study Group Trial. *Cancer Treat Rep*. 1986;70:405-7.
17. Droz JP, Schlumberger M, Rougier P, et al. Chemotherapy in metastatic nonanaplastic thyroid cancer: experience at the Institut Gustave-Roussy. *Tumori*. 1990;76:480-3.
18. Leboulleux S, Baudin E, Travaglini JP, Schlumberger M. Medullary thyroid carcinoma. *Clin Endocrinol (Oxf)*. 2004;61:299-310.
19. Schlumberger M, Gardet P, De Vathaire F, Sarrazin D, Travaglini JP, Parmentier C. External radiotherapy and chemotherapy in MTC patients. In: *Medullary Thyroid Carcinoma 1991* (eds Calmettes C, Guliana JM), p. 211, 213-20. Colloque INSERM/John Libbey, Eurotext Ltd, Paris, France.
20. Schlumberger M, Abdelmoumene N, Delisle MJ, Couette JE. Treatment of advanced medullary thyroid cancer with an alternating combination of 5 FU-streptozocin and 5 FU-dacarbazine. The Groupe d'Etude des Tumeurs a Calcitonine (GETC). *Br J Cancer*. 1995;71:363-5.
21. Druker BJ, Sawyers CL, Kantarjian H, Resta DJ, Reese SF, Ford JM, et al. Activity of a specific inhibitor of the BCR-ABL tyrosine kinase in the blast crisis of chronic myeloid leukemia and acute lymphoblastic leukemia with the Philadelphia chromosome. *N Engl J Med*. 2001;344:1038-42.
22. Vriens MR, Schreinemakers JM, Suh I, Guerrero MA, Clark OH. Diagnostic markers and prognostic factors in thyroid cancer. *Future Oncol*. 2009;5:1283-93.
23. Santoro M, Melillo RM, Fusco A. RET/PTC activation in papillary thyroid carcinoma: European Journal of Endocrinology Prize Lecture. *Eur J Endocrinol*. 2006;155:645-53.
24. Fusco A, Santoro M. 20 years of RET/PTC in thyroid cancer: clinico-pathological correlations. *Arq Bras Endocrinol Metabol*. 2007;51:731-5.
25. Greco A, Miranda C, Pierotti MA. Rearrangements of NTRK1 gene in papillary thyroid carcinoma. *Mol Cell Endocrinol*. 2009;Oct 31. [Epub ahead of print]
26. Xing M. BRAF mutation in papillary thyroid cancer: pathogenic role, molecular bases, and clinical implications. *Endocr Rev*. 2007;28:742-62.
27. Moretti S, Macchiarulo A, De Falco V, Avenia N, Barbi F, Carta C, et al. Biochemical and molecular characterization of the novel BRAF(V599Ins) mutation detected in a classic papillary thyroid carcinoma. *Oncogene*. 2006;25:4235-40.
28. Puxeddu E, Durante C, Avenia N, Filetti S, Russo D. Clinical implications of BRAF mutation in thyroid carcinoma. *Trends Endocrinol Metab*. 2008;19:138-45.
29. Puxeddu E, Moretti S. Clinical prognosis in BRAF-mutated PTC. *Arq Bras Endocrinol Metabol*. 2007;51:736-47.
30. Vasko V, Ferrand M, Di Cristofaro J, Carayon P, Henry JF, de Micco C. Specific pattern of RAS oncogene mutations in follicular thyroid tumors. *J Clin Endocrinol Metab*. 2003;88:2745-52.
31. Nikiforova MN, Lynch RA, Biddinger PW, Alexander EK, Dorn GW 2nd, Tallini G, et al. RAS point mutations and PAX8-PPAR gamma rearrangement in thyroid tumors: evidence for distinct molecular pathways in thyroid follicular carcinoma. *J Clin Endocrinol Metab*. 2003;88:2318-26.
32. Kroll TG. Molecular events in follicular thyroid tumors. *Cancer Treat Res*. 2004;122:85-105.
33. Kimura ET, Nikiforova MN, Zhu Z, Knauf JA, Nikiforov YE, Fagin JA. High prevalence of BRAF mutations in thyroid cancer: genetic evidence for constitutive activation of the RET/PTC-RAS-BRAF signaling pathway in papillary thyroid carcinoma. *Cancer Res*. 2003;63:1454-7.
34. Wang Y, Hou P, Yu H, Wang W, Ji M, Zhao S, et al. High prevalence and mutual exclusivity of genetic alterations in the phosphatidylinositol-3-kinase/akt pathway in thyroid tumors. *J Clin Endocrinol Metab*. 2007;92:2387-90.
35. Ricarte-Filho JC, Ryder M, Chitale DA, Rivera M, Heguy A, Ladanyi M, et al. Mutational profile of advanced primary and metastatic radioactive iodine-refractory thyroid cancers reveals distinct pathogenetic roles for BRAF, PIK3CA, and AKT1. *Cancer Res*. 2009;69:4885-93.
36. Malaguarnera R, Vella V, Vigneri R, Frasca F. p53 family proteins in thyroid cancer. *Endocr Relat Cancer*. 2007;14:43-60.

37. Smallridge RC, Marlow LA, Copland JA. Anaplastic thyroid cancer: molecular pathogenesis and emerging therapies. *Endocr Relat Cancer*. 2009;16:17-44.
38. Puxeddu E, Fagin JA. Genetic markers in thyroid neoplasia. *Endocrinol Metab Clin North Am*. 2001;30:493-513.
39. Kouvaraki MA, Shapiro SE, Perrier ND, Cote GJ, Gagel RF, Hoff AO, et al. RET proto-oncogene: a review and update of genotype-phenotype correlations in hereditary medullary thyroid cancer and associated endocrine tumors. *Thyroid*. 2005;15:531-44.
40. Carlomagno F, Guida T, Anaganti S, Vecchio G, Fusco A, Ryan AJ, et al. Disease associated mutations at valine 804 in the RET receptor tyrosine kinase confer resistance to selective kinase inhibitors. *Oncogene*. 2004;23:6056-63.
41. Romei C, Elisei R, Pinchera A, et al. Somatic mutations of the ret proto-oncogene in sporadic medullary thyroid carcinoma are not restricted to exon 16 and are associated with tumor recurrence. *J Clin Endocrinol Metab*. 1996;81:1619-22.
42. Elisei R, Cosci B, Romei C, Bottici V, Renzini G, Molinaro E, et al. Prognostic significance of somatic RET oncogene mutations in sporadic medullary thyroid cancer: a 10-year follow-up study. *J Clin Endocrinol Metab*. 2008;93:682-7.
43. Ferrara N, Kerbel RS. Angiogenesis as a therapeutic target. *Nature*. 2005;438:967-74.
44. Weinstein IB, Joe A. Oncogene addiction. *Cancer Res*. 2008;68:3077-80.
45. Inai T, Mancuso M, Hashizume H, Baffert F, Haskell A, Baluk P, et al. Inhibition of vascular endothelial growth factor (VEGF) signaling in cancer causes loss of endothelial fenestrations, regression of tumor vessels, and appearance of basement membrane ghosts. *Am J Pathol*. 2004;165:35-52.
46. Cohen EE, Rosen LS, Vokes EE, Kies MS, Forastiere AA, Worden FP, et al. Axitinib is an active treatment for all histologic subtypes of advanced thyroid cancer: results from a phase II study. *J Clin Oncol*. 2008;26:4708-13.
47. Eisenhauer EA, Therasse P, Bogaerts J, Schwartz LH, Sargent D, Ford R, et al. New response evaluation criteria in solid tumours: revised RECIST guideline (version 1.1). *Eur J Cancer*. 2009;45:228-47.
48. Polverino A, Coxon A, Starnes C, Diaz Z, DeMelfi T, Wang L, et al. AMG 706, an oral, multikinase inhibitor that selectively targets vascular endothelial growth factor, platelet-derived growth factor, and kit receptors, potently inhibits angiogenesis and induces regression in tumor xenografts. *Cancer Res*. 2006;66:8715-21.
49. Sherman SI, Wirth LJ, Droz JP, Hofmann M, Bastholt L, Martins RG, et al. Motesanib Thyroid Cancer Study Group. Motesanib diphosphate in progressive differentiated thyroid cancer. *N Eng J Med*. 2008;359:31-42.
50. Schlumberger M, Elisei R, Bastholt L, Wirth LJ, Martins RG, Locati LD, et al. Phase II study of safety and efficacy of motesanib in patients with progressive or symptomatic, advanced or metastatic medullary thyroid cancer. *J Clin Oncol*. 2009;27:3794-801.
51. Wilhelm SM, Carter C, Tang L, Wilkie D, McNabola A, Rong H, et al. BAY 43-9006 exhibits broad spectrum oral antitumor activity and targets the RAF/MEK/ERK pathway and receptor tyrosine kinases involved in tumor progression and angiogenesis. *Cancer Res*. 2004;64:7099-109.
52. Gupta-Abramson V, Troxel AB, Nellore A, Puttaswamy K, Redlinger M, Ransone K, et al. Phase II trial of sorafenib in advanced thyroid cancer. *J Clin Oncol*. 2008;26:4714-9.
53. Kloos RT, Ringel MD, Knopp MV, Hall NC, King M, Stevens R, et al. Phase II trial of sorafenib in metastatic thyroid cancer. *J Clin Oncol*. 2009;27:1675-84.
54. Hoftijzer H, Heemstra KA, Morreau H, Stokkel MP, Corssmit EP, Gelderblom H, et al. Beneficial effects of sorafenib on tumor progression, but not on radioiodine uptake, in patients with differentiated thyroid carcinoma. *Eur J Endocrinol*. 2009;161:923-31.
55. Kober F, Hermann M, Handler A, Krotla G. Effect of sorafenib in symptomatic metastatic medullary thyroid cancer. *J Clin Oncol*. 2007;25:Abstract 14065.
56. Hong DS, Sebti SM, Newman RA, Blaskovich MA, Ye L, Gagel RF, et al. Phase I trial of a combination of the multikinase inhibitor sorafenib and the farnesyltransferase inhibitor tipifarnib in advanced malignancies. *Clin Cancer Res*. 2009;15:7061-8.
57. Kim DW, Jo YS, Jung HS, Chung HK, Song JH, Park KC, et al. An orally administered multitarget tyrosine kinase inhibitor, SU11248, is a novel potent inhibitor of thyroid oncogenic RET/papillary thyroid cancer kinases. *J Clin Endocrinol Metab*. 2006;91:4070-6.
58. Cohen EE, Needles BM, Cullen KJ, Wong SJ, Wade JLIII, Ivy SP, et al. Phase 2 study of sunitinib in refractory thyroid cancer. *J Clin Oncol*. 2008;26:6025.
59. Ravaud A, de la Fouchardière C, Courbon F, Asselineau J, Klein M, Nicoli-Sire P, et al. Sunitinib in patients with refractory advanced thyroid cancer: the THYSU phase II trial. *J Clin Oncol*. 2008;26:6058.
60. Torino F, Corsello SM, Longo R, Barnabei A, Gasparini G. Hypothyroidism related to tyrosine kinase inhibitors: an emerging toxic effect of targeted therapy. *Nat Rev Clin Oncol*. 2009;6:219-28.
61. Wedge SR, Ogilvie DJ, Dukes M, Kendrew J, Chester R, Jackson JA, et al. ZD6474 inhibits vascular endothelial growth factor signaling, angiogenesis, and tumor growth following oral administration. *Cancer Res*. 2002;62:4645-55.
62. Carlomagno F, Vitagliano D, Guida T, Ciardiello F, Tortora G, Vecchio G, et al. ZD6474, an orally available inhibitor of KDR tyrosine kinase activity, efficiently blocks oncogenic RET kinases. *Cancer Res*. 2002;62:7284-90.
63. Wells SA Jr, Gosnell JE, Gagel RF, Moley JF, Pfister DG, Sosa JA, et al. Vandetanib in metastatic hereditary medullary thyroid cancer: Follow-up results of an open-label phase II trial. *J Clin Oncol*. 2007;25:6018.
64. Haddad RI, Krebs AD, Vasselli J, Paz-Ares LG, Robinson B. A phase II open-label study of vandetanib in patients with locally advanced or metastatic hereditary medullary thyroid cancer. *J Clin Oncol*. 2008;26:6024.
65. Cui JJ. Inhibitors targeting hepatocyte growth factor receptor and their potential therapeutic applications. *Expert Opin Ther Pat*. 2007;17:1035-45.
66. Kurzrock R, Sherman S, Hong D, Ng C, Frye J, Janisch L, et al. A phase I study of XL184, a MET, VEGFR2, and RET kinase inhibitor, administered orally to patients (pts) with advanced malignancies, including a subgroup of pts with medullary thyroid cancer (MTC). Proc 20th EORTCNCI-AACR Symposium on Molecular Targets and Cancer Therapeutics 2008, Geneva, Switzerland, p. 119 (Abstract 379).
67. Comoglio PM, Giordano S, Trusolino L. Drug development of MET inhibitors: targeting oncogene addiction and expedience. *Nat Rev Drug Discov*. 2008;7:504-16.
68. Liu YY, Stokkel MP, Pereira AM, Corssmit EP, Morreau HA, Romijn JA, et al. Bexarotene increases uptake of radioiodide in metastases of differentiated thyroid carcinoma. *Eur J Endocrinol*. 2006;154:525-31.
69. Su YB, Tuttle RM, Fury M, Ghossein R, Singh B, Herman K, et al. A phase II study of single agent desipeptide (DEP) in patients (pts) with radioactive iodine (RAI)-refractory, metastatic, thyroid carcinoma: preliminary toxicity and efficacy experience. *J Clin Oncol*. 2006;24:5554.
70. Kebebew E, Peng M, Reiff E, Treseler P, Woeber KA, Clark OH, et al. A phase II trial of rosiglitazone in patients with thyroglobulin-positive and radioiodine-negative differentiated thyroid cancer. *Surgery* 2006;140:960-6.