



Cardiac tamponade as a late complication of a minor trauma due to syncope: A case report and literature review

Hong Kong Journal of Emergency Medicine
1–4

© The Author(s) 2018

Article reuse guidelines:

sagepub.com/journals-permissions

DOI: 10.1177/1024907918793790

journals.sagepub.com/home/hkj



Matteo Guarino¹, Alessandra Bologna¹, Alfredo De Giorgi¹, Michele D Spampinato¹ , Christian Molino¹, Dario Gozzi¹, Laura Tonelli¹, Fabio Fabbian¹, Andrea Strada² and Roberto De Giorgio¹

Abstract

Haemopericardium with cardiac tamponade following minor blunt trauma is a rare, life-threatening condition. The diagnosis of cardiac tamponade as well as therapeutic management may be delayed, since the link between trauma and illness is often overlooked. We report the case of an old woman who developed a relatively delayed cardiac tamponade due to an otherwise minor blunt chest trauma following syncope.

Keywords

Pericardial tamponade, minor trauma, blunt chest trauma

Introduction

Cardiac tamponade is a life-threatening condition characterized by compression of the heart caused by a slow or rapid accumulation of liquid, pus, blood, clots or gas in the pericardium. These are usually secondary to inflammation, trauma, rupture of the heart or aortic dissection.^{1–3}

Haemopericardium with cardiac tamponade following minor blunt trauma is a rare and challenging condition for any physicians working in emergency units.⁴ Clinical sequelae from blunt cardiac trauma may range from minor electrocardiographic abnormalities to death due to free-wall rupture;⁵ however, concomitant comorbid conditions of patients could play a major contributory role and should be carefully considered.

Case report

An 87-year-old woman was admitted to the Emergency Department because she fell to the ground due to a likely syncopal episode. As a result of the trauma, the patient had

a contusion of the left part of the chest in the absence of radiologically evident rib fractures. Chest and hemithorax X-ray as well as abdominal ultrasound were unremarkable. Her clinical history evaluation disclosed multiple comorbidities such as hypertension (treated with angiotensin-converting enzyme inhibitors and diuretics), paroxysmal atrial fibrillation in oral anticoagulant therapy (warfarin), New

¹Department of Medical Sciences, Clinica Medica Unit, School of Specialization in Emergency Medicine, Faculty of Medicine, Pharmacy and Prevention, University of Ferrara, Ferrara, Italy

²Department of Medical Sciences, Emergency Department, School of Specialization in Emergency Medicine, Faculty of Medicine, Pharmacy and Prevention, University of Ferrara, Ferrara, Italy

Corresponding author:

Matteo Guarino, Department of Medical Sciences, Clinica Medica Unit, School of Specialization in Emergency Medicine, Faculty of Medicine, Pharmacy and Prevention, University of Ferrara, Nuovo Arcispedale St. Anna in Cona, Via Aldo Moro 8, Ferrara 44124, Italy.
Email: grnmtt@unife.it



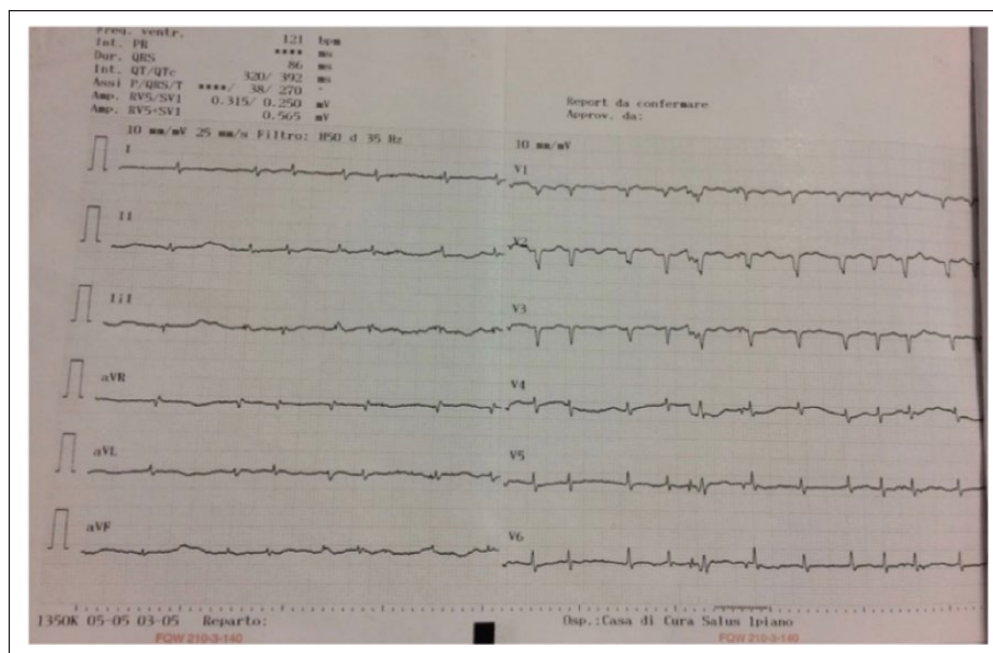


Figure 1. Representative ECG showing the low voltage in all leads and electric alternations suggestive of cardiac tamponade.

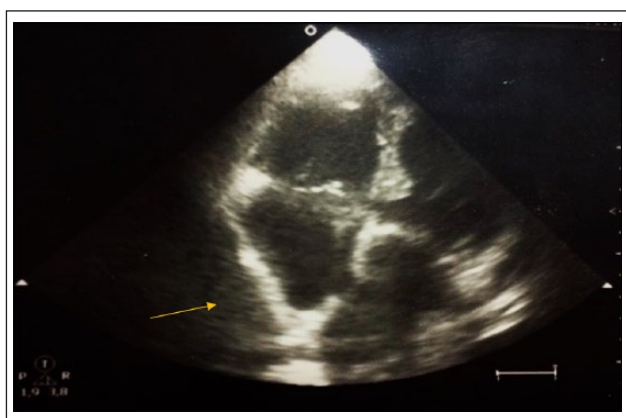

Figure 2. Bedside echocardiography picture showing accumulation of fluids (arrow) in the pericardial area indicative of cardiac tamponade.

RA: right atrium; RV: right ventricle; LA: left atrium; LV: left ventricle; PE: pericardial effusion.

York Heart Association (NYHA) class II heart failure, chronic kidney disease and chronic vascular encephalopathy with mild cognitive impairment.

At the time of the first visit, the patient appeared awake, collaborating although confused. The thoraco-abdominal physical examination as well as thorough neurological evaluation did not show significant alterations or acute deficits (in particular she did not present any chest wall tenderness or bruises). Vital parameters were normal, blood pressure 120/70 mmHg, heart rate 75 beats per minute and oxygen saturation was optimal (96%). Blood chemistry tests confirmed stable renal dysfunction, international normalized

ratio (INR) coagulation test was in the therapeutic range for warfarin treatment and D-dimer index was within the normal one. The following morning, the patient's clinical conditions rapidly worsened with the appearance of dyspnoea, arterial hypotension and loss of consciousness. High-flow O₂ was administered with a slight improvement in the respiratory panel and electrocardiogram revealed atrial tachyarrhythmia with a mean frequency of 150 bpm along with the evidence of low voltages in all leads (Figure 1). A transthoracic bedside echocardiography was performed and this test documented a significant pericardial effusion (with apparently corpuscular fluid) mainly located at the right atrium level, with atrial wall compression, and resultant acute cardiac tamponade (Figure 2). The clinical picture worsened rapidly, thus preventing any further therapeutic procedures also considering the will of the patient's relatives who denied a pericardiocentesis measure. Finally, the patient died due to the significant haemodynamic failure related to the cardiac (likely haemorrhagic) tamponade.

Discussion

Cardiac tamponade results from an accumulation of pericardial fluid increasing the pressure around the heart, leading to impaired cardiac filling and haemodynamic abnormalities.² Beck's triad, that is, sinus tachycardia, elevated jugular venous pressure and low arterial blood pressure, along with *pulsus paradoxus*, represents the main clinical features suggesting the occurrence of such life-threatening condition. Although mainly clinical, the diagnosis of cardiac tamponade should be confirmed by a

Table 1. Other cases that correlate minor trauma to pericardial tamponade.

Authors	Age (years)	Sex	OACs	Side of chest trauma	Rib fractures	Diagnostic test	Outcome	Delayed diagnosis (days)	ISS
Martin et al. ¹⁰	48	Male	No	Right and left	No	CC	Favourable	42	3
Indrani et al. ¹¹	9	Male	No	Left	No	TTE	Unknown	7	3
Ombrellaro and Hagedorn ¹²	19	Female	No	Right and left	No	Open	Favourable	1	3
Herbots et al. ¹³	15	Male	No	Right and left	No	TTE	Favourable	120	9
Speight and Sanders ¹⁴	18	Female	No	Right and left	No	TEE	Favourable	0	11
Hermens et al. (2007) ⁹	70	Male	No	Left	No	TTE	Favourable	30	3
Davey et al. ¹⁵	63	Male	Unknown	Right	Yes	CT	Unknown	42	3
Campo dell'Orto et al. ¹⁶	17	Male	No	Right and left	No	TTE	Favourable	0	3
Tabansi and Otaigbe ⁴	12	Female	No	Right and left	No	TTE	Favourable	21	3
Liang et al. ¹⁷	58	Male	No	Right and left	No	TTE	Favourable	21	6
Ryu and Lee ¹⁸	81	Male	Unknown	Right and left	Yes	CT	Favourable	14	3
Present case (2018)	87	Female	Yes	Left	No	TTE	Unfavourable	1	3

CC: cardiac catheterism; CT: computer tomography; ISS: injury severity score; OACs: oral anticoagulants; TEE: transesophageal echocardiography; TTE: transthoracic echocardiography.

number of tests including electrocardiogram, chest X-ray, echocardiography and/or more accurate imaging techniques.^{1,2} A recent randomized trial has shown that the use of transthoracic echocardiography improves the timing of the hospital admission of traumatized patients and their transfer to the operating room, thus resulting in a reduced mortality rate.^{1,6} This case suggests that bedside echocardiography should be used to unravel complications caused by minor chest traumas in elderly patients with various comorbidities and under polypharmacological treatment.^{7,8} The treatment of cardiac tamponade is aimed to sustain circulation and decompress the pericardial area by removing the accumulated fluids. This helps relieving pressure surrounding the heart and restore cardiac pump function leading to haemodynamic improvement.⁸ The rapid worsening of clinical conditions, the advanced age and comorbidities without putting aside the ongoing effect of warfarin treatment were all arguments to the detriment for invasive decompression of pericardium in our patient.

Blunt chest trauma may cause cardiac damage varying from minor contusion up to major complications, such as cardiac tamponade.⁹ Clearly, this latter event is expected with major traumas, as the high intensity of impact generates serious damage to the heart that can lead to the development of effusion or even the breaking of the ventricular wall. However, although to a lesser extent, even minor traumas may determine cardiac tamponade as indicated by this and other 11 cases^{4,9,10–19} that have been summarized in Table 1. Notably, there is no direct timing correlation between the traumatic event and cardiac tamponade, that is, the latter occurring from few hours up to months (Table 1).

This case highlights that a clear distinction about major and minor traumas is difficult to be established, particularly in the emergency setting. Many protocols have been

developed in order to identify and treat properly major traumas of the chest. In our case we used the injury severity score (ISS), which measures traumatic events and if the score is more than 15 it indicates a major trauma.¹⁹

In addition to the trauma score, another important factor to be considered is that the elderly population is gradually growing alongside with the co-occurrence of comorbidities. Ageing, multi-morbidities and poly-therapy (including anticoagulants and antiplatelet drugs) are three major risk factors for the development of serious complications. Indeed, our case showed that a minor chest trauma caused a life-threatening condition, that is, cardiac tamponade, in a patient with multi-morbidities and under warfarin treatment.

Conclusion

The experience gained with this case suggests that regardless the intensity of the trauma, any chest injury should require a thorough clinical and instrumental (i.e. beginning with bedside echocardiography) evaluation to timely detect cardiac tamponade. Frail, elderly patients taking anticoagulant or antiplatelet compounds⁶ are at risk for such life-threatening complication even if the traumatic injury occurred is mild.

Acknowledgements

The authors thank Dr Donato Bragatto, Dr Claudia Righini, Mrs Manuela Zappaterra (Biblioteca Interaziendale di Scienza della Salute, Hospital of Ferrara), Mrs Egizia Zironi and Mrs Silvia Bellotti (Unità Servizi Interbibliotecari, University of Ferrara) for their valuable collaboration.

Declaration of conflicting interests

The author(s) declared no potential conflicts of interest with respect to the research, authorship and/or publication of this article.

Funding

The author(s) received no financial support for the research, authorship and/or publication of this article.

Human rights

All procedures performed on the reported patients were conducted in accordance with good clinical practice respectful of any human rights.

Informed consent

Since the report did not show any identification with the patient involved, there was no need for ethics committee approval. Nonetheless, all procedures on the reported patient were subjected to informed consent.

ORCID iD

Michele D Spampinato  <https://orcid.org/0000-0002-2285-327X>

References

- Adler Y, Charron P, Imazio M, et al. 2015 ESC Guidelines for the diagnosis and management of pericardial diseases: The Task Force for the Diagnosis and Management of Pericardial Diseases of the European Society of Cardiology (ESC). Endorsed by: the European Association for Cardio-Thoracic Surgery (EACTS). *Eur Heart J* 2015; 36(42): 2921–2964.
- Spodick DH. Acute cardiac tamponade. *N Engl J Med* 2003; 349: 684–690.
- Ristić AD, Imazio M, Adler Y, et al. Triage strategy for urgent management of cardiac tamponade: a position statement of the European Society of Cardiology Working Group on myocardial and pericardial diseases. *Eur Heart J* 2014; 35: 2279–2284.
- Tabansi PN and Otaigbe BE. Late onset hemopericardium with cardiac tamponade from minor blunt chest trauma – a case report. *Clin Case Rep* 2015; 3(4): 247–250.
- Lancey RA and Monahan TS. Correlation of clinical characteristics and outcomes with injury scoring in blunt cardiac trauma. *J Trauma* 2003; 54(3): 509–515.
- De Caterina R and Abbate R. Lo Studio AVERROES. *G Ital Cardiol* 2011; 12(9): 551–555.
- Imazio M and Hoit BD. Post-cardiac injury syndrome. An emerging cause of pericardial disease. *Int J Cardiol* 2013; 168(2): 648–652.
- Jensen JK, Poulsen SHM and Ølgaard H. Cardiac tamponade: a clinical challenge. *J Cardiol Pract* 2015; 15: 17–27.
- Hermens JA, Wajon EM, Grandjean JG, et al. Delayed cardiac tamponade in a patient with previous minor blunt chest trauma. *Int J Cardiol* 2009; 131(3): e124–e126.
- Martin R, Mitchell A and Dhalla N. Late pericardial tamponade and coronary arteriovenous fistula after trauma. *Br Heart J* 1986; 55: 216–218.
- Indrani S, Raji V, Kalyani N, et al. Sonographic diagnosis of blunt trauma causing delayed hemopericardium and cardiac tamponade. *J Ultrasound Med* 1991; 10(5): 291–293.
- Ombrellaro M and Hagedorn F. Cardiac tamponade: a covert source of hypotension after minor blunt chest trauma. *Am J Emerg Med* 1994; 12(4): 507–509.
- Herbots T, Vermeersch P and Vaerenberg M. Delayed post-traumatic tamponade together with rupture of tricuspid valve in a 15 years old boy. *Heart* 2001; 86(5): E12.
- Speight J and Sanders M. Pericardial tamponade with a positive abdominal FAST scan in blunt chest trauma. *J Trauma* 2006; 61(3): 743–745.
- Davey S, Alam F and Malik S. A delayed presentation of cardiac tamponade after blunt trauma. *J Surg Case Rep* 2011; 2011(9): 1.
- Campo dell’Orto M, Kratz T, Wild C, et al. Pre-hospital ultrasound detects pericardial tamponade in young patients with occult blunt trauma: time for preparation? Case report and review of literature. *Clin Res Cardiol* 2014; 103(5): 409–411.
- Liang HM, Chen QL, Zhan EY, et al. Sternal fracture and delayed cardiac tamponade due to severe blunt chest trauma. *Am J Emerg Med* 2016; 34(4): 758.
- Ryu DW and Lee MK. Cardiac tamponade associated with delayed ascending aortic perforation after blunt chest trauma: a case report. *BMC Surg* 2017; 17(1): 70.
- Baker SP, O’Neill Haddon W and Long WB. The injury severity score: a method of describing patients with multiple injuries and evaluating emergency care. *J Trauma* 1974; 14(3): 187–196.