

## REVIEW ARTICLE

# Defining the actinic keratosis field: a literature review and discussion

I. Figueras Nart,<sup>1,\*</sup> R. Cerio,<sup>2</sup> T. Dirschka,<sup>3,4</sup> B. Dréno,<sup>5</sup> J.T. Lear,<sup>6</sup> G. Pellacani,<sup>7</sup> K. Peris,<sup>8</sup>  
A. Ruiz de Casas,<sup>9</sup> On Behalf of Progressing Evidence in AK (PEAK) Working Group

<sup>1</sup>Department of Dermatology, Bellvitge Hospital, Barcelona, Spain

<sup>2</sup>Department of Cutaneous Medicine and Surgery, The Royal London Hospital and QMUL, Bart's Health NHS Trust, London, UK

<sup>3</sup>CentroDerm<sup>®</sup> Clinic, Wuppertal, Germany

<sup>4</sup>Faculty of Health, University Witten-Herdecke, Witten, Germany

<sup>5</sup>Department of Dermato-Cancerology, University of Nantes, Nantes, France

<sup>6</sup>Manchester Academic Health Science Centre, MAHSC, Manchester University and Salford Royal NHS Foundation Trust, Royal Infirmary, The University of Manchester, Manchester, UK

<sup>7</sup>Department of Dermatology, University of Modena and Reggio Emilia, Modena, Italy

<sup>8</sup>Department of Dermatology, Catholic University of Rome, Rome, Italy

<sup>9</sup>Dermatology Unit, Virgen Macarena University Hospital, Seville, Spain

\*Correspondence: I. Figueras Nart. E-mail: ignasifiguerasnart@gmail.com

## Abstract

Despite the chronic and increasingly prevalent nature of actinic keratosis (AK) and existing evidence supporting assessment of the entire cancerization field during clinical management, a standardized definition of the AK field to aid in the understanding and characterization of the disease is lacking. The objective of this review was to present and appraise the available evidence describing the AK cancerization field, with the aim of determining a precise definition of the AK field in terms of its molecular (including genetic and immunological), histological and clinical characteristics. Eight European dermatologists collaborated to conduct a review and expert appraisal of articles detailing the characteristics of the AK field. Articles published in English before August 2016 were identified using PubMed and independently selected for further assessment according to predefined preliminary inclusion and exclusion criteria. In addition, a retrospective audit of patients with AK was performed to define the AK field in clinical terms. A total of 32 review articles and 47 original research articles provided evidence of sun-induced molecular (including genetic and immunological) and histological skin changes in the sun-exposed area affected by AK. However, the available literature was deemed insufficient to inform a clinical definition of the AK field. During the retrospective audit, visible signs of sun damage in 40 patients with AK were assessed. Telangiectasia, atrophy and pigmentation disorders emerged as 'reliable or very reliable' indicators of AK field based on expert opinion, whereas 'sand paper' was deemed a 'moderately reliable' indicator. This literature review has revealed a significant gap of evidence to inform a clinical definition of the AK field. Therefore, the authors instead propose a clinical definition of field cancerization based on the identification of visible signs of sun damage that are reliable indicators of field cancerization based on expert opinion.

Received: 10 July 2017; Accepted: 9 October 2017

## Conflicts of interest

All authors act as consultants to LEO Pharma. Professor Dirschka reports receiving lecture fees from Almirall, Biofrontera, Galderma, Janssen, LEO Pharma, Meda and Riemser; he is a member of advisory boards for Almirall, Biofrontera, Janssen, LEO Pharma, Meda, Novartis and Riemser. Dr Figueras Nart reports receiving reimbursement by LEO Pharma for national and international conference attendance. Dr Lear is a member of advisory boards for LEO Pharma; he has also received speaker fees from LEO Pharma. Professor Peris is a member of advisory boards for Almirall and LEO Pharma.

## Funding sources

This review was funded by LEO Pharma.

## Introduction

Actinic keratosis (AK) is a chronic and prevalent disease affecting areas of sun-exposed skin<sup>1</sup> where visible and subclinical, non-visible lesions coexist. This area of sun-damaged skin is prone to the development of further visible AK lesions and sun-related skin cancer and is known by many as 'field cancerization'.<sup>2</sup>

The concept of field cancerization was first introduced by Slaughter and colleagues in 1953 when looking at oral squamous cell carcinoma (SCC), to describe histologically abnormal surrounding tissue, which would explain the appearance of additional tumours within the field.<sup>3</sup> Since its first use, this concept has been described in many different organ systems, including head and neck, lung, vulva, oesophagus, cervix, breast, colon, bladder and skin.<sup>4</sup>

In AK, field cancerization occurs as a result of neoplastic changes induced by ultraviolet (UV) light across the whole sun-exposed field of the skin. Various AK stages can coexist within the cancerized field, which have become better characterized with the development of new imaging tools, such as confocal microscopy.<sup>2</sup> These stages include individual UV-damaged keratinocytes, subclinical non-visible lesions, early and late lesions, and in some cases, invasive SCC.<sup>2</sup>

Despite common usage of the term field or field cancerization and the concept being generally accepted, a precise and consistent definition of the AK field is lacking.<sup>5</sup> Without a clear definition of the field to aid in the understanding and characterization of the disease, clinicians are presented with a challenge in classifying and therefore assessing the options for the management of AK.

Given this background, the purpose of this review was to examine the available evidence that describes the AK field, through a systematic review and expert appraisal of the existing literature, to inform a robust definition in terms of the molecular (including genetic and immunological), histological and clinical changes that take place.

## Methodology

A committee was established, consisting of eight expert dermatologists from five European countries. One of the experts defined the criteria for a systematic assessment of the literature relating to the clinical, histological and molecular/genetic/immunological characteristics of the AK field. The search strings used are shown in Table 1. The search was carried out in PubMed and limited to articles in English. Articles published before 31 August 2016 were searched with no limits placed on the starting date.

Articles were independently selected for further assessment by one of the experts according to predefined preliminary inclusion and exclusion criteria. Articles were included if one or more of the following criteria were met: field cancerization was mentioned in the title; field treatment was covered; the genetics of

field disease, AK and SCC were covered; or the article was a published treatment guideline. Articles were excluded from review if they did not refer to field cancerization or were deemed irrelevant to informing a field definition; discussed treatment of specific lesions, melanoma or quality of life only; or related to techniques for modulating pain regarding certain treatments.

The articles selected for further assessment were distributed for review between the experts. Each expert summarized the key evidence that could inform the description of the characteristics of the AK field from their assigned articles. Clinical, histological and molecular/genetic/immunological evidence was captured separately in a standardized template. Experts could exclude articles that did not address field cancerization in AK.

Templates from all expert reviewers were collated. Statements, based on the strongest and most consistent findings from the literature search in terms of molecular/genetic/immunological, histological and clinical evidence, were developed (Table 2, left column). These statements were assessed by all experts and refined at a face-to-face meeting until expert agreement was reached on the summary statements that were best to inform a definition of the AK field from a molecular/genetic/immunological, histological and clinical perspective (Table 2, right column).

Due to the limited evidence existing in the literature to inform a clinical definition, the experts met again to define the AK field

**Table 1** Search strings

Search number	Search string	Number of results
1	'actinic keratosis'[All Fields]	2552
2	'field cancerization'[All Fields] OR 'field cancerisation'[All Fields] OR 'field-cancerized'[All Fields] OR 'skin field cancerization'[All Fields]	511
3	field[All Fields] AND cancerization[All Fields]	533
4	('actinically damaged skin' [All Fields] OR 'photodamaged skin' [All Fields] OR 'sun damaged skin'[All Fields]) OR (subclinical[All Fields] AND photodamage[All Fields])	807
5	('skin'[MeSH Terms] OR 'skin'[All Fields]) AND field[All Fields] AND ('carcinogenesis'[MeSH Terms] OR 'carcinogenesis'[All Fields])	116
6	1 AND 2	83
7	1 AND 3	73
8	1 AND 4	89
9	1 AND 5	7
10	6 OR 7 OR 8 OR 9	166
11	('genetic therapy'[MeSH Terms] OR ('genetic'[All Fields] AND 'therapy'[All Fields]) OR 'genetic therapy'[All Fields] OR 'genetic'[All Fields]) AND 'actinic keratosis'[All Fields]	93
12	molecular[All Fields] AND 'actinic keratosis'[All Fields]	137
13	10 OR 11 OR 12	344

**Table 2** Literature summary statements defining AK field before and after critical appraisal

Type of evidence	Before critical appraisal	After critical appraisal
Molecular/ immunological/ genetic	<ul style="list-style-type: none"> <li>UV radiation induces a cascade of molecular signalling events at a cellular level that produces inflammation, immunosuppression, failure of apoptosis and aberrant differentiation, resulting in mutagenesis and carcinogenesis</li> <li>Changes in the expression of the genes involved in these processes (e.g. tumour suppressor genes, most notably p53) occur frequently within the sun-exposed areas and are the first manifestation of the process known as 'field cancerization'</li> <li>Morphologically normal, sun-exposed tissue surrounding actinic keratosis (AK) and squamous cell carcinoma (SCC) lesions often show similarly altered expression of some of these genes, suggesting the existence of a disease continuum from the initial molecular changes that take place in individual cells to AK to SCC</li> </ul>	<ul style="list-style-type: none"> <li>UV radiation has been shown to induce a cascade of molecular signalling events at a cellular level that produces inflammation and immunosuppression, which can lead to mutagenesis and result in failure of apoptosis, aberrant differentiation and carcinogenesis</li> <li>Mutations and changes in expression of genes involved in these processes (e.g. tumour suppressor genes, most frequently cited p53) occur frequently within sun-exposed areas. This is a manifestation of the concept known as 'field cancerization'</li> <li>Morphologically normal, sun-exposed tissue surrounding actinic keratosis (AK) and squamous cell carcinoma (SCC) lesions often show similarly altered expression of some of these genes; this may suggest the existence of an association between initial molecular changes that take place in individual cells and the development of AK or SCC</li> </ul>
Histological	<ul style="list-style-type: none"> <li>Following the initial molecular changes, histopathological changes characteristic of AK can be detected</li> <li>Changes include crowded, atypical, epidermal keratinocytes with large, hyperchromatic and pleomorphic nuclei, some in mitosis</li> <li>Significant histological alterations, suggesting extensive preneoplastic alterations are often present in sun-damaged skin adjacent to visible AK lesions, providing further evidence for 'field cancerization' and a disease continuum</li> </ul>	<ul style="list-style-type: none"> <li>Histopathological changes known to be characteristic of AK can be detected following molecular changes</li> <li>Histopathological changes include crowding of atypical, epidermal keratinocytes with large, hyperchromatic and pleomorphic nuclei, some in mitosis; some of these changes can be seen in perilesional skin</li> </ul>
Clinical	<ul style="list-style-type: none"> <li>Visible AKs are most often seen on a background of sun-damaged skin (e.g. dermatoheliosis with solar elastosis, yellow discoloration, dyspigmentation, telangiectasias, ephelides, lentigos, sagging skin)</li> </ul>	<ul style="list-style-type: none"> <li>Visible AKs are most often seen on a background of clinically sun-damaged skin. <b>A clear definition and consensus on what constitutes sun damage is lacking</b></li> </ul>

in clinical terms based on their experience in clinical practice. Prior to the meeting, all experts carried out a retrospective audit, listing all visible signs of sun damage identifiable in their last five patients with AK (40 patients in total). At the meeting, these signs were ranked on their reliability as indicators of AK field disease on a scale from 1 to 9, where 1 represents 'strongly disagree' and 9 represents 'strongly agree' (Fig. 1). If at least 5/8 experts voted on a visible sign being reliable/very reliable (scores 7–9) or moderately reliable (scores 4–6) and unanimous agreement was reached following a moderated discussion, that visible sign of sun damage was accepted as a reliable indicator of AK field. Accepted reliable visible signs of sun damage were used to provide a clinical definition of AK field. Recommendations for disease management in the presence of the signs of sun damage indicative of field cancerization were then made.

## Results

The numbers of studies originally identified, assessed and finally included in the review are summarized in Fig. 2. A total of 32 review articles and 47 original research articles were included and reviewed. A detailed summary of the evidence from all original research articles, broadly categorized into molecular/genetic/immunological, histological and clinical and 'infraclinical' (with imaging techniques allowing visualization of deep layers of the

skin) evidence, is presented in Table 3. The key findings are summarized below.

## Literature review

**Molecular/genetic/immunological evidence** Twenty-nine studies provided molecular/genetic/immunological evidence relevant to inform a field definition in AK (Table 3).<sup>6–34</sup>

Evidence from the literature suggests that UVB-induced molecular/genetic/immunological changes take place in the entire anatomical area affected by AK and can lead to abnormalities in keratinocyte proliferation.<sup>35</sup>

For instance, several signalling pathways are affected in the UVB-induced transformation from normal skin to AK and SCC. In addition, downregulation of the Notch effector CSL (also known as RBP-Jκ) in dermal fibroblasts is sufficient for cancer-associated fibroblast (CAF) activation and ensuing keratinocyte-derived tumours. This activity has been observed in stromal fibroblasts of premalignant AK lesions and *in situ* SCCs.<sup>6,13</sup> Alterations in the RAF-1/MER/ERK cell survival pathway have also been observed.<sup>21</sup> Furthermore, UVB-induced changes in gene/protein expression play a role in the development of AK and SCC. These include changes affecting DNA damage repair responses,<sup>8,16,21</sup> loss of heterozygosity in chromosomes 6 and

### How RELIABLE are these visible signs of sun-damage as indicators of AK field disease?



Strongly disagree



Strongly agree

1	2	3	4	5	6	7	8	9
---	---	---	---	---	---	---	---	---

Please select the most appropriate score number (1-9) within each range

Sign*	Not reliable (≤33% of patients)			Moderately reliable (34-66% of patients)			Reliable/very reliable (≥67% of patients)		
	1	2	3	4	5	6	7	8	9
Erythema									
Redness									
Telangiectasia									
Inflammation									
Atrophy									
Scales									
Sand paper									
Xerosis									
Solar elastosis									
Wrinkles									
Cutis rhomboidalis									
Sagging skin									
Pigmentation disorders									
Polychromia									
Hypopigmentation									
Poikiloderma									
Yellow discoloration									
Freckles									
Lentigines									

\*Identified in audit

**Figure 1** Visible signs of sun damage identified in retrospective audit of patients with AK.

9<sup>17,24</sup> and alterations in tumour suppressor genes, including p53,<sup>6,22,24,26,27,32,36</sup> PTEN<sup>15,19</sup> and p16INK4a and p14ARF.<sup>24</sup> Microsatellite instability in chromosomes 6 and 9 has also been observed in AK and SCC lesions.<sup>17,24</sup>

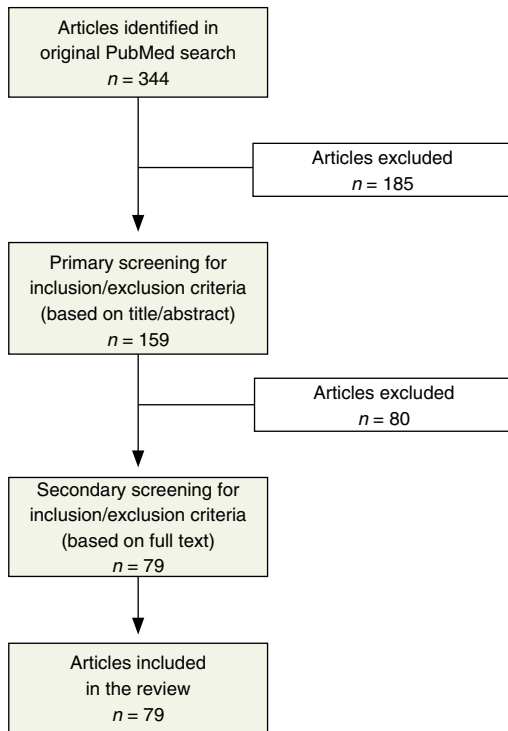
Many mutations and changes in gene expression are already observed in photodamaged skin, becoming increasingly prominent in AK and SCC. Therefore, photodamaged skin, AK and SCC are thought to be part of a disease continuum corresponding to field cancerization.<sup>37</sup>

Changes in intracellular signalling pathways, mediated by DNA damage induced by oxidative stress, can lead to alterations in cytokine regulation, inflammation, changes in T-cell homeostasis and immunosuppression.<sup>25,35</sup> The innate immune system, therefore, plays a key role in AK – the intense inflammatory response includes a significant increase in T lymphocytes

and Langerhans cells.<sup>13,25,35</sup> Based on the evidence above, preliminary statements to define the AK field from a molecular/genetic/immunological perspective were brought forward for expert appraisal (Table 2, before critical appraisal column).

**Histological evidence** Eleven studies provided histological evidence relevant to inform a field definition in AK (Table 3).<sup>36–46</sup>

These studies reported histological changes common to photodamaged skin adjacent to visible AK lesions as well as visible AK lesions, such as corneocytes, stratum corneum disruption, dermal inflammatory cells, increased vascularity/dilated vessels and solar elastosis. Keratinocyte pleomorphism and architectural changes as well as nuclear morphometric alterations were also common to both photodamaged skin and visible AK lesions, but generally more severe in the latter.<sup>37–39,45</sup> These findings were



**Figure 2** Study selection flow diagram.

interpreted as providing evidence for a disease continuum from photodamaged skin to AK corresponding to field cancerization.<sup>37</sup>

The fact that AKs are frequently found in the skin immediately surrounding cutaneous malignancies (SCCs, and less frequently basal cell carcinomas and malignant melanomas) has also been interpreted as providing additional evidence for field cancerization.<sup>46</sup>

Based on the evidence above, preliminary statements to define the AK field histologically were brought forward for expert appraisal (Table 2, before critical appraisal column).

**Clinical or 'infraclinical' evidence** Fourteen studies provided clinical or 'infraclinical' evidence relevant to inform a field definition in AK (Table 3).<sup>2,36,37,41–44,47–53</sup>

Only one study attempted to give a clinical definition of field cancerization as '*mild, moderate or severe, based on the degree to which the surrounding skin [adjacent to visible AK lesions] presented mottled erythema and pigmentation, telangiectasia, sallowness, laxity and a dry texture without fulfilling the definition of an AK lesion*'.<sup>47</sup>

The remaining studies reported on the usefulness of traditional imaging techniques, such as fluorescence and hyperspectral imaging (HIS), or more modern imaging techniques, including reflectance confocal microscopy (RCM) and optical

coherence tomography (OCT) to detect subclinical actinic changes (i.e. field cancerization) in anatomical areas adjacent to clinically visible AKs and other visible signs of photodamage (e.g. mottled pigmentation, fine lines, sallowness, roughness, facial erythema, telangiectasias, laxity, coarse wrinkles, dry texture).<sup>2,36,37,41–44,47–50,52,53</sup>

There was good concordance between diagnosis and grading of AK (clinical and subclinical) performed with HIS, RCM or OCT and histological analysis of biopsied tissue, suggesting that these techniques provide a suitable, non-invasive alternative for diagnosis.<sup>2,41–44,48,52,53</sup> The usefulness of RCM to monitor improvements in subclinical AK following treatment with field-directed therapies was also reported.<sup>40,52,53</sup>

Based on the limited clinical evidence available, preliminary statements to define the AK field clinically were brought forward for expert appraisal (Table 2, 'before expert appraisal' column). The need for a clear definition of visible clinical signs indicative of AK field was identified, and a retrospective audit of visible clinical signs of AK field was carried out to meet this need.

#### Clinical signs of AK field: retrospective audit results

Of all the visible signs of sun damage identified during the retrospective audit (Fig. 2), telangiectasia, atrophy and pigmentation disorders emerged as 'reliable or very reliable' indicators of AK field based on expert opinion. 'Sand paper' was deemed a 'moderately reliable' indicator of AK field.

#### Discussion

There is a large body of evidence on the UVB-induced changes that take place in the skin at a molecular/genetic/immunological level and at a histological level that can form the basis for a definition of the AK field, as summarized by the statements in Table 2. Following critical appraisal of the literature, however, the authors agreed on some points needing clarification.

UV radiation has, indeed, been shown to induce a cascade of molecular signalling events at a cellular level in the skin that produces inflammation and immunosuppression.<sup>6,13,21,35</sup> A decrease in innate immunity with ageing (immunosenescence) and sun exposure is well characterized.<sup>54,55</sup> These events can lead to mutagenesis and result in failure of apoptosis, aberrant differentiation and carcinogenesis,<sup>35</sup> but it is important to emphasize that this is not always the case as genetic make-up and environmental factors all play a major role in determining the final outcome.<sup>54</sup>

Furthermore, multiple mutations and changes in gene expression have been identified in sun-exposed areas of the skin, many of which have been shown to play a role in the development of AK and SCC.<sup>8,16,17,24</sup> The role of the tumour suppressor gene p53 has been widely studied and reported.<sup>6,22,24,26,27,32,36</sup> For this reason, its importance may have been overemphasized. Many other tumour suppressor genes are deregulated and also play a crucial role in AK development,<sup>14,15,19,24</sup> such as p16INK4a, p14ARF and PTEN.<sup>15,19</sup>

**Table 3** Summary of original research publications relevant to inform a definition of AK field in molecular/immunological/genetic, histological and clinical terms

References	Year	Methodology	Key findings
<b>Clinical, histological and molecular</b>			
36	2012	<ul style="list-style-type: none"> <li>Patients with PD skin and multiple AK on the face (<math>n = 26</math>) received three consecutive sessions of MAL-PDT with red light (<math>37 \text{ J/cm}^2</math>), 1 month apart</li> <li>All patients were evaluated for global photoaging, mottled pigmentation, fine lines, sallowness, roughness, facial erythema, telangiectasias and coarse wrinkles</li> <li>Biopsies before and 3 months after the last treatment session were taken from normal-appearing skin on the field-cancerized area</li> <li>IHC stainings were performed for TP-53, procollagen-I, MMP-1 and Tn-C</li> </ul>	<ul style="list-style-type: none"> <li>Results demonstrate clinical and histological improvement in field cancerization after multiple sessions of MAL-PDT</li> <li>All clinical parameters improved and were statistically significant except coarse wrinkles</li> <li>The improvement of PD skin is explained by the increase in new collagen deposition and a decrease in solar elastosis</li> <li>A positive correlation of the histological parameter 'extent of atypia' and TP-53 before treatment was noted based on the Pearson correlation test (<math>P = 0.002</math>), which means that higher TP-53 expression was observed with higher amounts of cellular atypia</li> <li>The decrease in severity and extent of keratinocyte atypia associated with a decreased expression of TP-53 suggest a reduced carcinogenic potential of the sun-damaged area</li> </ul>
<b>Clinical</b>			
47	2016	<ul style="list-style-type: none"> <li>Multicentre, non-interventional, cross-sectional study in three dermatology hospital departments and seven private dermatology clinics which enrolled 312 AK patients consecutively during 1 week</li> <li>Field cancerization defined as: mild, moderate or severe, based on the degree to which the surrounding skin presented mottled erythema and pigmentation telangiectasia, sallowness, laxity and a dry texture without fulfilling the definition of an AK lesion</li> <li>AK-affected regions (AKARs) defined as: single (1 AK lesion); scattered solitary lesions (2–4 AK lesions); or multiple lesions (<math>\geq 5</math> AK lesions)</li> </ul>	<ul style="list-style-type: none"> <li>NMSC was previously reported in 51.0% of patients and currently suspected in 9.4% of AK-affected anatomical regions</li> <li>Lesions of AK were located primarily on the face (38.6%), scalp (12.8%) and hands (11.2%)</li> <li>AK commonly presented with multiple lesions (38.6%) and field cancerization (38.5%)</li> <li>The prevalence of severe actinic damage (17.3% vs. 9.6%; <math>P &lt; 0.001</math>) and intake of immunosuppressive medication (29.0% vs. 2.0%) were higher in hospital-treated vs. private practice-treated patients</li> <li>The majority of AK patients in Danish dermatology clinics have a history of skin cancer, and NMSC is suspected in almost 10% of AK-affected regions</li> </ul>
51	1989	<ul style="list-style-type: none"> <li>This clinical study included 808 Caucasian Maryland watermen and examined the prevalence of non-melanoma skin cancer in relation to age and exposure to solar UVB radiation</li> <li>Prevalence of the three major types of non-melanoma skin neoplasms was analysed: SCC, BCC and AK</li> </ul>	<ul style="list-style-type: none"> <li>Average annual exposure to UVB radiation was strongly correlated with the prevalence of SCC, but not with the prevalence of BCC or AK</li> <li>This finding is consistent with dose saturation (plateau in dose–response relationship) for the induction of BCC and AK in humans with high annual exposure to UVB radiation</li> <li>Two small groups of apparently hypersusceptible individuals were present in the population – one group had SCC despite low annual exposure to UVB radiation, and the other group had multiple skin cancers despite average exposure to UVB radiation</li> </ul>
<b>Intraclinical (imaging)</b>			
50	2016	<ul style="list-style-type: none"> <li>Small clinical study including patients (<math>n = 10</math> male and 10 female, aged 58–80 years) affected by AKs on sun-exposed skin</li> <li>160 mg/g MAL was applied (under occlusion) on lesions and perilesional areas for an; extension of <math>44 \text{ cm}^2</math></li> </ul>	<ul style="list-style-type: none"> <li>After 3 months there was a significant 48% reduction in the fluorescence score in patients treated with PDT but no change in fluorescence score in untreated AK patients</li> </ul>

Table 3 Continued

References	Year	Methodology	Key findings
		<ul style="list-style-type: none"> <li>The fluorescence extension and intensity of PpIX emitted from the cells in each of 16 subareas of the 44 cm<sup>2</sup> treatment area were measured and photographed</li> <li>Group 1 (<i>n</i> = 10): treated with two sessions of daylight PDT at baseline and after 1 month</li> <li>Group 2 (<i>n</i> = 10): not treated with PDT and kept the occlusion for 24 h, with the aim to prevent the formation of PpIX</li> </ul>	<ul style="list-style-type: none"> <li>The field of cancerization covered an area greater than the 25 cm<sup>2</sup> that is usually indicated for field-directed treatment</li> <li>A control group of subjects without AK (<i>n</i> = 10), who applied MAL on skin that was not sun-exposed, showed a green fluorescence indicative of skin without actinic damage</li> </ul>
52	2015	<ul style="list-style-type: none"> <li>Case series of eight patients (1 female, 7 male, aged 56–82 years) with multiple clinical and subclinical AK lesions</li> <li>Patients received field-directed 5-FU/SA once daily for ≤6 weeks or until erosion and/or pain/bleeding</li> <li>Study aimed to test the applicability of RCM for non-invasive monitoring of actinic field cancerization and detection of subclinical AK</li> </ul>	<ul style="list-style-type: none"> <li>Complete clearance of clinical/subclinical AKs on various body areas was shown in most patients using RCM</li> <li>RCM allows non-invasive monitoring of treatment response <i>in vivo</i> and permits early detection of subclinical AK, increasing diagnostic accuracy compared with clinical evaluation alone</li> <li>Topical field-directed 5-FU/SA monitored with RCM is a promising management approach for subclinical AKs</li> </ul>
49	2013	<ul style="list-style-type: none"> <li>This pilot study included patients clinically diagnosed with bilateral field cancerization associated with AK and/or photodamage on the face (treatment area not defined)</li> <li>PDT was used for treatment (nano-ALA and MAL), whereas the fluorescence of the corresponding photosensitizer was used to evaluate the time evolution of field cancerization in a quantitative way</li> </ul>	<ul style="list-style-type: none"> <li>The half-life of field cancerization reduction was 43.3 days for nano-ALA and 34.3 days for MAL</li> <li>The efficacy of nano-ALA in treating skin field cancerization is higher than that of MAL</li> <li>Use of nano-ALA represents a feasible routine tool for detection, treatment and follow-up of AK and skin photodamage</li> </ul>
53	2010	<ul style="list-style-type: none"> <li>Small clinical study included 11 otherwise healthy Caucasian volunteers (Fitzpatrick skin phototype II–III; aged 59–77 years), with a clinical diagnosis of AK of the face and scalp and signs of field cancerization</li> <li>Study aimed to test the applicability of RCM for non-invasive monitoring of actinic field cancerization and detection of subclinical AK</li> </ul>	<ul style="list-style-type: none"> <li>RCM detected morphologic features of AK in both clinical and subclinical AK; features were more pronounced in clinical lesions</li> <li>The immunomodulatory response induced by IMIQ 5% cream (used to ‘highlight’ subclinical regions) was visualized by RCM</li> <li>RCM allows non-invasive monitoring of treatment response <i>in vivo</i> and permits early detection of subclinical AK, increasing diagnostic accuracy compared with clinical evaluation alone</li> </ul>
48	2007	<ul style="list-style-type: none"> <li>In this pilot study extension, participants (<i>n</i> = 112; aged 40–86 years) had either normal, sun-damaged or presence of AK on their forearm skin</li> <li>OCT images were obtained at two sun-protected and two sun-exposed sites, with a subsequent biopsy at each site</li> <li>Each site received dermatological evaluation, a histological diagnosis and a solar elastosis score</li> </ul>	<ul style="list-style-type: none"> <li>Significant differences in average attenuation values were found between: <ul style="list-style-type: none"> <li>Skin with minimal vs. skin with severe solar elastosis (<i>P</i> &lt; 0.0001)</li> <li>Undiseased skin vs. AK (<i>P</i> &lt; 0.0001 using a gradient analysis)</li> </ul> </li> <li>Using OCT image features, AK could be distinguished from undiseased skin with 86% sensitivity and 83% specificity</li> </ul>
<b>Infraclinical (imaging) and histological</b>			
37	2016	<ul style="list-style-type: none"> <li>Study included participants (<i>n</i> = 20; mean age 64 years) with skin phototype I and II</li> <li>RCM was performed on two PD sites and one AK lesion within a field of 25 cm<sup>2</sup> on the left dorsal forearm, followed by shave biopsies</li> </ul>	<ul style="list-style-type: none"> <li>Individual corneocytes, stratum corneum disruption, dermal inflammatory cells, increased vascularity/dilated vessels and solar elastosis were all detected in PD sites and AK lesions</li> <li>AK lesions demonstrated parakeratosis, hyperkeratosis, severe keratinocyte pleomorphism and</li> </ul>

Table 3 Continued

References	Year	Methodology	Key findings
		<ul style="list-style-type: none"> <li>Blinded evaluation of the histopathological and RCM images using established parameters in AK were performed retrospectively</li> </ul>	<ul style="list-style-type: none"> <li>architectural disruption, and the presence of epidermal inflammatory cells</li> <li>PD sites demonstrated keratinocyte pleomorphism and architectural disruption but less severe than in AK</li> <li>A small subset of PD sites showed comparable keratinocyte pleomorphism and architectural disruption to AK lesions</li> <li>The viable epidermis showed PD and AK to be part of a disease continuum corresponding to field cancerization</li> <li>Individual corneocytes, stratum corneum disruption, dermal inflammatory cells, increased vascularity/dilated vessels and solar elastosis may be present in PD; whereas, parakeratosis and hyperkeratosis may represent the key to distinguishing AK from PD using RCM</li> </ul>
41	2016	<ul style="list-style-type: none"> <li>Single-arm, open-label, split-face study in males with AK (<math>n = 30</math>; aged 67–93 years) attending a hospital outpatient clinic</li> <li>A suspected AK lesion and the normal-appearing, perilesional skin were imaged and biopsied for histopathological analysis</li> <li>The results were compared with the clinical and a blinded OCT diagnosis</li> </ul>	<ul style="list-style-type: none"> <li>OCT had 100% (28/28) correlation with the clinical diagnosis of AK and detected 73% (16/22) of histopathologically confirmed subclinical lesions from perilesional skin sites</li> <li>OCT was effective for the diagnosis of clinical and subclinical AK; all lesions that were identified as AK by OCT were histologically confirmed as AK or SCC</li> </ul>
40	2015	<ul style="list-style-type: none"> <li>This article describes field cancerization by RCM and the changes induced by the application of 3% diclofenac sodium gel in 2.5% hyaluronic acid</li> <li>Clinical examination, confocal microscopy and histological study of clinically visible lesions and 'normal-appearing' adjacent skin before and after treatment were examined</li> </ul>	<ul style="list-style-type: none"> <li>RCM showed a decrease in scaling (<math>P = 0.001</math>) and atypia of the honeycomb pattern (<math>P = 0.001</math>) after 2 weeks of treatment</li> <li>Changes in parakeratosis, inflammation and dermal collagen remodelling occurred</li> <li>Histology correlated with confocal features in AK and subclinical AK</li> <li>RCM was useful in the evaluation of field cancerization and monitoring of treatment response</li> </ul>
43	2015	<ul style="list-style-type: none"> <li>A histopathological study selected 48 AKs and two control areas (photodamaged and non-photodamaged skin)</li> <li>All areas were documented by RCM and biopsied for histopathology</li> <li>One representative image of the epidermis was selected for RCM and for histopathology and used for side-by-side comparison</li> <li>The assessor chose which of two images displayed more keratinocyte atypia</li> <li>Three evaluations were obtained for RCM and two for histopathology</li> </ul>	<ul style="list-style-type: none"> <li>Good interobserver correlation was obtained for RCM and histopathology grading, with high concordance between RCM and histopathology grading</li> <li>Expert rater scan consistently distinguish different grades of cytological atypia</li> <li>Non-invasive RCM data from <i>in vivo</i> imaging can be graded for keratinocyte atypia, comparable to histopathological grading</li> </ul>
42	2013	<ul style="list-style-type: none"> <li>This study used an objective, non-invasive, real-time hyperspectral imaging system (HIS) <i>in vivo</i> and included 52 clinical AKs in 12 patients</li> <li>In six patients, digital photographs were taken of the naive AKs, and again after MAL-fluorescence diagnosis which was used to teach HIS to find subclinical lesions</li> <li>Biopsies were taken from clinical AKs, healthy-looking skin and several suspected subclinical AKs</li> </ul>	<ul style="list-style-type: none"> <li>HIS detected all clinically visible AKs (<math>n = 52</math>) and numerous subclinical lesions</li> <li>The histopathology of the 33 biopsied lesions were concordant with the HIS results showing either AK (<math>n = 28</math>) or photodamage (<math>n = 5</math>)</li> <li>Of the 28 histopathologically confirmed AKs, 16 were subclinical. A specific diffuse reflectance spectrum of an AK and healthy skin was defined</li> </ul>



Table 3 Continued

References	Year	Methodology	Key findings
		<ul style="list-style-type: none"> <li>In the other six patients, digital and hyperspectral images were taken of the naïve AKs followed by one biopsy/patient</li> </ul>	<ul style="list-style-type: none"> <li>HIS offers a new, non-invasive method for early detection of field cancerization</li> </ul>
44	2007	<ul style="list-style-type: none"> <li>Caucasians (SPT I-III) with <math>\geq 1</math> AK lesion (<math>n = 44</math>) were included in this study</li> <li>Evaluation consisted of clinical examination, RCM and routine histology</li> <li>RCM evaluation parameters included parakeratosis, architectural disarray and keratinocyte pleomorphism</li> <li>44 AKs were included in the final analysis, which involved blinded evaluation by two independent investigators</li> </ul>	<ul style="list-style-type: none"> <li>97.7% of all skin samples were identified as AK using RCM</li> <li>2.3% were incorrectly identified as normal skin by RCM, while routine histology showed features consistent with AK</li> <li>RCM may be a feasible alternative in the diagnosis of AK and aid the differentiation against normal skin, as well as in the detection of subclinical disease</li> </ul>
<b>Histological</b>			
46	2016	<ul style="list-style-type: none"> <li>A study using cutaneous specimens submitted to the dermatopathology service assessed the presence of histologically identified AKs in the tissue immediately surrounding excision specimens of SCCs, BCCs and MMs</li> <li>Field cancerization was demonstrated by the presence of AKs (i.e. field damage with malignant potential) in the skin immediately surrounding cutaneous malignancies</li> </ul>	<ul style="list-style-type: none"> <li>AKs were observed significantly more frequently in SCC specimens [57% (35/61)] than BCC [33% (21/64)] or MM [25% (6/24)] specimens (<math>P = 0.0125</math>)</li> <li>Findings provide additional evidence for field cancerization due to presence of field damage with malignant potential in the skin immediately surrounding cutaneous malignancies</li> </ul>
45	2003	<ul style="list-style-type: none"> <li>A panel of dermatopathologists developed histological criteria (atypia, inflammation, hyperkeratosis, parakeratosis, dyskeratosis, epidermotropism and loss of the granular layer) and diagnostic definitions for the progression of lesions from early AK to AK</li> <li>The criteria were applied to a sample of 335 histological slides from an ongoing chemoprevention study</li> <li>A 10% sample of 35 slides was reread to assess intrarater reliability</li> </ul>	<ul style="list-style-type: none"> <li>Six of the 7 criteria demonstrated high reliability (&gt;85%)</li> <li>The total histological score, calculated using the 6 criteria, was found to significantly differentiate between (blinded) biopsy location (normal, pre-AK, AK and adjacent to SCC) and histological diagnosis (normal, pre-AK or early AK, AK and SCC)</li> <li>The total histological score is a reliable and valid endpoint for assessing the efficacy of agents in skin cancer chemoprevention studies</li> </ul>
<b>Histological and genetic</b>			
38	2004	<ul style="list-style-type: none"> <li>This clinical study included patients with a history of chronic sun exposure and clinical features of AK on sun-exposed surfaces of the upper extremities (<math>n = 51</math>; aged 44–86 years)</li> <li>Computer-assisted image analysis was used to measure nuclear morphometric parameters, p53 expression, and proliferation markers in biopsies taken from AK, sun-exposed and normal skin</li> <li>Histological analysis was performed to confirm diagnosis of normal skin, sun-damaged skin and AK</li> </ul>	<ul style="list-style-type: none"> <li>Nuclear morphometry showed increases in nuclear absorbance and irregularity of nuclear shape and size during progression from normal skin to AK</li> <li>Proliferation markers included argyrophilic nucleolar organizer (AgNOR) number and areas, which were greater in AK than in normal and sun-damaged skin, and Ki67 and p53 staining which were greater in sun-damaged skin compared with normal skin and greatest in AK lesions</li> <li>Progression from normal to sun-damaged skin to AK was accompanied by increasingly abnormal values of nuclear DNA content, size, shape and variability, as well as increases in p53 expression, Ki67 labelling index, and nucleolar organizer size and number</li> <li>Increased proliferation and p53 abnormalities preceded nuclear morphometric alterations in the progression towards AK</li> </ul>

Table 3 Continued

References	Year	Methodology	Key findings
39	1997	<ul style="list-style-type: none"> <li>• Study recruited subjects via advertisements, flyers and recontact from previous skin chemoprevention trials</li> <li>• Biopsies were collected from three groups: 78 subjects with sun damage on forearms, 33 with AK on forearms and 32 with previous SCC</li> <li>• IHC was conducted with anti-p53 antibody; video-prints were quantified manually</li> </ul>	<ul style="list-style-type: none"> <li>• There was a significant difference and a progressively increasing mean p53 labelling index in total epidermis (basal and suprabasal levels) between upper medial arm skin and AK-adjacent, and between AK and AK-adjacent skin; upper medial arm skin was marginally different from non-sun-exposed skin</li> <li>• This pattern was also seen when epidermis was separated into basal and suprabasal levels; epidermal p53 protein expression is associated with histological evidence of chronic sun damage</li> <li>• Clinical AKs appear primarily on sun-exposed areas and sites adjacent to AKs may contain significant histological alterations, suggesting extensive pre-neoplastic alterations in sun-damaged skin</li> </ul>
<b>Molecular/genetic/immunological</b>			
6	2015	<ul style="list-style-type: none"> <li>• Loss or downmodulation of the Notch effector CSL (also known as RBP-1κ) in dermal fibroblasts is sufficient for CAF activation and ensuing keratinocyte-derived tumours</li> <li>• The effects of CSL on senescence- and CAF-determinant genes were investigated in stromal fibroblasts from various organs</li> <li>• Experiments were performed using mouse and human tissue samples</li> </ul>	<ul style="list-style-type: none"> <li>• Stromal fibroblast senescence has been linked to an increased incidence of many cancer types with age</li> <li>• CSL, which halts the activation of CAF, is downmodulated in stromal fibroblasts of premalignant actinic keratosis lesions and <i>in situ</i> squamous cell carcinomas, whereas p53 expression and function are downmodulated only in the latter</li> <li>• Relative to less advanced AK lesions, more widespread stromal alterations around <i>in situ</i> SCCs are likely to occur, as part of expanding cancer fields</li> <li>• LCM analysis of stromal fibroblasts underlying these lesions, as well as flanking skin, showed that CSL levels were consistently reduced relative to an external set of age- and site-matched skin samples from other individuals. Importantly, p53 expression was also downregulated</li> <li>• Concomitant loss of CSL and p53 overcomes fibroblast senescence, enhances expression of CAF effectors and promotes stromal and cancer cell expansion</li> </ul>
8	2015	<ul style="list-style-type: none"> <li>• Immunohistochemistry was used to investigate expression of WRN in formalin-fixed, paraffin wax-embedded tissue specimens of 9 SCC, 15 AK, 11 BD and 11 normal-appearing peripheral tissue samples</li> <li>• Tissue samples were obtained from patients during surgical resections</li> </ul>	<ul style="list-style-type: none"> <li>• WRN has DNA helicase activity and plays a role in the recombination, replication and repair of DNA. Inactivating mutations in WRN lead to genetic instability, the premature onset of age-related diseases and cancer. Upregulation of WRN increases proliferation and survival of cancer cells</li> <li>• WRN expression was significantly increased in BD, AK and SCC compared with normal controls, with the mean WRN staining score being highest in BD, followed by AK and SCC. However, age, sex and sun exposure were not associated with WRN expression</li> <li>• To our knowledge, this is the first report to date investigating the expression of WRN in skin cancers. The overtly high expression of WRN in premalignant lesions and in <i>in situ</i> cancer, with relatively low WRN expression in SCC, may indicate that WRN contributes as a checkpoint for early DNA damage response in skin tumorigenesis</li> </ul>

Table 3 Continued

References	Year	Methodology	Key findings
7	2015	<ul style="list-style-type: none"> <li>Genetic susceptibility to AK was assessed in a genome-wide association study</li> <li>A full body skin examination was performed in 3194 elderly individuals of north-western European origin</li> <li>Physicians graded the number of AK using 4 severity levels (none, 1–3, 4–9 and <math>\geq 10</math>)</li> <li>In multivariable regression analyses, the association between 12 pigmentation-associated SNPs and AK risk was evaluated</li> </ul>	<ul style="list-style-type: none"> <li>IRF4, MC1R and TYR are involved in various kinds of human pigmentation traits including eye, hair and skin colour, tanning ability and freckling as well as with skin cancer, including BCC, SCC and melanoma of the skin</li> <li>IRF4, MC1R and TYR genes were identified as significant risk factors for AK in the north-western European study population</li> <li>After adjustments for skin colour, the strength and significance of the genetic association was hardly affected, indicating that the genetic effect is at least partially independent of skin colour and having a much stronger effect than skin colour on AK risk</li> <li>Overall, the study suggests that <i>IRF4</i>, <i>MC1R</i> and <i>TYR</i> genes likely have pleiotropic effects, a combination of pigmentation and oncogenic functions, resulting in an increased risk of AK</li> </ul>
9	2014	<ul style="list-style-type: none"> <li>This study evaluated tumour angiogenesis and lymphangiogenesis in cancerous and precancerous lesions of the eyelids using immunohistochemical techniques</li> <li>Overall, 147 formalin-fixed, paraffin-embedded samples were included. Most cases (<math>n = 113</math>) were BCC: six were BSC, 10 were SCC and 18 were precancerous lesions such as AK and BD</li> <li>The authors recorded the microvascular density of these tumours using the marker CD-105, a specific antibody against endoglin protein</li> </ul>	<ul style="list-style-type: none"> <li>Neoplastic angiogenesis plays a key role in tumour growth and spread</li> <li>Data analysis showed that the molecular factors that control angiogenesis are expressed in high proportions in the tumours studied and that this expression is positively correlated with tumour microvascular density</li> <li>Furthermore, correlations emerged with the mean diameter of these tumours</li> <li>They also found differences in microvascular density between precancerous and cancerous eyelid lesions</li> </ul>
10	2014	<ul style="list-style-type: none"> <li>Analytical cross-sectional study that included 62 skin tumour samples (<math>n = 49</math> malignant and 13 premalignant)</li> <li>High expression of COX-2 has been demonstrated in various neoplasms</li> <li>F-2 expression was investigated using IHC</li> </ul>	<ul style="list-style-type: none"> <li>COX-2 expression was found in: 16/17 (94%) SCC samples; 28/32 (87.5%) BCC samples; 8/9 (89%) BD samples; and 4/4 (100%) AK samples</li> <li>COX-2 expression (1+ or 2+) was found in normal tissue situated <math>\geq 4</math> mm distant from the involved area in 12/17 (70.6%) SCC samples; 11/32 (34.4%) BCC samples; 6/9 (66.7%) BD samples; and 2/4 (50%) AK samples</li> <li>Alteration of COX-2 was more frequent in and around squamous neoplasia than in other instances</li> <li>COX-2 expression was positive in skin tumours including malignant and premalignant skin lesions; COX-2 could be a molecular target in treating various skin tumours</li> </ul>
11	2013	<ul style="list-style-type: none"> <li>This study assessed CALML3 localization in normal epidermis and in hyperproliferative skin diseases including AK, SCC and BCC and compared CALML3 immunoreactivity with the proliferation marker Ki-67</li> <li>Paraffin-embedded tissue sections were examined by IHC and analysed for localization and expression of CALML3 and Ki-67</li> </ul>	<ul style="list-style-type: none"> <li>Increased CALML3 expression in suprabasal layers is characteristic for differentiating keratinocytes in normal epidermis; and nuclear expression of CALML3 inversely correlates with expression of the proliferation marker Ki-67</li> <li>CALML3 is a useful marker for normal and benign hyperplastic epidermal development, whereas the loss of nuclear CALML3 indicates progression to a proliferative and potentially malignant phenotype</li> </ul>
12	2012	<ul style="list-style-type: none"> <li>MTs can provide cell protection against free radicals that are known to be overexpressed in a variety of cancers</li> </ul>	<ul style="list-style-type: none"> <li>In the epithelium adjacent to SCC, intense MT labelling of the suprabasal layer was detected, suggesting that migrating tumour cells may induce</li> </ul>

Table 3 Continued

References	Year	Methodology	Key findings
		<ul style="list-style-type: none"> <li>This study assessed MT expression using IHC in 73 samples from SCCs, 23 samples from AKs and 20 normal skin samples</li> </ul>	<ul style="list-style-type: none"> <li>MT synthesis in healthy tissue adjacent to the tumour</li> <li>MT may serve as a good marker of proliferation in SCC and AK. MT overexpression in SCC may suggest a potential role of MT in skin carcinogenesis</li> </ul>
13	2012	<ul style="list-style-type: none"> <li>This preclinical study was conducted in mice carrying a mesenchymal-specific deletion of CSL/RBP-J<math>\kappa</math>, a key Notch effector, that exhibit spontaneous multifocal keratinocyte tumours</li> </ul>	<ul style="list-style-type: none"> <li>In human skin samples, stromal fields adjacent to multifocal premalignant actinic keratosis lesions exhibit decreased Notch/CSL signalling and associated molecular changes.</li> <li>Mice carrying a mesenchymal-specific deletion of CSL/RBP-J<math>\kappa</math>, a key Notch effector, exhibit spontaneous multifocal keratinocyte tumours that develop after dermal atrophy and inflammation.</li> <li>CSL-deficient dermal fibroblasts promote increased tumour cell proliferation through upregulation of c-Jun and c-Fos expression and consequently higher levels of diffusible growth factors, inflammatory cytokines and matrix-remodelling enzymes</li> <li>In 6-month-old mice, tumours exhibited features of malignant SCCs, with aberrant keratinization, pronounced dysplasia and inflammatory infiltration, and invasion of epithelial islands or spindle-shaped cells into dermis and connective tissue</li> </ul>
21	2009	<ul style="list-style-type: none"> <li>Expression levels of the genes BRAF and RKIP were examined in 16 AKs and 12 SCCs by RT-qPCR</li> <li>A novel allele-specific qPCR method, in combination with direct DNA sequencing, was performed to inspect the frequency of the V600E mutation in exon 15, as well as to examine the mutation status of the gene within exon 11</li> </ul>	<ul style="list-style-type: none"> <li>BRAF and RKIP are involved in the regulation of the RAF-1/MEK/ERK cell survival pathway. BRAF mutations play a role in melanoma and BCC and RKIP is downregulated in malignant melanoma and not expressed in melanoma metastasis.</li> <li>Both BRAF and RKIP expression levels exhibit a decrease from normal skin tissue and AK, progressing to SCC</li> <li>The decrease in RKIP mRNA levels in SCC suggests one novel mechanism in the deregulation of the BRAF signalling pathway</li> <li>The results further indicate that BRAF does not appear to be frequently mutated either in precancerous skin lesions (AK) or in non-melanoma skin tumours (SCC)</li> </ul>
23	2008	<ul style="list-style-type: none"> <li>This study characterized the four betapapillomavirus isolates [HPV-107, HPV-110 and HPV-111 and FA75(KI88-03)] present in skin cancers and investigated their clinical significance by assaying their prevalence and viral load among patients with skin lesions (<math>n = 263</math>)</li> <li>Used real-time PCR assays of skin biopsies (stripped lesions and healthy skin biopsy)</li> <li>Healthy skin biopsy taken 10–15 cm from lesion, or proximally to the ear, depending on the location of the lesion</li> </ul>	<ul style="list-style-type: none"> <li>Seventeen patients (6.5%) harboured <math>\geq 1</math> HPV types in their lesion, vs. seven patients (2.7%) in healthy skin</li> <li>Overall, the four viruses were more common in AK than in healthy skin (odds ratio 5.0, 95% CI 1.4–17.5), but the prevalence and viral loads were low</li> <li>The role of these four HPV types in carcinogenesis remains unclear</li> </ul>
34	2013	<ul style="list-style-type: none"> <li>This study aimed to identify pathways and genomic alterations that are consistently involved in the formation of SCCs and AKs</li> <li>RNA and DNA were isolated from SCC, AK and normal (unexposed) epidermis from each of 13 OTRs</li> </ul>	<ul style="list-style-type: none"> <li>Genetic sequencing of SCC and AK in OTR patients showing early and late events on malignant evolution</li> <li>Vast differences in gene expression profiles were identified between SCC, AK and normal (unexposed) epidermis from immunosuppressed OTRs,</li> </ul>

Table 3 Continued

References	Year	Methodology	Key findings
		<ul style="list-style-type: none"> <li>• Samples were subjected to genomewide expression analysis and genome SNP analysis</li> <li>• mRNA expression results were verified by quantitative PCR</li> </ul>	<ul style="list-style-type: none"> <li>• with several thousand genes found to be differentially expressed</li> <li>• Moreover, several pathways activated in SCCs were already activated in AKs, confirming the assumption that AKs are the precursor lesions of SCC</li> </ul>
15	2011	<ul style="list-style-type: none"> <li>• This immunohistochemical analysis studied the role of PTEN following UVB-induced DNA damage</li> <li>• Experiments were performed using mouse and human tissue samples</li> <li>• Formalin-fixed, paraffin-embedded human tissue blocks were obtained from a tissue bank</li> </ul>	<ul style="list-style-type: none"> <li>• PTEN is a critical tumour suppressor</li> <li>• There was a reduction in PTEN levels in human premalignant AK and malignant SCC, supporting a key role for PTEN in human skin cancer formation and progression</li> <li>• PTEN levels were reduced (score 0 or 1) in 92% of AK (23/25) and 94% of invasive SCC lesions (26/28) as compared to none of the normal skin samples (0/16)</li> <li>• PTEN downregulation was significantly associated with increasing sun damage</li> </ul>
14	2011	<ul style="list-style-type: none"> <li>• This study examined differential gene expression among normal skin, AK and SCC</li> <li>• Experiments were performed using formalin-fixed and paraffin-embedded blocks of skin: 5 normal (pooled), 6 from AK and 6 from SCC</li> <li>• RNA was extracted and amplified, and gene expression was analysed using DNA microarray</li> </ul>	<ul style="list-style-type: none"> <li>• Significant differential gene expression (&gt;2-fold change, <math>P &lt; 0.05</math>) was seen with 382 differentially expressed genes between SCC and normal skin, 423 differentially expressed genes between AKs and normal skin and 9 differentially expressed genes between AK and SCC</li> <li>• Relatively few genes were differentially expressed between AK and SCC. The detection of these genes using DNA microarray may assist in the differentiation of AK and SCC. These genes may also potentially serve as biomarkers for prognosis or therapeutic targets in the future</li> </ul>
17	2011	<ul style="list-style-type: none"> <li>• This study compared the repetitive DNA patterns of human AK and SCC to identify genetic alterations that are associated with malignant transformation</li> <li>• Eight AK and 24 SCC, which were pair-matched to adjacent skin tissues and/or leucocytes, were evaluated</li> <li>• The presence of microsatellite instability and the LOH in chromosomes 6 and 9 were investigated using nine PCR primer pairs</li> <li>• Random Amplified Polymorphic DNA patterns were also assessed using eight primers</li> </ul>	<ul style="list-style-type: none"> <li>• Microsatellite instability was detected in two of the eight patients with AK; the AK samples did not exhibit an LOH</li> <li>• The SCCs presented four LOHs and eight microsatellite instabilities</li> <li>• Total alterations in D6S251 microsatellites were significantly greater in the SCC (I + II + III) compared with the AK lesions (<math>P = 0.0398</math>)</li> <li>• The altered random amplified polymorphic DNA ranged from 70% AKs, 76% SCC-I and 90% SCC-II, to 100% SCC-III</li> <li>• The alterations that were observed in the repetitive DNA patterns suggest a spectrum of malignant progression from AKs to SCCs</li> </ul>
16	2011	<ul style="list-style-type: none"> <li>• This study investigated pATM expression patterns in cultured keratinocytes, skin explants and a spectrum of premalignant to malignant keratinocyte skin lesions using immunohistochemical techniques</li> <li>• Human AK, carcinoma <i>in situ</i> and SCC tissues were obtained from tissue banks</li> </ul>	<ul style="list-style-type: none"> <li>• In several tumour types, early precursor lesions show evidence of an activated DNA damage response, with a diminishing response in more advanced cancers. ATM is an important marker of DNA damage, which becomes phosphorylated (pATM) upon activation</li> <li>• pATM expression in precancerous keratinocyte lesions was greater and predominantly nuclear compared with invasive lesions, where pATM was weaker and predominantly cytoplasmic</li> <li>• In AK lesions, levels of pATM were mainly equal in the cytoplasm and nucleus (68.8%). pATM was higher in the cytoplasm compared to the nucleus in</li> </ul>

Table 3 Continued

References	Year	Methodology	Key findings
			<p>6.3% of lesions and lower in the cytoplasm than in the nucleus in 25.0% of lesions</p> <ul style="list-style-type: none"> <li>AKs show predominantly heavy nuclear expression of pATM which becomes progressively less nuclear and more cytoplasmic as the lesion evolves to more advanced SCC</li> <li>Early, pre-invasive lesions (such as AK) express pATM to a significantly greater extent than SCCs</li> <li>DNA damage response is active in pre-invasive lesions (such as AK), but this mechanism is overridden at a later point in the evolution of cutaneous SCC</li> </ul>
20	2010	<ul style="list-style-type: none"> <li>This was an analysis of the GSTM1 and T1 genotype of 33 participants with <math>\geq 3</math> solar keratoses and of 150 controls, before and after stratification based on smoking habits, sun exposure and immunosuppression</li> <li>Participants were from two regions of southern Italy</li> </ul>	<ul style="list-style-type: none"> <li>GSTs are enzymes involved in the defensive mechanisms against oxidative stress. Polymorphisms of GSTs have been linked with skin cancer, their association with AK has not yet been established</li> <li>Patients with GSTT1 (but not GSTM1) null phenotype were more likely to have AK in an Italian population (<math>P &lt; 0.03</math> for the association with GSTT1)</li> <li>This finding was in contrast with one study in an Australian population, where the opposite was true. The differences were attributed to ethnicity differences between the populations</li> </ul>
18	2010	<ul style="list-style-type: none"> <li>This observational study identified and compared the gene expression profiles of AK and SCC</li> <li>Skin biopsy specimens were taken from 16 patients with SCC</li> <li>The specimens included 14 normal non-sun-exposed skin samples, 14 normal sun-exposed skin samples, 5 AKs and 15 cutaneous SCCs</li> <li>Order-restricted inference was used to analyse the samples</li> <li>Prediction analysis of microarrays was performed for gene selection</li> </ul>	<ul style="list-style-type: none"> <li>Eighty-nine unique genes that most likely contribute to the molecular evolution of SCC were identified</li> <li>The model used was cross-validated using data from a separate study and clearly distinguishes between skin tumours (AK and SCC) and normal skin independent of sun exposure</li> <li>Genes that were upregulated in AK and SCC were downregulated in normal skin, and genes that were downregulated in AK and SCC were upregulated in normal skin</li> <li>AK and SCC are genetically related, and AK is a precursor lesion to SCC</li> </ul>
19	2010	<ul style="list-style-type: none"> <li>This study evaluated the effect of UVB on PTEN expression and its underlying molecular mechanisms</li> <li>Experiments were conducted using primary human keratinocytes, human HaCaT keratinocytes and mouse skin</li> <li>Human tissues were from formalin-fixed paraffin-embedded blocks in replicates from three individuals diagnosed with AK or without skin tumours. The PTEN levels were evaluated in basal keratinocytes of interfollicular epidermis</li> </ul>	<ul style="list-style-type: none"> <li>PTEN is a critical tumour suppressor</li> <li>UVB downregulates PTEN in primary human keratinocytes, human HaCaT keratinocytes and mouse skin. PTEN levels are reduced in human AK compared with normal skin</li> <li>UVB downregulates PTEN in apoptotic cells through degradation by active caspases, and in surviving cells through caspase-independent but ERK/Akt-dependent mechanisms</li> <li>The ERK/Akt/PTEN axis may form a positive feedback loop following UVB irradiation</li> </ul>
22	2009	<ul style="list-style-type: none"> <li>This study used a PCR and direct sequencing approach to assess mtDNA D-loop mutations in two precursors, a rare keratoacanthoma and NMSC (all tumours not related to smoking)</li> <li>The status of the tumour suppressor protein p53 was assessed using immunohistochemistry, to evaluate a potential association with the presence of mtDNA mutations</li> </ul>	<ul style="list-style-type: none"> <li>mtDNA D-loop mutations have been observed in SCC and basal cell carcinoma of NMSC. However, they have not been examined in SCC precursor lesions (BD or AK)</li> <li>D-loop mutations were present in 9/36 tumours (25%)</li> </ul>

Table 3 Continued

References	Year	Methodology	Key findings
			<ul style="list-style-type: none"> <li>p53 mutations were present in 50% and 90% of AK and SCC respectively but were not associated with the presence of mtDNA mutations</li> <li>Alteration in p53 status is unlikely to contribute to mtDNA mutagenesis</li> </ul>
24	2008	<ul style="list-style-type: none"> <li>Mutational analysis on exons 1a, 1b and 2 of the CDKN2A locus and exon 1 of the CDKN2B locus as well as allelic imbalance was performed in 26 AK specimens</li> <li>Expression levels of the genes p14(ARF), p15 (INK4b), p16(INK4a) and p53 were examined in 16 AKs and 12 SCCs by real-time PCR</li> </ul>	<ul style="list-style-type: none"> <li>The deregulation of the expression profiles of the CDKN2A, CDKN2B and p53 genes may, independently of mutations and LOH at 9p21, play a significant role in AK and progression of AK to SCC</li> <li>Apart from mutations and LOH/MSI at 9p21, the deregulation of the expression profile of the TSGs may play a significant role in AK appearance and progression of AK to SCC</li> </ul>
25	2007	<ul style="list-style-type: none"> <li>This study compared gene expression changes in AK lesions and in sun-exposed non-lesional skin and assessed the effect of the Toll-like receptor-7 agonist, imiquimod (5% cream) on these changes</li> <li>Male subjects (<math>n = 17</math>) with <math>\geq 5</math> AK lesions on their scalp applied vehicle or imiquimod three times a week for 4 weeks</li> <li>Gene expression analysis was performed on skin biopsies taken before and after treatment using an Affymetrix<sup>®</sup> oligonucleotide array</li> </ul>	<ul style="list-style-type: none"> <li>Forty-nine genes that were suppressed or expressed normally in sun-exposed, non-lesional skin were significantly more suppressed in AK lesions</li> <li>Ninety-one genes that were increased or expressed normally in sun-exposed, non-lesional skin were further increased in expression in AK lesions</li> <li>The findings suggest that chronic UV exposure leads to suppression of the cutaneous immune response, perhaps partly by the induction of tolerance to dysplastic cells</li> <li>The gene expression changes showed abnormalities in sun-exposed, non-lesional skin that were similar in nature but less pronounced than abnormalities seen in AK</li> </ul>
26	2007	<ul style="list-style-type: none"> <li>This study examined the link between connective and UV-damaged epithelial tissues in AK</li> <li>AK cases (<math>n = 30</math>) were divided into three grades according to the proportion of dermal elastosis and immunohistochemically analysed for the expression of Ki67, p53, p63, bcl-2, E-cadherin, 34-betaE12 and CD99</li> </ul>	<ul style="list-style-type: none"> <li>The increase in the solar elastosis grade was associated with an increase in positive cell numbers for all analysed markers</li> <li>These results support the hypothesis that a gradual evolution from slightly to severely sun-damaged connective tissue is related to augmented epithelial expression of apoptotic, cell proliferation and structural proteins</li> <li>The solar elastosis grade could be a useful morphologic marker in the assessment of neoplastic changes in sun-damaged skin</li> </ul>
27	2006	<ul style="list-style-type: none"> <li>This study explored p53 and proliferating cell nuclear antigen expression and polyamine content as biomarkers in skin cancer chemoprevention trials</li> <li>Biopsies were collected from individuals with sun damage on forearms (<math>n = 78</math>), AK on forearms (<math>n = 33</math>) or previous SCC (<math>n = 32</math>)</li> <li>Participants with sun damage were randomized to sunscreen or no sunscreen</li> </ul>	<ul style="list-style-type: none"> <li>p53 expression and polyamines (involved in cell proliferation, survival, signalling and apoptosis) in skin were elevated in early stages of skin tumorigenesis and were not affected by sunscreen</li> <li>There was a stepwise and significant increase in p53 expression from biopsies without characteristics of AK compared with early AK (<math>P = 0.02</math>) and AK (<math>P = 0.0006</math>)</li> <li>Biomarkers like p53 expression could be useful as predictive markers of future skin cancer risk</li> </ul>
29	2003	<ul style="list-style-type: none"> <li>A total of 33 cases was examined for evidence of E-cadherin promoter hypermethylation: spongiotic dermatitis as non-neoplastic skin control (<math>n = 9</math>), AK (<math>n = 9</math>), SCC <i>in situ</i> (<math>n = 8</math>) and invasive SCC (<math>n = 7</math>)</li> </ul>	<ul style="list-style-type: none"> <li>Silencing of e-cadherin is linked to increased potential for tumour invasiveness and distant metastasis This study reports silencing of e-cadherin in dysplastic (actinic keratosis) carcinoma and invasive carcinoma (~58% of cases)</li> <li>Two non-neoplastic skin controls were also positive for e-cadherin silencing. This finding may indicate</li> </ul>

Table 3 Continued

References	Year	Methodology	Key findings
			<p>the earliest stage of squamous carcinogenesis in these two individuals</p> <ul style="list-style-type: none"> <li>E-cadherin promoter hypermethylation occurs frequently and may represent an important mechanism of E-cadherin inactivation in cutaneous preneoplastic and neoplastic lesions</li> <li>The frequencies of E-cadherin promoter hypermethylation appear to be correlated with more advanced stage of squamous carcinogenesis in skin</li> </ul>
28	2003	<ul style="list-style-type: none"> <li>A total of 33 cases were examined for evidence of death-associated protein kinase and p16 hypermethylation: spongiotic dermatitis as non-neoplastic skin control (<math>n = 9</math>), AK (<math>n = 9</math>), SCC <i>in situ</i> (<math>n = 8</math>) and invasive SCC (<math>n = 7</math>)</li> </ul>	<ul style="list-style-type: none"> <li>Promoter methylation (i.e. inactivation) of these genes is found in various human cancers, including SCC of the head and neck</li> <li>Death-associated protein kinase promoter methylation was detected in one case of squamous cell carcinoma <i>in situ</i> and one case of non-neoplastic skin control but none of the cases of invasive SCC or AK</li> <li>P16 promoter methylation was detected in one case of invasive squamous cell carcinoma and one case of non-neoplastic skin control but none of the cases of SCC <i>in situ</i> or AK</li> <li>Promoter hypermethylation of the death-associated protein kinase and p16 genes does not appear to play an important role in the development of cutaneous SCC</li> </ul>
30	2002	<ul style="list-style-type: none"> <li>Five lesions of the skin, three AKs and two AK + CIS (CIS = squamous cell carcinoma <i>in situ</i>), from three patients were short-term cultured and analysed cytogenetically</li> </ul>	<ul style="list-style-type: none"> <li>Structural rearrangements involving chromosomal band 3p13 and the centromeric region of chromosome 3 in AK were shown to be common features for many types of malignant tumours, including skin SCC, suggesting that these changes are early genetic events associated with malignant transformation</li> </ul>
31	1999	<ul style="list-style-type: none"> <li>Skin lesions from cases of BCC (<math>n = 21</math>), SCC (<math>n = 26</math>), BD (<math>n = 10</math>) and hypertrophic AK (<math>n = 9</math>) were cultured and analysed for survivin expression using a GFP marker plasmid</li> </ul>	<ul style="list-style-type: none"> <li>Apoptosis inhibitor survivin is expressed in many human cancers, potentially contributing to disease progression</li> <li>By immunohistochemistry, survivin was expressed in 81% (17 of 21) of BCC of both nodular and morpheaform subtypes, and in 92% (24 of 26) of SCC.</li> <li>Survivin was also expressed in 19 premalignant lesions of Bowen's disease (SCC <i>in situ</i>) and hypertrophic AK, suggesting that its appearance occurs early during keratinocyte transformation</li> <li>Apoptosis inhibition by survivin may participate in the onset and progression of both BCC and SCC</li> </ul>
32	1994	<ul style="list-style-type: none"> <li>Authors investigated the tumour suppressor gene p53 in precancerous AK lesions and malignant SCCs using polymerase chain reaction and single-strand conformation polymorphism analysis (PCR-SSCP) techniques</li> </ul>	<ul style="list-style-type: none"> <li>Mutations in the tumour suppressor gene p53 were present in 53% of AK lesions and 69% of SCCs, suggesting that p53 mutations may be involved in the malignant transformation of AKs to SCCs</li> </ul>
33	1990	<ul style="list-style-type: none"> <li>To evaluate the role of HPV in the development of premalignant lesions and cancers of the skin, 314 biopsies obtained from 227 patients with benign neoplasms, premalignant lesions and cancers of the</li> </ul>	<ul style="list-style-type: none"> <li>HPV-DNA is rarely detected in skin malignancies (including AK), suggesting that HPV plays a minor role (if any) in skin carcinogenesis in the general population</li> </ul>



Table 3 Continued

References	Year	Methodology	Key findings
		skin and from 25 patients with SCC of the lip were analysed by Southern blot hybridization <ul style="list-style-type: none"> <li>• DNA probes specific for various cutaneous and genital HPV types were used in hybridizations conducted under non-stringent or stringent conditions</li> </ul>	

AK, actinic keratosis; Akt, protein kinase B; ARF, alternative reading frame; BCC, basal cell carcinoma; BD, Bowen's disease; BRAF, B-Raf protein; BSC, basosquamous cell carcinomas; CAF, cancer-associated fibroblasts; CALML3, calmodulin Like 3; CI, confidence interval; CDKN, cyclin-dependent kinase Inhibitor; COX-2, cyclooxygenase-2; D-loop, displacement loop; DNA, deoxyribonucleic acid; ERK, extracellular signal-regulated kinases; FU, 5-fluorouracil; GFP, green fluorescent protein; GST, glutathione S-transferase; GSTM1, glutathione S-transferase Mu 1; HIS, hyperspectral imaging systems; HPV, human papillomavirus; IHC, immunohistochemistry; IMIQ, imiquimod; IRF4, interferon regulatory factor 4; LCM, laser capture microdissection; LOH, loss of heterozygosity; MAL, methyl aminolevulinate; MEK, mitogen-activated protein kinase kinase; MM, malignant melanoma MMP-1, metalloproteinase-1; MT, metallothioneins; mRNA, messenger RNA; mtDNA, mitochondrial DNA; nano-ALA, 5-aminolevulinic acid; NMSC, non-melanoma skin cancer; OCT, optical coherence tomography; OR, odds ratio; OTR, organ transplant recipient; pATM, phosphorylated ataxia-telangiectasia mutated; PBC, palisading basal cells; PCR, polymerase chain reaction; PD, photodamaged; PDT, photodynamic therapy; PpIX, protoporphyrin IX; PTEN, phosphatase and tensin homolog; qPCR, quantitative polymerase chain reaction; RCM, reflectance confocal microscopy; RKIP, Raf kinase inhibitor protein; SA, salicylic acid; SCC, squamous cell carcinoma; SNP, single nucleotide polymorphism; SSCP, single-strand conformation polymorphism; Tn-C, tenascin-C; TP-53, tumour protein p53; TSG, tumour suppressor gene; TYR, tyrosinase; UV, ultraviolet; UVB, ultraviolet B; WRN, Werner protein.

Similarly, altered expression of some of the genes involved in AK development is observed in morphologically apparently normal sun-exposed skin, AK lesions and SCC.<sup>37</sup> This has often been described as a 'disease continuum' from photodamaged skin to AK to SCC.<sup>37</sup> In the authors' opinion, photodamaged skin, AK lesions and SCC can be differentiated from each other and, therefore, the term 'disease continuum' is not entirely accurate. It would be more accurate to talk about an association between the initial molecular changes in individual cells and the development of AK or SCC. The terminology disease continuum has also been used in studies where similar histological changes have been observed in AK lesions and adjacent skin.<sup>46</sup> Again, although some changes are common to both, they can be clearly differentiated. Therefore, it is inaccurate to talk about an association between these changes and the development of AK or SCC.

In addition, there is currently very little evidence to inform a clinical definition of the AK field. Some of the publications identify various signs of sun damage often seen concomitantly with AK lesions.<sup>36,47</sup> However, a clear definition and consensus on what constitutes visible sun damage relevant to define the AK field is lacking.<sup>56</sup>

Based on the above, critically appraised summary statements defining the AK field are summarized in Table 2 ('after critical appraisal' column).

Thus, the majority of publications have reported on molecular/genetic/immunological changes that take place in UVB-exposed skin that can lead to carcinogenesis. These provide a basic understanding on how UVB radiation affects skin and the role it has in the pathology of AK, SCC and other skin cancers, a knowledge that can be useful to identify new treatment targets. However, this information has very limited applicability in clinical practice, highlighting the existence of a clinical gap.

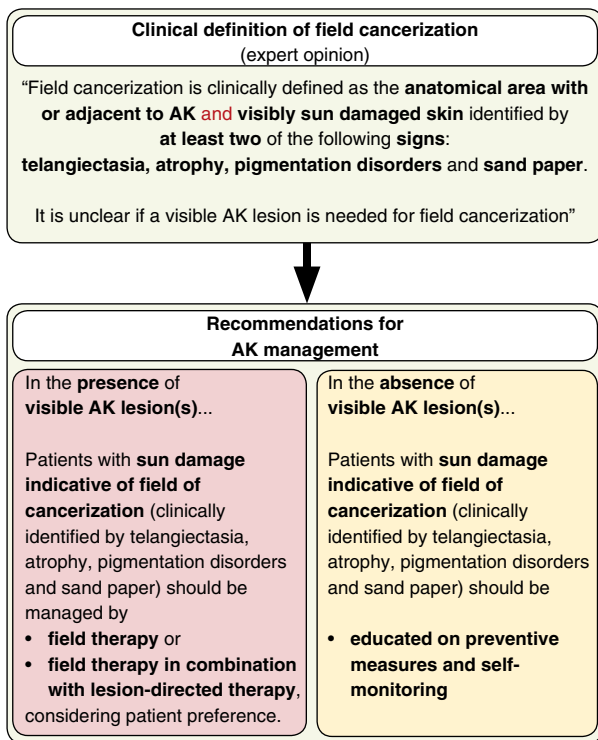
### Expert panel clinical opinion

This literature review has highlighted a very important gap of evidence limiting the development of a clinical definition of the AK field, which is essential to support AK diagnosis and treatment decisions.<sup>5</sup>

Until recently, the Olsen scale was the only clinical scale used to assess AK severity.<sup>57</sup> This scale, which grades severity/thickness of individual AK lesions in isolation, combined with lesion counts within a relatively small area, has been employed in clinical trials of field therapies to assess extent of disease severity and treatment effectiveness.<sup>57–59</sup> However, individual lesion counts are associated with poor reproducibility.<sup>60–62</sup> Therefore, while assessment of disease severity based on the Olsen scale and lesion counts is practical, it is unreliable and inconsistent for routine application.<sup>56</sup>

Current treatment algorithms and guidelines rely on the Olsen scale and/or lesion counts for assessing disease extent and providing treatment recommendations,<sup>63–65</sup> and such guidelines are therefore also limited for clinical practice. In clinical practice, dermatologists need to assess the severity of AK in the entire area affected to make a fully informed decision on optimum disease management options.<sup>56</sup> The need for global assessment of AK severity, beyond individual lesion counts, has been recognized recently by several working groups, and two novel AK severity scales have been published.<sup>56,66</sup> To grade disease severity, these scales take into account the entire area affected by visible AKs.<sup>56,66</sup> Moreover, the importance of including visible signs of sun damage in the AK field to assess disease severity has also been recognized,<sup>56</sup> highlighting the need for a clear definition of sun damage relevant in the context of AK, which is currently lacking.

To address this need, we have proposed a clinical definition of field cancerization based on the results of a retrospective audit



**Figure 3** Clinical definition of field cancerization and management recommendations based on expert opinion.

to identify visible signs of sun damage that are reliable indicators of field cancerization and expert opinion (Fig. 3, top). We have also proposed recommendations for AK management based on this definition (Fig. 3, bottom). Prospective studies will be needed to confirm these signs as reliable clinical indicators of field cancerization.

## Conclusion

There is a need for a clear definition of the AK field to support AK diagnosis and treatment decisions. Here, we have reviewed a large body of existing evidence and summarized the key sun-induced molecular/genetic/immunological and histological changes that take place in the AK field. However, there was a lack of evidence in the literature to inform a clinical definition. A clinical definition of the AK field based on reliable clinical indicators of sun damage, as determined by retrospective audit of AK patients and expert opinion, has been proposed.

## Acknowledgements

The authors acknowledge editorial assistance from Leading Edge (part of Lucid Group) funded by LEO Pharma, for developing a first draft from an agreed outline, collating and incorporating comments from all authors during the reviewing process and copy-editing the final draft for submission.

## References

- Dreno B, Amici JM, Basset-Seguín N *et al.* Management of actinic keratosis: a practical report and treatment algorithm from AKTeam expert clinicians. *J Eur Acad Dermatol Venereol* 2014; **28**: 1141–1149.
- Malvey J. A new vision of actinic keratosis beyond visible clinical lesions. *J Eur Acad Dermatol Venereol* 2015; **29**(Suppl 1): 3–8.
- Wheller L, Soyer HP. Clinical features of actinic keratoses and early squamous cell carcinoma. *Curr Probl Dermatol* 2015; **46**: 58–63.
- Braakhuis BJ, Tabor MP, Kummer JA, Leemans CR, Brakenhoff RH. A genetic explanation of Slaughter's concept of field cancerization: evidence and clinical implications. *Cancer Res* 2003; **63**: 1727–1730.
- Cerio R, Dirschka T, Dreno B *et al.* Actinic keratosis, a chronic, progressive disease: understanding clinical gaps to optimise patient management. *Acta Derm Venereol* 2017; **97**: 997–998.
- Procopio MG, Laszlo C, Al Labban D *et al.* Combined CSL and p53 downregulation promotes cancer-associated fibroblast activation. *Nat Cell Biol* 2015; **17**: 1193–1204.
- Jacobs LC, Liu F, Pardo LM *et al.* IRF4, MC1R and TYR genes are risk factors for actinic keratosis independent of skin color. *Hum Mol Genet* 2015; **24**: 3296–3303.
- Cha HJ, Lee DB, Jung HN, Choi YS, Suh HS. Investigation of Werner protein as an early DNA damage response in actinic keratosis, Bowen disease and squamous cell carcinoma. *Clin Exp Dermatol* 2015; **40**: 564–569.
- Tzoutzos K, Batistatou A, Kitsos G, Liasko R, Stefanou D. Study of microvascular density and expression of vascular endothelial growth factor and its receptors in cancerous and precancerous lesions of the eyelids. *Anticancer Res* 2014; **34**: 4977–4983.
- Amirnia M, Babaie-Ghazani A, Fakhrjou A *et al.* Immunohistochemical study of cyclooxygenase-2 in skin tumors. *J Dermatolog Treat* 2014; **25**: 380–387.
- Bennett RD, Pittelkow MR, Strehler EE. Immunolocalization of the tumor-sensitive calmodulin-like protein CALML3 in normal human skin and hyperproliferative skin disorders. *PLoS One* 2013; **8**: e62347.
- Zamirska A, Matusiak L, Dziegiel P, Szybejko-Machaj G, Szepietowski JC. Expression of metallothioneins in cutaneous squamous cell carcinoma and actinic keratosis. *Pathol Oncol Res* 2012; **18**: 849–855.
- Hu B, Castillo E, Harewood L *et al.* Multifocal epithelial tumors and field cancerization from loss of mesenchymal CSL signaling. *Cell* 2012; **149**: 1207–1220.
- Ra SH, Li X, Binder S. Molecular discrimination of cutaneous squamous cell carcinoma from actinic keratosis and normal skin. *Mod Pathol* 2011; **24**: 963–973.
- Ming M, Feng L, Shea CR *et al.* PTEN positively regulates UVB-induced DNA damage repair. *Cancer Res* 2011; **71**: 5287–5295.
- Ismail F, Ikram M, Purdie K, Harwood C, Leigh I, Storey A. Cutaneous squamous cell carcinoma (SCC) and the DNA damage response: pATM expression patterns in pre-malignant and malignant keratinocyte skin lesions. *PLoS One* 2011; **6**: e21271.
- Cabral LS, Festa Neto C, Sanches JA Jr, Ruiz IR. Genomic instability in human actinic keratosis and squamous cell carcinoma. *Clinics (Sao Paulo)* 2011; **66**: 523–528.
- Padilla RS, Sebastian S, Jiang Z, Nindl I, Larson R. Gene expression patterns of normal human skin, actinic keratosis, and squamous cell carcinoma: a spectrum of disease progression. *Arch Dermatol* 2010; **146**: 288–293.
- Ming M, Han W, Maddox J *et al.* UVB-induced ERK/AKT-dependent PTEN suppression promotes survival of epidermal keratinocytes. *Oncogene* 2010; **29**: 492–502.
- Guarneri F, Asmundo A, Sapienza D, Gazzola A, Cannavo SP. Polymorphism of glutathione S-transferases M1 and T1: susceptibility to solar keratoses in an Italian population. *Clin Exp Dermatol* 2010; **35**: 771–775.
- Zaravinos A, Kanellou P, Baritaki S, Bonavida B, Spandidos DA. BRAF and RKIP are significantly decreased in cutaneous squamous cell carcinoma. *Cell Cycle* 2009; **8**: 1402–1408.

- 22 Prior SL, Griffiths AP, Lewis PD. A study of mitochondrial DNA D-loop mutations and p53 status in nonmelanoma skin cancer. *Br J Dermatol* 2009; **161**: 1067–1071.
- 23 Vasiljevic N, Hazard K, Dillner J, Forslund O. Four novel human betapapillomaviruses of species 2 preferentially found in actinic keratosis. *J Gen Virol* 2008; **89**: 2467–2474.
- 24 Kanellou P, Zaravinos A, Zioga M et al. Genomic instability, mutations and expression analysis of the tumour suppressor genes p14(ARF), p15 (INK4b), p16(INK4a) and p53 in actinic keratosis. *Cancer Lett* 2008; **264**: 145–161.
- 25 Torres A, Storey L, Anders M et al. Microarray analysis of aberrant gene expression in actinic keratosis: effect of the Toll-like receptor-7 agonist imiquimod. *Br J Dermatol* 2007; **157**: 1132–1147.
- 26 da Silva TA, Coelho G, Lorenzetti Bocca A, Figueiredo Cavalcante Neto F. Expression of apoptotic, cell proliferation regulatory, and structural proteins in actinic keratosis and their association with dermal elastosis. *J Cutan Pathol* 2007; **34**: 315–323.
- 27 Einspahr JG, Xu MJ, Warneke J et al. Reproducibility and expression of skin biomarkers in sun-damaged skin and actinic keratoses. *Cancer Epidemiol Biomarkers Prev* 2006; **15**: 1841–1848.
- 28 Tyler LN, Ai L, Zuo C, Fan CY, Smoller BR. Analysis of promoter hypermethylation of death-associated protein kinase and p16 tumor suppressor genes in actinic keratoses and squamous cell carcinomas of the skin. *Mod Pathol* 2003; **16**: 660–664.
- 29 Chiles MC, Ai L, Zuo C, Fan CY, Smoller BR. E-cadherin promoter hypermethylation in preneoplastic and neoplastic skin lesions. *Mod Pathol* 2003; **16**: 1014–1018.
- 30 Jin Y, Jin C, Salemark L, Wennerberg J, Persson B, Jonsson N. Clonal chromosome abnormalities in premalignant lesions of the skin. *Cancer Genet Cytogenet* 2002; **136**: 48–52.
- 31 Grossman D, McNiff JM, Li F, Altieri DC. Expression of the apoptosis inhibitor, survivin, in nonmelanoma skin cancer and gene targeting in a keratinocyte cell line. *Lab Invest* 1999; **79**: 1121–1126.
- 32 Nelson MA, Einspahr JG, Alberts DS et al. Analysis of the p53 gene in human precancerous actinic keratosis lesions and squamous cell cancers. *Cancer Lett* 1994; **85**: 23–29.
- 33 Kawashima M, Favre M, Obalek S, Jablonska S, Orth G. Premalignant lesions and cancers of the skin in the general population: evaluation of the role of human papillomaviruses. *J Invest Dermatol* 1990; **95**: 537–542.
- 34 Hameetman L, Commandeur S, Bavinck JN et al. Molecular profiling of cutaneous squamous cell carcinomas and actinic keratoses from organ transplant recipients. *BMC Cancer* 2013; **13**: 58.
- 35 Berman B, Cockerell CJ. Pathobiology of actinic keratosis: ultraviolet-dependent keratinocyte proliferation. *J Am Acad Dermatol* 2013; **68**: S10–S19.
- 36 Szeimies RM, Torezan L, Niwa A et al. Clinical, histopathological and immunohistochemical assessment of human skin field cancerization before and after photodynamic therapy. *Br J Dermatol* 2012; **167**: 150–159.
- 37 Tan JM, Lambie D, Sinnya S et al. Histopathology and reflectance confocal microscopy features of photodamaged skin and actinic keratosis. *J Eur Acad Dermatol Venereol* 2016; **30**: 1901–1911.
- 38 Carpenter PM, Linden KG, McLaren CE et al. Nuclear morphometry and molecular biomarkers of actinic keratosis, sun-damaged, and nonexposed skin. *Cancer Epidemiol Biomarkers Prev* 2004; **13**: 1996–2002.
- 39 Einspahr J, Alberts DS, Aickin M et al. Expression of p53 protein in actinic keratosis, adjacent, normal-appearing, and non-sun-exposed human skin. *Cancer Epidemiol Biomarkers Prev* 1997; **6**: 583–587.
- 40 Malvey J, Roldan-Marin R, Iglesias-García P, Diaz A, Puig S. Monitoring treatment of field cancerisation with 3% diclofenac sodium 2.5% hyaluronic acid by reflectance confocal microscopy: a histologic correlation. *Acta Derm Venereol* 2015; **95**: 45–50.
- 41 Markowitz O, Schwartz M, Feldman E et al. Defining field cancerization of the skin using noninvasive optical coherence tomography imaging to detect and monitor actinic keratosis in ingenol mebutate 0.015%- treated patients. *J Clin Aesthet Dermatol* 2016; **9**: 18–25.
- 42 Neittaanmaki-Perttu N, Gronroos M, Tani T et al. Detecting field cancerization using a hyperspectral imaging system. *Lasers Surg Med* 2013; **45**: 410–417.
- 43 Pellacani G, Ulrich M, Casari A et al. Grading keratinocyte atypia in actinic keratosis: a correlation of reflectance confocal microscopy and histopathology. *J Eur Acad Dermatol Venereol* 2015; **29**: 2216–2221.
- 44 Ulrich M, Maltusch A, Rowert-Huber J et al. Actinic keratoses: non-invasive diagnosis for field cancerisation. *Br J Dermatol* 2007; **156**(Suppl 3): 13–17.
- 45 Bozzo P, Saboda K, Einspahr JG et al. Reliability and validity of a histologic score as a marker for skin cancer chemoprevention studies. *Anal Quant Cytol Histol* 2003; **25**: 285–292.
- 46 Lanoue J, Chen C, Goldenberg G. Actinic keratosis as a marker of field cancerization in excision specimens of cutaneous malignancies. *Cutis* 2016; **97**: 415–420.
- 47 Erlenndsson AM, Egekvist H, Lorentzen HF et al. Actinic keratosis: a cross-sectional study of disease characteristics and treatment patterns in Danish dermatology clinics. *Int J Dermatol* 2016; **55**: 309–316.
- 48 Korde VR, Bonnema GT, Xu W et al. Using optical coherence tomography to evaluate skin sun damage and precancer. *Lasers Surg Med* 2007; **39**: 687–695.
- 49 Passos SK, de Souza PE, Soares PK et al. Quantitative approach to skin field cancerization using a nanoencapsulated photodynamic therapy agent: a pilot study. *Clin Cosmet Investig Dermatol* 2013; **6**: 51–59.
- 50 Rossi A, Garelli V, Pranteda G et al. Dermoscopy and methyl aminolevulinic acid: a study for detection and evaluation of field cancerization. *J Photochem Photobiol B* 2016; **162**: 72–76.
- 51 Strickland PT, Vitasa BC, West SK, Rosenthal FS, Emmett EA, Taylor HR. Quantitative carcinogenesis in man: solar ultraviolet B dose dependence of skin cancer in Maryland watermen. *J Natl Cancer Inst* 1989; **81**: 1910–1913.
- 52 Ulrich M, Alarcon I, Malvey J, Puig S. In vivo reflectance confocal microscopy characterization of field-directed 5-fluorouracil 0.5%/salicylic acid 10% in actinic keratosis. *Dermatology* 2015; **230**: 193–198.
- 53 Ulrich M, Krueger-Corcoran D, Roewert-Huber J, Sterry W, Stockfleth E, Astner S. Reflectance confocal microscopy for noninvasive monitoring of therapy and detection of subclinical actinic keratoses. *Dermatology* 2010; **220**: 15–24.
- 54 Gomez CR, Nomellini V, Faunce DE, Kovacs EJ. Innate immunity and aging. *Exp Gerontol* 2008; **43**: 718–728.
- 55 Rittie L, Fisher GJ. Natural and sun-induced aging of human skin. *Cold Spring Harb Perspect Med* 2015; **5**: a015370.
- 56 Dreno B, Cerio R, Dirschka T et al. A novel actinic keratosis field assessment scale for grading actinic keratosis disease severity. *Acta Derm Venereol* 2017; **97**: 1108–1113.
- 57 Olsen EA, Abernethy ML, Kulp-Shorten C et al. A double-blind, vehicle-controlled study evaluating masoprocol cream in the treatment of actinic keratoses on the head and neck. *J Am Acad Dermatol* 1991; **24**: 738–743.
- 58 Leibold M, Dinehart S, Whiting D et al. Imiquimod 5% cream for the treatment of actinic keratosis: results from two phase III, randomized, double-blind, parallel group, vehicle-controlled trials. *J Am Acad Dermatol* 2004; **50**: 714–721.
- 59 Leibold M, Swanson N, Anderson LL, Melgaard A, Xu Z, Berman B. Ingenol mebutate gel for actinic keratosis. *N Engl J Med* 2012; **366**: 1010–1019.
- 60 Epstein E. Quantifying actinic keratosis: assessing the evidence. *Am J Clin Dermatol* 2004; **5**: 141–144.
- 61 Lee KC, Lew R, Weinstock MA. Improvement in precision of counting actinic keratoses. *Br J Dermatol* 2014; **170**: 188–191.
- 62 Weinstock MA, Bingham SF, Cole GW et al. Reliability of counting actinic keratoses before and after brief consensus discussion: the VA topical tretinoin chemoprevention (VATTC) trial. *Arch Dermatol* 2001; **137**: 1055–1058.

- 63 Dirschka T, Gupta G, Micali G *et al.* Real-world approach to actinic keratosis management: practical treatment algorithm for office-based dermatology. *J Dermatolog Treat* 2016; **28**: 431–442.
- 64 Peris K, Calzavara-Pinton PG, Neri L *et al.* Italian expert consensus for the management of actinic keratosis in immunocompetent patients. *J Eur Acad Dermatol Venereol* 2016; **30**: 1077–1084.
- 65 Werner RN, Stockfleth E, Connolly SM *et al.* Evidence- and consensus-based (S3) Guidelines for the Treatment of Actinic Keratosis – International League of Dermatological Societies in cooperation with the European Dermatology Forum – Short version. *J Eur Acad Dermatol Venereol* 2015; **29**: 2069–2079.
- 66 Dirschka T, Pellacani G, Micali G *et al.* A proposed scoring system for assessing the severity of actinic keratosis on the head: actinic keratosis area and severity index. *J Eur Acad Dermatol Venereol* 2017; **31**: 1295–1302.