

CLINICAL REPORT

Dermoscopic Changes in Melanocytic Naevi in Children during Digital Follow-up

Anna BELLONI FORTINA¹, Edoardo ZATTRA^{1,2}, Bianca BERNARDINI^{1,2}, Mauro ALAIBAC² and Andrea PESERICO²¹Unit of Pediatric Dermatology and ²Unit of Dermatology, University of Padua, Padua, Italy

The aim of this study was to investigate the dermoscopic changes in acquired melanocytic naevi in a large paediatric population over an interval of several years. Images of 717 melanocytic naevi were obtained from 160 consecutive patients. Dermoscopic pigment pattern changes were observed in one of two lesions after a follow-up of one year, in 34 of 295 lesions (11.5%) after 2 years, in 40 of 190 lesions (21.1%) after 3 years, in 40 of 141 lesions (28.4%) after 4 years, in 5 of 37 lesions (13.5%) after 5 years, in 12 of 31 lesions (38.8%) after 6 years, and in 7 of 21 lesions (33.3%) after 7 years. Dermoscopic changes were detected in 25.3% of the lesions in patients aged 3–6 years, in 21% of the lesions in patients aged 7–12 years, and in 15.5% of the lesions in patients over 13 years. Main pattern changes consisted of transition from globular to globular-reticular (35 naevi), from globular to reticular (14 naevi) and from globular-reticular to reticular (24 naevi). These results are consistent with the view that melanocytic naevi generally undergo a characteristic transition from a globular pattern to a reticular pattern. Most of the changes are observed in the 3–6 years age group when hormonal and/or environmental factors are not thought to play a role in pattern alterations. **Key words:** melanocytic; naevi; dermoscopy; pattern; changes.

(Accepted October 16, 2011.)

Acta Derm Venereol 2012; 92: 427–429.

Edoardo Zattra, Dermatology Unit, University of Padua, Via C. Battisti 206, IT-35128 Padova, Italy. E-mail: edoardo.zattra@unipd.it

Dermoscopy is a non-invasive technique that allows the visualization of subsurface structures by decreasing reflection at the stratum corneum–air interface. In adults, the dermoscopic features and evolution of melanocytic

naevi during follow-up have been studied extensively (1). In children, while data concerning dermoscopic features of acquired naevi are available (2, 3), there are scarce data on dermoscopic changes in melanocytic naevi during follow-up. Dermoscopic follow-up of melanocytic lesions in children have been performed only on small series of patients, in particular those with Spitz- or Reed-type naevi (4, 5). The aim of this study was to investigate the dermoscopic changes in a considerable number of acquired melanocytic naevi in a large paediatric population over an interval of several years.

METHODS

The dermoscopic images evaluated in this study were collected in the database of the melanocytic lesion clinic of the Unit of Pediatric Dermatology of the University of Padua. Images of 717 melanocytic naevi were obtained from 160 consecutive patients (78 females, 82 males). At the first visit, age 3–16 years, all patients had skin types I, II, or III according to Fitzpatrick's classification (6). Images were acquired using a computerized polarized-light videodermoscopy system (FotoFinderdermoscope, Teachscreen Software, Bad Birnbach, Germany) with a water interface solution at magnifications of $\times 20$ – $\times 40$. Patterns were defined according to the 2003 consensus conference (7). A pattern was defined as "changed" in the presence of any change from a defined dermoscopic pattern observed at baseline into a different dermoscopic pattern observed at subsequent visits.

RESULTS

Digital dermoscopic follow-up was available at one year for 2 naevi, 2 years for 295 naevi, 3 years for 190 naevi, 4 years for 141 naevi, 5 years for 37 naevi, 6 years for 31 naevi, and 7 years for 21 naevi. We divided our population into 3 age groups: 3–6 years (79 naevi), 7–12 years (386 naevi), and over 13 years (252 naevi). At baseline 284 naevi showed a reticular pattern, 119 a globular pattern, 110 a cobblestone pattern, 16 a

Table I. Distribution of dermoscopic variations in melanocytic naevi

Age	Follow-up							Total
	1 years	2 years	3 years	4 years	5 years	6 years	7 years	
	Changed/Total	Changed/Total	Changed/Total	Changed/Total	Changed/Total	Changed/Total	Changed/Total	Changed/Total
3–6 years	0/1	7/31	2/14	11/30	0/3	0/0	0/0	20/79
7–12 years	1/1	20/186	25/99	22/67	1/7	7/15	5/11	81/386
> 13 years	0/0	8/78	13/77	7/44	4/27	5/16	2/10	39/252
Total	1/2	35/295	40/190	40/141	5/37	12/31	7/21	140/717

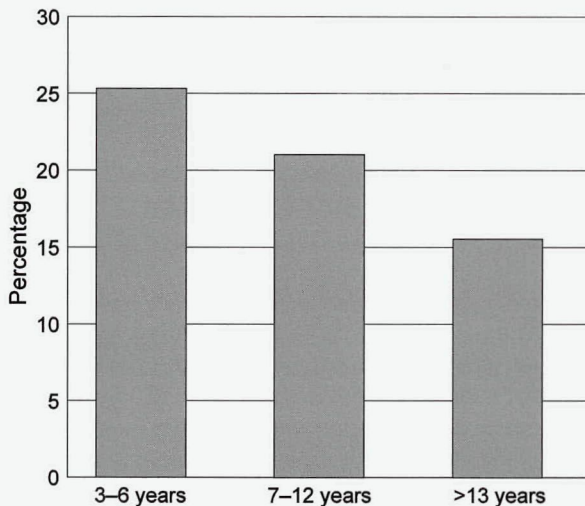


Fig. 1. Percentage of changed naevi by age group.

homogeneous pattern, 45 a multicomponent pattern, 64 a reticular/globular pattern, 2 a reticular/cobblestone pattern, 48 a reticular/homogeneous pattern, and 25 a globular/homogeneous pattern. Dermoscopic changes in the 717 lesions were observed in 128 naevi (18%).

Dermoscopic pattern changes were observed in one of two lesions after a follow-up of 1 year, in 34 of 295 (11.5%) after 2 years, in 40 of 190 (21%) after 3 years, in 40 of 141 (28.4%) after 4 years, in 5 of 37 (13.5%) after 5 year, in 12 of 31 (38.7%) after 6 years, and in 7 of 21 (33.3%) after 7 years (Table I). Patients aged 3-6 years showed a dermoscopic change in 25.3% of the lesions; patients aged 7-12 years in 21% of the lesions; and patients over 13 years of age in 15.5% of the lesions (Fig. 1). Changes in dermoscopic pattern are displayed in Table II. The main changes, regardless of age group, were from globular to globular-reticular (35 naevi), from globular to reticular (14 naevi) and from globular-reticular to reticular (24 naevi). Other changes were: cobblestone to globular-reticular (7 naevi) and cobblestone to reticular-cobblestone (5 naevi) or to multicomponent pattern (5 naevi). The figures show a naevus changing from a globular pattern (Fig. 2a) to a reticular pattern (Fig. 2b) in 2 years.

DISCUSSION

Dermoscopic pattern changes in pigmented lesions have been studied in acral lesions (8), slow-growing malignant melanoma (9), and in common melanocytic naevi after intense sun exposure (10). Articles dealing with variation in the dermoscopic pattern of congenital melanocytic naevi were published in 2006 (11) and 2007 (12). There is a general theory that the dermoscopic pattern in children evolves from globular to reticular with growth (3). This hypothesis was formulated on the basis of the greater prevalence of the globular (and cobblestone) pattern in young children and of the reticular pattern in adults (13). We analysed a large number of melanocytic naevi over time in order to substantiate this hypothesis. The main changes in our population of naevi (717 lesions) were from globular to globular-reticular (35 naevi), from globular to reticular (14 naevi), and from globular-reticular to reticular (24 naevi). These data are consistent with the view that acquired melanocytic naevi have a peculiar transition from one pattern to another. From a histological point of view naevi with a globular pattern are dermal proliferations of melanocytes, while naevi with a reticular pattern are epidermal proliferations of melanocytes (14). Naevi with a globular pattern are generally considered to persist throughout lifetime, evolving to the typical dermal naevi in adults, while naevi with a reticular pattern, which are epidermal proliferations, are thought to develop later in life in response to ultraviolet (UV) exposure or hormones (14). Our work instead shows several cases of a single naevus evolving from a globular pattern, characterized by a dermal proliferation to a reticular pattern consistent with an epidermal proliferation. Studies in the literature have usually divided young populations into older and younger age groups (e.g. 1-15 years (2)). We decided to analyse the variations in pattern, dividing our population into different age groups (3-6, 7-12, >13 years) in order to include or exclude the effects of hormones (e.g. pre- or post-pubertal patients) and sun-exposure. One interesting observation is that most of the changes occurred in the 3-6-year age group, when

Table II. Changes in dermoscopic pattern types

	Naevi at baseline, n	Pattern at final					Three or more	Globular reticular	Reticular cobblestone	Reticular homogenous	Globular homogenous
		Reticular	Globular	Cobblestone	Homogenous						
Reticular	288	0	1	3	2	3	0	1	0		
Globular	119	14	0	3	2	35	0	1	1		
Cobblestone	110	2	0	1	5	7	5	0	1		
Homogenous	16	1	0	0	0	0	0	0	0		
≥ 3 patterns	45	0	0	1	0	0	0	0	0		
Globular reticular	64	24	0	0	0	0	0	0	1		
Reticular cobblestone	2	0	0	0	0	0	0	0	0		
Reticular homogenous	48	2	0	0	0	1	0	0	0		
Globular homogenous	25	2	0	0	3	2	0	4	0		

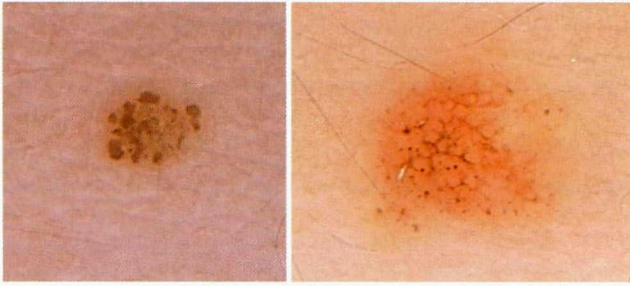


Fig. 2. (a) Naevus with globular pattern. (b) Naevus changed to a reticular pattern after the 2-year follow-up.

hormonal factors are not thought to be involved in pattern alterations and children generally have a limited sun exposure. In conclusion, we have investigated for the first time in a large series of paediatric patients pattern modifications of melanocytic naevi. Our study provides definitive clinical data to support a previous view concerning dermoscopic changes in pattern (12). Furthermore, the results of our study clearly delineate the age groups in which these modifications can be observed.

The authors declare no conflicts of interest.

REFERENCES

- Zalaudek I, Manzo M, Savarese I, Docimo G, Ferrara G, Argenziano G. The morphologic universe of melanocytic nevi. *Semin Cutan Med Surg* 2009; 28: 149–156.
- Aguilera P, Puig S, Guilabert A, Julià M, Romero D, Vicente A, et al. Prevalence study of nevi in children from Barcelona. *Dermoscopy, constitutional and environmental factors*. *Dermatology* 2009; 218: 203–214.
- Zalaudek I, Grinschgl S, Argenziano G, Marghoob AA, Blum A, Richtig E, et al. Age-related prevalence of dermoscopy patterns in acquired melanocytic naevi. *Br J Dermatol* 2006; 154: 299–304.
- Fernández-Pugnaire MA, Arias-Santiago S, Serrano-Falcón C, Almazán-Fernández FM, Aneiros-Fernández J, Serrano-Ortega S. Evolution of Reed nevi dermoscopic pattern in childhood. *Arch Dermatol* 2010; 146: 814.
- Nino M, Brunetti B, Delfino S, Brunetti B, Panariello L, Russo D. Spitz nevus: follow-up study of 8 cases of childhood starburst type and proposal for management. *Dermatology* 2009; 218: 48–51.
- Fitzpatrick TB. The validity and practicality of sun-reactive skin types I through VI. *Arch Dermatol* 1988; 124: 869–871.
- Argenziano G, Soyer HP, Chimenti S, Talamini R, Corona R, Sera F, et al. Dermoscopy of pigmented skin lesions: results of a consensus meeting via the Internet. *J Am Acad Dermatol* 2003; 48: 679–693.
- Altamura D, Zalaudek I, Sera F, Argenziano G, Fargnoli MC, Rossiello L, et al. Dermoscopic changes in acral melanocytic nevi during digital follow-up. *Arch Dermatol* 2007; 143: 1372–1376.
- Argenziano G, Kittler H, Ferrara G, Rubegni P, Malvey J, Puig S, et al. Slow-growing melanoma: a dermoscopy follow-up study. *Br J Dermatol* 2010; 162: 267–273.
- Dobrosavljevic D, Brasanac D, Apostolovic M, Medenica L. Changes in common melanocytic naevi after intense sun exposure: digital dermoscopic study with a 1-year follow-up. *Clin Exp Dermatol* 2009; 34: 672–678.
- Seidenari S, Pellacani G, Martella A, Giusti F, Argenziano G, Buccini P, et al. Instrument-, age- and site-dependent variations of dermoscopic patterns of congenital melanocytic naevi: a multicentre study. *Br J Dermatol* 2006; 155: 56–61.
- Changchien L, Dusza SW, Agero AL, Korzenko AJ, Braun RP, Sachs D, et al. Age- and site-specific variation in the dermoscopic patterns of congenital melanocytic nevi: an aid to accurate classification and assessment of melanocytic nevi. *Arch Dermatol* 2007; 143: 1007–1014.
- Scope A, Marghoob AA, Dusza SW, Satagopan JM, Agero AL, Benvenuto-Andrade C, et al. Dermoscopic patterns of naevi in fifth grade children of the Framingham school system. *Br J Dermatol* 2008; 158: 1041–1049.
- Zalaudek I, Hofmann-Wellenhof R, Kittler H, Argenziano G, Ferrara G, Petrillo L, et al. A dual concept of nevogenesis: theoretical considerations based on dermoscopic features of melanocytic nevi. *J Dtsch Dermatol Ges* 2007; 5: 985–992.

Copyright of Acta Dermato-Venereologica is the property of Society for Publication of Acta Dermato-Venereologica and its content may not be copied or emailed to multiple sites or posted to a listserv without the copyright holder's express written permission. However, users may print, download, or email articles for individual use.