



Available online at [www.sciencedirect.com](http://www.sciencedirect.com)

ScienceDirect

journal homepage: [www.elsevier.com/locate/gie](http://www.elsevier.com/locate/gie)



ORIGINAL ARTICLE/ARTICOLO ORIGINALE

# Endodontic and periodontal treatment of dens invaginatus: Report of 2 clinical cases

*Trattamento endodontico e parodontale di dens invaginatus: rapporto di 2 casi clinici*

Cristian Coraini<sup>1,\*</sup>, Tommaso Mascarello<sup>1</sup>, Cristina Maria de Palma<sup>1</sup>,  
Edoardo Alvise Gobbato<sup>1</sup>, Roberto Costa<sup>1</sup>, Luca de Micheli<sup>2</sup>,  
Davide Castro<sup>3</sup>, Carmen Giunta<sup>1</sup>, Sylvie Rossi<sup>1</sup>, Chiara Casto<sup>1</sup>

<sup>1</sup> Italian Stomatological Institute, CAD-CAM Prosthetic Department, Milan, Italy

<sup>2</sup> Italian Stomatological Institute, Department of Periodontology-Implantology III, Milan, Italy

<sup>3</sup> Dental School – Lingotto, University of Turin, Italy

Received 10 June 2013; accepted 1 September 2013

Available online 16 October 2013

## KEYWORDS

Dens invaginatus;  
Classification of Oehlers;  
Upper lateral incisor;  
Abnormal tooth  
development;  
Pro-Root MTA.

## Abstract

**Objectives, materials and methods:** The purpose of this work is to describe the treatment of two lateral incisors affected by developmental abnormalities (Oehlers, types I and II) treated respectively through periodontal regenerative therapy associated with conservative correction of shape anomaly, and orthograde retreatment.

**Results:** Both therapies used resulted in complete remission of the initial symptoms and total healing of the lesions present.

**Conclusions:** “Dens invaginatus” is a dental development malformation that can predispose to the onset of caries, pulpal involvement and periodontal lesions, the treatment of which may require a specialized and often multidisciplinary approach. This malformation should therefore be recognized in time in order to establish effective prevention protocols, when possible, or prevent related consequences generating non-recoverable endodontic, periodontal or combined disease.

© 2013 Società Italiana di Endodonzia. Production and hosting by Elsevier B.V. All rights reserved.

\* Corresponding author at: 32 Piazza della Repubblica, 20124 Milan, Italy. Tel.: +39 02 781924 02/36523566.

E-mail: [cristian.coraini@fastwebnet.it](mailto:cristian.coraini@fastwebnet.it) (C. Coraini).

Peer review under responsibility of Società Italiana di Endodonzia.



Production and hosting by Elsevier

1121-4171/\$ – see front matter © 2013 Società Italiana di Endodonzia. Production and hosting by Elsevier B.V. All rights reserved.

<http://dx.doi.org/10.1016/j.gien.2013.09.005>

**PAROLE CHIAVE**

Dens invaginatus;  
Classificazione di  
Oehlers;  
Incisivo laterale  
superiore;  
Anomalie sviluppo  
dentale;  
MTA-Pro root.

**Riassunto**

*Obiettivi e materiali e metodi:* Scopo del lavoro è descrivere il trattamento di due incisivi laterali superiori affetti da anomalie di sviluppo (Oehlers, tipo I e II) trattati rispettivamente mediante terapia rigenerativa parodontale associata a correzione conservativa dell'anomalia di forma, e ritrattamento ortograde.

*Risultati:* Entrambe le terapie praticate hanno determinato la completa remissione dei sintomi iniziali e la totale guarigione delle lesioni presenti.

*Conclusioni:* Il "dens invaginatus" è una malformazione dello sviluppo dentale che può predisporre all'insorgenza di carie, coinvolgimento pulpare e lesioni parodontali, il cui trattamento può richiedere un approccio specialistico e talvolta multidisciplinare. Tale malformazione dovrebbe essere quindi riconosciuta per tempo per poter instaurare efficaci protocolli di prevenzione, quando possibili, o evitare che le conseguenze correlate generino una patologia endodontica, parodontale o combinata non recuperabile.

© 2013 Società Italiana di Endodonzia. Production and hosting by Elsevier B.V. Tutti i diritti riservati.

**Introduction**

During the physical examination of the oral cavity the observation of dental anomalies is a very frequent clinical event. Within these anomalies dens invaginatus constitutes one of the most commonly encountered. According to the literature, in fact, its prevalence is between 0.3% and 10%.<sup>1</sup> This is an alteration of odontogenesis that results in invagination of the enamel organ into the dental papilla.<sup>2</sup> Salter was the first to describe in 1855 these anatomical abnormalities defining them as a "tooth in a tooth." The subsequent discovery of X-rays allowed Bush in 1897 to describe the radiographic appearance of such pathologic findings, confirming the presence of a dysmorphic dental element inside a tooth proper.<sup>3</sup>

The permanent teeth more frequently affected by this anomaly are the upper lateral incisors (90% versus 6.5% of posterior teeth), often bilaterally (in 43% of cases according to the study by Grahnén et al.), also in the literature cases have been reported of dens invaginatus, also borne by the second deciduous molars.<sup>2,4,5</sup> The etiology of this particular clinical picture remains very controversial, as evidenced in the work.<sup>6,7</sup>

The purpose of this work is the description of two clinical cases that came to our attention relating to the above-mentioned dental anomaly, attributable to periodontal preservation and endodontic treatment, respectively.

**Materials and methods****Case 1**

In May 2010, patient I.D. was presented to our attention, of Asian descent and 36 years old, reporting pain symptoms in the palatine region at element 2.2. The proximate and remote medical history were negative, as well as was the extra-oral examination. The intra-oral examination of that area however allowed the observation of invagination of the enamel which distorted the Carabelli cuspid ancillary of palatal element 2.2. There was also a brown vertical groove in the region of convergence of the invagination of the enamel, and the periodontal probing of that groove measured 9 mm. An X-ray (radiograph performed with Rinn centering) showed the presence of an infrabony, mesial and

distal defect in which the peaks were normo-maintained ("bowl-like" infrabony defect). Detailed mapping of the periodontal defect for the mentioned diagnosis was also set out.

The vitality test of element 2.2 was normo-positive, there was no occurrence of pain caused to the vertical and lateral percussion, and mobility was 1°. After the initial site preparation consisting of ultrasonic decontamination and manual classical instrumentation (curettage), we opted for a periodontal regeneration of the defect, with the intent also at the same time to correct the open dental anatomy invaginated above and subgingivally, responsible for the pathology described. In pursuing this objective, we proceeded as follows. After performing plexus anesthesia 1:100,000 (Ubi-tesin 40 mg/ml, 3M-Espe, Seefeld, Germany), vestibularly and palatally to element 2.2, we performed a palatal intra-sulcular incision from mesial 1.3 to distal 1.1. Into the periosteum a full thickness flap was low-cut carved to guarantee access to the surgical defect and optimal vision. We therefore proceeded to clean up and decontaminate the infra-formed bone pocket further, using both hand tools (Gracey curettes 3/4 and 7/8) and mechanical (long shank burs, 40 micron particle size mounted on counter-angle to blue ring, Perio-set cutter CA 440 Intensiv, Montagnola, Switzerland) and antiseptic agents (washing with 12 volumes hydrogen peroxide and chlorhexidine 0.12%). By the use of cutters mounted on the red ring counter-angle handpiece we smoothed and flattened the brown groove throughout its length in correspondence to the entire invagination, and we filled with Mineral Aggregate Trioxid white color. This according to a rationale for use for which please refer to that section of the discussion. Before completing the operation dedicating ourselves to the regeneration of the periodontal defect in a manner to be described below, we assembled an open flap rubber dam, and ran coronally to the cemento-enamel line reconstruction in a small composite "bridge", above the MTA, (ProRoot MTA Root Canal Repair Material, Dentsply Tulsa Dental Specialties, Tulsa, Oklahoma, USA) to improve the anatomy of invagination corresponding to the dental track, which was thus transformed into a convexity. At this point, apically to the cemento-enamel junction, we filled the infra-bone defect with deproteinized bovine bone (Bioss, Geistlich Pharma, Wolhusen Switzerland) positioned at the cemento-enamel junction, and the grafting of biocompatible

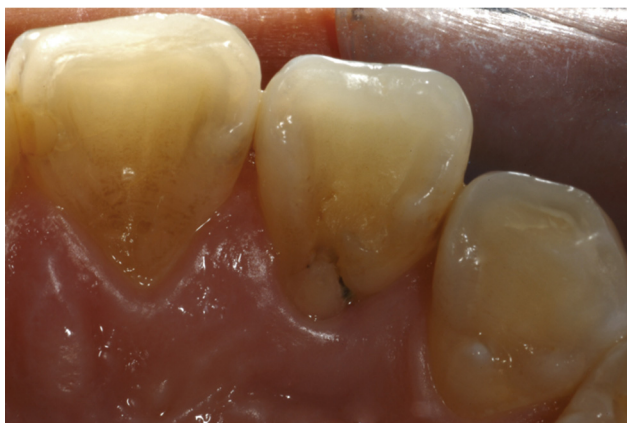material was covered with a collagen membrane (Bio-Gide, Geistlich Pharma, Wolhusen Switzerland), suitably trimmed and shaped. Finally we replaced the flap to its original position, by applying a suture at detached points with the vertical mattress stitch and simple detached points on the apex of the papillae between the elements involved (Goretex CV5, Gore-Tex sutures, WL Gore & Associates, Flagstaff, Arizona, USA).<sup>8,9</sup>

We prescribed antibiotic medication to the patient (Augmentin cp. 1 g, 2 cp./day for 5 days) and an analgesic/anti-inflammatory (Synflex strong 550 mg, 1 cp as needed), also suggesting the use of local mouthwashes for the entire stay in situ of the suture (10–2 volume hydrogen peroxide, diluted to 50%, 1 rinse per day, Chlorhexidine 0.12% with Anti-Discoloration System 2/day, chlorhexidine gel applications 4 times/day), which was removed on day 8. The patient's clinical course was good, with no complications, and marked by little postoperative pain. In particular, the patient has not materialized short or long-distance exposure of portions of the membrane, proving the tissue seal was reached via the suturing applied and the subsequent primary closure healing, or reported the presence of micro-granules of bio-material within the oral cavity. This case is described iconographically in Figs. 1–4.

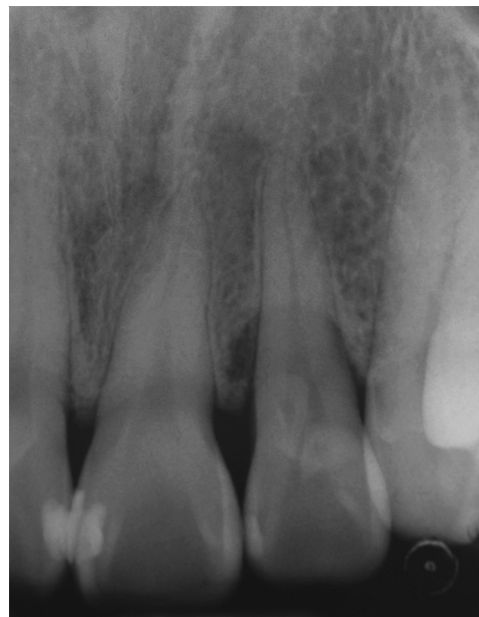
## Case 2

S.I., 14 years old, is referred as a patient by a colleague after the repeated occurrence of abscesses borne by the upper right lateral incisor (item 1.2). The necrotic element is treated by orthograting but without success. Two months ago a first reprocessing was undertaken but acute symptoms persist, with the further emergence of a fistula on the vestibular fornix. Radiographically three areas of radiolucency were shown, one at apical level and two on the mesial profile of the root. Within 4 months of the last operation a second reprocessing was carried out that temporarily resolved the abscess condition. The reappearance of the fistula after 6 months argues in favor of sending the patient for a new reprocessing to be performed by microscopy.

The re-opening of the pulp chamber and a more accurate view of the complex root system highlights the presence of

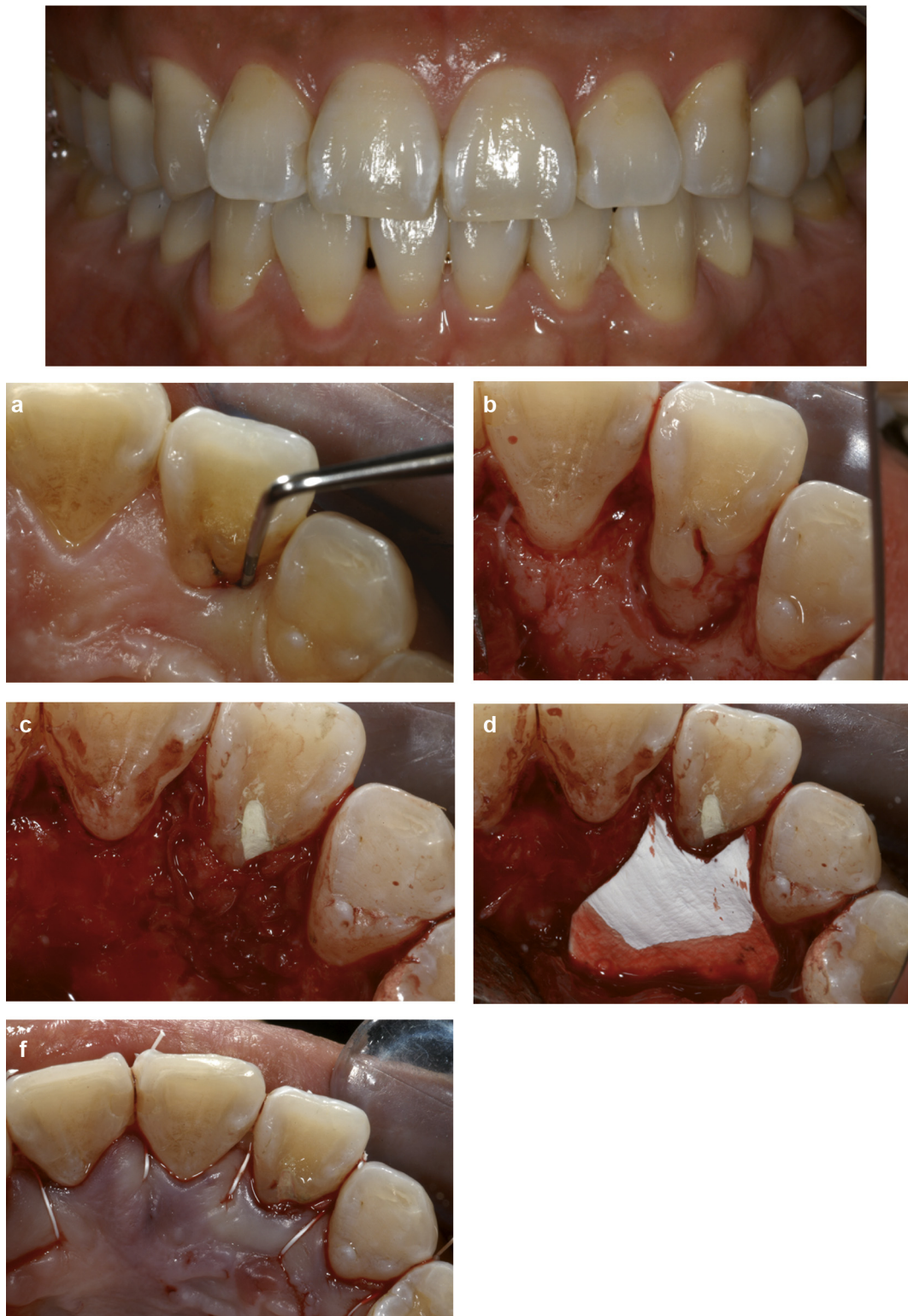

**Figure 1** Case 1. The initial case: note the presence of a brown groove corresponding to the track.

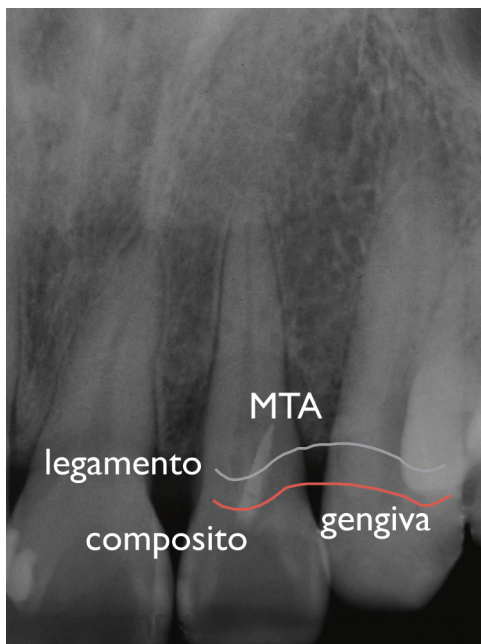


**Figure 2** Initial radiography. Periodontal lesion infra-bone and presence of tooth shape anomaly concerning item 2.2.

multiple inter-canal septa, which prevented, in the previous treatments, the performance of adequate action by irrigating solutions and, consequently, obtaining an effective three-dimensional seal in the final stage of filling. Through the use of the operating microscope and special ultrasonic tips (Start X no. 3, Dentsply Maillefer, Tulsa, Oklahoma, USA), the septa, and necrotic and infected material contained therein was removed. High magnification vision together with effective coaxial illumination made it possible to detect the presence of three independent output exits, two at the level of the apical portion and one on the buccal surface in correspondence with the middle third of the root. It was not necessary to use the rotating tools. The focus was on deep irrigation action, alternating the use of heated sodium hypochlorite (5% Niclor, OGNA Lab S.r.l., Muggiò MB, ITALY) and EDTA (Tubuliclean, OGNA Lab S.r.l., Muggiò MB, ITALY), activated by ultrasound (Endo Activator, Dentsply Tulsa Specialties, Tulsa, Oklahoma, USA) and left to act for about 45 min. The abnormal morphology of the root canal system and persistent apical moisture made us opt for the execution of an obturation MTA filling (MTA ProRoot Root Canal Repair Material, Dentsply Tulsa Dental Specialties, Tulsa, Oklahoma, USA) in white commercial form. The material was made with the MAP-SYSTEM dedicated tip (Dentsply Maillefer, Tulsa, Oklahoma, USA) system with increments starting at 3 independent exits until it reached a thickness of 8 mm. Compaction was favored by the use of a dedicated plugger. The 4 mm upper portion has remained in contact with the damp apical interface, the lower one with wet cotton placed in the chamber. The provisional filling was made with a 5 mm layer of Cavit (3M-Espe, Seefeld, Germany). After 72 h the correct hardening of the MTA was verified and the final filling proceeded, performed using composite materials (Filtek Supreme, 3M-Espe, Seefeld, Germany). Case 2 is also illustrated iconographically in Figs. 5–13. This study was undertaken by consent of the patients involved and in accordance with ethical standards established by the



**Figure 3** The patient shows at the initial physical examination almost perfect teeth. (a) The brown groove on the track of item 2.2 shows a very deep periodontal probing. (b) The palatal infra-bone lesion with flap open. It is clear that the dental anomaly, which promotes bacterial penetration, has contributed to the formation of the lesion. (c) After the “smoothing” of the brown groove and preparation of the infra-bone defect, Mineral Trioxide Aggregate (MTA Pro Root) was positioned and then the grafting of biocompatible material executed. (d) The defect is adequately protected by contouring a resorbable membrane. (e) The flap suture, palatine view. The small composite reconstruction performed open-flap, following isolation with rubber dam, which covers a portion of Pro-Root MTA coronally at the track, is evident.

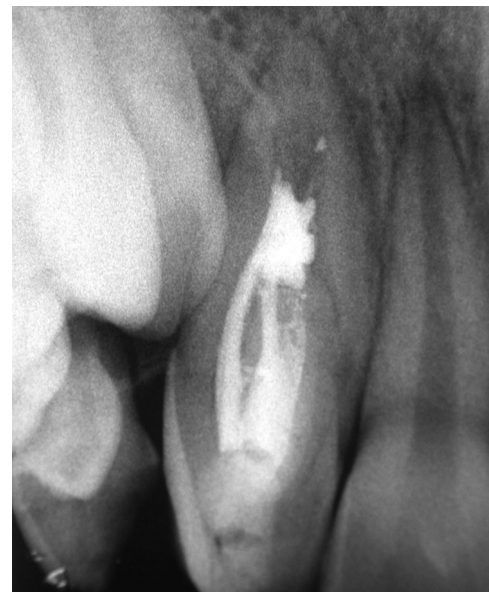

**Figure 4** Final radiograph at 18 months, with illustration of the steps performed and the apparent resolution of the original infra-bone defect (compare with Fig. 2).

Helsinki Declaration. Informed consent was freely and fully expressed by the patients involved before their recruitment.

## Results

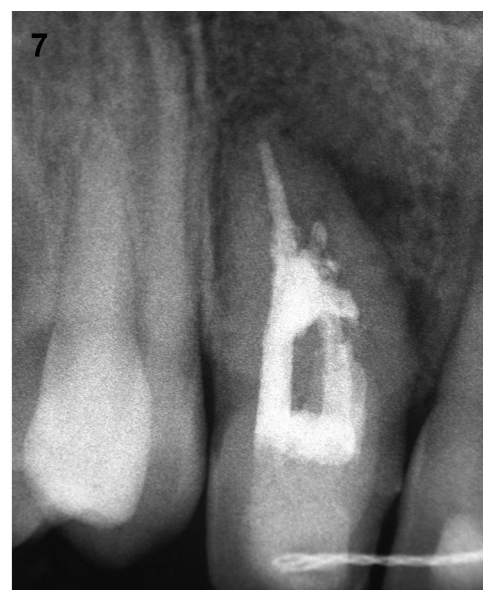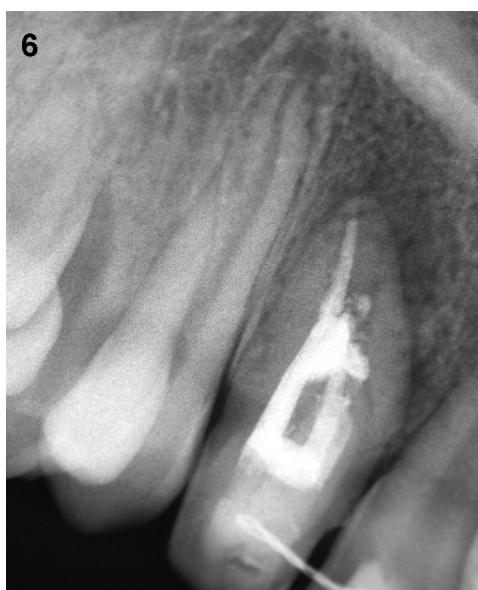*Case I.* As shown in the clinical description of the case, the course of action had good results, the patient did not report particular pain, beyond the slight inconvenience post-surgery. The wound always seemed healthy and with rosy



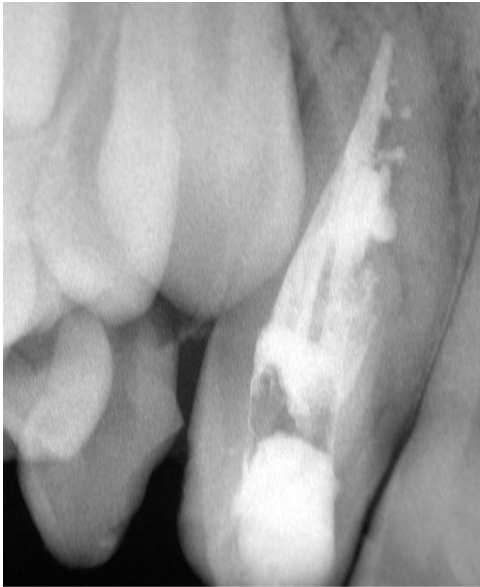**Figure 5** Case 2. Initial radiograph of the first treatment of item 1.2.

complexion, not denoting redness with clinical signs of inflammation or worse of re-infection of the site. We ran clinical and radiographic inspections by means of intra-oral radiographs every 15 days, 1 month, 2 months, 4 months, 6 months, 1 year. In each of the aforementioned controls the dental element appeared normal-vital in tests, stable, and non-tender to percussion. The radiographic appearance of the filled defect was gradually acquiring greater mineralization. The periodontal probing, not executed before a year after intervention, was less than 4 mm.

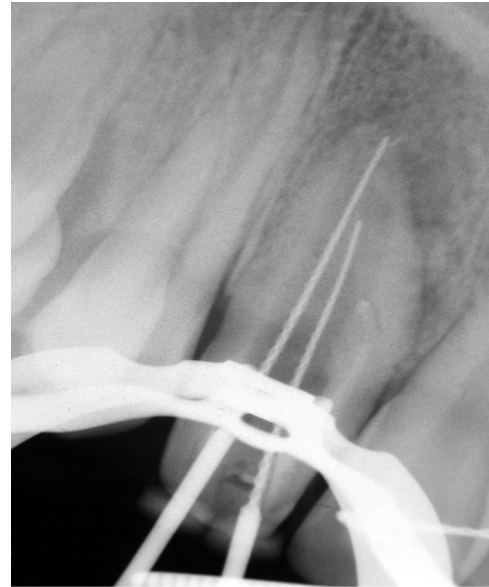
*Case II.* The acute symptoms, along with vestibular fistula, were resolved after 48 h from the operation. Radiographic controls after 6 and 12 months indicate the return of integrity of the cortical bone and the complete resolution of the case.



**Figures 6 and 7** Intra-oral radiographs at 2 months (Figure 6) and 4 months (Figure 7) after the first reprocessing of the element. Note the presence of radio-transparent lesions evident clinically, associated with the appearance of a vestibular fistula.



**Figure 8** Intra-oral X-ray 6 months after the second reprocessing.



**Figure 10** New working lengths; we highlight: removal of septa, finding exits, deep cleansing obtained (checked with the operating microscope).

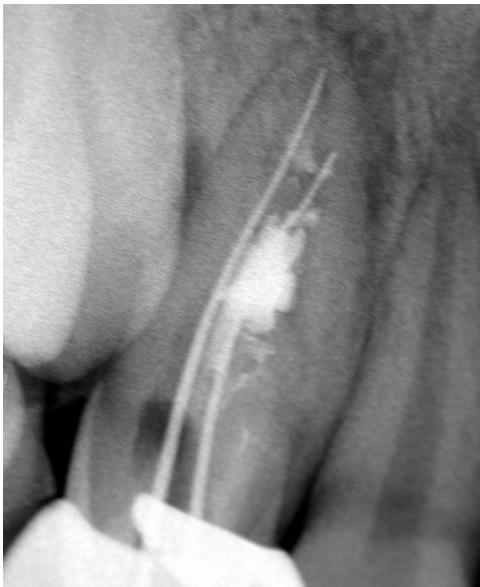
## Discussion

Various etiology hypotheses were formulated in relation to dens invaginatus. According to a study by Rushton this condition would indicate a faulty cell stimulation of the enamel organ that would migrate to all the dental papilla.<sup>10,11</sup> Atkinson in 1943 suggested that behind this anomaly in tooth development there might be an outside force coming from the adjacent teeth or by traumatic or phlogistic events.<sup>12</sup> Subsequent discoveries in DNA research led to analyzing the genetic and hereditary aspect of the disease. In fact, there is some familial predisposition to the

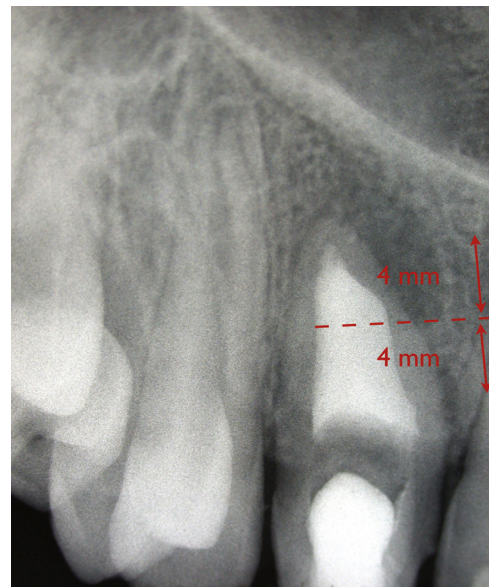
disorder. According to a study conducted on a population of 3020 Swedish children, about 2.7% present with dens invaginatus, 43% of whom have parents and 32% brothers or sisters with the same issue.<sup>4</sup>

In the literature there are many possibilities for the classification of the malformation considered.<sup>13–16</sup> The one that has experienced the most success due to its simplicity, but especially its prognostic value, is that of Oehlers.<sup>17</sup> He proposed as criteria for classification of invagination depth from the crown to the root by radiographic analysis:

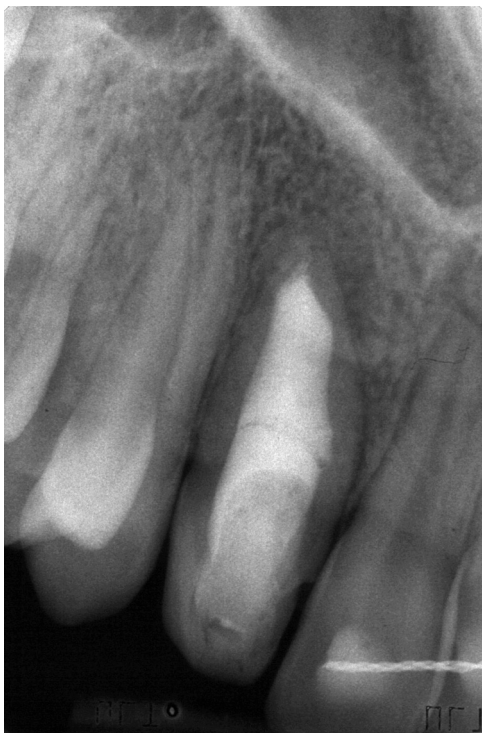- Type I: The invagination coated with enamel does not exceed the cemento-enamel junction.



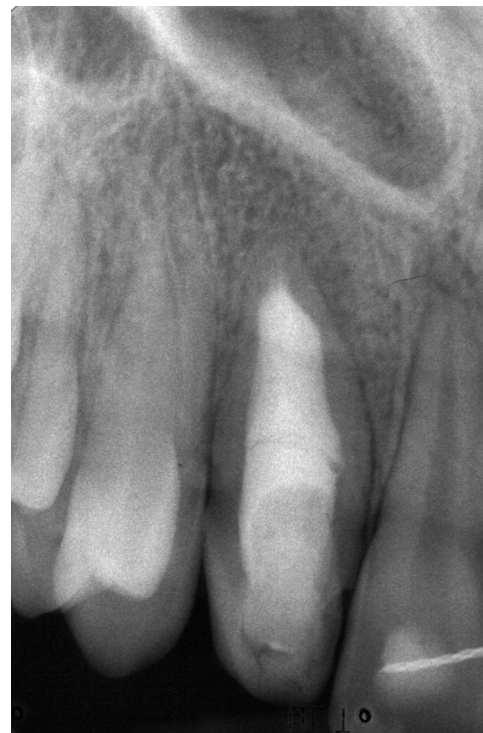**Figure 9** Working lengths of the third retreatment (early care by Dr. Castro, 1 year after the second reprocessing previously performed by third parties).



**Figure 11** MTA apical plug, with direct seal of output ports, direct wet cement apical contact, and compaction of the material performed by ultrasonic processes.



**Figure 12** Three days after inserting a wet cotton-pellet in the chamber, the temporary filling is replaced with a final restoration in composite resin. Radiograph at 6 months after completion of therapy.



**Figure 13** The final radiograph at 12 months shows the complete healing of the originally present lesions.

- Type II: The invagination coated with glaze, enters into the pulpal chamber but remains confined to the root canals without interaction with the periodontium.
- Type IIIA: The invagination extends to the roots and interacts with the periodontal ligament laterally through a pseudo-foramen. Generally there are no interactions with the pulp that is compressed in the root.
- Type IIIB: The invagination extends into the roots and interacts with the periodontal ligament through the apical foramen. There are usually no interactions with the pulp.

While inheriting all the limits of conventional radiography (two-dimensional representation of three-dimensional reality), this classification makes it possible to distinguish the incomplete invaginations (type I–II) from complete (type III) with its prognostic and therapeutic implications. The inflammatory processes borne by the invagination of an Oehlers type III have inevitable repercussions at the periodontal level, creating a lesion difficult to clinically manage. Fortunately, this type of problem is also the most rare, being only 5% of dentes invaginati, compared to 79% and 15% respectively of the Oehlers types I and II. Sometimes, the beginning of invagination is difficult to identify for which you may need the use of chemical detection systems like methylene blue or radiopaque, used in conjunction with magnification systems. But when should you suspect you are facing this type of problem? Often the Salter invaginations are accompanied by evident alterations in dental anatomy such as an increase in the mesial-distal diameter or lingual-labial element, the presence of a notch at the incisal level in association with a labial sulcus, a conical or triangular morphology, the presence of a girdle or a very prominent “cusp

heel”.<sup>17–19</sup> Obviously before these concerning clinical aspects, we cannot be exempt from conducting a careful radiographic examination, using not only the parallel rays technique, but by integrating this data with that of one or more intra-oral radiographs exposed by an X-ray tube inclined at 15° with respect to the film (unprojected radiography). Also in this case the dens invaginatus presents a possible wide range of radiographic representations: From the “crosshair” appearance, that of a pulp chamber of difficult definition, by the presence of a “pseudo-channel” that opens sideways to the periodontal ligament, in the presence of an abnormal lesion and irregular contours. All this portends the difficulties which the clinician may encounter should endodontic treatment of the element be required.

Regarding the histological appearance of the disease, it is noted that while the enamel and dentin of the “external tooth” are normal, on the contrary the tissues that cover the invagination appear dysplastic and sometimes may also present gaps and fenestrations, which constitute an easy access route for bacteria to the pulp. The SEM analysis of the invagination enamel reveals a different chemical composition, rich in phosphates and calcium ions and magnesium deficient. This is in clear contrast to the Beynon studies of 1982 according to which the tissues of the invagination would be hypo-mineralized.<sup>1,3</sup> The early interception of type I Oehlers, more than of other anomalies, turns out to be a discriminant in determining the prognosis of the dental element concerned. In fact, if you do not see pulpal pathology, the clinical intervention should be limited to a simple prophylactic sealing of the invagination. If, instead, the endodontic treatment is required, the therapeutic protocol can

vary depending on the case: from a simple pulpotomy of the immature tooth in pulpitis, necrotic tooth orthograde treatment, with or without endodontic surgery.<sup>20</sup>

Endodontic treatment of these teeth is a complex procedure because they have a difficult root canal anatomy and possible non-formation of the root apex, and in addition, the morphology of the main channel can be irregular and invaginated tissue could occupy and block the channel at different levels. These conditions often do not allow us to fully orchestrate the root canal walls.<sup>21,22</sup> For this reason you must often treat these teeth with a combined approach, i.e. with both an orthograde endodontic and endodontic-surgical treatment. Non-surgical treatment should be the first choice, and the surgical phase should occur only in cases where the orthograde canal treatment has not been successful, or in severe cases of dens invaginatus in which there are serious periapical lesions or if the teeth have anatomical variations that do not allow access and cleaning of all parts of the same channel.<sup>23</sup>

The work shown in case 1 is an upper lateral incisor with normo-positive vitality in which it was surgically addressed as a first choice, as endodontic treatment was not indicated, but rather the resolution of periodontal intra-bone defects generated as a result of the dental malformation present. Obtaining that resolution was due to proceeding with the decontamination of the site and the correction of the anatomy, to then be able to seal the invagination defect with white color Trioxid Mineral Aggregate. It was decided to use this material because of its affinity with a moist environment, such as the sub-crestal root surface, but especially because it allows the periodontal ligament that you want to regenerate to "find new attack," or better, provides a valid adhesion surface and thus promotes creeping, a phenomenon which does not occur with the composite material. In fact, according to a recent study in vitro on the roots of perforated elements, the amount of fibroblasts migrating from periodontal ligament is statistically higher in the vicinity of the perforations repaired with MTA than perforations not repaired or repaired with other materials (amalgam, composites, comonomers and zinc oxide eugenol cement).<sup>24</sup>

Case 2 however refers to an upper right lateral necrotic incisor, clinically characterized by repeated abscess phenomena, by the presence of a vestibular fistula and 3 zones of radiolucency appreciable radiographically at an apical level and two on the profile of the mesial root. In this type of problem, you may experience an indirect interaction in this case between the pulp, the periodontal ligament and the oral cavity, so that bacteria from saliva could indirectly infect the endodontium, and subsequent necrosis led to the formation of the periapical lesion and periradicular lesions. Usually the patient does not notice the presence of an anomaly of the dens invaginatus until the onset of symptoms and clinical features like acute dento-alveolar abscess. In case 2, the more conservative solution was chosen given the difficulty of the case. In fact, using dedicated ultrasonic tips, it was decided to attack the unfavorable anatomy of the tooth coronal level only at, while in the third and apical middle one has totally abstained from orchestrating the channel, therefore making use of the instrumentation of the previous treatment and the use of root canal irrigating. Please note that the

case in question, beyond the anatomical difficulties, remains a clinical case of "endodontic retreatment," whose prognosis requires maximum atraumaticity. Regarding the recommended systems of root canal obturation, root canal filling with calcium hydroxide for a limited period of time to attempt apexification of the element could be indicated: the abnormal morphology of the root canal system and the presence of persistent apical humidity made for opting for a filling with MTA (PRO-ROOT, Maillefer).<sup>25</sup> This material formed hard tissue with consistency significantly higher than the gutta-percha and to a high degree of biocompatibility. Therefore, it has become an excellent alternative to conventional long-term therapy with calcium hydroxide.

## Conclusions

In the literature there are few studies that test the incidence of pulpal pathology in dens invaginatus. According to a study by Ridell in 2004, 11.3% of teeth that have had preventive sealing of invagination practiced have, however, subsequently manifested pulpal pathology.<sup>26</sup> It is of paramount importance in every way to recognize this type of dimorphism in time and to learn to manage the possible complications which, as shown, may possibly not be only as a result of endodontic nature, but unfortunately sometimes can also have a clear and eventual likely periodontal evolution.

This study proposes a rational and effective approach to address the difficulties that underlie this anatomical type of malformation. In both cases, in the first through regenerative periodontal therapy, in the second through orthograde endodontic therapy, we have tried to by-pass the anatomic problem seeking to treat the dimorphism, thereby returning the element to an anatomical simplicity that would make it easier for management of clinical complications.

## Clinical relevance

The upper lateral incisor can sometimes be a difficult element to treat endodontically, as it often has a narrow apical and pronounced curvature. Just as often, however, it can also be characterized by abnormalities of form, of embryological basis, which can determine the need for endodontic, periodontal, or combined treatment (endodontic and periodontal). The formulation of a proper diagnosis is therefore required in these cases, always unique, specific to which may be sometimes multi-disciplinary and specialist operational strategies.

## Conflict of interest

The authors state that there is no conflict of interest economic or otherwise by any of the authors themselves involved in the work presented.

## Study funding

The authors state that the manuscript presented was not supported by sources of funding.



## Acknowledgements

The authors wish to thank Mr. Paolo Pavan and Dr. Federico Ferraris, for the contribution made; Dr. Roberto Costa and the Scientific Directorate of the Italian Stomatological Institute of Milan in the person of the Director in charge, Dr. Luca De Micheli, both co-authors of the work presented here.

## References

- Alani A, Bishop K. Dens invaginatus. Part 1. Classification, prevalence and aetiology. *Int Endod J* 2008;**41**:1123–36.
- Hülsmann M. Dens invaginatus: aetiology, classification, prevalence, diagnosis and treatment considerations. *Int Endod J* 1997;**30**:79–90.
- Alani A, Bishop K. Dens invaginatus. Part 2. Clinical, radiographic features and management options. *Int Endod J* 2008;**41**:1137–54.
- Grahnén H, Lindahl B, Omnell K. Dens in dente. *Br Dent J* 1959;**88**:83–8. 111–22, 144–6.
- Mann RW, Dahlberg AA, Stewart TD. Anomalous morphologic formation of deciduous and permanent teeth in a 5-year-old 15th century child: a variant of the Ekman–Westborg–Juslin syndrome. *Oral Surg Oral Med Oral Pathol* 1990;**70**:89–94.
- Dassule HR, Lewis P, Bei M, Maas R, McMahon AP. Sonic hedgehog regulates growth and morphogenesis of the tooth. *Development* 2000;**127**:4775–85.
- Kattunen P, Laurikkala J, Itaranta P, Vainio S, Itoh N, Thesleff I. Association of FGF-3 and FGF-10 with signaling networks regulating tooth morphogenesis. *Dev Dyn* 2000;**219**:322–32.
- Chung KM, Salkin LM, Stein MD, Freedman AL. Clinical evaluation of a biodegradable collagen membrane in guided tissue regeneration. *J Periodontol* 1990;**61**:732–6.
- Camelo M, Nevins M, Schenk R, Simon M, Rasperini C, Lynch S, et al. Clinical radiographic, and histologic evaluation of human periodontal defects treated with Bio-Oss and Bio-Giude. *Int J Periodontics Restorative Dent* 1998;**18**:109–19.
- Rushton MA. A collection of dilated composite odontomas. *Br Dent J* 1937;**63**:65–85.
- Rushton MA. Invaginated teeth (dens in dente): contents of the invagination. *Oral Surg Oral Med Oral Pathol* 1958;**11**:1378–87.
- Atkinson SR. The permanent maxillary lateral incisor. *Am J Orthod* 1943;**29**:685–98.
- Hallett GE. The incidence, nature and clinical significance of palatal invagination in the maxillary incisors teeth. *Proc R Soc Med* 1953;**46**:491–9.
- Schulze C, Brand E. Über den dens invaginatus[[nkl]]Dens in dente. *Zahnärztliche Welt/Reform* 1972;**81**:569–73. 613–20, 653–60, 699–703.
- Ulmansky M, Hermel J. Double dens in dente in a single tooth. Report of a case and radiologic study of the incidence of small dens in dente. *Oral Sur Oral Med Oral Pathol* 1964;**17**:92–7.
- Vincent-Towen J. Dens invaginatus. *J Dent* 1974;**2**:234–8.
- Oehlers FA. Dens invaginatus (dilated composite odontome). I. Variations of the invagination process and associated anterior crown forms. *Oral Surg Oral Med Oral Pathol* 1957;**10**:1204–18.
- Khabbaz MG, Konstantaki MN, Sykaras SN. Dens invaginatus in a mandibular lateral incisor. *Int Endod J* 1995;**28**:303–5.
- Mupparapu M, Singer SR, Pisano D. Diagnosis and clinical significance of dens invaginatus to practicing dentist. *N Y State Dent J* 2006;**72**:42–6.
- Sauveur G, Roth F, Sobel M, Boucher Y. Surgical treatment of a periradicular lesion on an invaginated maxillary lateral incisor. *Int Endod J* 1997;**30**:145–9.
- Gondim Jr E, Setzer F, Zingg P, Karabucak B. A maxillary central incisor with three root canals: a case report. *J Endod* 2009;**35**:1445–7.
- Gound TG. Dens invaginatus – a pathway to pulpal pathology: a literature review. *Pract Periodont Aesthet Dent* 1997;**9**:585–94. quiz 596.
- Baumgart M, Hänni S, Suter B, Schaffner M, Lussi A. Dens invaginatus. Review of the literature and diagnostic and therapeutic guidelines. *Schweiz Monatsschr Zahnmed* 2009;**119**:697–714.
- Hakki SS, Bozkurt SB, Ozcopur B, Purali N, Belli S. Periodontal ligament fibroblast response to root perforations restored with different materials: a laboratory study. *Int Endod J* 2012;**45**:240–8.
- Coraini C, Castro D. Il trattamento endodontico del dente necrotico: peculiarità clinico-operative e considerazioni prognostiche The endodontic treatment of necrotic teeth: clinico-operative peculiarities and prognostic considerations *Il Dentista Moderno The Modern Dentist* 2013;**3**:28–54.
- Ridell K, Mejäre I, Matsson L. Dens invaginatus: a retrospective study of prophylactic invagination treatment. *Int J Paediatr Dent* 2001;**11**:92–7.